

Dept. of Anatomy,
Faculty of Medicine, Assiut University

**A MORPHOLOGICAL AND HISTOLOGICAL STUDY
ON THE POSTNATAL DEVELOPMENT
AND AGING CHANGES OF THE ALBINO
RAT HIPPOCAMPUS**
(With 4 Tables, 9 Figures and 4 Graphs)

By

M. EL-BADRY MOHAMED and E.S. KAMEL *

*: Dept. of Anatomy, Sohag Faculty of Medicine, South Valley University

**دراسة شكلية وهستولوجية على التطور بعد الولادة والتغيرات السنوية
لحصين الفار الابيض**

محمد البدرى محمد وعصام صلاح كامل

الحصين هو جزء من الجهاز الطرفى بالمخ المهم فى الذاكرة واسترجاع العلاقات المكانية. وقد وجد انه خاصة حساس لتكبير الخلايا العصبية نتيجة التقدم فى العمر لذلك كان الهدف من هذا العمل هو دراسة النمو بعد الولادة والتغيرات السنوية للطبقة المحببة لحصين الفار الابيض. استخدم فى هذه الدراسة عدد اربع وعشرون فارا ابيضا ذكرا، وقسموا الى اربعة مجموعات كل منها ستة فئران. كانت المجموعات المستخدمة حديثى الولادة وعشرة ايام وبالغة والمجموعة المسنة. قطعت رؤوس الفئران واستخرجت الامخاخ. عوملت العينات هيستولوجيا وصبغت بصيغة الجالوسيانين، وفحصت بالميكروسكوب الضوئى. كذلك عمل تقييم كمى لقياس الكثافة العصبية ومتوسط قطر الطبقة المحببة للحصين ومتوسط السمك الكلى للحصين ومتوسط سمك الطبقة المحببة لكل عمر. وكذلك تم تحديد كثافة الخلايا الدبقية لمجموعتى البالغين والمجموعة المسنة. اظهرت النتائج الهيستولوجية لحصين المجموعة السنوية ان خلايا الطبقة المحببة كانت كثيفة الصباغة، مكسرة وغير منتظمة فى الشكل بالمقارنة بالمجموعة البالغة. بينما اظهرت النتائج الكمية ان متوسط سمك الحصين الكلى، متوسط قطر الانوية العصبية زادت من عمر حديث الولادة لى عمر البلوغ بعدها نقصت فى العمر المسن. من ناحية اخرى، نقصت الكثافة العصبية للخلايا بمعدل ثابت من عمر حديث الولادة الى عمر البلوغ ثم تنقص فى العمر المسن وزادت كثافة الخلايا الدبقية فى العمر المسن. نستنتج من ذلك ان الحصين يتاثر بشدة نتيجة تقدم العمر الذى يمكن ان يفسر بعض اضطرابات السلوك والذاكرة فى الشيخوخة.

SUMMARY

Hippocampus is a part of the limbic system which is important in memory and recalling spatial relationship. It is particularly susceptible to cell loss associated with aging. So, aim of this work is to study the

postnatal development and aging changes of the granular layer of the hippocampus. Twenty four male albino rats were included in this study. They were divided into four groups, each of which was formed of six rats. The groups used were newly-born, ten days, adult and aged group. The animals were decapitated and the brains were extracted. The specimens were histologically processed and stained with Einarson's Gallocyanine stain. They were examined by the light microscopy. As well, morphometric evaluation was made to measure neuronal density, mean diameter of the nuclei of the granular layer of the hippocampus, mean total hippocampal thickness and mean thickness of hippocampal granular layer for each age group. Glial cell density for adult and aged groups was also done. These morphometric results were statistically analysed. The histological results showed that regarding hippocampus of the aged group, nuclei of the granular layer were deeply stained, fragmented and irregular in shape in comparison with adult. While, the morphometric results showed that mean total hippocampal thickness, mean diameter of the neuronal nuclei were increased from newly-born till adult then decreased along the aged group. On the other hand, neuronal density was decreased steadily from newly-born till the adult age, then it was decreased along the aged group. However, glial cell density was increased in the aged group.

In conclusion, the hippocampus is greatly affected by aging, which may explain some behavioral and memory disturbances in senility.

Key words: *Postnatal - development – aging – hippocampus – morphometry.*

INTRODUCTION

Hippocampus is the inferolateral part of the temporal lobe. It lies in the floor of the inferior horn of the lateral ventricle and deep to the parahippocampal gyrus (Crossman and Neary, 1999). The hippocampus consists of complexly folded layers of the dentate gyrus and cornu ammonis, the later being continuous through the subicular region with the parahippocampal cortex. The name stems from its supposed resemblance, in coronal section, to the profile of a sea-horse (Berry *et al.*, 1999). The dentate gyrus is considered a trilaminar cortical structure. Extending deeply from the hippocampal sulcus, it consists of a superficial molecular layer, an intermediate granular layer and a deep polymorphic layer.

As part of the limbic system, the principal functions of the hippocampus are in relation to memory and the emotional aspects of behavior (Crossman and Neary, 1999). Cognitive deficits following insults to the central nervous system-particularly those involving the hippocampus and related structures are often persistent and severely debilitating. Progress has been made in establishing the role of the hippocampus in integrating information in the formation of memory necessary for subsequent recollection of information. Hippocampus is particularly susceptible to decrease in total number of their cells associated with aging leading to disturbance of mood and memory (Bacon and Niles, 1983 and Crossman and Neary, 1999).

Many studies were done on other tissues and organs regarding aging changes; kamel (2001) on rat corpus striatum and El-Badry *et al.* (2002) on rat motor cerebral cortex. So, the aim of this work is to study the postnatal development and aging changes of the granular layer of the hippocampus, focusing on the quantitative changes.

MATERIALS and METHODS

Twenty four male albino rats were used in this work. They were brought from the Animal House at Faculty of Medicine, University of Assiut. The animals were subdivided into four age groups, six rats each. The ages of the groups were newly-born, ten days, adult (three months) and aged rats (28-29 months). 28-29 months rats are considered aged since 50% survival rate of the rats is 27 months. So, this age group is suitable for the research on aging (Matsumoto *et al.*, 1982). The animals were anaesthetized with ether, the heart was opened and perfused with saline to wash out the blood of the circulatory system, then with freshly prepared Bouin's fixative. The animals were decapitated, their skulls were opened and their brains were extracted.

The brains were histologically processed according to Drury and Wallington (1980). Morphometric evaluation was made using the morphometric equipment Leica Quantiment 500 MC image processing and analysis system located at The Department of Anatomy and Histology, Faculty of Veterinary Medicine, University of Assiut. The stereological techniques according to Weibel (1979) were made to measure:

1. Neuronal density for all the ages used in a defined measurable field ($10000\mu^2$).
2. Mean diameter of the neuronal nuclei for all the ages used.

3. Mean hippocampal thickness and mean thickness of the granular layer for all ages used.
4. Glial cell density for adult and aged groups.

The results were evaluated and statistically analysed using T-test.

RESULTS

A. Morphometrical results:

I. Total hippocampal thickness and mean thickness of the granular layer in different postnatal ages (Table 1 and Graph 1):

The total hippocampal thickness showed a statistically significant increase in thickness from newly-born through 10 days old albino rats and adults then a highly significant decrease was demonstrated in the aged rats when compared with the adults. Concerning the granular layer of the hippocampus there was a statistically significant increase in thickness from newly-born through 10 days old albino rats followed by a significant decrease in the adults compared with 10 days old albino rats and also a significant decrease in the aged compared with the adult albino rats.

Table 1: Total hippocampal thickness and mean thickness of the granular layer of the hippocampus (in μm) for different ages.

Age	Total hippocampal thickness Means \pm SD	Mean thickness of the granular layer Means \pm SD
Newly-born	116.29 \pm 6.7 a	65.19 \pm 6.25 a*
Ten days	170.63 \pm 16.73 b	74.97 \pm 6.39 b
Adult	400.21 \pm 13.16 c	54.84 \pm 3.3 c
Aged	250.15 \pm 16.77 d	37.41 \pm 0.98 d

Values with different letters in the same column are significantly different ($p < 0.01$)

* the significance p value between newly-born and ten days ($p < 0.05$)

II. Nuclear diameter of the granular layer of the the hippocampus in different postnatal ages (Table 2 and Graph 2):

The neuronal nuclei in the granular layer of the hippocampus showed a significant increase in mean diameter along 10 days old albino rats and adults. However, there was a non significant decrease in adults

compared with 10 days old albino rats. As well as significant decrease in the aged compared with adult albino rats.

Table 2: Mean nuclear diameter of the granular layer of the hippocampus (in μm) for different ages.

Age	Mean nuclear diameter Means \pm SD
Newly-born	5.11 \pm 39 a
Ten days	11.55 \pm 0.62 b
Adult	11.12 \pm 0.88 b
Aged	8.74 \pm 0.64 c

Values with different letters in the same column are significantly different ($p < 0.01$).

III. Neuronal density of the granular layer of the the hippocampus in different postnatal ages (Table 3 and Graph 3):

The neuronal density in the granular layer of the hippocampus showed a decrease in the number of neurons along 10 days old albino rats and adults followed by a decrease in the aged group.

Table 3: Neuronal density of the granular layer of the hippocampus for different ages.

Age	Neuronal density / Field
Newly-born	130
Ten days	60
Adult	50
Aged	40

IV. Glial density of the granular layer of the the hippocampus in adult and aged groups (Table 4 and Graph, 4):

The glial density in the granular layer of the hippocampus showed an increase in the number of glial cells along the aged group.

Table 4: Glial density of the granular layer of the hippocampus for adult and aged groups.

Age	Glial density / Field
Adult	6
Aged	8

B: Histological results:

1- Newly-born rat (Figs. 1, 2 &3):

The stratification of the sea-horse shaped hippocampus was evident into outer molecular layer, middle granular layer and inner polymorphic layer (Figs.,1, 2). The neurons of the granular layer of the hippocampus of the newly-born albino rat showed small sized deeply stained nuclei with small amount of Nissl's granules, Some cells have a vesicular nucleus (Fig. 3).

2- Ten days albino rat (Figs. 4 & 5):

The neurons of the granular layer of the hippocampus of ten days albino rat showed moderate sized rounded cells with vesicular nuclei and moderate amount of Nissl's granules (Fig.5).

3- Adults albino rat (Figs. 6 &7) :

The neurons of the granular layer of the hippocampus of adult albino rat showed moderate sized rounded cells which is less than that of ten days with vesicular nuclei and moderate amount of Nissl's granules (Fig. 7).

4- Aged albino rat (Figs. 8 & 9):

The neurons of the granular layer of the hippocampus of aged albino rat showed small sized cells with irregular outlines the nuclei are distorted with small amount of Nissl's granules, also there is an increase in the number of glial cells (Fig.9).

DISCUSSION

Many quantitative and histologic studies were done on different brain regions of the rat regarding the postnatal development and aging changes; corpus striatum (Kamel, 2001) and cerebral motor cortex (El-Badry *et al.*, 2002). So far, in the available literatures, the same type of studies on the rat hippocampus is lacking. It is well known that, the hippocampus is very important in memory (Crossman and Neary, 1999). Also, it is one of the first regions to be affected by degenerative process that leads to Alzheimer disease (Hof, *et al.*, 2003). So, we tried to through the light on the postnatal and aging changes of the rat hippocampus using morphometric and histological methods.

DISCUSSION OF THE MORPHOMETRIC RESULTS:

(A) Postnatal development:

1. Total hippocampal thickness:

Our results reported that the total cortical thickness displayed an increase in thickness from newly-born till adult aged rats. This coincides with the previous reports of Fritschy and Garey (1986) in the developing Visual cortex of Marmoset monkey, Kamel (2001) in rat corpus striatum and EL-Badry *et al.* (2002) in rat motor cortex. This could be explained by the expansion of the nuclear volume due to increase in the mean diameter of the nuclei and the greatly increasing arborization of the dendritic trees of the neurons.

2. Neuronal density of the granular layer of the hippocampus:

The results of this study revealed that the neuronal density of the granular layer of the hippocampus decreased gradually from newly-born albino rat till adult. This is in agreement with previous studies findings of Kamel (2001) on rat corpus striatum, Masliukov (2001) in cat stellate ganglion and EL-Badry *et al.* (2002) in rat motor cortex. The high cell density of newly-born granular layer could be explained by overcrowding of the cells due to immaturity of newlyborn neurons (Tepper and Trent, 1993). The gradual decrease in neuronal density can be explained by the cell death which is an important feature in the late differentiation (Burt, 1993).

3. Mean diameter of neuronal nuclei:

The result of our finding revealed that the mean diameter of neuronal nuclei increased from newly-born till the adult. This is in harmony with previous reports of, Bosseila *et al.* (1983) in rat substantia nigra and EL-Badry *et al.* (2002) in rat motor cortex and this may be explained by increase in the volume of nucleoplasm due to amplification of DNA to form rRNA needed for the synthesis of some specific proteins needed during nerve cell differentiation.

(B) Aging changes:

1. Total hippocampal thickness:

Our results revealed that the total hippocampal thickness of aged albino rat decreased significantly in aged albino rat compared with that of control. This is in agreement with previous reports of Soininen *et al.* (1994) in human hippocampus, Pantel *et al.* (2003) in human parahippocampus gyrus and Redwine *et al.* (2003) in mice dentate gyrus. This may be explained by decreased neuronal density and diameter of neuronal nuclei with aging.

2. Neuronal density of the granular layer of the hippocampus:

The result of our finding revealed that the neuronal density of the granular layer of the hippocampus of aged albino rat was decreased than of adult rat. This is in agreement with previous reports on human [Ball (1977), Devany and Johnson (1984), Adam and Victor (1989), West *et al.* (1994)] and on rat [Shetty and Turner (1999)]. Several mechanisms may explain the decrease of neuronal density in aged rat including poor glucose tolerance which influence hippocampal structure and function (Convit *et al.*, 2003), decrease of the intracellular enzymes and neurotransmitters (Adams and Victor, 1989) and damaged blood vessels that results in structural deterioration of the hippocampus (Landfield, 1977).

Our results disagree with previous reports of Von Bohlen and Unsicker (2002) on mice and Gallagher *et al.* (2003) on rat. They reported small but insignificant reduction in the neuronal density of the hippocampus and mentioned that the mechanisms underlying age related dysfunction depend on parameters other than neuronal density.

3. Mean nuclear diameter of the granular layer of the hippocampus:

The result of our study revealed that the mean nuclear diameter of the granular layer of the hippocampus of aged albino rat was decreased than that of adult rat. This is in accordance with previous reports of Alvarez *et al.* (1998) in human medial vestibular nucleus, Kamel (2001) in rat corpus striatum and EL-Badry *et al.* (2002) in rat motor cortex. This may be explained by substantial losses of rDNA in aged neurons (Strehler, 1983).

Our finding revealed that the glial cell density in the granular layer of the hippocampus of aged albino rat was greater than that of adult. This is in agreement with Zhu *et al.* (2003) in rat hippocampus and in accordance with Kamel. (2001) in rat corpus striatum and EL-Badry *et al.* (2002) in rat motor cerebral cortex. This may be related to neuronal degeneration and increased glial responsiveness with aging (Zhu *et al.*, 2003).

II. DISCUSSION OF THE HISTOLOGICAL RESULTS:

Our findings that the histological changes the granular layer of the hippocampus during aging as diminished Nissl's granules and chromatolysis (nuclei became deeply stained and fragmented). This coincides with previous reports of previous reports of Kamel (2001) in rat corpus striatum and EL-Badry *et al.* (2002) in rat motor cortex and

Hof *et al.* (2003) in the entorhinal cortex .This may be related to degenerative cellular process which primarily affects the entorhinal cortex and hippocampus during aging (Hof *et al.*, 2003), programmed cell death and progressive decline of neuronal metabolic competence with aging (Bertoni-freddari *et al.*, 1993 and Convit *et al.*, 2003).

In conclusion, the hippocamal cells are greatly affected, both quantitavely and qualitatively, by aging which explain the memory deficits occured in senility.

AKNOLEDGMENT

We wish to thank Dr. Zayed, A. E. Assistant Professor in Anatomy, Department of Anatomy and Histology, Faculty of Veterinary Medicine, University of Assiut.for his help in the morphometric results of this study.

REFERENCES

- Adams, R.D. and Victor, M. (1989):* Neurology of aging. In principles of neurology. 4th Edition, McGraw-Hill information services company. NewYork, Mexico, Tokyo and Toronto. Ch.29. Pp:491-495.
- Alvarez, J.C.; Diaz, C.; Suarez, C.; Fernandez, J.A.; Gonzalez, D.R.C.; Navarro, A. and Tolviva, J. (1998):* Neuronal loss in human medial vestibular nucleus. *Anat. Rec.*,251(4):431-438.
- Bacon, R.L. and Niles, N.R. (1983):* Medical Histology. A text-atlas with introductory pathology. Spring-Verlag, New York, Heidelberg, Berlin. pp. 445-459.
- Ball, M.J. (1977):* Neuronal loss, neurofibrillary tangles and granulovacuolar egeneration in the hippocampus with aging and dementia.Aquantitative study. *Acta Neuropathol*, 28, 37(2):111-118.
- Berry, M.M.; Standring, S.M. and Bannister, L.H. (1999):* Nervous system, hippocampal formation. In: Gray's anatomy. Edited by Churchill Livingstone, Edinburgh, New York, Toronto. 38 ed., pp:1123- 1141.
- Bertoni-Freddari, C.; Fattoretti, P.; Casoli, T.; Spagna, C. and Ulrich, J. (1993):* Morphological plasticity of synaptic mitochondria during aging. *Brain Res.*, 628(1-2): 193- 200.

- Boseila, A.A.; Hassan, M.I. and Abdel-All, M.E. (1983):* Quantitative studies on the substantia nigra of the rat's brain at different ages. *Eg. J. Histol.*, 6 (2):329- 337.
- Burt, A.M. (1993):* Histology and fine structure of nervous tissue. In: Textbook of Neuroanatomy. Edited by Saunders company. Philadelphia, London and Toronto. Pp: 31-43.
- Convit, A.; Wolf, O.T.; Tarshish, C.; Deleon, M.G. (2003):* Reduced glucose tolerance is associated with poor memory performance and hippocampal atrophy among normal elderly. *Proct. Natl. Acad. Sci.*, 100(4):2019-2022.
- Crossman, A.R. and Neary, D. (1999):* Neuroanatomy. An illustrated colour text. Edited by Churchill Livingstone. Edinburgh, London, Toronto. pp 145-142. New York, Philadelphia, St Louis, Sydney.
- Devaney, K.O. and Johnson, H.A. (1984):* Changes in cell density within the human hippocampal formation as a function of age. *Gerontology*, 30:100-108.
- Drury R.A. and Wallington E.A. (1980):* Carleton's histological technique, fifth edition, Oxford university press, New York, Toronto, Hong Kong and Tokyo.
- EL-Badry, M.; Kamel, E.S. and Zayed, A.E. (2002):* Postnatal development and aging changes of the motor cortex of albino rat (Morphometry and histological study). *South Valley medical Journal*, 6(2): 289-310.
- Fritschy, J.M. and Garey, L.J. (1986):* Quantitative changes in morphological parameters in the developing visual cortex of the marmoset monkey. *Brain Res*, 394(2):173-188.
- Gallagher, M.; Bizon, J.L.; Hoyt, E.C.; Helm, K.A. and Lund, P.K. (2003):* Effects of aging on the hippocampal formation in a naturally occurring animal model of mild cognitive impairment. *Exp. Gerontol.*, 38(1-2): 71-77.
- Giap, B.; Jong, C.; Ricker, J.; Cullen, N. and Zafonte, R. (2000):* The hippocampus: anatomy, pathophysiology and regenerative capacity. *J. Head Trauma Rehabil.*; 15: 875-894.
- Hof, P. R.; Bussiere, T.; Gold, G.; Kovari, E.; Giannakopoulos P.; Bouras, C.; Perl, D.P. and Morrison, J.H. (2003):* Stereologic evidence for persistence of viable neurons in layer II of the entorhinal cortex and the CA1 field in Alzheimer disease. *J. Neuropathol. Exp. Neurol.*, 62(1): 55-67.

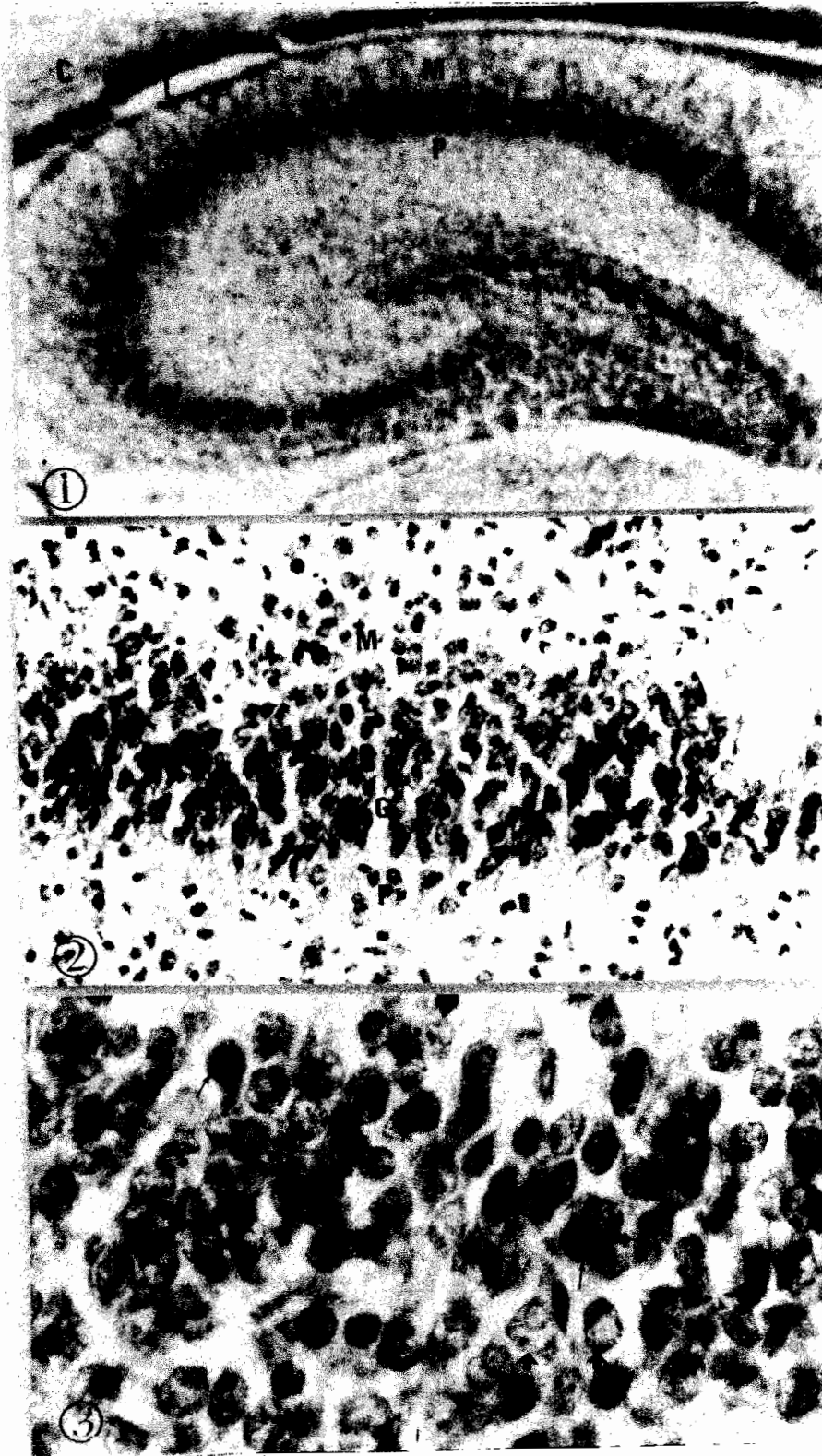- Kamel, E.S. (2001):* Postnatal development and aging changes of the corpus striatum of the albino rat. Ph.D thesis(Anatomy). Sohag Faculty of Medicine, South Valley University.
- Landfield, P.W.; Rose, G.; Sandles, L.; Wohlstadter, T.C. and Lynch, G. (1977):* Patterns of astroglial hypertrophy and neuronal degeneration in the hippocampus of aged memory-deficient rat. *J. Gerontol.*, 32 (1): 3-12.
- Masliukov, P.M. (2001):* Sympathetic neurons of the cat stellate ganglion in postnatal ontogenesis: morphometric analysis. *Auton Neurosci.*, 89(1-2):48-53.
- Matsumoto, A.; Okada, R. and Arai, Y. (1982):* Synaptic changes in the hypothalamic arcleus nucleus of old male rats. *Exp .Neurol.*, 78: 583- 590.
- Pantel, J.; Kratz, B.; Essig M. and Schrodel, J. (2003):* Parahippocampal volume deficits in subjects with aging associated cognitive decline. *Am. J. psychiatry*,160(2): 382-397.
- Redwine, J.M.; Kosofsky, B.; Jacobs, R.E.; Games, D.; Reilly, J.F.; Morrison, J.H.; Young, W.G. and Bloom, F.E. (2003):* Dentate gyrus volume is reduced before onset of plaque formation in PDAPP mice: a magnetic resonance microscopy and stereologic analysis. *Proc. Natl. Acad. Sci.*,100(3):1381- 1386.
- Shetty, A.K. and Turner, D.A. (1999):* Vulnerability of the dentate gyrus to aging and intracerebroventricular administration of kainic acid.*Exp.Neurol.*,158(2):491- 503.
- Soininen, H.S.; Partanen, K.; Pitkanen, A.; Vainio, P.; Hanninen, T.; Hallikainen, M.; Koivisto, K. and Riekkinen, P.J.Sr. (1994):* Volumetric MRI analysis of the amygdala and the hippocampus in subjects with age associated memory impairment: correlation to visual and verbal memory. *Neurology*, 44(9):1660- 1668.
- Tepper, J.M. and Trent, F. (1993):*In vivo studies of the postnatal development of rat neostriatal neurons. In: *Chemical signalling in the basal ganglia*. Edited by Arbuthnott, G. W. and Emson, P. C. Elsevier Science Publishers, Amsterdam, 99,pp:35- 50.
- Von Bohlen U.H.O. and Unsicker K.(2002):* Morphological alterations in the amygdala and hippocampus of mice during aging. *Eur. J. Neurosci.* 16(12): 2434-40.
- Weibel, E.R. (1979):* Stereological methods. Volume. 1: Practical methods for biological Morphometry. Academic press.

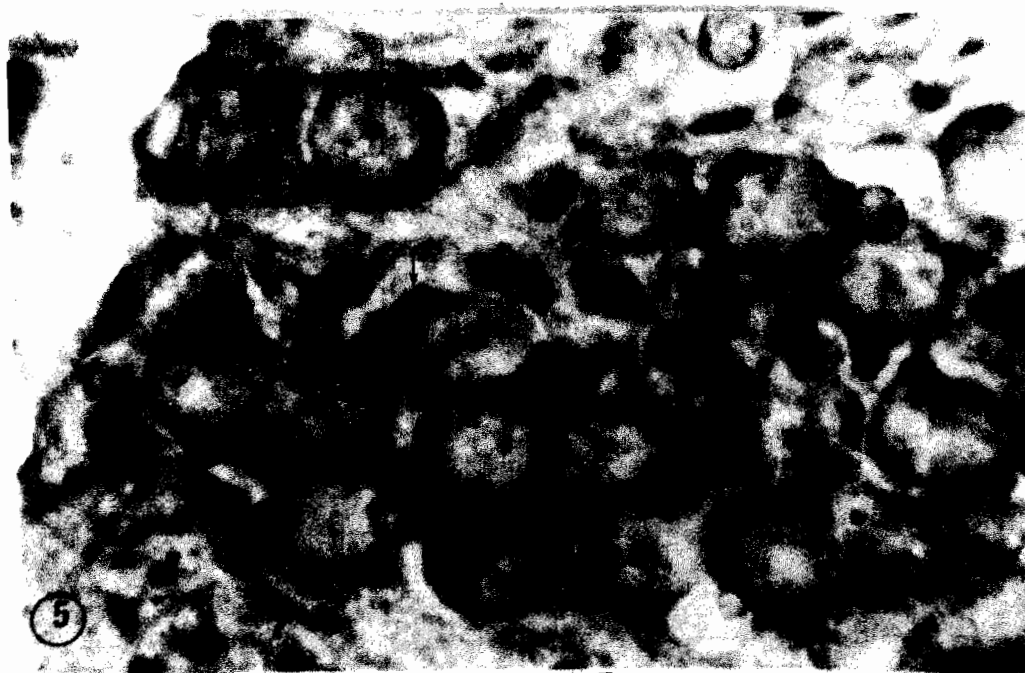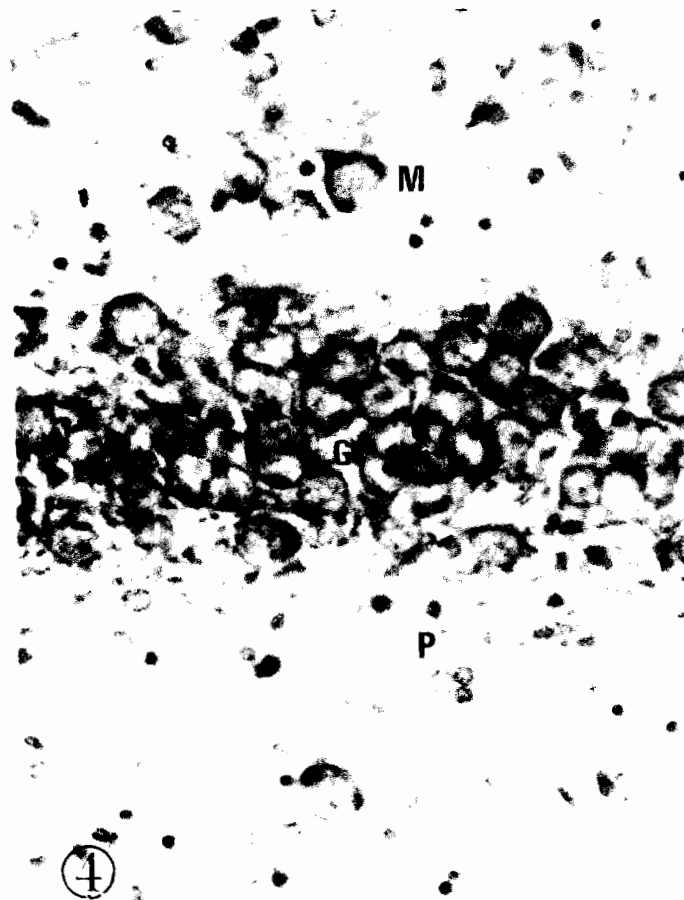
- West, M.J.; Coleman, P.D.; Flood, D.G. and Troncoso, J.C. (1994):* Differences in the pattern of hippocampal neuronal loss in normal aging and Alzheimer's disease. *Lancet*, 344(8925): 769-772.
- Zhu, W.; Umegaki, H.; Shinkai, T.; Kurotani, S., Suzuki, Y., Endo H and Iguchi, A. (2003):* Different glial reactions to hippocampal stab wounds in young adult and aged rats. *J. Gerontol. A. Biol. Sci. Med. Sci.*, 58(2):117- 122.

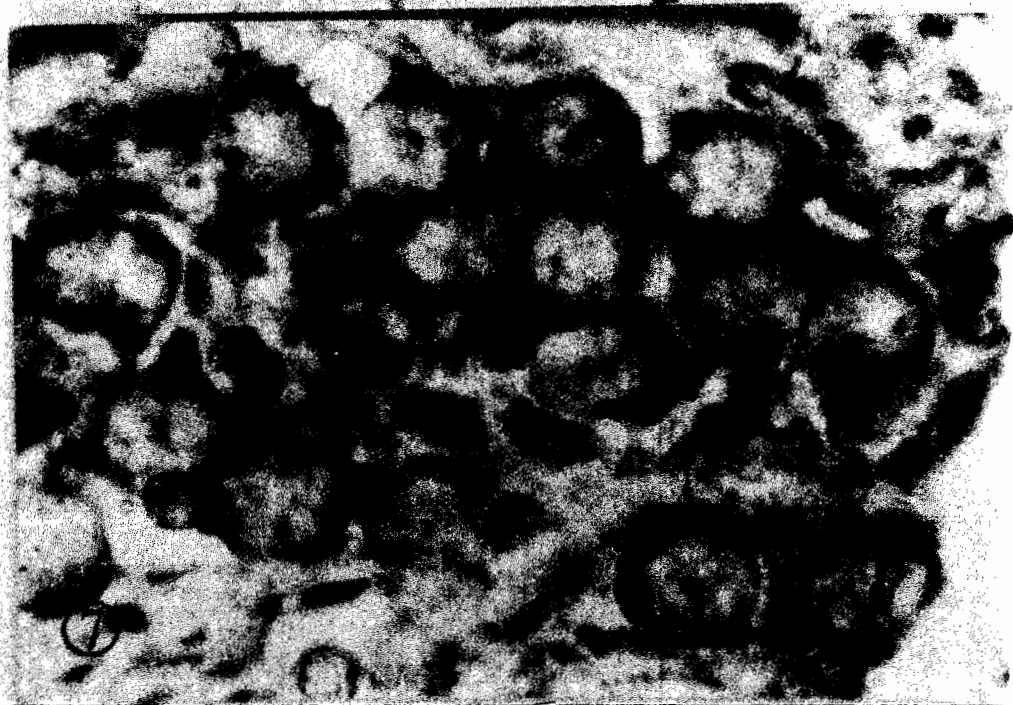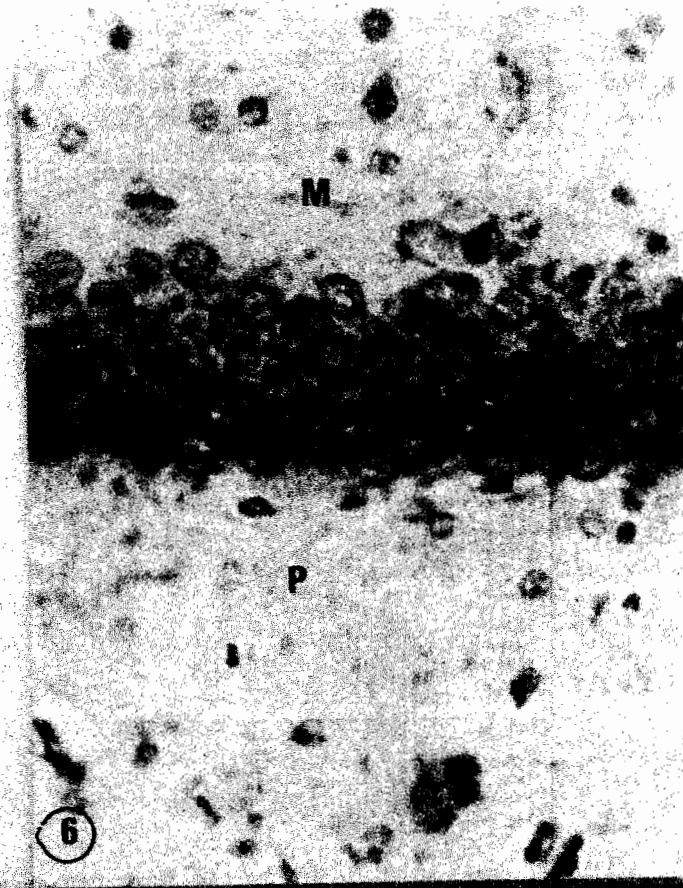
LEGEND OF FIGURES

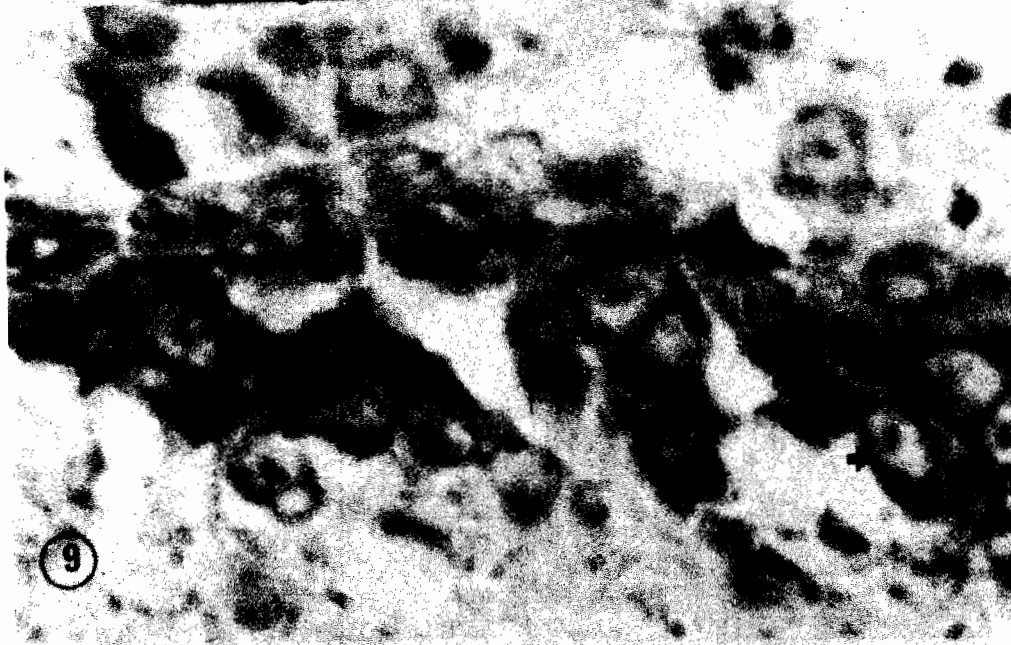
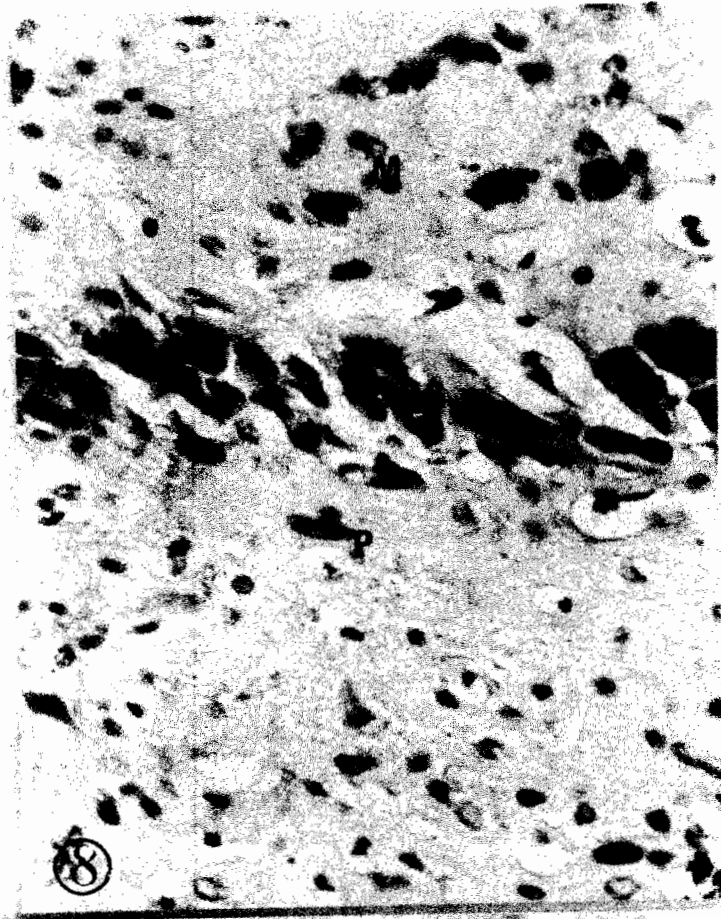
- Fig. 1:** A coronal section of the newly-born rat brain showing the sea-horse shaped, normal position and stratification of the hippocampus; Molecular layer (M), Granular layer (G) and Polymorphic layer (P). Notice that: C = Cerebral cortex and L = Lateral ventricle. (Einarson's Galloxyanine x 100)
- Fig. 2:** A coronal section of the newly-born rat brain showing the normal position and stratification of the hippocampus; Molecular layer (M), Granular layer (G) and Polymorphic layer (P). (Einarson's Galloxyanine x 400)
- Fig. 3:** A coronal section of the granular layer of the hippocampus of the newly-born albino rat showing small sized deeply stained nuclei with small amounts of Nissl's granules (long thin arrow), Some cells have a vesicular nucleus (short thick arrow). (Einarson's Galloxyanine x 1000)
- Fig. 4:** A coronal section of the hippocampus of the ten days albino rat showing the normal position and stratification of the hippocampus; Molecular layer (M), Granular layer (G) and Polymorphic layer (P). (Einarson's Galloxyanine x 400)
- Fig. 5:** A coronal section of the granular layer of the hippocampus of the ten days albino rat showing moderate sized rounded cells with vesicular nuclei and moderate amount of Nissl's granules (arrow). (Einarson's Galloxyanine x 1000)
- Fig. 6:** A coronal section of the hippocampus of adult albino rat showing the normal position and stratification of the hippocampus; Molecular layer (M), Granular layer (G) and Polymorphic layer (P). (Einarson's Galloxyanine x 400)

- Fig. 7:** A coronal section of the granular layer of the hippocampus of adult albino rat showing moderate sized rounded cells which is less than that of ten days with vesicular nuclei and moderate amount of Nissl's granules (arrow). (Einerson's Gallocyanine x 1000)
- Fig. 8:** A coronal section of the hippocampus of aged albino rat showing the normal position and stratification of the hippocampus; Molecular layer (M), Granular layer (G) and Polymorphic layer (P).(Einarson's Gallocyanine x 400)
- Fig. 9:** A coronal section of the granular layer of the hippocampus of aged albino rat showing small sized cells with irregular outlines (thick short arrow), the nuclei are distorted with small amount of Nissl's granules, also there is increase in the number of glial cells (thin arrow). (Einarson's Gallocyanine x 1000).

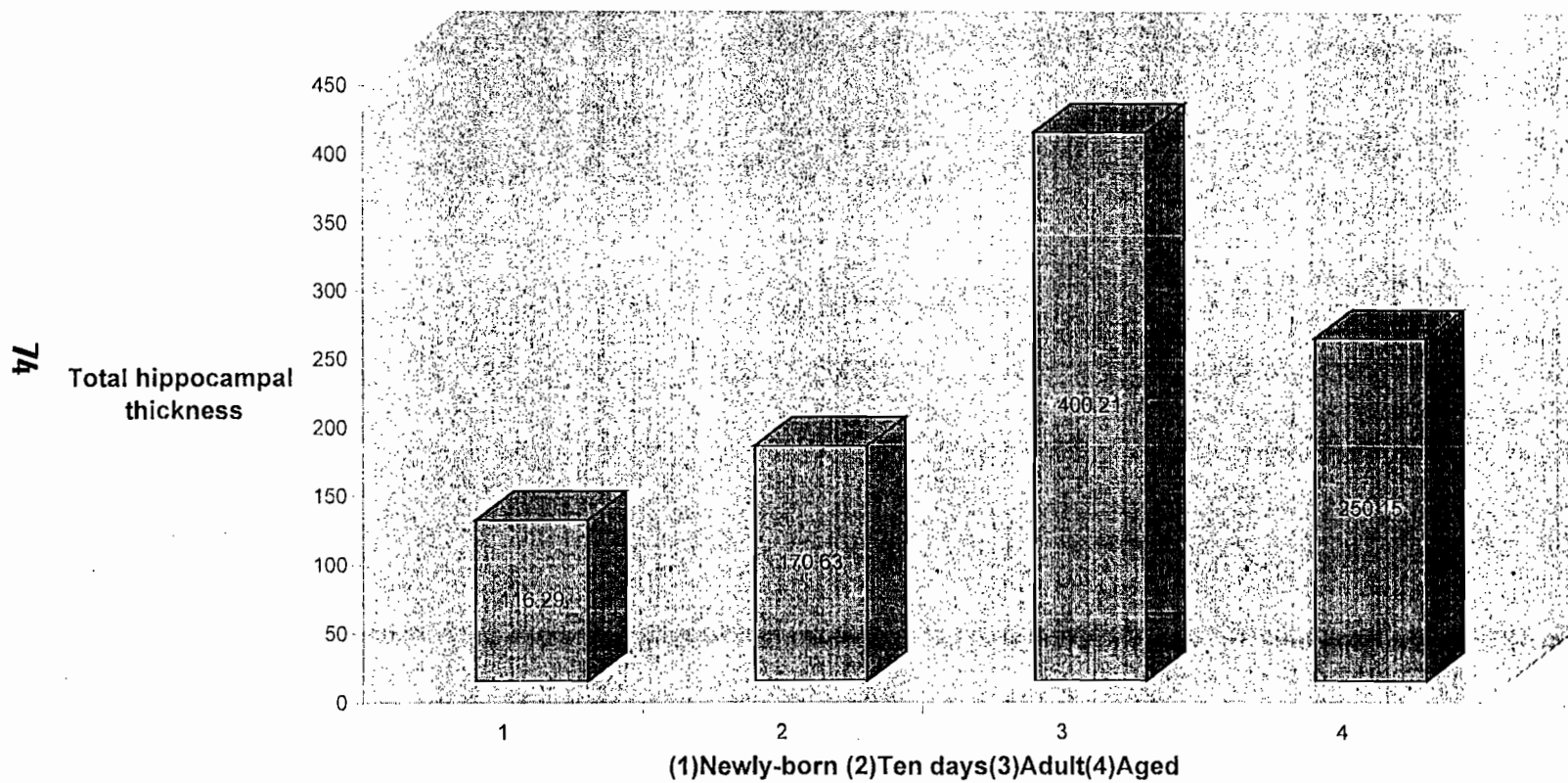








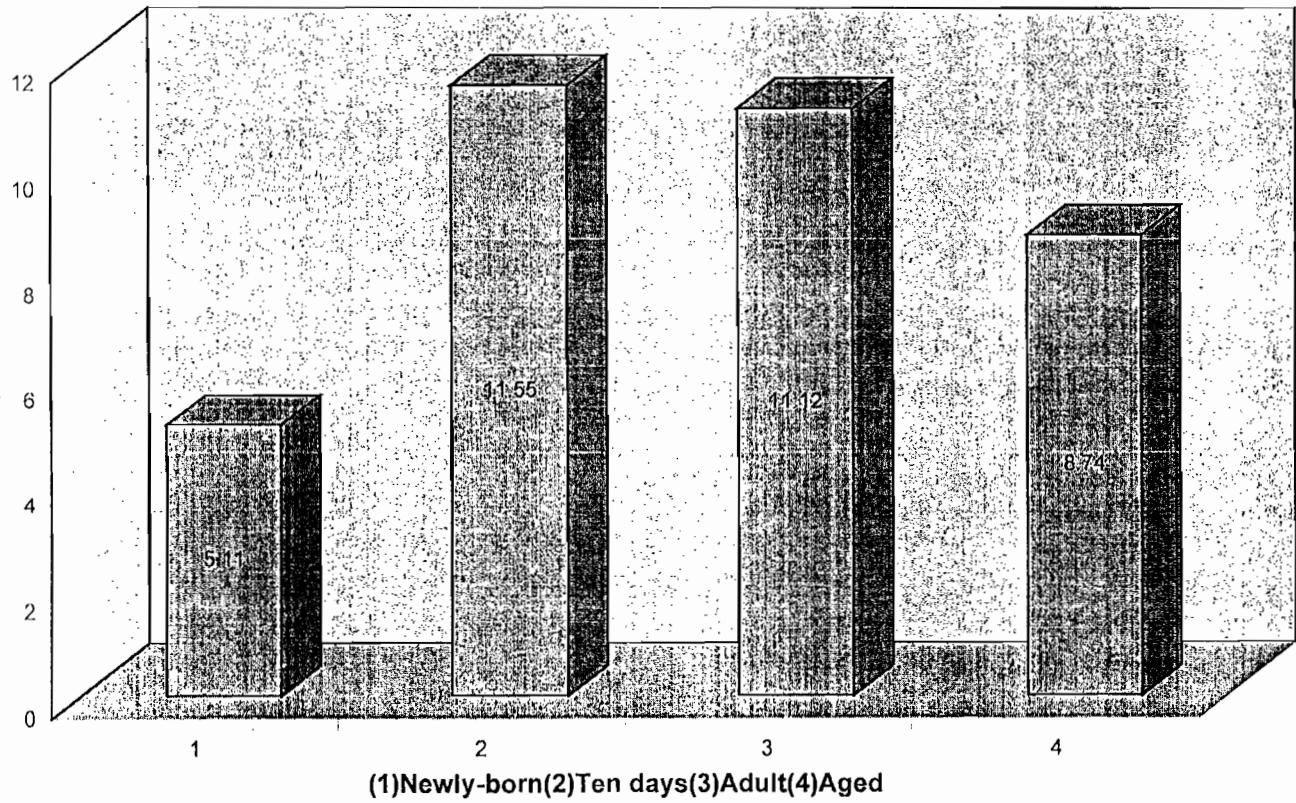
Graph(1) Total hippocampal thickness for different ages



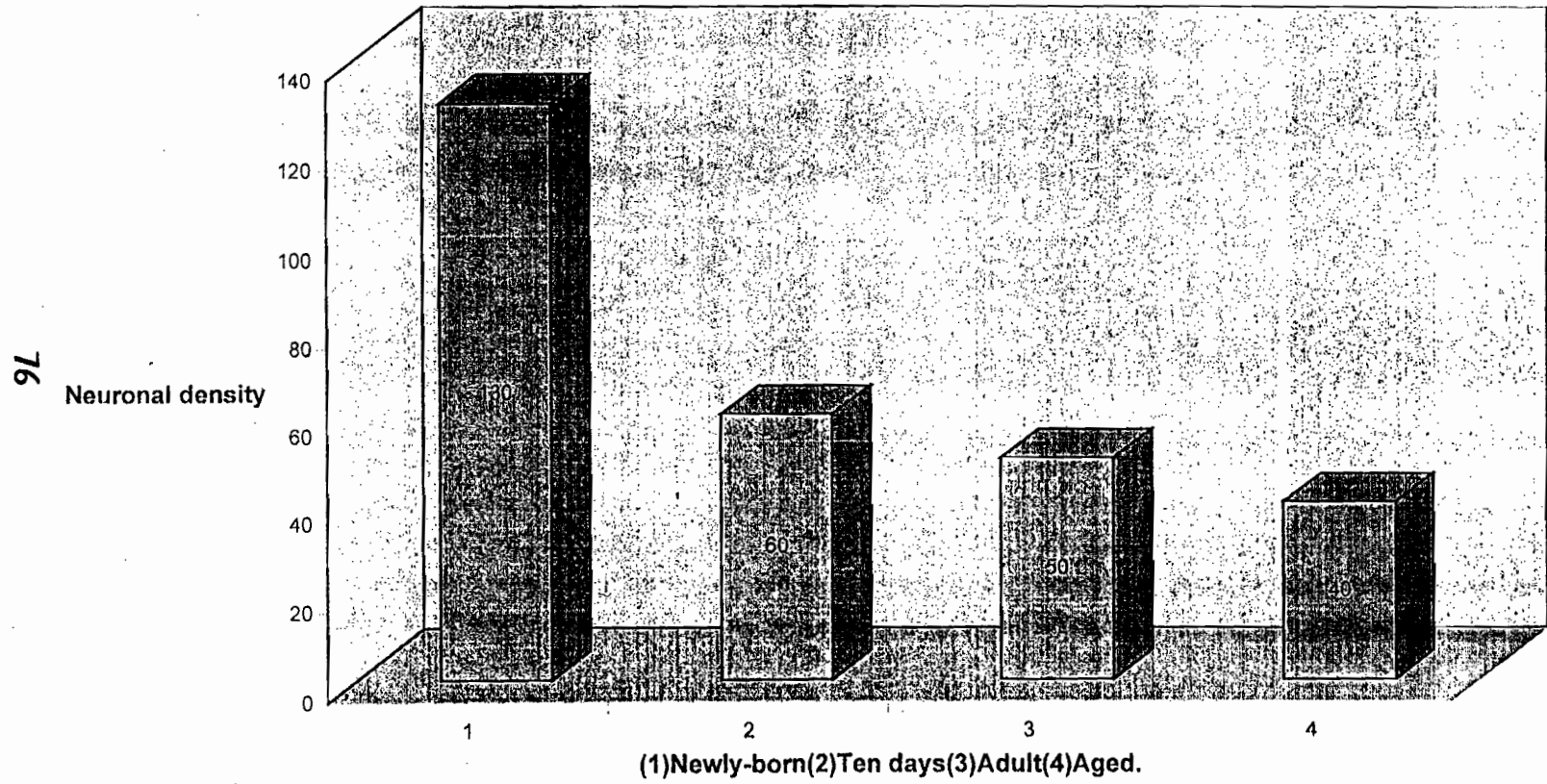
Graph(2): Mean nuclear diameter of the granular layer of the hippocampus in different ages.

75

Mean nuclear diameter



Graph(3):Neuronal density of the granular layer of the hippocampus for different ages.



Graph(4):Glial cell density for adult and aged group rats.

