

STUDIES ON THE EFFICACY OF GARLIC EXTRACT ON CRYPTOSPORIDIOSIS IN EXPERIMENTALLY INFECTED MICE

WAHBA A.A.

Animal Health Research Institute, Agricultural Research Centre, Dokki, Giza, Egypt

(Manuscript received 24 Decembre 2002)

Abstract

The present work was conducted to detect the efficacy of garlic extract on *Cryptosporidium parvum* in experimentally infected mice. Thirty six Swiss mice aging 2 – 3 weeks were divided into 3 groups, each of 12 mice. Group I was the infected treated, group II was the infected non-treated control and group III was the non-infected non-treated control one. The mice in the infected groups were given 10^6 *C. parvum* oocysts. Garlic extract was given orally to mice of the treated group at a dose of 1 ml / 100 g body weight. Faecal smears from mice of each group were examined every 2 days after staining by modified Ziehl Neelsen staining technique and the oocysts were counted in 100 randomly selected field at X 1000 magnification.

The results showed that, there was a significant difference in the mean values of oocysts shedding between the infected treated group I and the infected non-treated control group II from the 7th day post-treatment (d.p.t.) (mean \pm SD; 25.17 ± 5.56 and 40.33 ± 16.72 respectively) until the termination of the experiment on the 25th d.p.t. (mean \pm SD) 0.94 ± 1.43 and 55.75 ± 19.79 respectively). The therapeutic efficacy of garlic extract on cryptosporidiosis in experimentally infected mice was 58.3%. At the termination of the experiment on the 25th d.p.t., the mice of the three groups were sacrificed and the ilea were collected for histopathological examination. The villi of ilea in the infected-treated mice in group I showed no pathological changes and regained their normal appearance. They showed neither atrophy nor desquamation of villi when compared to ilea of infected-non treated control mice. At the end of experiment, some infected-treated mice (5/12) belonging to group I showed some degrees of oocysts count in faeces, but didn't show neither atrophy nor desquamation of villi.

INTRODUCTION

Cryptosporidiosis is a protozoan zoonotic parasite of mammals in which the immune status plays an important role in the progress of the parasite. It inhabits the intestinal tract primarily of neonatal farm animals, especially calves and causes varying degrees of diarrhoea (Soulsby, 1982). The most severe lesions are seen in the posterior jejunum and ileum characterized by villous blunting and atrophy (Koudela and Jiri, 1997). In immunocompromised hosts, the disease is persistent and frequently pro-

gresses to life-threatening illness. The immune mechanisms responsible for acquired resistance to *Cryptosporidium parvum* are not well defined, thus, the development of effective therapeutic agents available to combat this parasite is still under experimentation, due to an incomplete understanding of the mechanisms of resistance recovery from *Cryptosporidia* (Zu *et al.*, 1992).

Many drugs have been tested against *Cryptosporidium* infection in mammals (Fayer, 1993), but, only a few have shown detectable anticryptosporidial activity (Tzipori, 1998).

Garlic (*Allium sativum*) has a wide spectrum of actions; not only as antibacterial, antiviral, antifungal and antiprotozoal, but it also has beneficial effects on the immune system. Allicin, ajoene and organosulfides from garlic are effective antiprotozoals (Harris *et al.*, 2001).

Garlic extract proved effective against various protozoan parasites including *Trichomonas vaginalis* (Lang and Zhang, 1981), *Trichomonas gallinae* (Abu El-Magd and El-Badri, 1991), *Trypanosoma*, *Entamoeba histolytica* and *Giardia lamblia* (Lun *et al.*, 1994), *Plasmodium* (Perez *et al.*, 1994) and *Leishmania* (McClure *et al.*, 1996).

Thus, in the present study, the efficacy of garlic extract on *Cryptosporidium parvum* in experimentally infected mice was conducted.

MATERIALS AND METHODS

Identified oocysts of *Cryptosporidium parvum* were originally obtained from naturally infected cattle calves slaughtered at El-Bassatine abattoir on different occasions. The oocysts were collected by Sheather's sugar solution, then, stored in 2.5% potassium dichromate at 4°C until use within one month (Rasmussen *et al.*, 1995).

For experimental infection, 36 susceptible Swiss mice aging 2 – 3 weeks, kept at Animal Health Research Institute and offered food and water *ad libitum* were used. They were divided into 3 groups, each of 12 mice. Group I was the infected-treated, group II was the infected non-treated control and group III was the non-infected non-treated control one. Each mouse of groups I and II was infected with 10⁹ *Cryptosporidium parvum* oocysts using a special gastric tube. One week later, faecal pellets were collected per rectum from each mouse of both groups, and faecal smears were examined by modified Ziehl Neelsen staining technique (Henriksen and Pohlenz, 1981). After confirmation of infection, each mouse of group I received garlic extract daily till the termination of the experiment at a dose of 1 ml / 100 g body weight of mice using the

gastric tube. The extract was obtained from a special seller. Then, faecal smears from mice of the three groups were examined every 2 days, for as long as the 25th day post-treatment (d.p.t.) when they were sacrificed. The oocysts were counted and their number was compared in both groups I and II in 100 randomly selected fields at X 1000 magnification.

Immediately after sacrifice on the 25th d.p.t., the ilea of mice of the three groups were collected and fixed in 10% formalin, embedded in paraffin, sectioned at 5 microns and stained with haematoxylin and eosin (Harris, 1898) for histopathological examination. Differences between faecal oocysts shedding among treated and control groups were tested for statistical analysis by ANOVA test with the aid of SPSS (Win. 98). Differences were considered significant at $p < 0.05$.

RESULTS

Table 1 shows the mean of oocysts shedding among mice of both groups I and II. There was a significant difference in the mean values of oocysts shedding between the infected treated group I and the infected non-treated control group II, from the 7th d.p.t. (25.17 ± 5.56 and 40.33 ± 16.72 , respectively) ($p = 0.01$) until the 25th d.p.t. (0.94 ± 1.43 and 55.75 ± 19.79 , respectively) ($p = 0.00$). This was evident in Fig. 1.

Table 2 shows the efficacy of therapeutic effect of garlic extract on *C. parvum* in experimentally infected mice in group I on the basis of the number of negative cases post-treatment. It was 0% from the 1st d.p.t. until the 7th d.p.t., while, it was 25% on the 10th d.p.t., 41.7% on the 13th and 22nd d.p.t. and 58.3% on the 16th, 19th and 25th d.p.t.

Concerning histopathological examination of the villi of ilea in the three groups, Fig. 2 showed the status of the villi in infected-treated mice at the termination of experiment on the 25th d.p.t. The villi showed no pathological changes and regained their normal appearance resembling those in non-infected non-treated control group III (Fig. 3). On the contrary, the villi of infected non-treated control mice showed atrophy and most of them were desquamated (Fig. 4).

At the termination of the experiment, in which the mean \pm SD of cryptosporidial oocysts excreted from mice of infected-treated group I was 0.94 ± 1.43 , some mice (5 of 12) showed normal appearance of villi (Fig. 5) like those of mice in non-infected non-treated control group III.

During the whole period of experiment, the mice of non-infected non-treated control group III did not show any cryptosporidial oocysts shedding.

Table 1. Mean values of cryptosporidial oocysts shedding from mice, per 100 microscopical fields, in infected-treated group I and infected non-treated control group II

Days post-treat.	Oocysts shedding in infected-treated group I of mice (mean±SD)	Oocysts shedding in infected non-treated control group II of mice (mean±SD)	p value
1	41.75±19.93	47.33±22.03	0.52
4	35.08±12.71	44.33±15.69	0.13
7	25.17±5.56	40.33±16.72	0.01*
10	5.54±6.62	44.50±18.30	0.00*
13	1.06±1.78	55.75±20.82	0.00*
16	0.40±0.76	53.42±22.65	0.00*
19	2.28±3.87	54.92±23.77	0.00*
22	1.08±1.36	54.33±21.97	0.00*
25	0.94±1.43	55.75±19.79	0.00*

* Significantly different at $p < 0.05$

SD : Standard deviation

Table 2. The efficacy of treatment with garlic extract on cryptosporidial infection in experimentally infected mice in group I, on the basis of number of negative cases post treatment.

Days post treatment	Number of infected cases	Number of negative cases	Treatment efficacy (%)
1 st	12/12	0/12	0
4 th	12/12	0/12	0
7 th	12/12	0/12	0
10 th	9/12	3/12	25
13 th	7/12	5/12	41.7
16 th	5/12	7/12	58.3
19 th	5/12	7/12	58.3
22 nd	7/12	5/12	41.7
25 th	5/12	7/12	58.3

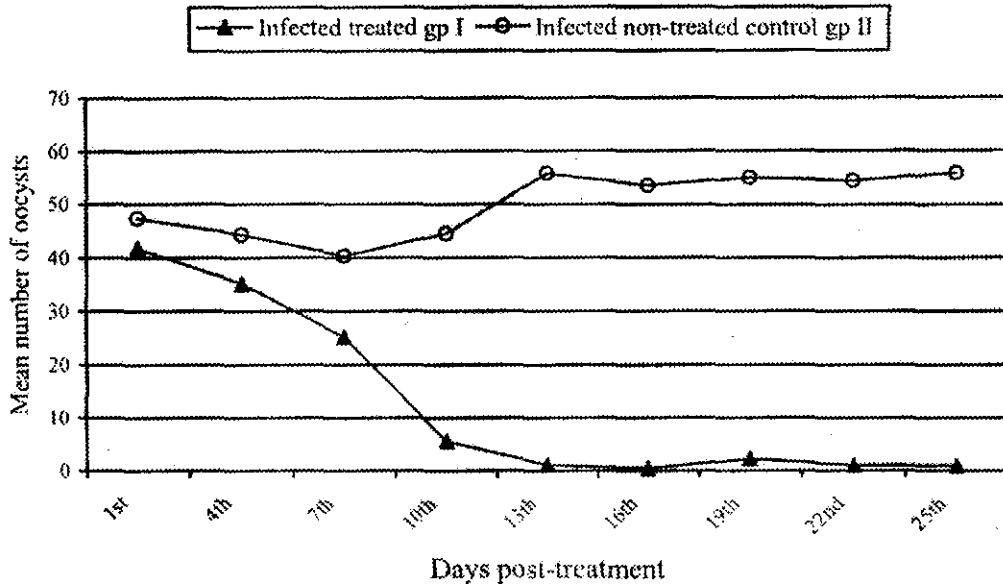


Fig. 1. The difference in the mean values of cryptosporidial oocysts shedding between the infected treated group I and the infected non-treated control group II of mice.

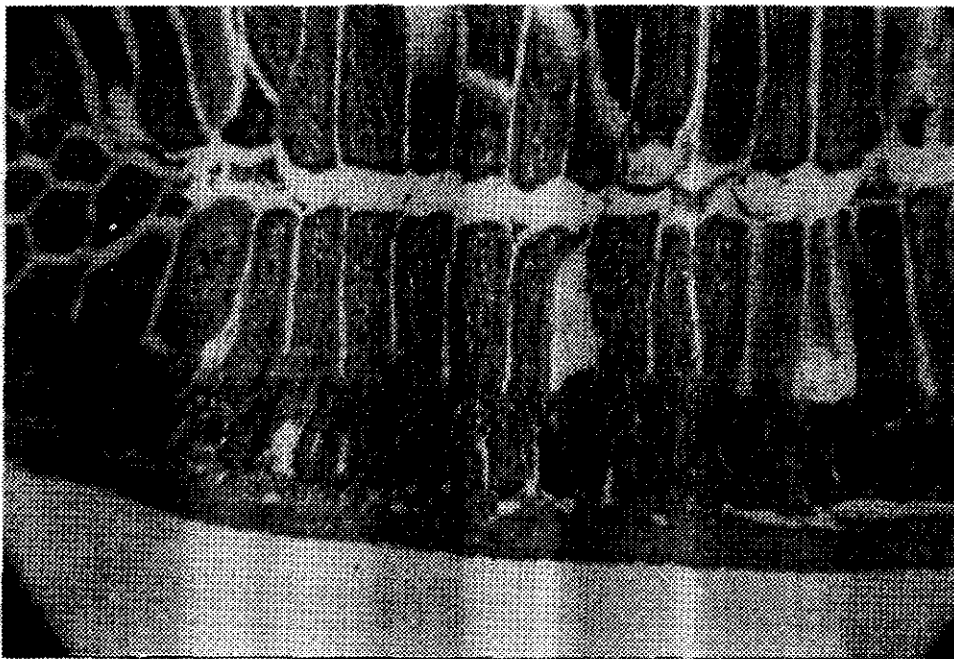


Fig. 2. Cross section of ileum of treated mouse with garlic extract on the 25th d.p.t. showing villi regaining their normal appearance. (H & E, X 125)

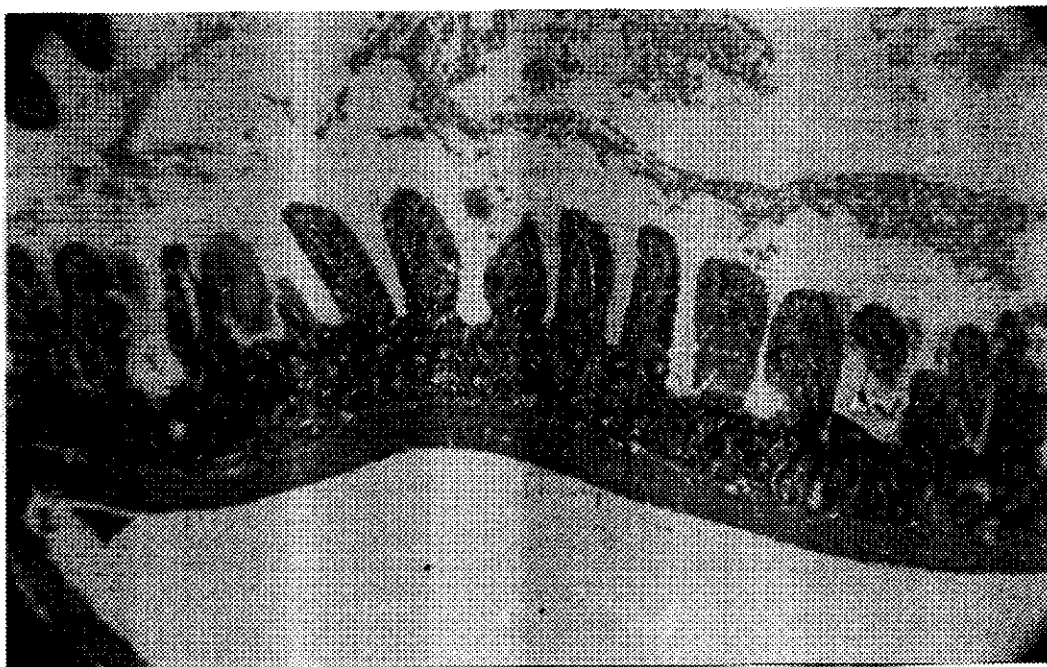


Fig. 3. Cross section of ileum from mouse of non-infected non-treated control group III showing normal appearance of villi. (H & E, X 125)

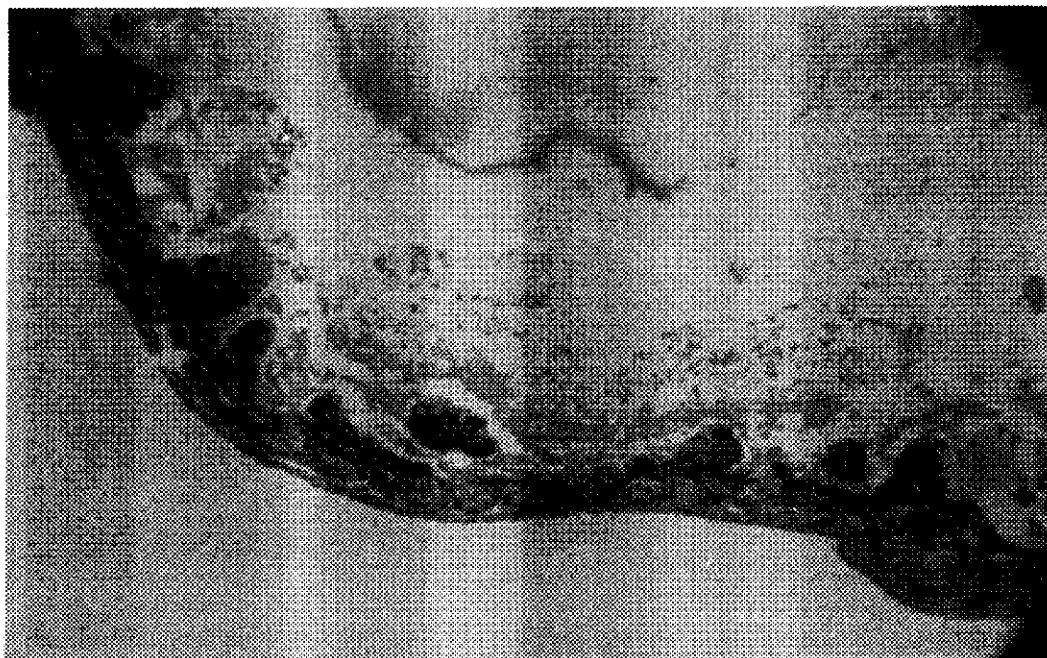


Fig. 4. Cross section of ileum from mouse of infected non-treated control group II, showing atrophy and desquamation of villi. H & E. X 125

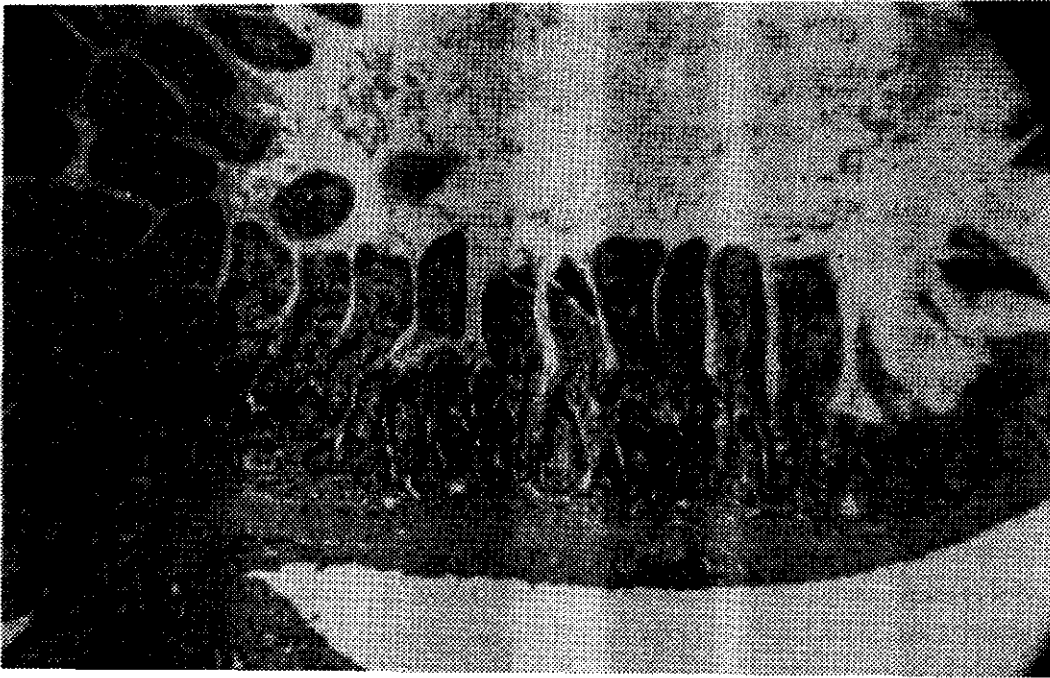


Fig. 5. Cross section of ileum of infected treated mouse, with little excretion of cryptosporidial oocysts, showing villi in normal appearance. (H & E, X 125)

DISCUSSION

In the present study, it was evident that, there was a significant difference in the mean values of *Cryptosporidium parvum* oocysts shedding, between the infected treated group I and the infected non-treated control group II from 7th d.p.t. until the termination of the experiment on 25th d.p.t. This proved that garlic extract had an appreciable effect on cryptosporidiosis in experimentally infected mice. Garlic extract may directly affect the cryptosporidial oocysts as Lazarides (1996) stated that allicin, the active principle of garlic, enters the blood stream when ingested, and soon reaching all parts of the body. She also found that after treatment of patients suffering from cryptosporidial diarrhoea with garlic extract, there was an evident improvement of diseased cases. This was referred to the regaining of normal immune status as garlic extract enhanced the natural killer cells to restore its activity. In this connection, Soulsby (1982) stated that, *Cryptosporidia* was one of the zoonotic protozoon that was affected by the immune status of the host. Furthermore, Harris *et al.* (2001), found that garlic which contained allicin, had a beneficial effect on the immune system.

Thus, the obtained result in the present study (58.3%) could be explained by improvement of the immune status of the mice. In a comparative study, Sréter *et al.* (1999), found that efficacy of garlic extract was 24.4% on cryptosporidiosis in chickens. The difference in the percentage may be due to the different hosts.

From the pathological point of view, garlic extract was effective to a great extent on ilea of infected-treated mice as these ilea regained their natural appearance and showed neither atrophy nor desquamation of villi when compared to ilea of infected-non treated control mice in which atrophy and desquamation of villi was very evident.

In this study, some infected-treated mice (5/12) belonging to group I showed some degrees of oocysts count in faeces (mean \pm SD, 0.94 ± 1.43), but didn't show neither atrophy nor desquamation of villi in histopathological sections. This is explained by the fact that allicin can protect the villi by being intact inspite of the presence of the parasite by improving the immune status of the host, which can tolerate *Cryptosporidium* infection without showing any clinical signs. Olson *et al.* (1998), stated that intensive administration of allicin, found in garlic extract, delayed the onset of diarrhoea in neonatal calves exposed to infection with *C. parvum* oocysts.

From the foregoing results, it is concluded that garlic extract had proved its efficacy against cryptosporidial infection in experimentally infected mice; being a zoonotic disease, thence, such results could be adopted in human beings having similar infection.

REFERENCES

1. Abu El-Magd M.M. and A.A. El-Badri. 1991. Pigeon trichomoniasis at Qena Governorate, Egypt. Beni-Suef Vet. Med. Res., 1 (2): 116-120.
2. Harris, H.E. 1898. Cited by Carleton, M.A., R.A. Drury, E.A. Wallington and H. Cameron. 1907. Carleton's histological technique, 4th ed., Oxford Univ. Press.
3. Soulsby, E.J.L. 1982. Helminths, Arthropods and Protozoa of domesticated animals. 7th ed. The English Language Book Society and Baillière Tindall. London.
4. Koudela B. and V. Jiri. 1997. Experimental cryptosporidiosis in kids. Vet. Parasitol., 71: 273-281.
5. Zu, S.X., G.D. Fang, R. Fayer and R.L. Guerrant. 1992. Cryptosporidiosis. Pathogenesis and immunology. Parasitol. Today, 8: 24-27.
6. Fayer R. 1993. Current strategies to meet a widespread problem. In Proceedings of 6th International coccidiosis Conference. June 21-25, Guelph, Ontario, Canada. p. 95-101.
7. Tzipori S. 1998. Cryptosporidiosis: Laboratory investigations and chemotherapy. Advances in Parasitology, 40: 187-221.
8. Harris J.C., S.L. Cottrell, S. Plummer and D. Lloyd. 2001. Antimicrobial properties of *Allium sativum* (garlic). Appl. Microbiol. Biotechnol., 57: 282-286.
9. Lang, Y.J. and K.Y. Zhang. 1981. Studies on the effective components of garlic (*Allium sativum* L.). Chin. Herb. Med., 4: 4-6.
10. Lun, Z.R., C. Burri, M. Menzinger and R. Kaminsky. 1994. Antiparasitic activity of diallyl trisulfide (Dasuansu) on human and animal pathogenic protozoa (*Trypanosoma sp.*, *Entamoeba histolytica* and *Giardia lamblia*) in vitro. Ann. Soc. Belg. Med. Trop., 74: 51-59.
11. Perez, H.A., M. De-La-Rosa and R. Apitz. 1994. In vivo activity of ajoene against rodent malaria. Antimicrobial Agents and Chemotherapy, 38: 337-339.
12. McClure, C.D., L.L. Nolan, S.A. Zatyryka, L.A. Craker and L. Nolan. 1996. Antileishmanial properties of *Allium sativum* extracts and its derivatives. Acta Horticulturae, 426: 1983-191.

13. Rasmussen, K.R., M.C. Healey, L. Cheng and S. Yang. 1995. Effects of dehydroepiandrosterone in immunosuppressed adult mice infected with *Cryptosporidium parvum*. J. Parasitol. 81 (3): 429-433.
14. Henriksen S.A. and J.F.L. Pohlenz. 1981. Staining of Cryptosporidia by a modified Zeihl-Neelsen technique. Acta Vet. Scand., 22: 594-596.
15. Lazarides, L. 1996. The Nutritional Health Bible. 1st ed. Published by Thorsons, Hazel Courteney, UK.
16. Sréter, T., Z. Széll and I. Varga. 1999. Attempted chemoprophylaxis of cryptosporidiosis in chickens, using diclazuril, toltrazuril or garlic extract. J. Parasitol., 85 (5): 989-991.
17. Olson, E.J., W.B. Epperson, D.H. Zeman, R. Fayer and M.B. Hildreth. 1998. Effects of an allicin-based product on cryptosporidiosis in neonatal calves. J. Am. Vet. Med. Assoc. 212 (7): 987-990.

دراسات على تأثير مستخلص الثوم على مرض الكريبتوسبورديا فى الجرذان المعدية تجريبياً

أحمد أنور وهبة

معهد بحوث صحة الحيوان ، مركز البحوث الزراعية ، وزارة الزراعة ، الجيزة ، مصر

أجريت هذه الدراسة لمعرفة تأثير مستخلص الثوم على طفيل الكريبتوسبورديا فى الفئران المعدية تجريبياً . تم تقسيم الفئران الخاضعة لهذه الدراسة الى ٢ مجموعات كل منها ١٢ جرذ تتراوح أعمارها بين ٢ : ٣ أسابيع . تمت العدوى بطفيل الكريبتوسبورديا فى المجموعة الأولى والثانية (٦١٠ حويصلة لكل جرذ) ثم أعطى العلاج بمستخلص الثوم للمجموعة الأولى فقط بجرعة قدرها ١ مللى / ١٠٠ جرام من وزن الجرذ . أما المجموعة الثالثة فقد ظلت بدون عدوى أو علاج كمجموعة ضابطة ، أخذت مسحات براز من الجرذان كل يومين من كل مجموعة ثم صبغت بصيغة الزيل نيلسون المعدلة وتم عد حويصلات الكريبتوسبورديا فى كل ١٠٠ حقل ميكروسكوبى بقوة تكبير ١٠٠٠ .

أظهرت النتائج وجود فرق معنوى فى متوسط أعداد حويصلات طفيل الكريبتوسبورديا وذلك بين المجموعة الأولى (المعدية والمعالجة) والمجموعة الثانية (المعدية فقط) وذلك ابتداء من اليوم السابع للعدوى حتى نهاية التجربة فى اليوم الخامس والعشرين للعدوى . وقد تبين من التجربة أن قوة التأثير العلاجية لمستخلص الثوم على طفيل الكريبتوسبورديا فى الجرذان هى ٥٨.٣ ٪ فى نهاية التجربة عند اليوم الخامس والعشرين تم ذبح الجرذان فى المجموعات الثلاث وأخذت الأجزاء الأخيرة من الأمعاء الدقيقة للفحص الهستوباثولوجى ، تبين من الفحص أن خملات الأمعاء الدقيقة فى المجموعة الأولى (المعدية والمعالجة) استعادت شكلها الطبيعى ولم يظهر بها أى تغيرات باثولوجية . أما فى المجموعة الثانية المعدية ولم تأخذ العلاج فقد ظهر ضمور ، وتقرش فى خملات الأمعاء الدقيقة ، فى نهاية التجربة وفى المجموعة الأولى (المعدية والمعالجة) أظهرت بعض الجرذان (عدد ٥ جرذان من ١٢) وجود بعض حويصلات الكريبتوسبورديا فى البراز ولكن لم يتبين وجود ضمور أو تقرش فى خملات الأمعاء الدقيقة .