

EXPERIMENTAL DIAGNOSTIC USES OF LAPAROSCOPE IN DOGS

G. A. El-Sayad; M. A. Seleim and A. S. Atiba

Department of Surgery, Fac. Vet. Med.; Kafr El-Sheikh

Tanta University, Egypt

ABSTRACT

The present study was carried out on 65 dogs in surgery dept. Fac. Vet. Med., Kafr El-Sheikh, Tanta University. The results of laparoscopic examination of the abdominal cavity provide accurate inspection of the anatomical relations between the abdominal organs and differentiate between the normal and abnormal appearance of these organs.

Laparoscopic biopsy of the liver was done under direct inspection of the selected lobe and provides enough tissue size for histopathological examination.

From the proceeding results, it can be concluded that the laparoscopy is an accurate non-invasive technique for examination and biopsy of the abdominal organs. The changes of the site of the primary port are indicated according to the organ of interest. The changes of the animal posture are indicated to enhance inspection of the abdominal organs. The complications of diagnostic laparoscopy and biopsy were minimal.

INTRODUCTION

Laparoscopy is a surgical procedure performed through a very small incision in the abdomen, using specialized instruments. A pencil-thin instrument called a laparoscope is used and it gives the surgeon an exceptionally clear view on a T.V. monitor, in the interior of the abdominal cavity.

The first diagnostic dog laparoscopic procedures were performed by **Kelling (1901)**, using essentially the same technique employed today. Further development of laparoscopic procedures and equipments till it's called now "minimal invasive procedures."

Diagnostic laparoscopy is a technique which, allows visualization of the interior of the abdominal cavity and differentiate between the normal and pathological conditions of the visceral organs, with minimal complications and avoidance of unnecessary laparotomy.

Laparoscopic guide biopsy is one of the definitive diagnostic methods of the internal organ. It was done under direct observation of the organ of interest and provides opportunity to detect a

very small lesion.

The aim of this work is to study the application of laparoscope and its benefit in exploration of the abdominal cavity, selection of the more suitable accesses to variant visceral organs and select the animal position that enhance visualization of these organs, as well as safe liver laparoscopic guide biopsy, all with minimal complications.

MATERIALS AND METHODS

The present study was carried out on (65) apparently healthy adult dogs from both sexes weighting from 15 to 25 kilograms, at Surgery Dept. Faculty of Veterinary Medicine Kafr El-Sheikh, Tanta University.

The dogs were housed in separate kennels. One day prior to surgery, the dogs received no food. The hair at the abdominal area from 10th intercostal space caudally to the flank and from dorsal to ventral midline was clipped and shaved.

Instrumentation :

1. The laparoscope connected to the light source (Fig. 1).
2. Co₂ Insufflator (Fig. 2).
3. CO₂ tank.
4. Camera unit (Fig. 3)
5. Video endoscopic computerized system.
6. Insufflation needle (Veress needle) (Fig. 4).
7. Trocar and cannulas (Fig. 5).




Fig. 1: Showing 10 mm 0° angle laparoscope (A), the light source (B) and the light cable (C)




Fig. 2: Showing the insufflator unit (A), connected with the gas filter (B) and the gas tube (C).




Fig. 3: Showing the camera unit (C.U.), connected with the camera cable (C.C.) and the camera head (C.H).



Fig. 4: Showing the Veress Needle (V.N).




Fig. 5: showing the 5 mm trocar-cannula "a" and 10 mm trocar-cannula "b"




Fig. 6: showing the blunt probe (B.P)

Fig. 7: Showing scissors (A), biopsy forceps (B), grasping forceps (C) and trocar_cannula (D).

8. Accessory laparoscopic instruments: Blunt probe (Fig. 6), Graspers, for holding of the abdominal organs, Scissors and Biopsy forceps (Fig. 7).

9. Other instruments required for laparoscopic procedures as: Scalpel No. 3 or 4, Scissors, Towel clips, Needle holder, needles and Suture materials.

Anaesthesia and laparoscopic procedures:

A venous cannula was inserted and fixed in the recurrent tarsal vein for injection of pre-anaesthetic medications as well as anaesthetic solution then for injection of fluid therapy in some cases if needed.

The dogs were pre-medicated with 0.02 mg/kg b.wt of atropine sulphate⁽¹⁾ injected subcutaneously to prevent vasovagal reflex from visceral manipulation. Xylazin HCl⁽²⁾ was given in a dose of 2.2mg/kg b.w. injected intravenously just before the induction of general anaesthesia using pentothal sodium⁽³⁾ in a dose rate of 10-15 mg/kg b.w 5% sol. injected intravenously until the main reflexes disappeared. The dog was placed on dorsal recumbent position and traditional measures for aseptic surgery (de-fattening, disinfections with betadine⁽⁴⁾ and surgical draping) were adopted in each animal.

Establishment of pneumoperitoneum:

The Veress needle was used to penetrate the abdominal wall and it was connected with insufflator by insufflating tube to deliver CO_2 gas into the abdomen. Insufflation produces a gas layer that separates the abdominal wall from the underlying viscera (Fig. 8).

Primary port placement:

The closed technique of primary port placement of 10 mm trocar-cannula was used to penetrate the abdominal wall, and through it, the laparoscope could be passed (Fig. 9).

Secondary port placement:

The secondary port (Trocar-cannula 5 mm) was inserted (Fig. 10) to allow passage of accessory instruments that used for either manipulation of the viscera or to perform some procedures as laparoscopic biopsy (Fig. 11).

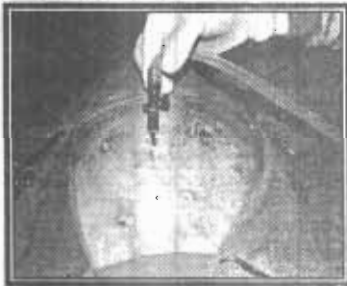


Fig. 8: Showing the uniform distention of the abdominal cavity.

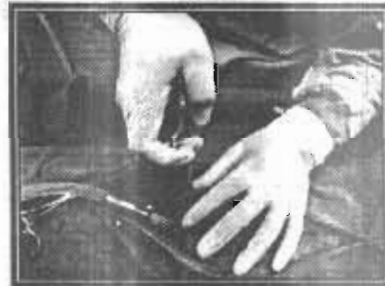

Fig. 9: Showing the method of insertion of the primary port.

- ¹ Atropine sulphate : Misr Co
- ² Xylazin Hcl :Adwia
- ³ Pentothal sodium : Biochemic GmbH
- ⁴ Betadine (Bovidine iodine, Nile Co., A.R.E)

Laparoscopic guide liver biopsy:

Liver biopsy is one of the definitive diagnosis of the liver diseases; it was done under the guide of laparoscope after complete examination of the liver surfaces, and the selection of the area to be biopsied according to the nature of the liver disease (focal or diffuse).

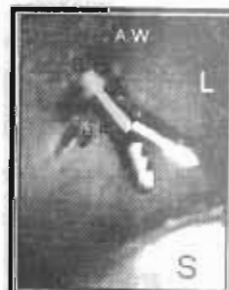

Fig. 10: Showing the site of placement of the secondary trocar-cannula (a) insertion of the secondary port under direct observation of the laparoscope and appearance of trocar tip (T.T) pass through the abdominal wall (A.W) and the stomach (S) (b)

Fig. 11: Showing the secondary trocar cannula (S.T) justed through the abdominal wall (A.W) (a) The biopsy forceps (B.F) passed through the secondary trocar cannula (S.T) and appearance of part of the liver (L) and the stomach (S) (b)

- * Atropine sulphate : Misr Co
- * Pentothal sodium : Biochemic GmbH

- * Xylazin Hcl :Adwia
- * Betadine (Bovidine iodine, Nile Co., A.R.E)

RESULTS

The results of the present study revealed that, there are different sites of entry of the primary port. Each site was indicated for one or more organs to provide maximal visualization and minimal complications.

The changes in animal posture during laparoscopic procedures were indicated for better exposure of abdominal organs, which in dorsal recumbent animal and the head in a down position for exposure of the caudal half of the abdominal cavity While in dorsal recumbent and head up position for exposure the cranial half of the abdominal cavity. The animal was shifted to the right or left side for exposure of the opposite side.

Laparoscopic exploration of abdominal organs :

Liver :

Regarding to exploration and examination of the liver, there were three accesses :

1. The Umbilical access or midline 1-2cm caudal to the umbilicus access :

The animal was placed in a dorsal recumbency and his head in upward position. The secondary port was placed about 5cm right to the primary one to help in retraction of the liver lobes. The falciform ligament fat restricts the free movement of the laparoscope and its cannula.

2. Right lateral mid abdominal access:

The primary port was placed at 3 to 5cm caudal to the last rib or between the right costal arch and the proximal aspect of the iliac crest and midway between ventral midline and the lumbar vertebrae with the animal head in upward position and 30° left lateral recumbency. This access was selected for right side lobes of the liver (right medial, right lateral, caudate and part of quadrate lobe).

3. Left lateral mid abdominal access:

The primary port was placed at 3 to 5 cm caudal to the last rib or between the left costal arch and the proximal aspect of the iliac crest and midway between the ventral midline and the lumbar vertebrae with the animal head in upward position and 30° right lateral recumbency. This access was selected for left side lobes of the liver (left medial, left lateral and part of quadrate lobe).

Normal liver has a smooth surface with sharp borders and uniform deep red colour (Fig. 12). The portal areas and uniform sinusoidal configuration could be detected with close up examination to the liver surfaces. Gentle palpation of the liver with either the laparoscope or the palpation probe causes temporary blanching and depression of the organ's surface and not tear or bleed.

Most of the liver surfaces could be examined by the laparoscope. The convex surface of the liver was easily viewed as it drapes over the stomach and intestine. The concave surface and the helix of the liver appeared when the animal was tilted with its head down and the blunt probe used for elevation of the lobes up (Fig. 13). The caudal portion of the caudate lobe caps the cranial pole of the right kidney.

Gall Bladder :

The most suitable site of the primary port used for evaluation of the gall bladder was at the umbilicus or at the right lateral mid abdominal access. The animal was placed in dorsal recumbency with its head up and slightly shifted to the left lateral side. The second port trocar-cannula was placed at 5 cm right to the primary one.

Normal gall bladder was not appeared from the convex surface of the liver. Exposure of the gall bladder was done, using the blunt probe to separate between the right medial and the quadrate lobes or elevation of the right lateral or medial lobes up (Fig. 14). Normal gall bladder appears dark green blackish in color, soft and fluctuant on manipulation with the probe.

Liver biopsy:

The same three accesses for laparoscopic examination of the liver could be adapted for liver biopsy. The biopsy samples could be taken from all the liver lobes (Fig. 15, 16 & 17). The Biopsy sample taken from the liver by this technique was of less tissue damage to the liver and the sample, (Fig. 16).

The amount of bleeding from the biopsy site was minimal and the clotting was occurred within few minutes (2-4). In some cases with increased amount of bleeding the biopsy site was occluded by the blunt probe, the biopsy forceps or the laparoscope for one minute till clotting occurred (Fig. 18 & 19).

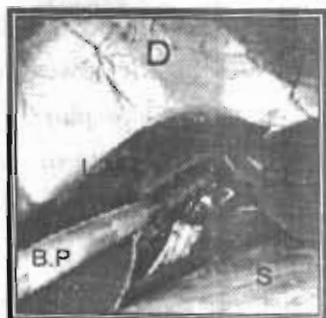


Fig. 12: Showing separation between the left medial lobe (L.M.L.) and the left lateral lobe (L.L.L.) of the liver using the blunt probe (B.P) And the diaphragm (D) and the stomach (S).

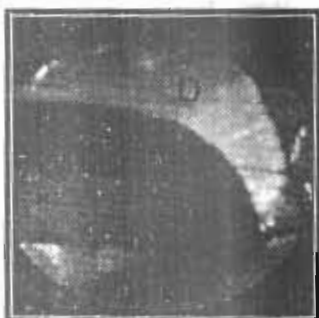

Fig. 13: Showing elevated left medial lobe (L.M.L.) and appearance of the concave surface. Part of the left lateral lobe (L.L.L.) and the diaphragm (D).

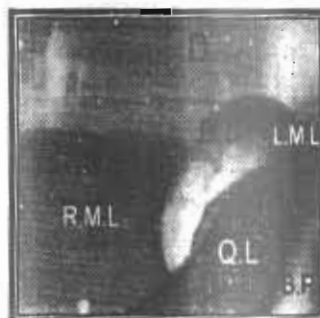

Fig. 14: Showing the gall bladder (G.B) after separation between the right medial lobe (R.M.L.) and the quadrate lobe (Q.L) using the blunt probe (B.P). Also appearance of the left medial lobe (L.M.L.) and the diaphragm (D).



Fig. 15: Showing the biopsy forceps (B.F) grasping the left lateral lobe of the liver (L.L.L.) and pulled it up. Part of the stomach (S) and the diaphragm (D).




Fig. 16: Showing the biopsy forceps (B.F) grasping the left lateral lobe of the liver (L.L.L.) and pulled it up. Part of the stomach (S), left medial lobe (L.M.L.), and the diaphragm (D).



Fig. 17: Showing the biopsy forceps (B.F.) after cutting the biopsy sample (B.S.), the diaphragm (D) and the convex liver surface (L).

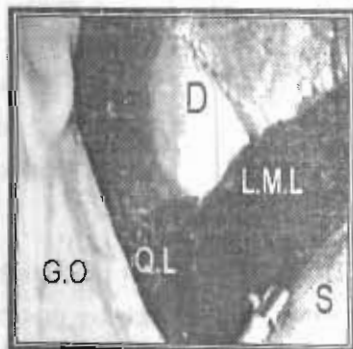


Fig. 18: Showing the biopsy forceps (B.F) after cutting the biopsy sample from the left medial lobe (L.M.L.), the diaphragm (D). Part of the stomach (S) and the greater omentum (G.O.)



Fig. 19: Showing the biopsy site at the left medial lobe and part of the stomach.

Stomach:

The most suitable site for the primary port insertion was at the umbilicus or ventral midline 1cm caudal to it. The animal was placed in dorsal recumbency with its head in upward position. The stomach lies largely in a transverse position more to the left of the median plane. It lies in contact with the liver lobes to produce an extensive gastric impression or concavity in the caudal surface of the liver (Fig. 12 & 16), and its greater curvature attached to the spleen (Fig. 20). It is separated from small intestine and left kidney by greater omentum.

Intestine:

The most suitable site of the primary port insertion was at the umbilicus or at the ventral midline 1-2 cm caudal to the umbilicus and the secondary port placed at 5 cm right to the primary one. The animal position was in dorsal recumbency with the head in downward position.

The intestines occupy most of the abdominal cavity and extend caudal to the liver and the stomach till the pelvic inlet (Fig. 22). It was found that, the intestines are covered by the omentum which, was reflected using the blunt probe or grasping it using the grasping forceps and moved cranially to be rested on the ventral surface of the stomach (Fig. 22).

The duodenum appeared at the right side of the abdomen as it runs caudally from the pylorus (Fig. 21). Multiple jejunal loops with its attached mesentery were located beneath the umbilicus (Fig. 22 & 23). The most accessible portion of the colon was the descending colon, which is long and usually quite straight (Fig.23). It lies dorsally close to the ilio-positoas muscle and at its beginning it lies in contact with ventral surface of the left kidney (Fig. 25, 30 & 31).

Spleen:

There were different accesses for exploration of the spleen:

The umbilicus access was suitable for exploration of most of the spleen surface. To gain better access to the splenic hilus, the animal should be rotated 45° to the right. The left lateral mid abdominal approach may be associated with many complications as the spleen located close to the entry site.

The spleen with its normal appearance and relation to other organs is demonstrated in (Fig. 24, 26 & 27). Spleen was attached to the greater curvature of the stomach by gastrosplenic ligament, through it, the left gastro-epiploic vessels cross from the stomach to the spleen (Fig. 20). Spleen was contacted with the cranio-lateral surface of the left kidney (Fig. 25, 29 & 30).

Pancreas:

The most suitable site of the primary port used for evaluation of the pancreas was placed at

the umbilicus or at the right lateral access, with the animal placed in dorsal recumbency and slightly shifted to the left side.

The pancreas was found adjacent to the duodenum and to enhance its visualization, the omentum was reflected away with the blunt probe or biopsy forceps (Fig. 28). Normal pancreas appears pale cream colour and coarsely lobulated (Fig. 28).

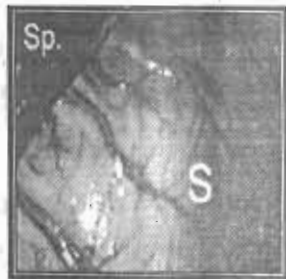

Fig. 20: Showing the greater curvature of the stomach (S) attached to the spleen (Sp).

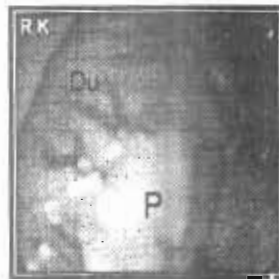

Fig. 21: Showing the duodenum (Du) attached to the pancreas (P) medially and contact to the right kidney (R.K.) laterally.

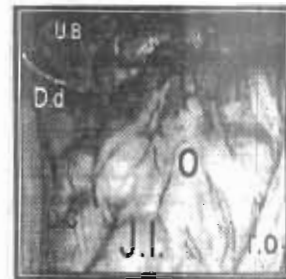

Fig. 22: Showing the multiple jejunal loops (J.I.) with retraction of the omentum (O) also appearance of part of the descending colon (D.C), the urinary bladder (U.B) and the ductus deferens (D.d)

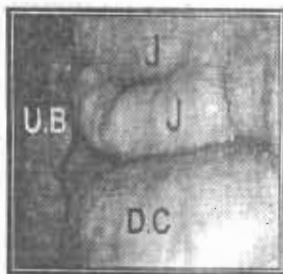


Fig. 23: Showing the anti-mesenteric side of the jejunum (J), the descending colon (D.C) and the urinary bladder (U.B)

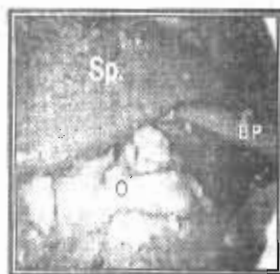

Fig. 24: Showing the spleen (Sp) which elevated up using the blunt probe (B.P). The omentum (O)

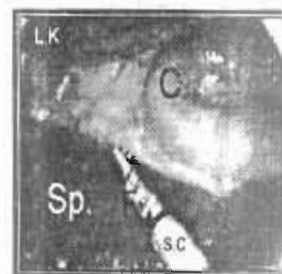


Fig. 25: Showing the spleen (Sp) which adjacent to the left kidney (L.K) and the colon (C) but separation between them by grasping forceps (F) introduced through the secondary cannula (S.C)

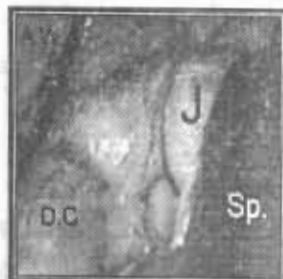

Fig. 26: Showing the enlarged spleen (Sp.) which extended caudally and its relation to the descending colon (D.C) and the jejunum (J).



Fig. 27: Showing the close up to the spleen surface (Sp.)

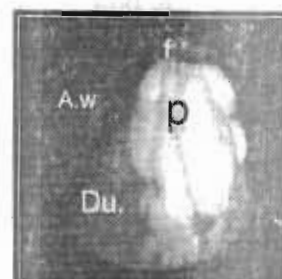


Fig. 28: Showing the pancreas (P) which grasped and elevated up using grasping forceps (F) and appearance of the duodenum (Du.) and the abdominal wall (A.W)

Kidneys:

There were different accesses for exploration of the kidneys

a. The umbilical access for the primary port placement.

The two kidneys could be inspected through this access. For inspection of the right kidney, the animal head was in upward position and rotated 30-60° to the left and the laparoscope directed cranially and to the right side of the animal.

For inspection of the left kidney the animal head was in upward position and rotated 30-60... to the right and the laparoscope was directed cranially and to the left side of the animal.

b. Right lateral access for inspection of the right kidney.

The Animal was placed with the head in upward position and at 30-60° left lateral recumbency. The primary port placed at 5 cm caudal to the last rib and 3 to 5 cm ventral to the border of the lumbar muscles and the trocar-cannula pointed in craniodorsal direction and enter the abdomen in shallow angle.

c. Left lateral access for inspection of the left kidney.

The Animal was placed in head up position and at 30-60° right lateral recumbency. The primary port placed at 5 cm caudal to the last rib and 3 to 5 cm ventral to the border of the lumbar muscles and the trocar-cannula pointed in cranial dorsal direction.

Kidney appeared bean in shape, pale gray colour and has readily apparent capsular vasculature (Fig. 29 & 32).

The right kidney was bounded cranially by caudate lobe of the liver and fixed to it by the hepato-renal ligament. The caudal pole was contacted with the pancreas and ascending colon.

The left kidney was appeared without attachment to other organs. It was in contacted with the spleen and stomach cranially, descending colon caudally and abdominal wall laterally and lumbar muscles dorsally (Fig. 29 & 30).

The renal hilus contains a variable amount of adipose tissue, renal pelvis and branches of renal artery and vein (Fig. 31).

Urinary bladder :

The most suitable site of the primary port used for evaluation of the urinary bladder was at the ventral midline midway between the umbilicus and xiphoid with the animal in dorsal recumbency and its head in downward position. The laparoscope directed caudally. Urinary bladder appears with close inspection gray with tortuous serosal vessels (Fig. 33 & 34).

Deep inguinal ring :

The most suitable site of the primary port used for evaluation of the deep inguinal ring was placed at the ventral midline 1-2cm caudal to the umbilicus.

The animal was placed in a dorsal recumbent position and slightly shifted to the right side for better visualization of the left deep inguinal ring and the laparoscope directed to the left side. The animal was slightly shifted to the left side for better visualization of the right deep inguinal ring and the laparoscope directed to the right. Deep inguinal ring consisted of vaginal tunic and spermatic cord (ductus deferens and testicular artery and vein) (Fig. 35 & 36).

Ovaries :

The most suitable site of the primary port used for evaluation of the right and left ovaries was placed at the umbilicus. The animal was placed in dorsal recumbent position with head down (Trendelenburg position) and tilted 45° to the left to expose the right ovary and 45° to the right to expose the left ovary. Left ovary located caudal to the caudal pole of the left kidney (Fig. 37) and the right ovary located caudal to the caudal pole of the right ovary. The right ovary was found more cranial than the left one.

Laparoscopic complications:

In the present study most of complications was related to the blind insertion of the Veress needle and the primary port. Three cases were recorded with the veress needle insertion, two of them caused injury to the spleen surface (Fig. 38) and one cause complete penetration to the spleen (Fig. 39, 40 & 41).

Also, the primary trocar caused injury to small abdominal blood vessels in two cases and caused injury to the spleen surface at the left lateral mid-abdominal access (Fig. 42). The secondary trocar-cannula caused no complications neither to the abdominal wall blood vessels nor to the abdominal viscera because it was done under visualization of the laparoscope.

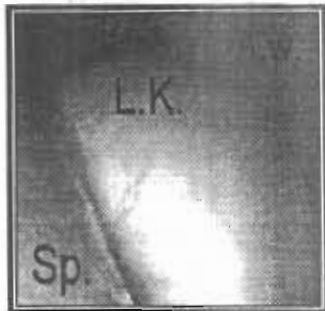


Fig. 29: Showing the left kidney (L.K.) and the abdominal wall (A.W.) and part of the spleen (Sp.)

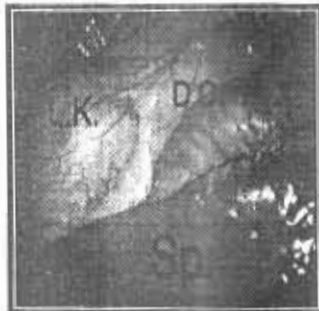

Fig. 30: Showing the left kidney (L.K.) with its caudal pole, the descending colon (D.C.) and the spleen (Sp.)

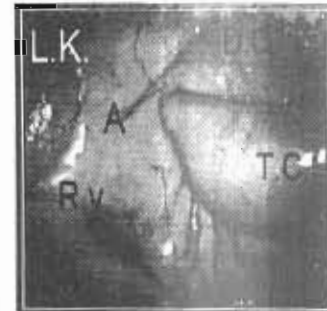

Fig. 31: Showing the left kidney (L.K.) with its relation to the colon (descending colon (D.C.) and transverse colon (T.C.)) and appearance of the renal vein (R.v.) and the adipose tissue (A)

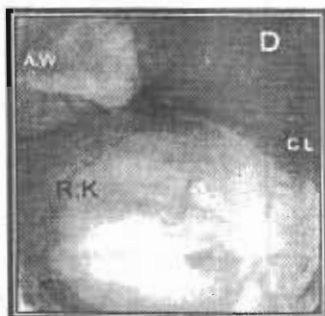


Fig. 32: Showing the right kidney (R.K.) and part of the caudate lobe of the liver (C.L) and the diaphragm (D)

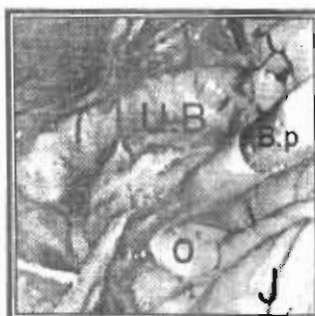


Fig. 33: Showing the urinary bladder (U.B.) and the jejunum (J), the omentum (O) reflected by the blunt probe (B.p.)

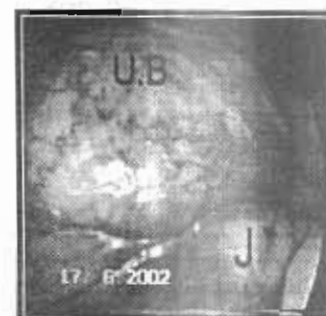

Fig. 34: Showing the close up of the urinary bladder (U.B.) with tortuous serosal vessels and part of the jejunum (J)

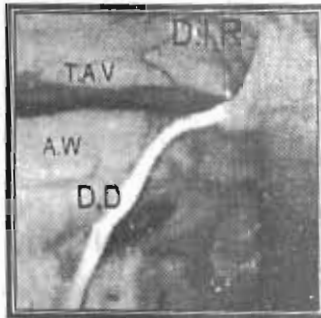


Fig. 35: Showing the deep inguinal ring (D.I.R) and testicular artery and vein (T.A.V) and the ductus deferens (D.D) and the abdominal wall (A.W).

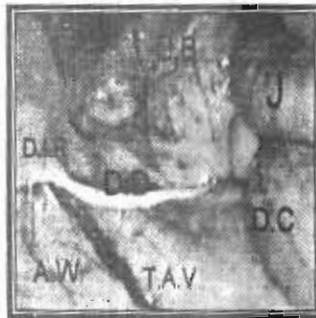

Fig. 36: Showing the deep inguinal ring (D.I.R), testicular artery and vein (T.A.V), the ductus deferens (D.D), the urinary bladder (U.B.), the descending colon (D.C) and the jejunum (J).




Fig. 37: Showing the left ovary (L.O), the caudal pole of the left kidney (L.K.), dorsal muscles (D.M) and the abdominal wall (A.W).

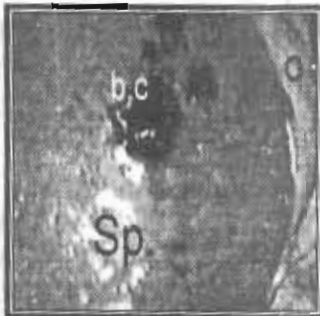

Fig. 38: Showing injury of the spleen surface (Sp.) during insertion of the Verres needle and formation of blood clot (b.c) at the site of injury.



Fig. 39: Showing the complete penetration of the spleen (Sp.) by the Verres needle (V.N) during its insertion. And appearance of the greater omentum (O) and the abdominal wall (A.W).

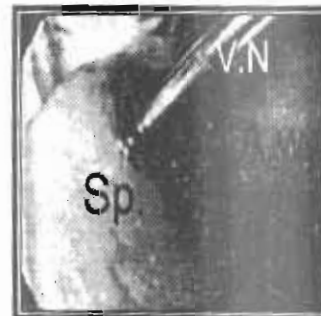

Fig. 40: Showing the complete penetration of the spleen (Sp.) by the Verres needle (V.N) during its insertion. And appearance of the abdominal wall (A.W).




Fig. 41: Showing the removal of the Verres needle (V.N) from the spleen (Sp.) And appearance of the blood clot (b.c) at the site of penetration and the abdominal wall (A.W) during its insertion. And appearance of the abdominal wall (A.W) the omentum (O).

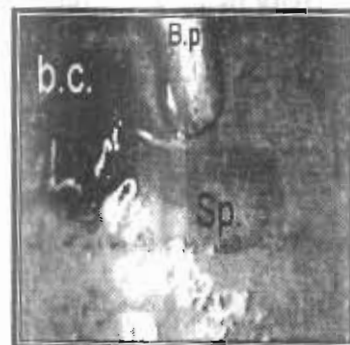


Fig. 42: Showing the injury of the spleen surface (Sp.) during insertion of the primary trocar and formation of blood clot (b.c) at site of injury. Appearance of the blunt probe (B.p).

DISCUSSION

Laparoscopy was considered as an accurate non-invasive technique to study the normal anatomical relations between the abdominal organs, evaluate the abdominal cavity and taken a biopsy from an abdominal organ. These results were in agreement with **Johson and Twedt (1977); Coupland, et. al. (1981); Boyce (1982) and Jones (1990)**.

The Veress needle was inserted after making a stab incision (3mm in length) of the skin. It was wide enough for easily insertion of the needle without resistance and to avoid leakage of pneumoperitoneum gas from around the needle. **Whereas Silva, et. al. (1995)** preferred introduction of the Veress needle to the abdominal cavity by direct puncture of the skin without incision. While the incision was smaller than that described by **Kenawy (1998) and Schossler (1998)** whose made 1 cm incision for insertion of the Veress needle.

In the present study, the Veress needle was introduced at caudolateral to the umbilicus and directed toward the pelvis with slight head down position of the animal. This technique has been proved to be safe procedure and decrease the chance of injury to the spleen. Similar results were recorded by **Brearley, et. al. (1991) and Freeman (1999)**.

To ensure that, the tip of the Veress needle was in the abdominal cavity, a 5ml saline was injected through a syringe attached to the hub of the Veress needle and injected without resistance. In the same time the abdominal wall must be symmetrically distended and produce tympanic sound on percussion. This was in the same line as that described by **Clayman and McDougall (1993)**.

The suitable intra abdominal pressure (14 mm Hg) has been reached with maximum distention of the abdominal cavity by insufflation of 1-2 litter of gas according to the size of the experimental dogs. This result was in agreement with **Wildt, et. al. (1977); Jones (1990) and Freeman (1999)**.

The safe insertion of the primary port was done by placement of the animal in dorsal recumbent position with slightly head down. Transient increasing of the intra abdominal pressure was done by more insufflation of gas between 20 and 30 mm Hg to avoid depression of body wall during trocar insertion and injury of the abdominal organs. This elevation of the intra-abdominal pressure had no serious effect on the physiological function of the animal because it was done in few minutes and then return to 14 mm Hg during the laparoscopic procedures. This technique was described by **McDougall, et.al. (1994)**. Similar results were obtained for the safe insertion of the primary port, but with the intra abdominal pressure increased transiently to 17-19 mmHg.

The secondary portal with minimal complications was done under direct guidance and transillumination of the laparoscope. It was performed to allow manipulation of viscera and other laparoscopic procedures as biopsy. This result was agreed with **Kavoussi and Clayman (1992) and Fischer (2002)**.

The distance between the primary cannula and the secondary cannula was at least 5cm to provide enough space for free movement and manipulation of the abdominal organs. This result was in agreement with **Jones, et. al. (1985)**.

The shop stick method was suitable for location of the accessory instruments within the abdominal cavity by crossing the laparoscope with the accessory instrument and sliding them against one another until the later appears in front of the laparoscope lens. This result coincided with **Rioux (1978)**.

There are different accesses had been described in literatures for evaluation and biopsy of the liver at right lateral and left lateral mid abdominal and umbilical sites. It has been found that, the right lateral mid abdominal access was suitable for inspection of most of the liver lobes and gall bladder. This result was agreed with **Jones, et. al. (1985) and Twedt (1999)**.

The laparoscope port at midline 1-2 cm caudal to the umbilicus was not suitable for the liver inspection and biopsy due to the presence of the falciform fat that interferes with the free movement of the laparoscope cranially. It is indicated mainly for diagnostic and operative procedures in the stomach and intestines (small and large). This result was coinciding with **Jones, et. al. (1985); Bohm and Milson (1994); Silva, et. al. (1995); Twedt (1999); Rawlings, et. al. (2001) and Rawlings, et al. (2002)**.

The injury of the spleen at the primary port occurred during the left lateral mid abdominal access due to the closely relation of the spleen to this site of entry. This result was in agreement with that reported by **Jones, et. al. (1985); Trias, et. al. (1996) and Twedt (1999)**.

A 10 mm rigid scope provided suitable light, largest field of view and the greatest clarity of vision in the present study, the same as founded by **Freeman (1999)**.

The changes of the animal posture during laparoscopic procedures were indicated to allow better exposure of the organ of interest by shifting the abdominal viscera away from this organ. The head down tilt, expose the caudal abdominal organs and the head up tilt, expose the cranial abdominal organs. These results were coincided with those mentioned by **Wildt (1980); Spaw, et. al. (1991); Bailey and Pablo (1999) and Peroni and Rondenay (2002)**.

The umbilical access of the primary port was suitable for examination of the spleen with the animal tilt 45° to the right. The same access was indicated for the diagnostic and operative sur-

gery of the organs in the caudal half of the abdomen, as intestines (most of the jejunum and the descending colon), urinary bladder and deep inguinal ring with its structure (ductus deferens and testicular artery and vein) with the animal in head down position. For the ovaries (right and left) the animal was placed in head down position and tilt 45° to the right to expose the left ovary and tilt 45° to the left to expose the right one. These results were in agreement with **Wildt, et. al. (1977); Wildt, et. al. (1981); Wildt and Lawler (1985); Thiele, et. al. (1993); Poppas, et. al. (1994); Britanisky, et. al. (1995); Trias, et. al. (1996); Minami, et. al. (1997) and Freeman and Hendrickson (1999)**.

The right and left kidneys could be examined by one access at the mid line, 2-4 cm caudal to the umbilicus. The animal was placed in reverse Trendelenburg position and turns 30° 60° to the right for access the left kidney and turn 30° 60° to the left for access the right kidney. The blunt probe was used to separate between the right kidney, duodenum, the left kidney, the spleen and the intestine. Laparoscopic close examination of intestines allowed the assessment of the intestinal viability as intestinal color, mesenteric arterial pulsation and peristalsis. This result was in agreement with **Rudd and Hendrickson (1999)**.

The most suitable site for the right kidney laparoscopic access was approximately 5 cm caudal to the last rib and 3 to 5 cm ventral to the border of the lumbar muscles. The right kidney is more stable due to its attachment to the caudate lobe of the liver. It is located between the right dorsal abdominal wall, the liver and the diaphragm. The kidneys appeared pale gray with readily apparent vasculature. This result coincided with **Grauer, et. al. (1983) and Grauer (1990)**.

Laparoscopic biopsy under guidance of laparoscope could be performed with minimal complications and good direct visualization of target organ with possible multiple biopsy of organs. This result was agreed with **Wildt, et al. (1977); Jones (1978); Nord (1982); Jones, et al. (1985); Kerwin (1995); Richer (2001) and Fischer (2002)**.

The cutting and crushing technique during liver biopsy were of less tissue damage to the liver and the biopsy sample. The bleeding from the biopsy site was minimal and the clotting action lasted usually in 1-3 minutes. When increased amount of bleeding at the biopsy site, it could be occluded by the blunt probe, the biopsy forceps or by the laparoscope tip till clotting occurred. These results were agreed with **Twedt (1999)**.

The rate of complications in diagnostic laparoscopy generally was low due to the decreased number of instruments and organs manipulation in compare with operative laparoscopy. This result coincided with **Wang, et. al. (2001)**. Most of complications were related to the Veress needle and the primary port trocar insertions, as these were done blindly. This result was agreed with **Crist and Gadacz (1993)**.

The veress needle insertion had higher complication rate than that done by the primary port trocar. This result was in agreement with that reported by **Lee, et. al. (1993)** and **Yerdel, et. al. (1999)**.

The complication rate for the secondary port was less than that of the primary port as it was done under direct visualization and illumination of the laparoscope. Similar results were also noted by **Davis, et. al. (2000)**.

REFERENCES

- Bailey, J. E. and Pablo, L. S. (1999)** : Anaesthetic and physiologic considerations for veterinary endosurgery in *Veterinary endosurgery* by Freeman, L. J. ed, chapter 2 Mosby. Inc.
- Bohm, B. and Milson, J. W. (1994)** : Animal models as educational tools in laparoscopic colorectal surg. *Surg. Endosc.* 8: 707-713.
- Boyce, H. W. (1982)** : Laparoscopy. In: Schiff, L. and Schiff, E. R. eds *Disease of liver*. Philadelphia: J.B. Lippincott 333-348.
- Brearley, M. J.; Cooper, J. E. and Sullivan, M. (1991)** : Color atlas of small animal endoscopy. Wolt publishing Ltd. pp 87-89.
- Britanisky, R. G.; Poppas, D. P.; Shichman, S. N.; Mininberg, D. T. and Sosa, R. E. (1995)** : Laparoscopic laser-assisted bladder autoaugmentation. *Urology* 46: 31-35.
- Clayman, R. V. and McDougall, E. M. (1993)** : pneumoperitoneum in: *Laparoscopic urology*. By Clayman, R. V. and McDougall, E. M. eds. St. Louis Quality medical publishing
- Coupland, G.; Townsend, D. and Martin, C. (1981)** : Peritoneoscopy use in assessment of intra-abdominal malignancy surgery. 89: 645-649.
- Crist, D. W. and Gadacz, T. R. (1993)** : Complications of laporoscopic surgery. *Surg. Clin. North. Am.* 73: 264-289.
- Davis, D. R.; Schilder, J. M. and Hurd, W. W. (2000)** : Laparoscopic secondary port conversion using a reusable blunt conical trocar. *Obstetrics & Gynecology* 96: 634-635.
- Fischer, A. T. (2002)** : *Equine diagnostic & surgical laparoscopy*. W.B. Saunders company. 9th Ed.
- Freeman, L. J. (1999)** : *Veterinary endosurgery*. chapters 1&4 Mosby Inc.
- Freeman, L. J. and Hendrickson, D. A. (1999)** : Minimal invasive surgery of reproductive system. In *veterinary endosurgery* by Freeman, L. J. chapter 11 Mosby, Inc.
- Grauer, G. F.; Twedt, D. C. and Mero, K. N. (1983)** : Evaluation of laparoscopy for obtaining renal biopsy specimens from dogs and cats. *J. Am. Vet. Med. Assoc.* 183: 677.
- Grauer, G. F. (1990)** : Laparoscopy of the urinary tract. In *small animal endoscopy* by Tams, T. R. editor (1990) St. Louis, Mosby
- Johnson, G. F. and Twedt, D. C. (1977)** : Endoscopy and laparoscopy in the diagnosis and management of neoplasia in small animals. *Vet. Clin. North. Am.* 7: 77-92.

- Jones, B. D. (1978)** : The use of laparoscopy to obtain liver biopsies. *Scien. Pres. 45th annual meeting Am. Anim. Hosp. assoc.* 245-246.
- Jones, B. D. (1990)** : Laparoscopy. *Vet. Clin. North. Am. small animal pract* 20: 1243-1263.
- Jones, B. D.; Hilt, M. and Hurst, T. (1985)** : Hepatic biopsy. *Vet. Clin. North. Am.* 15: 39.
- Kavoussi, L. R. and Clayman, R. V. (1992)** : Urologist at work trocar fixation during laparoscopy *J. Endourol* 6: 71-72.
- Kelling, G. (1901)** : The first experimental laparoscopy. Cited by: **Gunning, J. E. (1974)**: The history of laparoscopy. *J. Reprod. Med.* 12: 223-231.
- Kenawy, A. (1998)** : Experimental laparoscopy and instrumentation in dogs. *Assiut Vet. Med. J.* Vol. 39 No. 78
- Kerwin, S. C. (1995)** : Hepatic aspiration and biopsy techniques. *Vet. Clin. North. Am. (Small animal pract)* 25: 275.
- Lee, V. S.; Chan, R. S.; Cucchiaro, G. and Meyers, W. C. (1993)** : Complications of laparoscopic cholecystectomy. *Am. J. Surg.* 65: 527-532.
- McDougall, E. M.; Figenshau, R. S. and Clayman, R. V. (1994)** : Laparoscopic pneumoperitoneum: impact of body habitus. *J. Laparoendosc. Surg.* 4: 385.
- Minami, S.; Okamoto, Y.; Eguchi, H. and Kato, K. (1997)**: Successful laparoscopy assisted ovariohysterectomy in two dogs with pyometra. *J. Vet. Med. Sci.* 59:845-847.
- Nord, H. J. (1982)** : Biopsy diagnosis of cirrhosis: blind percutaneous versus guided direct vision techniques -a review. *Gastrointest. Endosc.* 28: 102-104.
- Peroni, J. F. and Rondenay, Y. (2002)** : Analgesia and anaesthesia for equine laparoscopy and thoracoscopy in equine diagnostic and surgical laparoscopy by Fischer, A.T. (2002). ed., chapter 11, W.B. Saunders Company.
- Poppas, D. P.; Gomella, L. G. and Sosa, R. E. (1994)** : Basic laparoscopy. Pneumoperitoneum and trocar placement in Gomella, L. G.; Kozminski, M. and Winfield, H. N. laparoscopic urologic surgery. New York Raven press pp. 75-84.
- Rawlings, C. A.; Foutz, T. L.; Mahaffey, M. B.; Howerth, E. W.; Bement, S. and Canalis, C. (2001)**: Rapid and strong laproscopic assisted gastropexy in dogs. *Am. J. Vet. Res.* 62: 871-875.
- Rawlings, C. A.; Howerth, E. W.; Bement, S. and Canalis, C. (2002)** : Laparoscopic-assisted enterostomy tube placement and full-thickness biopsy of the jejunum with serosal

patching in dogs. *Am. J. Vet. Res.* 63: 1313-1319.

Richter (2001) : Liver biopsy methods: laparoscopy us ultrasound us fine needle aspiration. Tufts Animal Expo. Conference Proceedings. Sept. 1.

Rioux, J. E. (1978) : An unusual complication of double puncture laporoscopy in Endoscopy in Gynecology Phillips, J.M. ed. American Association of Gynecologic laparoscopists Dept. of Publications. Downey calif 76-77.

Rudd, R. G. and Hendrickson, D. A. (1999) : Minimally invasive surgery of the urinary system. In veterinary endosurgery by Freeman, L. J. (1999) ed., chapter 12 Mosby Inc.

Schossler, J. E. (1998) : Diagnostic laparoscopy in dogs. *Brazilian J. Vet. Res. and Animal Science.* 35: 123-126.

Silva, L. D. M.; Onclin, K.; Snaps, F. and Verstegen, J. (1995) : Laparoscopic intrauterine insemination in the bitch. *Theriogenology* 43: 612-623.

Spaw, A. T.; Ennis, B. W. and Spaw, L. P. (1991) : Laparoscopic hernia repair: the anatomic basis. *J. Laparoendosc. Surg.* 1: 269.

Thiele, S.; Kelch, G. and Gerlach, K. (1993) : Kastration der hundin durch laparoskopische ovariectomie. *Kleintierpraxis* 38: 463-466.

Trias, M.; Targarona, E. M. and Balague, C. (1996) : Laparoscopic spleenectomy: an evolving technique. A comparison between anterior and lateral approaches *Surg. Endosc.* 10: 389-392.

Twedt, D. C. (1999) : laparoscopy of the liver and pancreas. In small animal endoscopy by Tams, T. R. ed (1990) 2nd ed. Mosby st.;Louis pp 409-418.

Wang, P. H.; Lee, W. L.; Yuan, C. C.; Chao, H. T.; Liu, W. M.; Tsai, Y. K. and Wang, K. C. (2001) : Major complications of operative and diagnostic laparoscopy for gynecologic disease. *J. Am. Asso. of Gynaecologic laparoscopists* 8: 68-73.

Wildt, D. E.; Kinney, G. M. and Seager, S. W. J. (1977) : Laparoscopy for the direct observation of internal organs of the domestic cat and dog. *Am. J. Vet. Res.* 38: 1429-1432.

Wildt, D. E. (1980) : Laparoscopy in dog and cat. In animal laparoscopy by Harrison, R. M. and Wildt, D. E. eds. (1980) Williams & Wilkins, Baltimore.

Wildt, D. E.; Seager, S. W. J. and Bridges, C. H. (1981) : Sterilization of the male dog by laparoscopic occlusion of the ductus deferens. *Am. J. Vet. Res.* 42: 1888-1897.

Wildt, D. E. and Lawler, D. F. (1985) : Laparoscopic sterilization of the bitch and queen by ute-

rine horn occlusion. Am. J. Vet. Res. 46: 864-869.

Yerdel, M. A.; Karayalcin, K.; Koyuncu, A.; Akin, B.; Koksoy, C.; Turkcapar, A. G.; Erverdi, N.; Alacayir, I.; Bumin, C. and Aras, N. (1999) : Direct trocar insertion versus veress needle insertion in laparoscopic cholecystectomy. American Journal of surgery. 177: 249-274.

المخلص العربى

الاستخدامات التشخيصية التجريبية لمنظار البطن فى الكلاب

المشركون فى البحث

جمال الصياد مجدى سليم أيمن عتيبه

قسم الجراحة - كلية الطب البيطرى بكفر الشيخ - جامعة طنطا

تمت هذه الدراسة على ٦٥ كلب من الجنسين تتراوح أوزانهم ما بين ١٥ إلى ٢٥ كجم وقد أجريت هذه الدراسة بقسم الجراحة بكلية الطب البيطرى بكفر الشيخ جامعة طنطا.

تم تصوير الحيوانات لمدة ٢٤ ساعة ومنعها عن الماء فى يوم إجراء التجربة وإعدادها لإجراء خطوات منظار البطن عن طريق قص وحلاقة الشعر فى منطقة البطن.

وقد تم إجراء هذه الخطوات تحت تأثير المخدر العام (بنتوثال صوديوم) عن طريق الحقن فى الوريد وتم ترقيد الحيوان على ظهره وإجراء فتحه فى الجلد لاتتعدى ٣ مم بجوار السرة يتم من خلالها إدخال إبرة فيرز (Veress needle) وضع غاز ثانى أكسيد الكربون داخل بطن الحيوان ليصل ضغط الغاز عند حد معين وهو ١٤ : ١٥ ضغط زئبقى، ويعمل هذا الغاز داخل البطن على الفصل ما بين أعضاء البطن وجدار البطن مما يساعد على إدخال ثاقب المنظار وباقى الأدوات المساعدة بأقل المشاكل.

وتم بعد ذلك إدخال ثاقب المنظار فى البطن بعد إجراء فتحه فى الجلد باستخدام المشروط لاتتعدى ١ سم مع تحديد مكان الفتحة حسب نوع العضو المراد فحصه أو أخذ عينه منه.

وقد أظهرت النتائج أن تغيير وضع الحيوان يحسن من رؤية الأعضاء الداخلية للبطن حيث أن إرتفاع راس الحيوان فى الوضع راقداً على ظهره يحسن من رؤية الأعضاء فى النصف الأمامى للبطن نتيجة لتحريك معظم الأعضاء إلى النصف الخلفى وأيضاً تحريك الحيوان بخفض الرأس فى الوضع راقداً على ظهره يحسن من رؤية الأعضاء فى النصف الخلفى نتيجة لتحريك معظم الأعضاء إلى النصف الأمامى.

وتم إدخال ثاقب ثانى فى البطن تحت رؤية مباشرة من المنظار لإدخال أدوات مساعدة مثل المجس عديم الحس الذى يعمل على الفصل بين الأعضاء مما يساعد على رؤية أفضل للعضو المراد فحصه وأيضاً يساعد على إدخال جفت العينات الذى يتم من خلاله أخذ العينة من الكبد أو أى عضو آخر يراد أخذ عينه منه.

من هذه النتائج يمكننا إستخلاص الآتى :

- أن منظار البطن يعتبر من الأجهزة التى تساعد على الفحص الحقيقى لأعضاء البطن بصورة واضحة والتفريق بين السليم منها والمصاب عن طريق فتحة لاتتعدى 1سم ممايساعد على الالتئام السريع للجرح بأقل مشاكل.
- يوجد العديد من الأماكن لإدخال ثاقب المنظار ولكن لكل عضو من أعضاء البطن مكان مفضل يساعد على رؤيته بصورة أوضح.
- يمكن أخذ عينات من الكبد مع تحديد مكان أخذ العينة ورؤيته بوضوح وبأقل المشاكل .