

## **EFFECTS OF "PEDIOCOCCUS ACIDILACTIC" ON ZOOTECHNICAL PERFORMANCE AND E.COLI INFECTION IN BROILER CHICKENS**

**M. H. H. AWAAD, SAHAR A. ZOULFAKAR, M. O. EL-SHAZLY, MANAL, A. AFIFY  
and A. H. OSMAN**

Faculty of Veterinary Medicine, Cairo University.

Received: 1.3.2003.

Accepted:30.3.2003.

### **SUMMARY**

The effects of *Pediococcus acidilactici* (*P. acidilactici*) on zootechnical performance and *E.coli* infection in broiler chickens were determined.

The product significantly improved the zootechnical performance response variables including: body weight, weight gain, relative growth rate, European production efficiency factor (EPEF), total feed consumption, performance index, and final feed conversion rate as compared to the untreated controls. These results could be explained in the view that probiotics are natural control method that is based on ensuring the bird has an adequate gut microflora to counter pathogenic bacteria colonization in its digestive tract and consequently has healthy gut that results in good digestion and nutrient absorption.

Results of subcutaneous infection with pathogenic *E.coli* serogroup O 142 resulted in significant reduction in both the rate of mortality and lesion score in *P. acidilactici* treated group (64 % and 1.83) over their untreated control group (72 % and 2.39) respectively.

---

### **INTRODUCTION**

The gastrointestinal tract of poultry harbors microflora, which is formed immediately after the hatching bird is born and is an important barrier against colonization of potentially pathogenic microorganisms. The bird's microflora is potentially depleted for a period of time at hatching and following any medication with an anti-microbial product (Nigel Horrox, 1997).

Competitive exclusion (CE) is a term that has been used to describe the protective effect of the

natural or native bacterial flora of the intestine for limiting the colonization of some bacterial pathogens of chickens and turkeys. The first CE products were simply fecal contents from healthy adult chickens suspended in an aqueous solution and placed in the crop of the newly hatched chicks. Other research groups have developed defined mixtures of bacteria for use as CE products. CE products are also called probiotics, direct-fed microbials or CE cultures.

Probiotics (previously known as ecological health control products) are defined as cultures of living microorganisms which are able to proliferate in the host-bird's intestinal tract, resulting in a balanced microflora. A probiotic product is composed of pure cultures of one or more microorganisms (Mulder, 1996). Using probiotics is a natural control method that is based on ensuring the bird has an adequate gut microflora to counter pathogenic bacteria in its digestive tract.

This experiment was adopted to determine the possible effects of the probiotic "Pediococcus acidilactici" (*P. acidilactici*) on the zootechnical performance and E.coli infection in broiler chickens.

## MATERIAL AND METHODS

*P. acidilactici*. *P. acidilactici* MA 18 / 5M produced by Lallemand, France under the trade name "Bactocell®" was used and added in a

dosage of 100 g / ton feed.

Experimental chickens. A total of 600 day-old meat type chickens "Hubbard were assigned into 4 groups (1-4). Each group was consisting of 150 chickens reared in 3 replicate pens of 50 chicks each. All chickens fed on a commercial balanced ration ad libitum consumption.. They were vaccinated against Newcastle and Infectious bursal diseases using Hitchner B1 vaccine at 5 day old, Gumboro vaccine at 13 and 23 day-old and La Sota vaccine at 18 day-old. Starter ration was used for the first 4 weeks and a finisher feed for the remainder of the period. Ration contained semduramicin at a concentration of 25 PPM as a coccidiostate. No antibiotics were added to the ration.

Experimental design. The experiment lasted for 7 weeks. Chickens of groups 1 and 3 received ration containing *P. acidilactici*, while those of 2 and 4 received plain ration. Birds of groups 1 and 2 were weighted weekly, and chicken performance response variables were determined including:

- 1- Bird body weight by group (weekly).
- 2- Relative growth rate After Brady (1968).
- 3- Final body weight (at day 42).
- 4- Feed Conversion Ratio (FCR).
- 5- European production efficiency factor (EPEF) after Sainsbury (1984).
- 6- Performance index after North (1984).

For bioassay: chickens of groups 3 and 4 were subcutaneously infected with *E.coli* serogroup O142 (a highly pathogenic strain) in a dose of  $10^9$  CFU / bird at 28 days of age and were kept under observation for clinical signs and mortality for 3 weeks. Dead as well as sacrificed birds at the end of observation period was subjected to post-mortem lesion scoring. The lesions are given numeric score of 1 for mild, 2 for moderate and 3 for severe in the challenged birds. The mean per bird in the group is then plotted and a disease lesion profile for the flock could be obtained. Three chickens out of each group were sacrificed at 3, 7, 14 and 21 days post *E.coli* infection and specimens from heart, liver and spleen were kept in 10 % formol saline processed using conventional paraffin embedding technique, sectioned and stained with haematoxyline and eosin for histomorphological studie (Carleton, 1976) and the histopathological lesion score was then performed.

## RESULTS

Obtained results are shown in tables 1-3 and Figs. 1-2.

No histopathological changes were found in chickens of the uninfected blank control group throughout the experimental period. Lesions observed in other experimental groups were confined to liver and heart.

### Liver:

At 31 days of age, chickens showed congested hepatic blood vessels with mild perivascular heterophile cell infiltration. Similar findings were observed both in birds infected with *E.coli* and those treated with *P. acidilactici* and infected with *E.coli* which in addition, showed focal areas of hepatic necrosis (Fig. 1. A). By the 14<sup>th</sup> day of age, mild bile duct hyperplasia associated with portal mononuclearcell infiltration (Fig.1. B) and intense perivascular heterophile cell infiltration (Fig.1. C) were commonly observed in birds treated with *P. acidilactici*, whereas birds infected with *E.coli* and those treated with *P. acidilactici* and infected with *E. coli* revealed vacuolar degeneration of hepatocytes,variable sized multifocal areas of hepatic necrosis and mononuclear cell infiltration in which many heterophiles were seen (Fig.1. D) and dense aggregates of heterophiles (Fig. 1. E). By the 42 th.day lesions observed were similar to those found at 14 days but were less severe particularly in birds treated with *P. acidilactici* which revealed mild perivascular heterophile cell infiltration. The liver of birds treated with *P. acidilactici* (group 1) and those treated with *P. acidilactici* and infected with *E.coli* (group 3) appeared normal by the 49 th day, whereas minute foci of hepatic cell necrosis and mononuclear cell infiltration (Fig. 1. F) were still observed in birds infected with *E.coli* (group 4).

Table 1. The Zootechnical performance of treated and untreated broiler chickens with *P.acidilactici* (Bactocel®)

Group No.	Treatment	Age (days)	No. of birds	Body weight (g).	Weight gain	Feed consum. (kg).	Relative growth rate	@ EPEF	Feed consum. (total)	Performance index	** FCR final
1	Bactocill	0	150	N=150 51.600± 0.87	0	0	0%	0%	495.3	96.4	*1.850
		7		N=136 137.210 ± 0.995	85.6	14.4	90.7%	68.9*			
		14		N=134 269.290 ± 2.2	217.7	23.4	65.0%	74.4*			
		21		N=134 470.035± 3.86	418.4	51	54.3%	78.7*			
		28		N=133 744.437± 6.099	692.8	64.5	45.2%	93.5*			
		35		n=127* 1115.000±13.4	1063.4	108	39.9%	112.0*			
		42		n=124* 1379.033±16.88	1327.4	108	21.2%	115.4*			
		49		n=121* 1784.077±24.01	1732.5	126	25.6%	128.0*			
2	Control	0	150	N=150 51.6± 0.87	0	0	0%	0%	503.70	81.9	2.025
		7		N=138 134.756 ± 1.096	83.2	16.8	89.2%	49.3			
		14		n=138 261.076± 2.6	209.4	23.4	63.8%	47.7			
		21		n=121 456.347± 3.5	404.7	51	54.4%	55.6			
		28		n=120 718.308± 5.9	666.7	64.5	44.6%	65.7			
		35		n=114 980.000±13.21	928.4	108	30.8%	71.7			
		42		n=111 1273.420± 17.1	1221.8	108	26.0%	77.6			
		49		n=108 1658.425±24.03	1606.8	132	26.3%	86.7			

\* = Significance difference (P<0.05).

\*\* FCR = Feed conversion rate. N = Number of chicks.

± Standard error =  $\frac{\text{Standard deviation}}{n}$

**Statistical analysis of Zootechnical performance data:**

At the 95% significance level, comparison between Bactocill treated and untreated groups revealed:

- 1- Significant difference between mean body weight at 5th, 6th and 7th weeks of age.
- 2- Significant difference in European production efficiency factor (EPEF), performance index and the final feed conversion ratio (FCR).

Table 2: Results of subcutaneous infection of *P.acidilactici* (*Bactocel l®*) treated and untreated broiler chickens with  $10^9$  CFU of *E.coli* serogroup O142.

Group No.	Treatment	Age (days)	No. of birds	No. of survivors	No. of dead	Lesion score	Mortality rate	Protection percentage
3	Bactocell	7	150	150	0	1.83*	64%	36%*
		14		150	0			
		21		150	0			
		28		150	0			
		35		59	91			
		42		54	5			
		49		54	0			
4	Control	7	150	150	0	2.39	72%	28%
		14		150	0			
		21		150	0			
		28		150	0			
		35		51	99			
		42		43	8			
		49		42	1			

\* = Significance difference (P<0.05).

Statistical analysis of the challenge data:

At the 95% significance level, it was found that there is a significant difference between the disease lesion profiles as well as the mortality rate of the control birds (which received no Bactocell) and the birds receiving Bactocell from the start of the experiment (P<0.05).

Table 3: The severity index of histopathological changes in different chicken groups.

Weeks P.T.	<i>P.acidilactici</i> ( <i>Bactocel l®</i> ) treated group		<i>E.coli</i> infected group		<i>P.acidilactici</i> ( <i>Bactocel ®</i> ) treated and <i>E.coli</i> infected group		Blank control group	
	Heart	Liver	Heart	Liver	Heart	Liver	Heart	Liver
3	1	1	3	4	3	3	0	0
4	2	1	3	4	3	3	0	0
5	1	1	2	3	2	2	0	0
6	0	0	1	2	0	0	0	0

Severity index (Lesion score):

4 = Very severe, 3 = Severe, 2 = Moderate, 1 = Mild, 0 = No lesions.

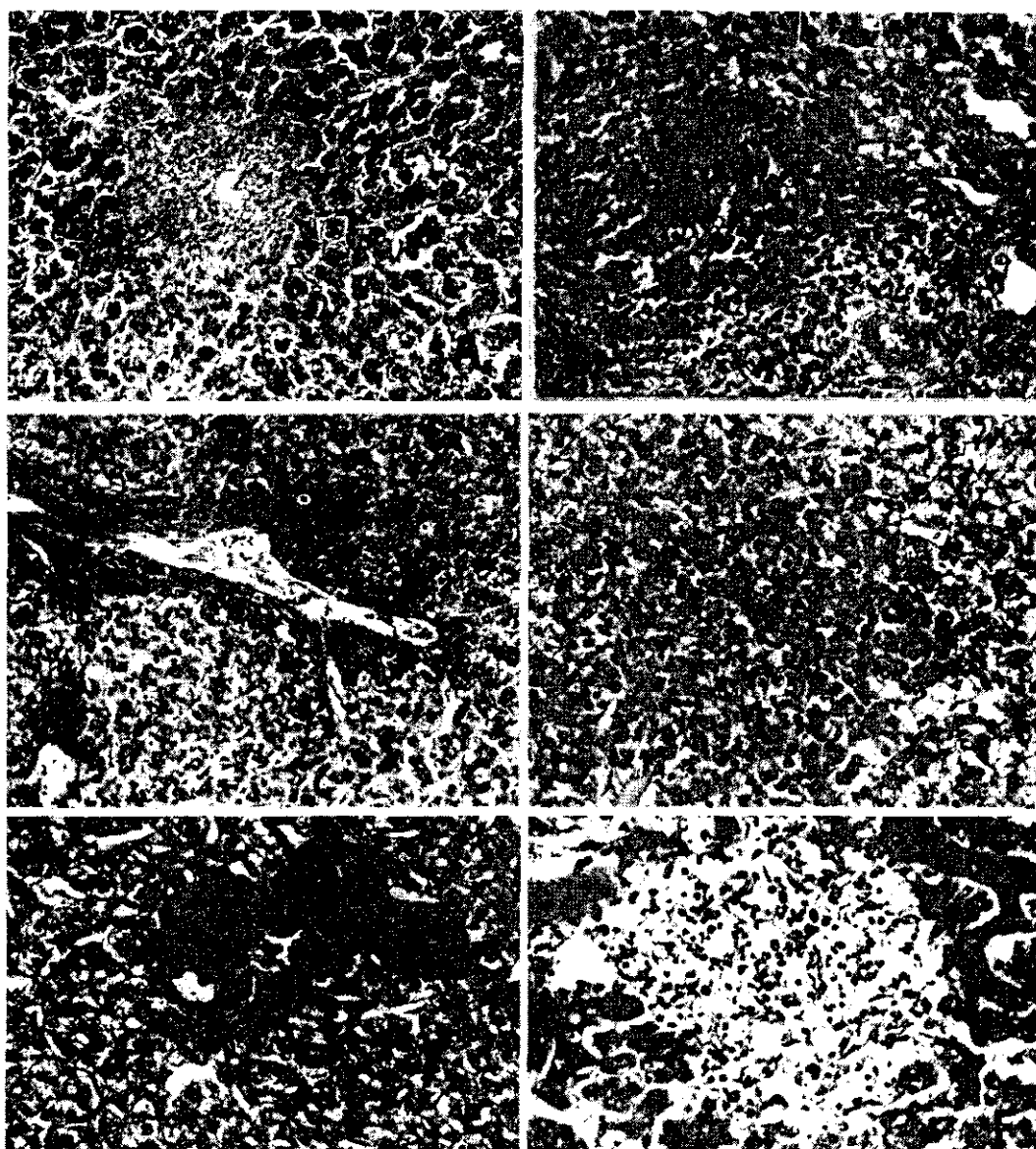


Fig.1: Liver A, 31 day-old chickens treated with *P.acidilactici* showing focal areas hepatic necrosis (H & E,X 33). B, the same bird group at 35 days of age showing bile duct hyperplasia and portal mononuclear cell infiltration (H & E,X66). C, the same bird group at 35 days of age showing intense perivascular heterophile cell infiltration (H & E, X33). D, chickens treated with *P.acidilactici* and infected with *E.coli* showing focal necrotic areas and mononuclear cell infiltration in which many heterophiles are observed (H & E X 132). E, the same bird group showing dense aggregates of heterophiles (H & E X 40). F, Birds infected with *E.coli* at 49 days of age showing small foci of hepatic cell necrosis and mononuclear cell infiltration (H & E X 132).

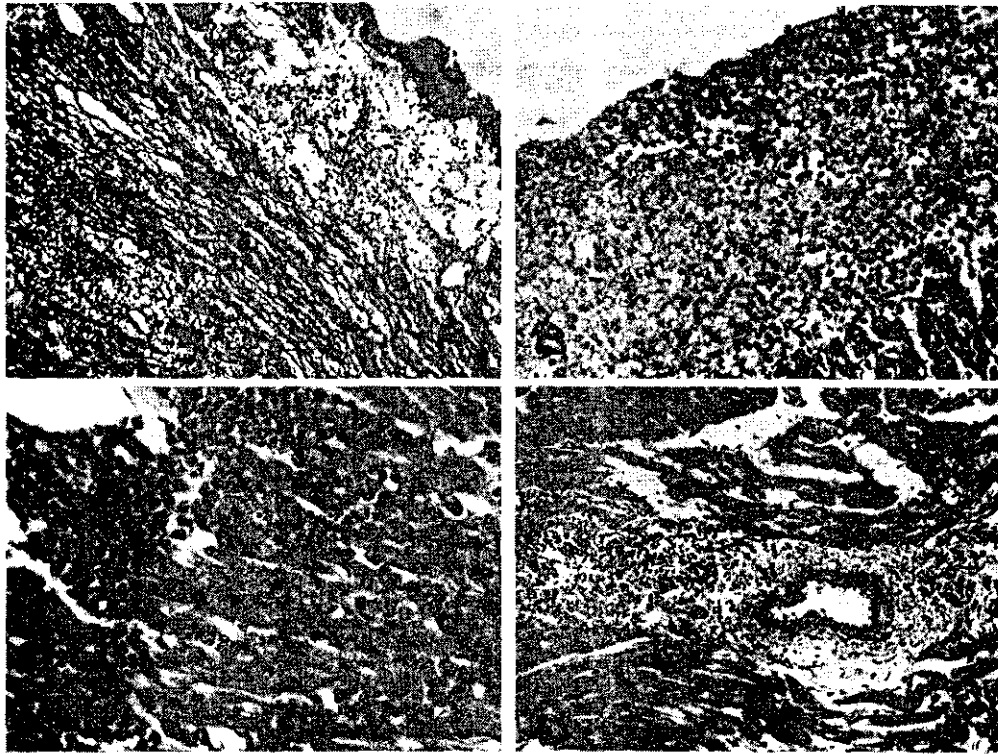


Fig. 2. Heart. A, 35 day-old chickens infected with *E.coli*, showing severe pericarditis and subepicardial myocarditis (H & E, X 33). B, 35 day-old chickens treated with *P.acidilactici* and infected with *E.coli* showing less severe pericarditis in which many heterophiles are evident (H & E, X 66). C, 42 day-old chickens treated with *P.acidilactici* showing myocardial heterophile cell infiltration (H & E, X 66). D, 49 day-old chickens infected with *E.coli* showing focal areas of non-suppurative myocarditis (H & E, X 66).

### Heart:

At 31 and 35 days of age, chickens of group 1 (*P. acidilactici* treated) showed mild myocardial heterophile cell infiltration, whereas birds infected with *E.coli* (group 4) revealed very severe pericarditis and subepicardial myocarditis. The pericardium and the underlying myocardium were intensely infiltrated with mononuclear cells (Fig. 2.A). Less severe pericarditis was observed in infected birds that were treated with *P. acidilactici* (group 3). Many heterophiles were seen infiltrating the pericardium (Fig. 2 B). By the 21<sup>st</sup> day of age, le-

sions observed were similar to those found 28 days of age in group 1 but were less severe. The myocardium of birds treated with *P. acidilactici* showed focal areas of myocardial heterophile cell infiltration (Fig.2.C). At 49 day of age, no pathological changes were seen both in birds treated with *P. acidilactici* either infected or uninfected with *E.coli*, whereas in untreated-infected birds, mild to moderate pericarditis and focal non-suppurative pericarditis (Fig. 2. D) was still evident.

## DISCUSSION

Using *P. acidilactici* in the ration of broiler chickens resulted in improvement in the zootechnical performance parameters including: body weight, weight gain, relative growth rate, European production efficiency factor (EPEF), total feed consumption, performance index, and final feed conversion rate as compared to the untreated control groups (Table 1 and Figs 1-6). Statistical analysis revealed significant differences in the mean body weight at 5th -7th week of age, in EPEF at 1st - 7th week of age, in performance index and in final FCR at 95% significance level. Improving of these parameters could be explained in the view that probiotics are natural

control method that is based on ensuring the bird has an adequate gut microflora to counter pathogenic bacteria colonization in its digestive tract and consequently has healthy gut that results in good digestion and nutrient absorption. Results of subcutaneous infection with pathogenic *E. coli* serogroup O 142 resulted in significant reduction in both the rate of mortality and lesion score in *P. acidilactici* treated group (64 % and 1.83) as compared with untreated group (72 % and 2.39) respectively (Table 2 and Figs. 2). This could be attributed to the high performance of birds induced by the prebiotic used which possibly indirectly improved the immune status of the treated chickens. Joan Jeffrey (1998) reported that the use of CE products can protect newly hatched,



highly susceptible chicks or poults being placed into commercial production systems and could be of great benefit in reducing colonization and disease caused by paratyphoid salmonellae. He added also that a similar protective effect has been demonstrated in controlled studies against *Escherichia coli*, *Campylobacter jejuni*, *Clostridium botulinum* and *Clostridium perfringens*. A view which completely accords with our present findings.

Mulder (1996) mentioned that probiotics are able to inhibit the growth of potentially pathogenic microorganisms by lowering the pH through production of lactate, lactic acid and volatile fatty acids.

Regarding our results and taking in consideration the report of Joan Jeffrey (1998) about the use of CE products to restore a protective microflora following disruption of the intestinal bacteria by a disease, alterations of intestinal flora due to stress, or effect of feed additives (such as antibiotics and coccidiostats) that can alter intestinal flora: the use of probiotics seems to be of great significance. Application of such policy in controlling intestinal infections likes to be the body's first line of defense against harmful microorganisms and this bacterial army prevents a range of illnesses. Moreover, it might be valuable in decreasing the use of antibiotics, whose usage may result in bacterial resistance and formation of residues in organs and tissues of treated birds.

In conclusion the present results clarified that *P. acidilactici* can make a valuable contribution to flock health and the safety of poultry products as food. It may provide a significant tool for the poultry industry in combating the occurrence of intestinal diseases and in reduction of food borne pathogens.

## REFERENCES

- Brady W. L. (1968): Measurement of some poultry performance parameters. Vet. Rec. 88: 245-260.
- Carlton, H. (1976): Carleton's; Histological technique. 4<sup>th</sup>. Ed. London, Oxford University press, New York.
- Joan S. Jeffrey (1998): University of California Poultry Symposium--University of California-Davis.
- Mulder, R.W.A.W (1996): Probiotics competitive exclusion microflora against salmonella. World Poultry, misset May 1996, 30-32.
- Nigel Horrex (1997): Salmonella - a practical overview. International Hatchery Practice, 12, No. 2, pp 15-17.
- North M.O. (1984): Broiler, Roaster, and Capon management Ch.20, P.387. "In commercial chicken production Manual". 3<sup>rd</sup>. Ed. By The AVI publishing Company Inc. West Port Connecticut.
- Sainsbury, D. (1984): Systems of management Ch.9 P. 102. In "Poultry health and Management ". 2<sup>nd</sup>. Ed. By D. Sainsbury. Granada Publishing Ltd. 8 Grafton Street. London W1X 3 LA.