

Department of Anatomy,  
Faculty of Medicine, Assiut University

## **EFFECT OF NICOTINE ON THE POSTNATAL DEVELOPMENT OF THE CEREBELLAR CORTEX OF ALBINO RAT**

(With 4 Tables and 24 Figures)

By

**M.A.M. GABR; A.T. GALAL; FATEN, Y. MAHMOUD and  
T.M. MOSTAFA**

(Received at 23/9/2004)

**تأثير النيكوتين على نمو قشرة المخيخ في الفأر الأبيض  
في مرحلة ما بعد الولادة**

**محمد عبد المقتى محمد جبر ، أحمد طلعت جلال ، فاتن يوسف محمود  
طارق محمد مصطفى**

يعد المخيخ مكون هام في الدائرة العصبية المسؤولة عن تنسيق ووضعية و تحريك العضلات وكذلك وضع الرأس. تهدف هذه الدراسة الى إيضاح تأثير مادة النيكوتين على نمو قشرة المخيخ في الفأر الأبيض في مرحلة ما بعد الولادة. استخدم في هذا البحث ثمانون فأر أبيض قسمت الى مجموعتين (مجموعة ضابطة ومجموعة تجريبية). تشمل المجموعة التجريبية نتاج الأمهات المعطاة مادة النيكوتين. وقد أعطيت مادة النيكوتين للأمهات الحوامل بداية من اليوم الرابع عشر من الحمل وكذلك طوال فترة الرضاعة بجرعة يومية تعادل 6 مجم لكل كيلو جرام من وزن الجسم بالحقن تحت الجلد. تم التضحية بثمانية من الحيوانات في كل من المجموعة الضابطة والمجموعة التجريبية عند الأعمار الآتية (حديث الولادة وعمر سبعة أيام وعمر خمسة عشر يوما وعمر واحد وعشرون يوما وعمر ستون يوما) واعداد عينات من قشرة المخيخ بها لدراستها بالميكروسكوب الإلكتروني النافذ وكذلك أجرى قياس لمبمك طبقات المخيخ (الطبقة الجزيئية وطبقة خلايا بيركنجى والطبقة المحببة الداخلية) وكذلك قياس عدد الخلايا خلال مساحة محددة (تعادل 12060 ميكرون مربع) من الطبقة المحببة الداخلية وأجراء التحليل الأحصائي لها. أوضحت نتائج هذا البحث اختفاء الطبقة المحببة الخارجية عند عمر واحد وعشرون يوما بعد الولادة في المجموعة الضابطة في حين استمر تواجدها في المجموعة التجريبية بعد هذا العمر. أما خلايا بيركنجى فقد ظلت مكونة من عدة طبقات حتى اليوم الخامس عشر بعد الولادة في المجموعة التجريبية مقارنة بالمجموعة الضابطة حيث رتبست في طبقة واحدة بنهاية الأسبوع الأول بعد الولادة. وقد تبين وجود العديد من الفجوات في الطبقة المحببة الداخلية بالمجموعة التجريبية. أما الفحص الدقيق لخلايا بيركنجى بالمجموعة التجريبية فقد أوضح وجود تغيرات انحلالية بها. وكذلك أظهر قياس سمك طبقات المخيخ وعدد الخلايا في الطبقة المحببة الداخلية بالمجموعة التجريبية وجود نقصا ذو دلالة

احصائية عند مقارنتها بمثيلاتها في المجموعة الضابطة. وقد أستنتج من هذه الدراسة أن النيكوتين يسبب تأخر نمو قشرة المخ مع تلف للخلايا العصبية بها ولهذا ينصح بامتناع عن التدخين أثناء فترة الحمل وخلال فترة الرضاعة.

## SUMMARY

The cerebellum is a crucial component in the neuron circuit responsible for muscle coordination, posture, locomotion and head position. The aim of this study is to clarify the effect of nicotine on the postnatal development of the cerebellar cortex in the albino rat. A total number of 80 albino rats were used in this work. They were divided into two groups, a control group and an experimental one. The experimental group included the offspring of nicotine treated mothers. Nicotine free base was administered to the pregnant rats started from the 14<sup>th</sup> day of gestation till birth and during the whole period of lactation. The dose of nicotine used in this study was 6 mg/ kg/ day. Nicotine was injected subcutaneously in a single dose. Eight animals in both control and nicotine treated groups were sacrificed at the following ages (newly born, seven days, fifteen days, twenty-one days and sixty days). Specimens of the cerebellar cortex were processed for the study by transmission electron microscope. The thickness of the cerebellar cortical layers (molecular, purkinje and internal granular layers) and the number of cells in the internal granular layer per field (12060 micron<sup>2</sup>) were measured and statistically analyzed. The results of the present work revealed complete disappearance of the external granular layer at twenty one postnatal day in the control group while it was noticed persistence of it in the nicotine-treated group after this age. In the nicotine treated group, the purkinje cell layer remained as multicellular layer till the age of fifteen days in comparison with the control group which attained the typical moncellular pattern by the end of the first week. Several cavities appeared to be present in the internal granular layer of nicotine-treated group. The ultrastructural study of purkinje neurons of the nicotine-treated group showed the presence of many degenerative changes. The thickness of the cerebellar cortical layers and the number of cells in the internal granular layer revealed statistically significant decrease in the nicotine-treated group at all ages as compared with that of the control. It was concluded from this work that nicotine could induce delayed cerebellar development with neuronal damage. So, cigarette smoking was recommended to be prohibited during pregnancy and through the period of lactation.

**Key words:** *Nicotine, cerebellar cortex, development, rat.*

## **INTRODUCTION**

The increased prevalence of smoking has received considerable public attention. Nicotine is the principle active component in cigarette and cigar (Anderson *et al.*, 2002). It has good lipid solubility. It is rapidly absorbed through oral mucosa, respiratory tract, gastrointestinal tract as well as skin (Ellenhorn *et al.*, 1997). Sastry and Chance (1994) reported that nicotine crosses freely the placental barrier and transfers to the fetal compartment. They found that the fetal nicotine concentration is higher than the maternal concentration. Furthermore, nicotine is excreted in the breast milk (Klonoff-Cohen *et al.*, 1995). De Zwart and Sellman (2002) reported that maternal smoking, either actively or passively, has not only an adverse pregnancy outcome but also a potential long-term effects on both maternal and fetal health. Slotkin *et al.* (2000) stated that prenatal and neonatal nicotine exposure evokes alterations in the development of central nervous system structurally, neurochemically and neurobehaviorally.

The cerebellum is a crucial component in the neuron circuit. It is responsible for muscle coordination, posture, locomotion and head position. It is one of the few regions of the rat brain that undergoes a profound morphogenetic transformation after birth (Carpenter, 1991). The aim of this study is to clarify the effect of nicotine on the postnatal development of the cerebellar cortex in the albino rat.

## **MATERIALS and METHODS**

In this work, a total number of 80 albino rats were used. They were divided into two groups, a control group and an experimental one. The experimental group included the offspring of nicotine treated mothers. Nicotine free base was administered to the pregnant rats started from the 14<sup>th</sup> day of gestation till birth and during the whole period of lactation (21<sup>st</sup> day postnatally). Then the nicotine administration was stopped. The dose of nicotine used in this study was 6 mg/kg/ day. Nicotine was injected subcutaneously in a single dose. The control group included the offspring of non treated mothers. The control mother rats were injected by saline on the same regimen. Eight animals in both control and nicotine-treated groups were sacrificed at the following ages: newly born, seven days, fifteen days, twenty-one days and sixty days.

The cerebella were extracted and fixed in cacodylate buffered glutaraldehyde solution (PH > 7.2). Pieces of cerebellar vermis were processed for the ultrastructural study with transmission electron microscope. Semithin sections (0.5 – 1  $\mu$ m) were stained with toluidine blue. Ultrathin sections (450-500  $\text{\AA}$ ) were stained with uranyl acetate and lead citrate. Stained ultrathin sections were examined by Jeol- JEM-100 CXII electron microscopy.

### **Morphometric procedure**

In this work, estimation of the thickness of the molecular, purkinje and internal granular layers and the number of cells in the internal granular layer per field (12060  $\mu\text{m}^2$ ) were done. All these parameters were estimated in both control and nicotine treated groups at the previously selected ages. They were measured from semithin sections using computerized image processing and analysis system Lecia Q500 M.C.

### **Statistical analysis:**

For both the control and nicotine treated rats in each age, the mean and standard error for the thickness of the cerebellar cortical layers and the number of cells in the internal granular layer per field (12060  $\mu\text{m}^2$ ) were calculated. Difference between groups were tested by the student's t-test.

## **RESULTS**

### **Newly born rats:**

In the control animals, the cerebellar cortex at this age shows the presence of the following layers: external granular layer, molecular layer, purkinje cell layer and internal granular layer, from the pial surface inward. The external granular layer is formed of a relatively thick sheet of rounded and oval cells lying underneath the pial surface. The molecular layer is poorly developed pale zone formed of few oblonged cells with several mitotic figures. The purkinje cell layer appears as a multilayered sheet of relatively large cells intermingled with those of the superficial zone of the internal granular layer. The line of demarcation between the molecular layer and purkinje cell layer is ill-defined. The internal granular layer is formed of packed, deeply stained round cells (Fig.1). The ultrastructure of the purkinje neuron shows that the cell has a considerable degree of differentiation. It has an oval nucleus with fine granular chromatin. The nucleus is surrounded by a

narrow rim of cytoplasm which contains mitochondria, rough endoplasmic reticulum and free ribosomes (Fig. 11).

In the nicotine-treated animals, the external granular layer shows the presence of multiple cavities. The molecular layer is formed of faintly stained cells. Purkinje cells are relatively small with pale staining as compared with those of the control. The internal granular layer shows the presence of several cavities (Fig. 2). The ultrastructure of the purkinje neuron demonstrates that it is less differentiated as compared with the control. Its nucleus shows the presence of multiple invaginations of the nuclear membrane. The cytoplasm contains swollen rough endoplasmic reticulum, damaged mitochondria, free ribosomes and many lysosomes (Fig. 12).

#### **Seven days old rats:**

In the control animals, the molecular layer appears at this age as a well defined zone and shows marked increase in its cellularity. The purkinje cell layer is formed of a single row of well-defined cells arranged parallel to the pial surface. These cells have large sized and flask shaped body with well-defined nuclei and prominent nucleoli. Purkinje cells are still intermingled within the cells of superficial zone of the internal granular layer. The internal granular layer is stuffed with densely packed round cells with well defined nuclei (Fig. 3). The ultrastructure of the purkinje neurons shows well developed nuclei with homogenous distribution of chromatin. The cytoplasm contains many free ribosomes, rough endoplasmic reticulum and mitochondria (Fig.13).

In the nicotine-treated animals, the molecular layer seems to be hypocellular as compared with the control animals. The purkinje cell layer is still a multilaminated layer composed of more than two rows of cells. The cytoplasm of the purkinje cells appears to be faintly stained with relatively ill-defined nuclei and nucleoli. Multiple cavities are present within the internal granular layer (Fig. 4). The ultrastructure of the purkinje neurons shows irregularly shaped nuclei with multiple invaginations of the nuclear membrane. The nucleus also has multiple densely stained chromatin patches. The cytoplasm contains damaged mitochondria, free ribosomes and many lysosomes (Fig. 14).

#### **Fifteen days old rats:**

In the control animals, the molecular layer appears to reach its maximal cellularity by this age. It contains many round and oval cells. The purkinje cells are well developed and arranged in a single row. They contain an abundant amount of Nissl granules, well defined nuclei and prominent nucleoli. The internal granular layer is well developed

(Fig. 5). The ultrastructural features of the purkinje neuron at this age demonstrate that the cell has oval nucleus with fine granular chromatin. The cytoplasm appears to be rich with mitochondria, rough endoplasmic reticulum and free ribosomes (Fig. 15).

In the nicotine-treated animals, the molecular layer appears relatively hypocellular than that of the control animals. The purkinje cell layer is still formed of more than one row of cells. Purkinje cells are of variable size and distorted in shape. Some cells appear to be separated from the underlying internal granular layer. The internal granular layer shows the presence of multiple cavities (Fig. 6). The ultrastructure of the purkinje neuron shows delayed differentiation which is manifested by the presence of irregular shaped nucleus. The cytoplasm shows the presence of free ribosomes, vesicles of variable size and many lysosomes (Fig. 16).

#### **Twenty one days old rat:**

In the control animals, the cerebellar cortex at this age reveals complete disappearance of the external granular layer. The molecular layer has a considerable number of cells. The purkinje cell layer is well defined. These cells are arranged in one row which are widely separated from each other. The internal granular layer is well developed and formed of well defined granular cells with deeply stained nuclei (Fig. 7). The ultrastructural picture of purkinje neurons shows well circumscribed nuclei with evenly distributed chromatin material. The cytoplasm is filled with free ribosomes, numerous mitochondria and rough endoplasmic reticulum (Fig. 17).

In the nicotine-treated animals, the external granular layer still persists and shows few scattered cells that are arranged in two rows. The molecular layer contains many swollen round cells. Purkinje cells appear to be faintly stained and lying close to each other. The internal granular layer shows the presence of multiple cavities (Fig. 8). The ultrastructure of purkinje neuron demonstrates that the nucleus has peripheral condensation of chromatin. The cytoplasm contains ribosomes, short swollen segments of rough endoplasmic reticulum and many lysosomes (Fig. 18).

#### **Sixty days old rats:**

In the control animals, the cerebellar cortex at this age shows that the molecular layer appears to be well developed. The purkinje cell layer is well-defined and widely separated from each other. They contain distinct nuclei with prominent nucleoli. The internal granular layer is well developed (Fig. 9). The ultrastructural features of purkinje neurons

show the presence of well developed oval centrally located nuclei with fine granular chromatin. The cytoplasm is rich with free ribosomes, rough endoplasmic reticulum and mitochondria (Fig. 19).

In the nicotine-treated animals, the molecular layer shows a relative decrease in width as compared with the control one. It also shows the presence of some swollen cells. The purkinje cells appear to be swollen and faintly stained. The internal granular layer shows the presence of many cavities (Fig. 10). The ultrastructural study of purkinje neuron shows that it has a relatively small nucleus with peripheral chromatin condensation. The cytoplasm contains swollen cisternae of rough endoplasmic reticulum, free ribosomes and many lysosomes (Fig. 20).

### **Morphometric findings:**

Estimation of the molecular layer thickness shows highly significant decrease ( $P < 0.001$ ) in the nicotine-treated animals at all ages as compared with that of the control animals. The means of the molecular layer thickness at 7 days, 15 days, 21 days and 60 days old nicotine-treated animals are ( $46.74 \pm 0.1245$ ,  $97.11 \pm 0.1929$ ,  $127.2 \pm 0.2099$  and  $138.4 \pm 0.2002$ ) and in the control animals at the same ages are ( $61.77 \pm 0.096$ ,  $99.4 \pm 0.2864$ ,  $130.8 \pm 0.1107$  and  $139.9 \pm 0.194$ ) respectively (Table 1, Fig. 21).

The mean thickness of the purkinje cell layer at 7 days old nicotine-treated animals is ( $21.64 \pm 0.01269$ ) which shows highly significant decrease ( $P < 0.001$ ) as compared with that of the control animals ( $23.35 \pm 0.2448$ ). At 15 days old nicotine-treated rats, there is mild significant decrease ( $P < 0.05$ ) in the thickness of the purkinje cell layer where the mean is ( $22.35 \pm 0.1786$ ) and in the control is ( $22.93 \pm 0.271$ ). The thickness of the purkinje cell layer shows moderate significant decrease ( $P < 0.01$ ) in the 21 days old nicotine-treated rats where the mean is ( $23.62 \pm 0.1109$ ) as compared with that of the control ( $24.21 \pm 0.1323$ ). The mean thickness of the purkinje cell layer at 60 days old nicotine-treated animals is ( $25.36 \pm 0.1158$ ) which shows mild significant decrease ( $P < 0.05$ ) than that of the control animals ( $26.01 \pm 0.2297$ ) (Table 2, Fig. 22).

The thickness of the internal granular layer in the nicotine-treated rats shows decrease at the all ages as compared with that of the control rats. This decrease is non significant at the newly born and 7 days old nicotine-treated rats where the means of the internal granular layer thickness are ( $52.1 \pm 0.0903$  and  $73.11 \pm 0.0983$ ) and in the control are

( $52.15 \pm 0.1111$  and  $73.28 \pm 0.0728$ ) respectively. The decrease is found to be highly significant ( $P < 0.001$ ) at 15 days, 21 days and 60 days old nicotine-treated rats where the means of the internal granular layer thickness are ( $94.65 \pm 0.0441$ ,  $119.1 \pm 0.1710$  and  $136.7 \pm 0.1819$ ) and in the control are ( $115.6 \pm 0.0988$ ,  $142.7 \pm 0.0514$  and  $146.9 \pm 0.1614$ ) respectively (Table 3, Fig. 23).

Measuring the mean number of cells per field ( $12060 \text{ micron}^2$ ) within the internal granular layer at the newly born nicotine-treated rats is found to be ( $121.8 \pm 0.2906$ ) which shows no difference from that of the control ( $121.8 \pm 0.359$ ). At 7 days old nicotine-treated rats, the mean number of cells per field ( $12060 \text{ micron}^2$ ) in the internal granular layer is ( $124.6 \pm 0.2667$ ) which shows mild significant decrease ( $P < 0.05$ ) than that of the control ( $125.8 \pm 0.4667$ ). The number of cells per field ( $12060 \text{ micron}^2$ ) within the internal granular layer shows highly significant decrease ( $P < 0.001$ ) at 15 and 21 days old nicotine-treated rats where the means are ( $139.1 \pm 0.2333$  and  $158.2 \pm 0.2$ ) and in the control animals are ( $145.1 \pm 0.233$  and  $162.7 \pm 0.2134$ ) respectively. The mean number of cells per field ( $12060 \text{ micron}^2$ ) within the internal granular layers at 60 days old nicotine-treated rats is ( $102.9 \pm 0.314$ ) which shows significant increase ( $P < 0.001$ ) as compared with that of the control ( $99.7 \pm 0.3$ ) (Table 4, Fig. 24).

## LEGENDS FOR FIGURES

**Fig. 1:** A photomicrograph of semithin section of the cerebellar cortex of newborn control rats. It shows well differentiated external granular layer (EGL); the molecular layer (ML) is formed of few oblonged cells with mitotic figure among these cells (arrow), purkinje cells (P) are arranged in multiple rows and the internal granular layer (IGL) is formed of packed round cells .

(Toluidine blue; X400)

**Fig. 2:** A photomicrograph of semithin section of the cerebellar cortex of newborn nicotine-treated rats. It shows multiple cavities (arrows) in the external granular layer (EGL), cells of the molecular layer (ML) are faintly stained, purkinje cells (P) are relatively small as compared with the control and the internal granular layer (IGL) shows the presence of many cavities (arrows).

(Toluidine blue; X400)



**Fig. 3:** A photomicrograph of semithin section of the cerebellar cortex of seven days old control rats. It shows increase in the cellularity of the molecular layer (ML) than the previous age, purkinje cells (P) are arranged in a single row and the internal granular layer (IGL) is stuffed with densely packed round cells.

(Toluidine blue; X400)

**Fig. 4:** A photomicrograph of semithin section of the cerebellar cortex of seven days old nicotine-treated rats. It shows hypocellularity of the molecular layer (ML) as compared with the control. Note that the purkinje cells (P) are faintly stained and arranged in 2-3 rows and the internal granular layer (IGL) shows the presence of multiple cavities (arrows).

(Toluidine blue; X400)

**Fig. 5:** A photomicrograph of semithin section of the cerebellar cortex of fifteen days old control rats. It shows that the purkinje cells (P) are arranged in a single row and have well defined nuclei prominent nucleoli. Note that the internal granular layer (IGL) is well developed.

(Toluidine blue; X400)

**Fig. 6:** A photomicrograph of semithin section of the cerebellar cortex of fifteen days old nicotine-treated rats showing distorted purkinje cells (P) that are arranged in two rows in some areas. Note the presence of many cavities (arrows ) within the internal granular layer (IGL).

(Toluidine blue; X400)

**Fig. 7:** A photomicrograph of semithin section of the cerebellar cortex of twenty one days old control rats showing complete disappearance of the external granular layer. Note that the molecular layer (ML) has a considerable number of cells, the purkinje cells (P) contains an abundant amount of Nissl granules and widely separated from each other and the internal granular layer (IGL) is formed of cells with deeply stained nuclei.

(Toluidine blue; X400)

**Fig. 8:** A photomicrograph of semithin section of the cerebellar cortex of twenty one days old nicotine-treated rats showing persistence of the external granular layer (EGL). Note that the molecular layer (ML) contains many swollen cells, purkinje cells (P) are faintly stained and lying close to each other and the presence of many cavities (arrows) within the internal granular layer (IGL).

(Toluidine blue; X400)

**Fig. 9:** A photomicrograph of semithin section of the cerebellar cortex of sixty days old control rats showing well developed molecular layer (ML), purkinje cells layer (P) and internal granular layer (IGL).

(Toluidine blue; X400)

**Fig. 10:** A photomicrograph of semithin section of the cerebellar cortex of sixty days old nicotine-treated rats. It shows the presence of some swollen cells in the molecular layer (ML), purkinje cells (P) are swollen and faintly stained and the presence of many cavities (arrows) within the internal granular layer (IGL).

(Toluidine blue; X400)

**Fig. 11:** Electron photomicrograph of purkinje neuron in the newborn control rat cerebellar cortex. It shows that the cell has oval nucleus (N) with fine granular chromatin. The nucleus is surrounded by a narrow rim of cytoplasm which contains mitochondria (M), rough endoplasmic reticulum (RER) and free ribosomes (R).

(X 6.700)

**Fig. 12:** Electron photomicrograph of purkinje neuron in the newborn nicotine- treated rat cerebellar cortex. It shows that the nucleus (N) has multiple invaginations of the nuclear membrane. The cytoplasm contains swollen rough endoplasmic reticulum (RER), damaged mitochondria (M), free ribosomes (R) and many lysosomes (L).

(X 6.700)

**Fig. 13:** Electron photomicrograph of purkinje neuron of seven days old control rat cerebellar cortex. It shows that the cell has well developed nucleus (N) with homogenous distribution of chromatin. The cytoplasm has many free ribosomes (R), rough endoplasmic reticulum (RER) and mitochondria (M).

(X 6.700)

**Fig. 14:** Electron photomicrograph of purkinje neuron of seven days old nicotine-treated rat cerebellar cortex showing irregular shaped nucleus (N) with multiple densely stained chromatin patches. The cytoplasm shows the presence of damaged mitochondria (M), free ribosomes (R) and many lysosomes (L).

(X 6.700)

**Fig. 15:** Electron photomicrograph of purkinje neuron of fifteen days old control rat cerebellar cortex showing that it has oval nucleus (N) with fine granular chromatin. The cytoplasm contains mitochondria (M), rough endoplasmic reticulum (RER) and free ribosomes (R).

(X 6.700)

**Fig. 16:** Electron photomicrograph of purkinje neuron of fifteen days old nicotine-treated rat cerebellar cortex showing that it has irregular shaped nucleus (N). The cytoplasm shows the presence of free ribosomes (R), vesicles of variable size (V) and many lysosomes (L).

(X 6.700)

**Fig. 17:** Electron photomicrograph of purkinje neuron of twenty one days old control rat cerebellar cortex showing that the nucleus (N) has evenly distributed chromatin material. The cytoplasm contains mitochondria (M), rough endoplasmic reticulum (RER) and many free ribosomes (R),.

(X 6.700)

**Fig. 18:** Electron photomicrograph of purkinje neuron of twenty one days old nicotine-treated rat cerebellar cortex. It shows that the nucleus (N) has peripheral condensation of chromatin. The cytoplasm contains swollen rough endoplasmic reticulum (RER), ribosomes (R), and many lysosomes (L).

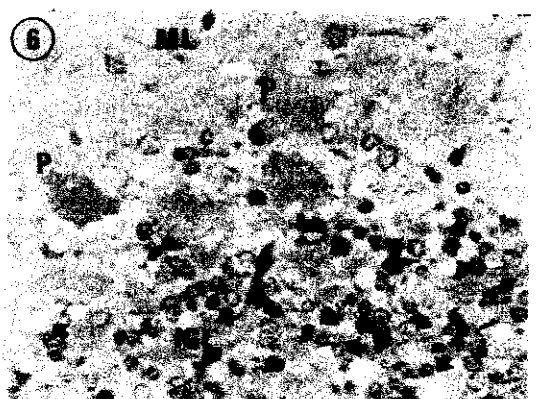
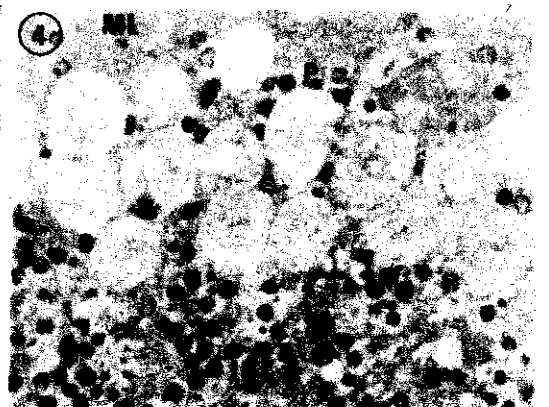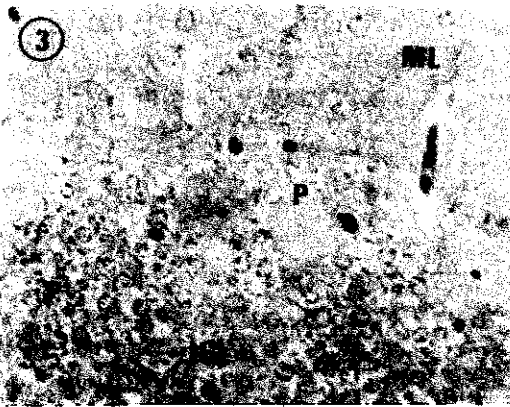
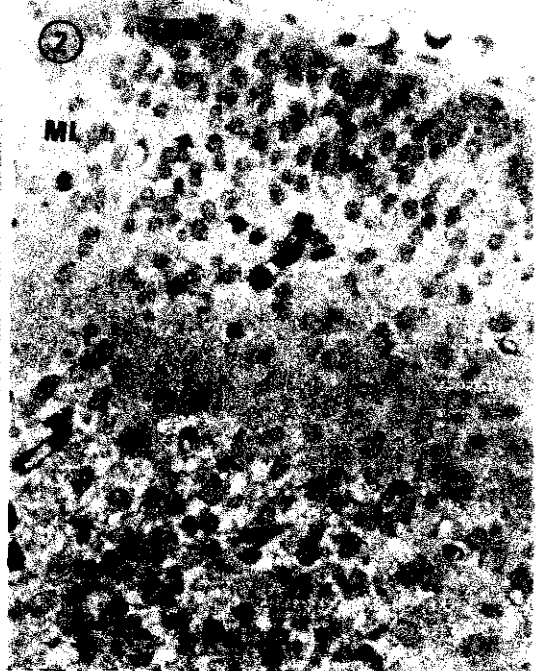
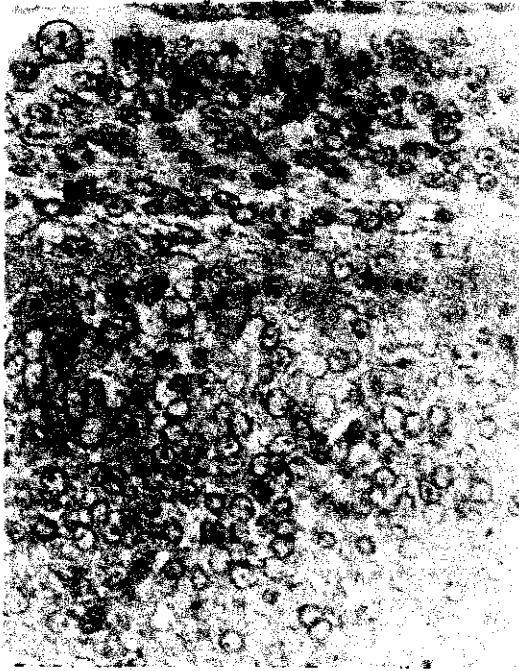
(X 6.700)

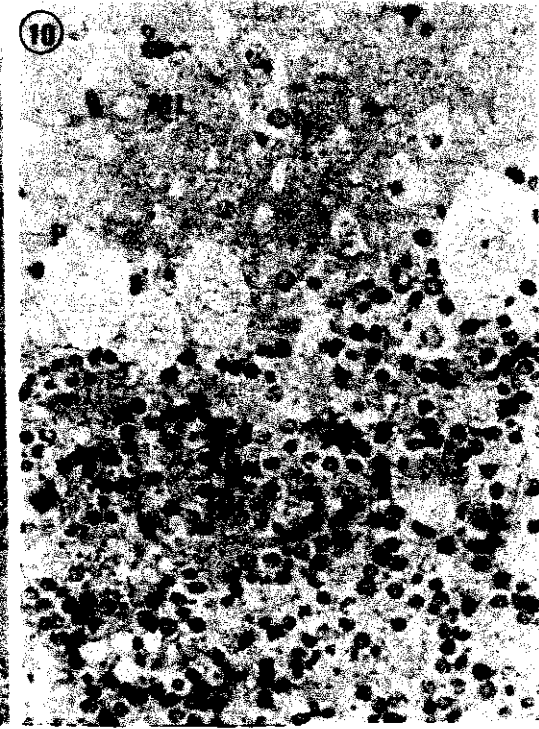
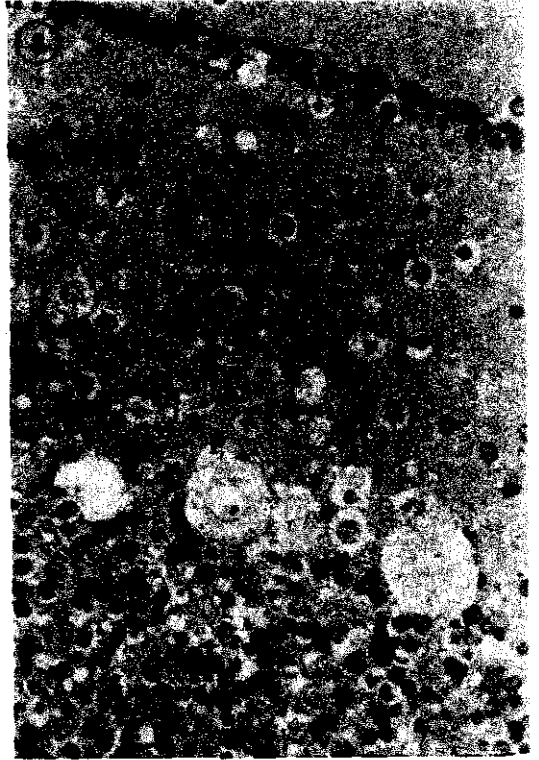
**Fig. 19:** Electron photomicrograph of purkinje neuron of sixty days old control rat cerebellar cortex. It shows well developed oval centrally located nucleus (N) with fine granular chromatin. The cytoplasm is rich with free ribosomes (R), rough endoplasmic reticulum (RER) and mitochondria (M).

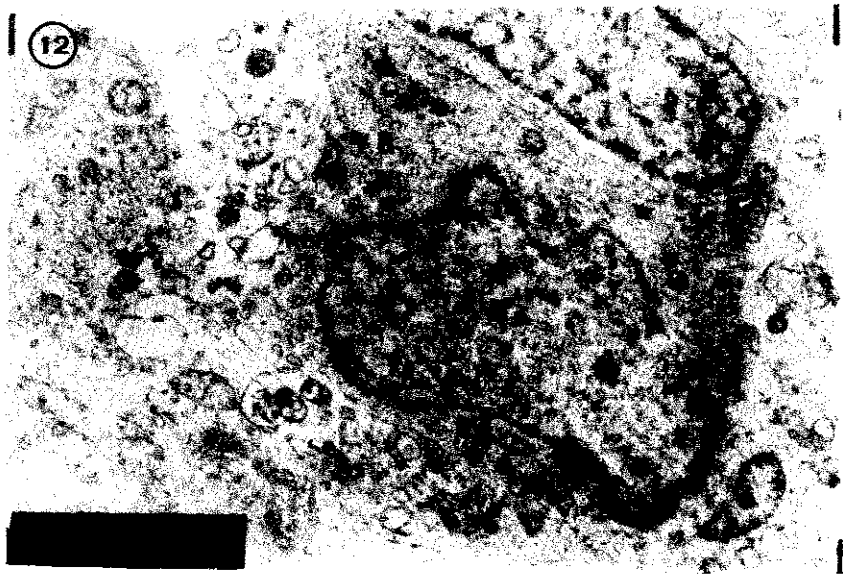
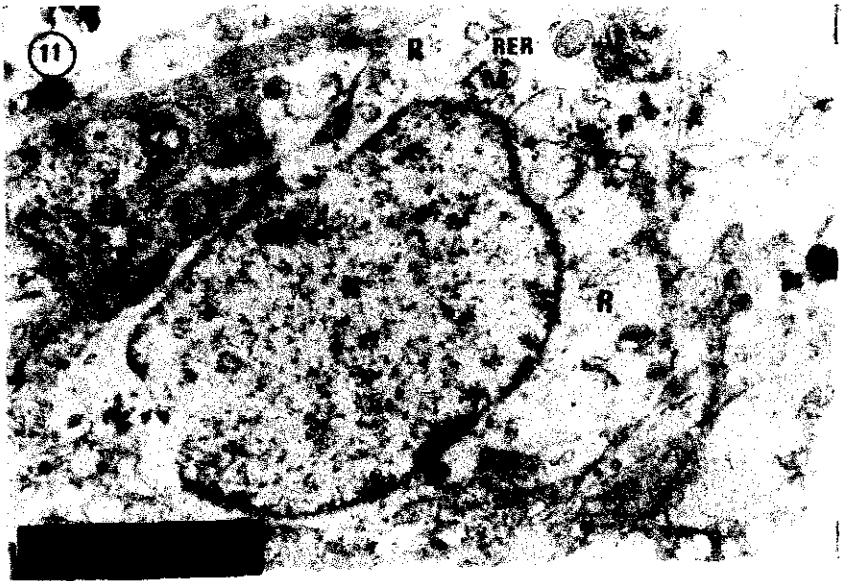
(X 6.700)

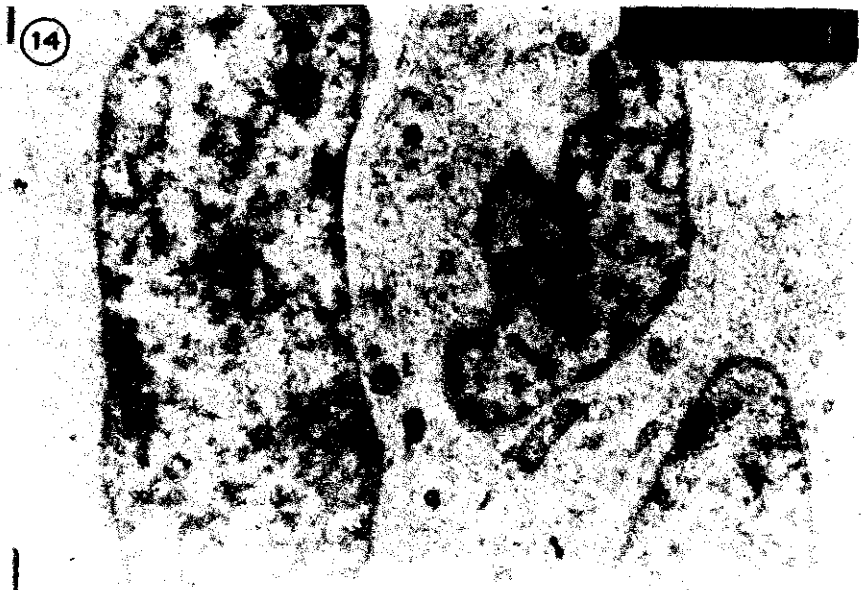
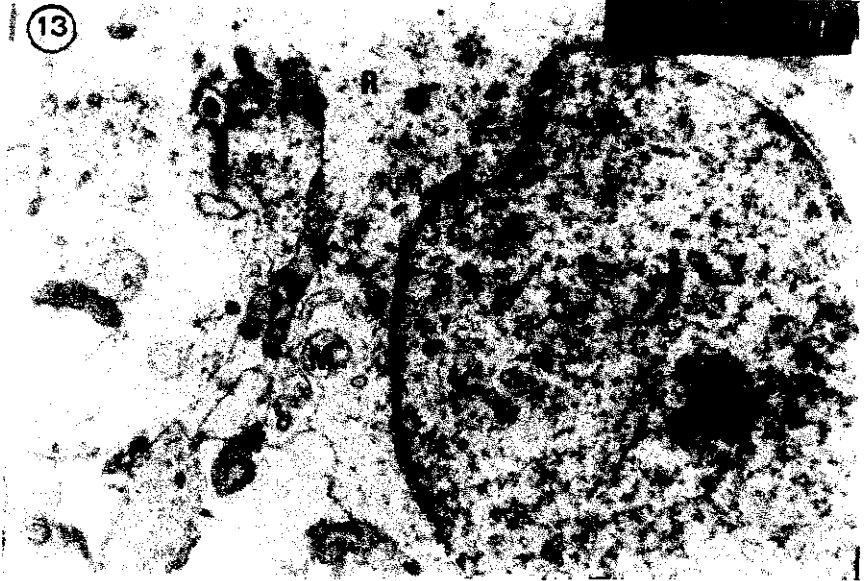
**Fig. 20:** Electron photomicrograph of purkinje neuron of sixty days old nicotine-treated rat cerebellar cortex showing that it has relatively small nucleus (N) with peripheral chromatin condensation. The cytoplasm contains swollen rough endoplasmic reticulum (RER), free ribosomes (R) and lysosomes (L).

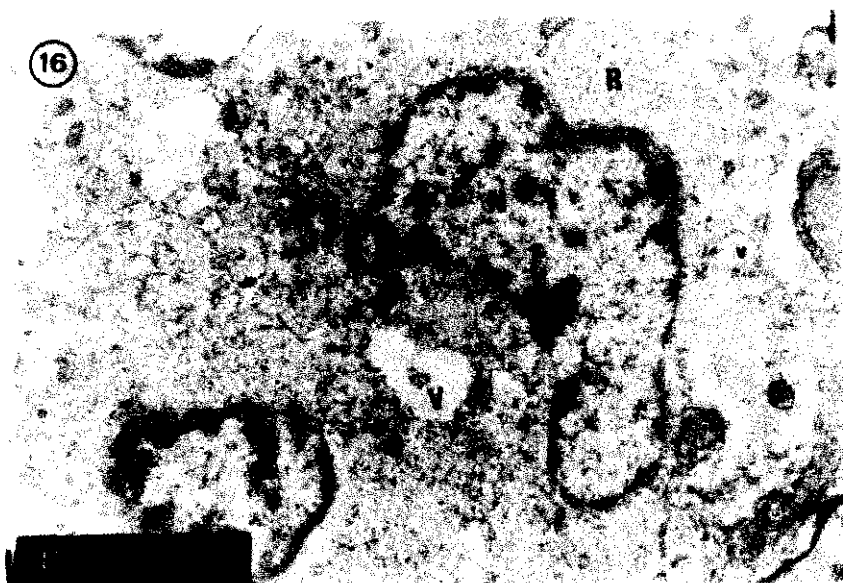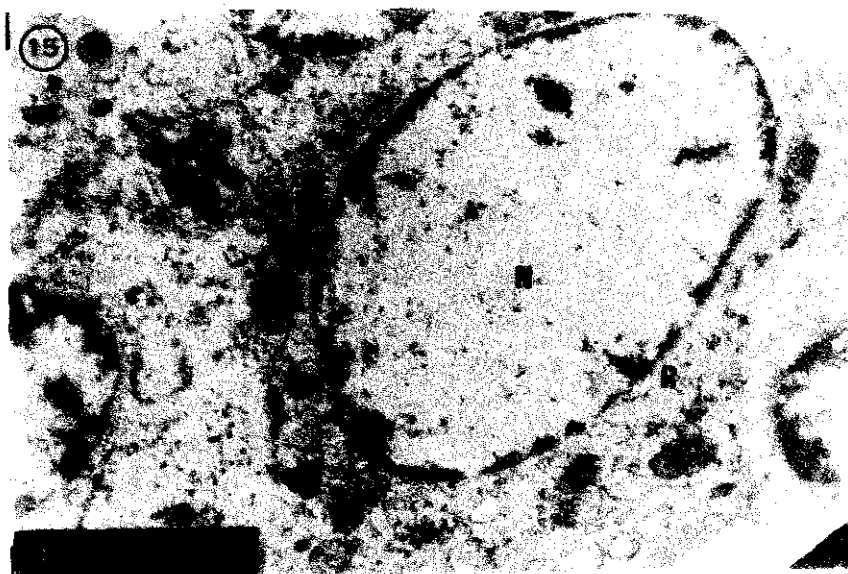
(X 6.700)



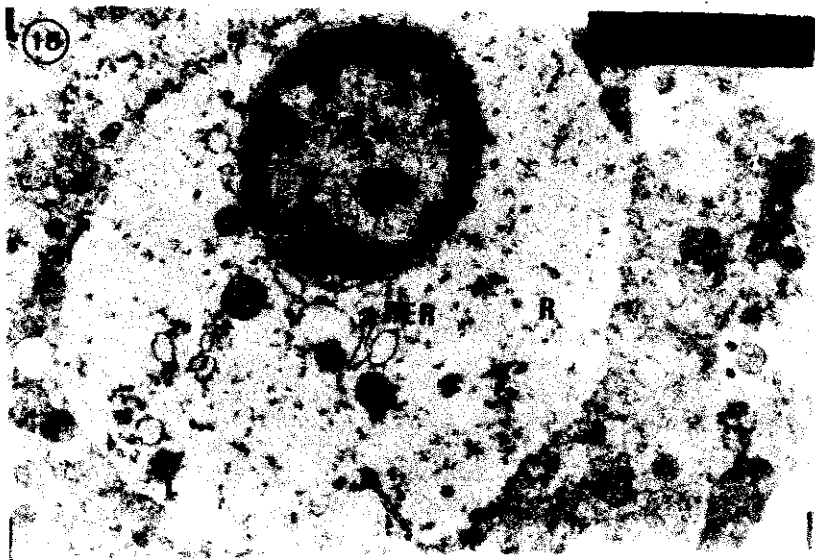
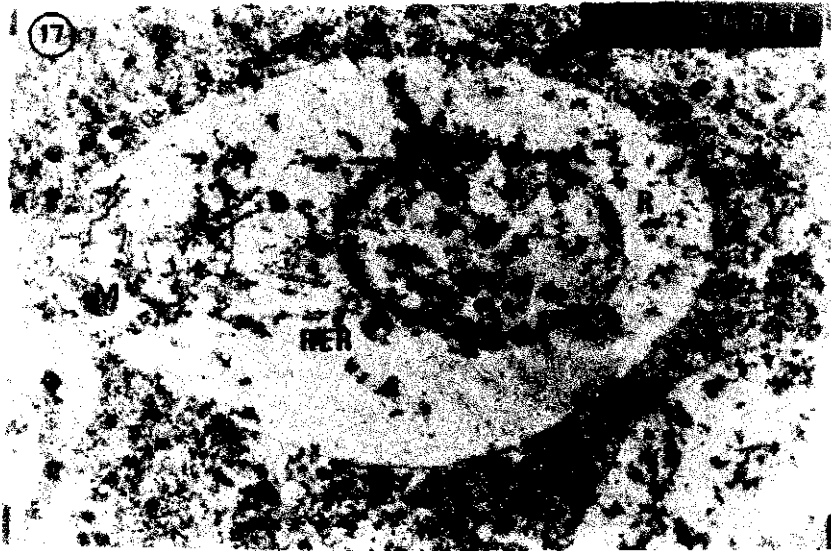


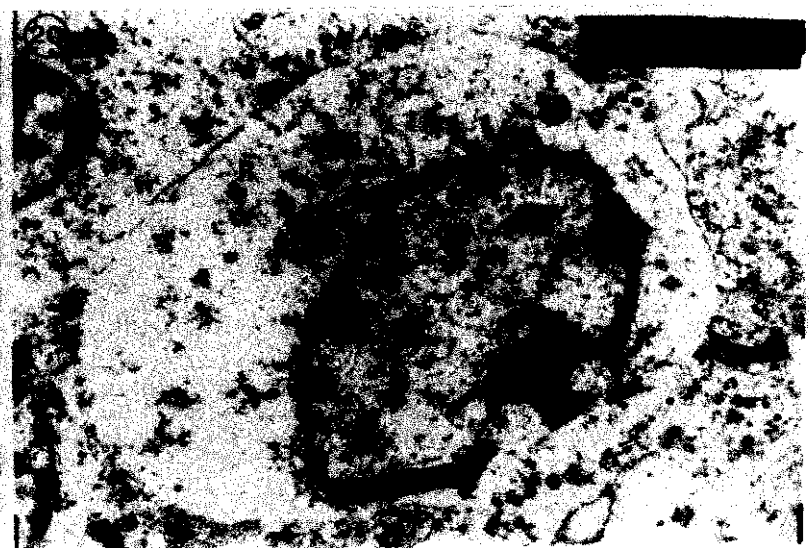
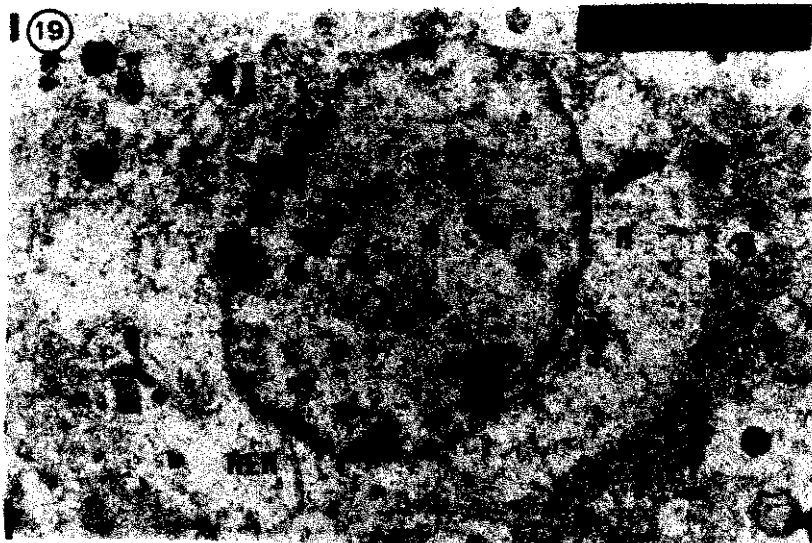












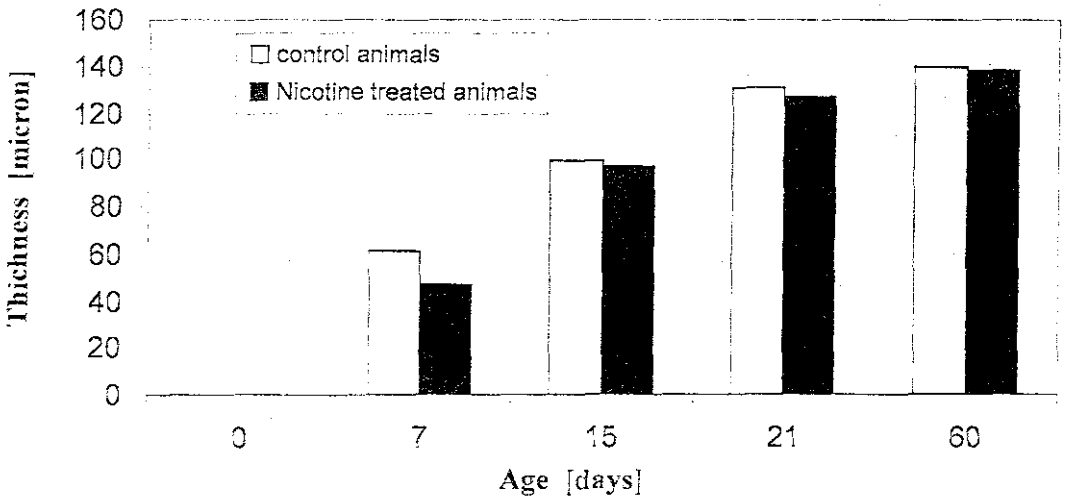
**Table 1:** Thickness of the molecular layer (micron) of control and nicotine treated rats at different ages

Age	Control animals			Nicotine treated animals			Difference	t
	No.	Mean	S.E.	No.	Mean	S.E.		
New born	---	---	---	---	---	---	---	---
7 days	8	61.77	0.096	8	46.74	0.1245	15.03	95.612 ***
15 days	8	99.4	0.2864	8	97.11	0.1929	2.29	6.6519 ***
21 days	8	130.8	0.1107	8	127.2	0.2099	3.6	15.061 ***
60 days	8	139.9	0.194	8	138.4	0.2002	1.5	5.316 ***

$P < 0.05^*$

$P < 0.01^{**}$

$P < 0.001^{***}$



**Fig. 21:** It shows the relation between the thickness of the molecular layer (micron) of the control and nicotine treated rats.

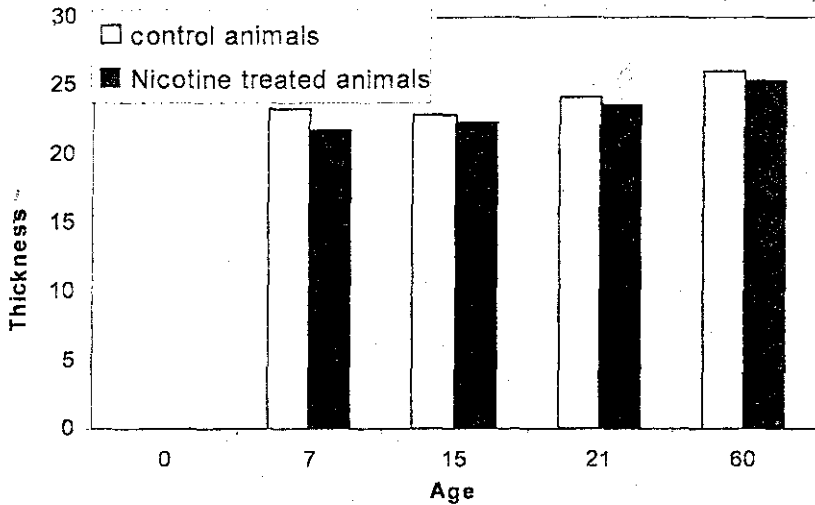
**Table 2:** Thickness of the Purkinje cell layer (micron) of control and nicotine treated rats at different ages

Age	Control animals			Nicotine treated animals			Difference	t
	No.	Mean	S.E.	No.	Mean	S.E.		
New born	---	---	---	---	---	---	---	---
7 days	8	23.35	0.2448	8	21.64	0.01269	1.71	6.9474
15 days	8	22.93	0.271	8	22.35	0.1786	0.58	1.8000
21 days	8	24.21	0.1323	8	23.62	0.1109	0.59	3.3816
60 days	8	26.01	0.2297	8	25.36	0.1158	0.65	2.5268

$P < 0.05^*$

$P < 0.01^{**}$

$P < 0.001^{***}$



**Fig. 22:** It shows the relation between the thickness of purkinje cell layer (micron) of the control and nicotine treated rats.

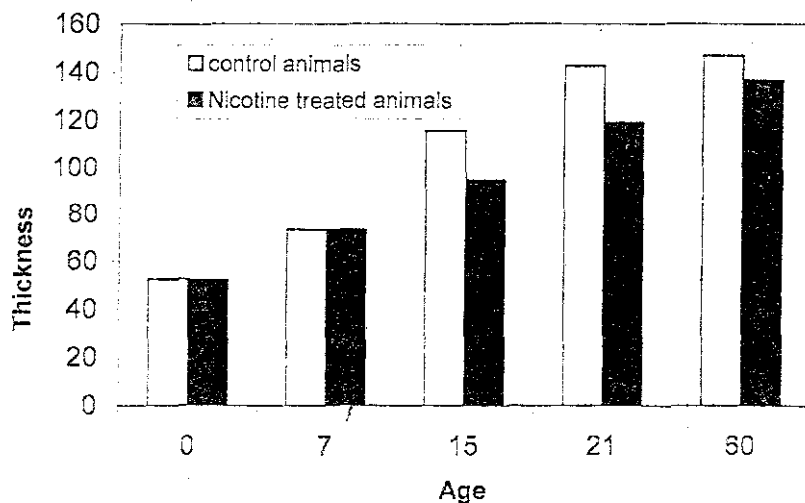
**Table 3:** Thickness of the internal granular layer (micron) of control and nicotine treated rats at different ages

Age	Control animals			Nicotine treated animals			Difference	t
	No.	Mean	S.E.	No.	Mean	S.E.		
New born	8	52.51	0.1111	8	52.1	0.0903	0.31	1.7837
7 days	8	73.28	0.0728	8	73.11	0.0983	0.17	1.3811
15 days	8	115.6	0.0988	8	94.65	0.0441	21.00	194.1 <sub>f</sub> ***
21 days	8	142.7	0.0514	8	119.1	0.1710	23.61	132.34 ***
60 days	8	146.9	0.1614	8	136.7	0.1819	10.2	41.738 ***

$P < 0.05^*$

$P < 0.01^{**}$

$P < 0.001^{***}$



**Fig. 23:** It shows the relation between the thickness of the internal granular layer (micron) of the control and nicotine treated rats.

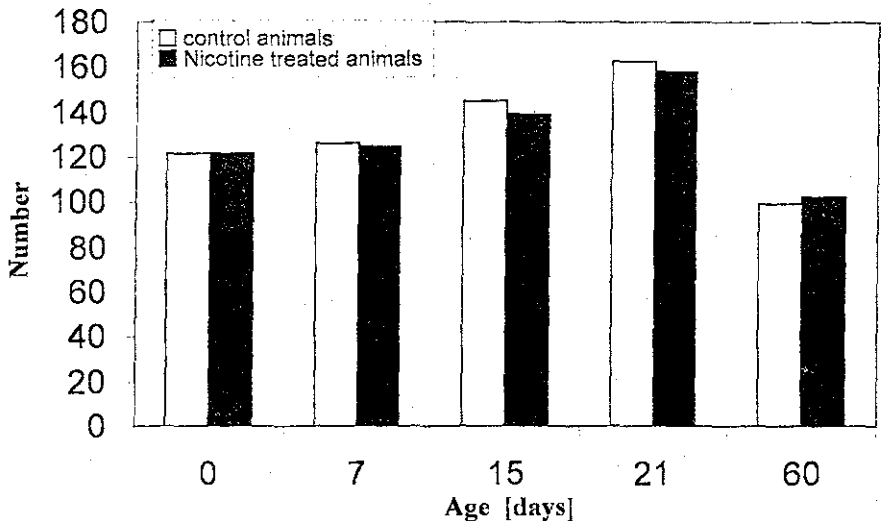
**Table 4:** Number of cells per field (12060 micron<sup>2</sup>) within the internal granular layer of control and nicotine treated rats at different ages

Age	Control animals			Nicotine treated animals			Difference	t
	No.	Mean	S.E.	No.	Mean	S.E.		
New born	8	121.8	0.359	8	121.8	0.2906	0.000	0
7 days	8	125.8	0.4667	8	124.6	0.2667	1.2	2.2325*
15 days	8	145.1	0.2333	8	139.1	0.2333	6.0	7.2294***
21 days	8	162.7	0.2134	8	158.2	0.2	4.5	15.386***
60 days	8	99.7	0.3	8	102.9	0.314	3.2	7.3688***

P < 0.05\*

P < 0.01\*\*

P < 0.001\*\*\*



**Fig. 24:** It shows the relation between the number of cells per field (12060 micron<sup>2</sup>) within the internal granular layer of control and nicotine treated rats.

## DISCUSSION

### **Normal postnatal development of the cerebellar cortex:**

The present results revealed that the cerebellum of rat was immature at the time of birth. In the newly born animals, the cerebellar cortex appeared to be formed of the external granular layer, molecular layer, purkinje cell layer and the internal granular layer from outside inwards. The external granular layer was gradually increased in its width, reached its maximum by the 7<sup>th</sup> postnatal day, then began to decline and completely disappeared by the 21<sup>st</sup> postnatal day. These findings were in agreement with the results of Gaber *et al.* (1985) in rats and Komuro *et al.* (2001) in mice. In human, Abraham *et al.* (2001) found that the external granular layer showed the maximal cellular proliferation rate between the 28<sup>th</sup> and 34<sup>th</sup> gestational week. Then followed by gradual decrease to be completely disappeared by the 11<sup>th</sup> postnatal month.

The results of this work demonstrated that the width of the molecular layer slowly increased at the first postnatal week, followed by rapid increase till the third postnatal week where it reached the adult pattern of development. These results match those of Altman (1972) and Sidman and Rakic (1982) who attributed the increase in the molecular layer thickness to the normal process of migration and differentiation of the granular cells within the external granular layer. The increased width of molecular layer was also explained by Chez (1991) who reported that the axons of the granular cells within the internal granular layer and the migrating cells from the external granular layer played a great role in this process.

The present results demonstrated that the purkinje cell layer was multilayered at birth and attained a typical monocellular layer by the 7<sup>th</sup> postnatal day. Purkinje cells appeared to be crowded at birth and then dispersed after the 7<sup>th</sup> postnatal day to attain its final maturity by the end of the third postnatal week. These findings were in accordance with the results of Mohamed (1984) and Chen *et al.* (1998) in which they described that the rate of neuronal growth of the purkinje cell soma and nucleus showed the greatest increase during the first two postnatal weeks and then followed by gradual increase up to the age of fifth week. Altman and Winfree (1977) attributed the monocellular alignment of purkinje cells to the spread of the transverse components of the (T) shaped axons of the granular cells that pull the dendrites of purkinje cells along a craniocaudal direction. Smeyne *et al.* (1995) reported that the

rapid proliferation of the cells within the external granular layer could induce an adequate expansion of the cerebellar cortex with subsequent cellular dispersion. Goldowitz *et al.* (2000) added that differentiation of purkinje cells depend on some inductive stimuli exerted by the external granular cells as they migrated between the rows of purkinje cells.

The ultrastructural features of the development of the purkinje cells revealed that the nucleus of the neonatal purkinje cell was regular in shape and had homogeneously dispersed chromatin. This uniform dispersion of chromatin was obvious in the succeeding ages. The chromatin dispersion was considered as an early ultrastructural index of neuronal differentiation (Bertossi *et al.*, 1986). The cytoplasm contained mitochondria, ribosomes and rough endoplasmic reticulum. These organelles became more abundant in the cytoplasm with the progress in age. The previous ultrastructural findings were in accordance with the study of Mohamed (1984) in which he described the developmental sequences of purkinje cells. He stated that the purkinje cells became mature at two weeks postnatally.

The present study showed progressive increase in the cellularity of the internal granular layer till reached its maximum by the age of sixty days old. In consistent with the present results, Gabr *et al.* (1985) reported that the internal granular layer appeared as few scattered cells at birth, gradually demarcated at 7<sup>th</sup> –15<sup>th</sup> postnatal day and then increased in its width and cellularity by the 21<sup>st</sup> postnatal day. These findings were explained by the study of Geurts *et al.* (2001) in which they reported that the differentiation of granular cells within the internal granular layer and the functional maturation of these cells depend principally upon the timed cellular migration from the external granular layer towards the deep zone.

### **Effect of nicotine on the postnatal development of the cerebellar cortex**

Normal brain development was a potential target for the perturbation by exposing it to environmental contaminants such as cigarette smoking during the critical period of development. Dobbing and Sands (1973) reported that in human, the period of most rapid brain growth began at the second trimester and reached its peak in the third trimester. While in the rat, occurred during the first two weeks postnatally (Dobbing and Sands, 1979).

In this work, nicotine was administered to the pregnant rats starting from the 14<sup>th</sup> day of gestation till birth and during the whole period of lactation (21<sup>st</sup> postnatal day). The dose of nicotine used in this



study was 6mg/ kg/ day injected subcutaneously in a single dose. The choice of nicotine administration by the 14<sup>th</sup> prenatal day was to avoid its interference with the time of implantation and occurrence of spontaneous abortion (Nabby and Persaud, 1988). Sparks and Pauly (1999) reported that either continuous subcutaneous or intermittent subcutaneous injection was considered the most commonly utilized routes of chronic drug delivery. Furthermore, Murin *et al.* (1987) stated that the oral administration of nicotine was not palatable to rats owing to its nauseating effect and its interference with absorption of some nutrients. The typical administration of 6mg/ kg/ day in rats simulated plasma nicotine level that was found in human heavy smokers (Lichtensteiger *et al.*, 1988).

In this work, the external granular layer of nicotine-treated rat demonstrated the presence of various cavities which might indicate cellular degeneration. Also, it was observed the persistence of the external granular layer after the third postnatal week, while in the control rats it was completely disappeared at the 21<sup>st</sup> postnatal day. The explanation of this event might be due to failure of cellular migration to their final destination in the molecular and internal granular layers at the proper time. Haustein (1999) stated that the impaired migration of granular cells might occur as a result of alteration of glial processes morphology, interference with cell adhesion molecules and distribution of trophic factors that were considered as growth promoting factors. All these mechanisms reflected the neurodevelopmental toxicity of nicotine.

In the present study, it was noticed hypocellularity of the molecular layer more than that of the control group till the end of the second postnatal week. At the 21<sup>st</sup> postnatal day, it seemed to be hypercellular as compared with the control rats. The first observation could be attributed to the decrease in the number of migrating cells towards the internal granular layer. Whereas, the hypercellularity at the 21<sup>st</sup> postnatal day might be due to delayed migration of cells as evidenced by persistence of the external granular layer. These findings were supported by Miao *et al.* (1998) who considered that the second postnatal week was a critical period for the effects of nicotine upon the cerebellar development. This period was corresponding to the timing of receptor control of cell replication, differentiation and maturation. The morphometric findings in this work revealed a highly significant reduction in the thickness of the molecular layer in the nicotine treated rats as compared to the control rats. This could be attributed to defective

dendritic arborization of the internal granular cells with subsequent shortening of their cellular processes that spread through out this layer.

The present research showed delayed differentiation of purkinje cells in the nicotine-treated rats as compared with the control group. This was evidenced by reduced staining affinity, variability in their size, distortion of their shape and alignment in multilaminated layer. One of the most striking finding was the delayed arrangement of purkinje cells in a single layer between the molecular and the internal granular layers. This would be attained by the 15<sup>th</sup> postnatal day in the nicotine treated rats while it was established during the first postnatal week in the normal group. This delay of purkinje cells to reach their final position and attain monolayered pattern could be attributed to the delayed proliferation of the cells of the external granular layer. This resulted in decrease in the number of granular cells and to a significant decrease in the number of their axons that spread as "T" shaped pattern within the molecular layer. These findings were in agreement with Lee *et al.* (2001) who reported that nicotine administration could interfere with the differentiation and maturation of purkinje cells. The mechanism that mediate this developmental defect included physicochemical membrane disruption and gross oxidative damage. Katsetos *et al.* (2001) stated that purkinje cells were vulnerable to hypoxic-ischemic insults of both prenatal and postnatal nicotine administrations.

Electron microscopic examination of the nicotine treated purkinje cells showed multiple invaginations of the nuclear membrane, reduction in the nuclear size with peripheral chromatin condensation, damaged mitochondria, swollen rough endoplasmic reticulum and the presence of many lysosomes as well as several vacuoles in the cytoplasm. These changes indicated not only delayed cellular differentiation but also neuronal degeneration. These observations were in accordance with Cormier *et al.* (2001) who reported that nicotine had strong affinity to the mitochondria and mitochondrial membranes. Thus nicotine could exert profound ultrastructural alteration of mitochondria. It was also supported by the study of Fonnum and Lock (2000) in which they hypothesized that altered cellular energy metabolism was involved in the pathogenesis of nicotine neurotoxicity.

The morphometric findings of this study revealed significant reduction in the thickness of the purkinje cell layer in the nicotine treated rats at all ages as compared with that of the control. These findings were confirmed by Chen and Edwards (2002) who stated that prenatal nicotine exposure deplete purkinje cells number.

In this work, the internal granular layer in the nicotine-treated rats at all ages showed the presence of many cavities. These observations were supported by Kowalska and Marcinkowski (1998) who found that the granular cells were vulnerable to nicotine administration during all phases of cellular replication, differentiation, migration and synaptogenesis. The morphometric findings showed a highly significant reduction in the mean thickness of the internal granular layer of the nicotine treated rats as compared with that of the control rats. This effect was prominent from the 15<sup>th</sup> postnatal day onwards. These results were in accordance with the study of Opanashuk *et al.* (2001) in which they reported that the second postnatal week was the critical period during which nicotine administration could induce permanent defects. Also, the morphometric data obtained in this work showed a significant reduction in the mean number of cells within a defined area in the internal granular layer in the nicotine-treated rats as compared with the control rats with exception of sixty days age that showed the reverse. The reduction in the number of granular cells could be attributed to the delayed migration of the external granular cells into the internal granular layer and secondary to the intrauterine growth inhibitory effect of nicotine (Mallard *et al.*, 2000). The defective dendritic arborization of the cells in the internal granular layer might be considered the cause of the apparently increase in their number in the nicotine treated rats at the age of sixty days as compared with the control rats. These findings were supported by Ernst *et al.* (2001) who observed marked impairment of cellular proliferation and differentiation secondary to prenatal exposure to nicotine. Trask and Kosofsky (2000) added that the neuronal damage caused by fetal nicotine exposure is likely to be irreversible.

It was concluded from this work that nicotine could induce delayed cerebellar development with neuronal damage. So, cigarette smoking was recommended to be prohibited during pregnancy and through the period of lactation.

## REFERENCE

- Abraham, H.; Tornoczky, T.; Kosztolany, G. and Serss, L. (2001):* Cell formation in the cortical layers of the developing human cerebellum. *Int. J. Dev. Neurosci.*, Feb., 19(1): 53-62.
- Altman, J. (1972):* Postnatal development of the cerebellar cortex in the rat. I: the external granular and the transitional molecular layer. *J. Comp. Neurol.*, 145: 353-398.

- Altman, J. and Winfree, A. (1977):* Postnatal development of the cerebellar cortex in the rat. V: Spatial organization of Purkinje cell Perikarya. *J. Comp. Neurol.*, 171: 1-16.
- Anderson, J.E.; Jorenby, D.E.; Scott, W.J. and Fiore, M.C. (2002):* Treating tobacco use and dependence: an evidence based clinical practice guideline for tobacco cessation. *Chest*, Mar. 121 (3): 932-941.
- Bertossi, M.; Roncali, L.; Mancini, L.; Ribatti, A. and Nico, B. (1986):* Process of differentiation of cerebellar Pukinje neurons in the chick embryo. *Anat. Embryol.*, 175(1): 25 – 34.
- Carpenter, M.B. (1991):* The cerebellum. In: *Core Text of neuroanatomy*. Ed. (Malcolm, B. Carpenter, A.B.) 4<sup>th</sup> edition PP 224-249. Williams and Wilkins. Baltimore.
- Chen, W.J.A. and Edwards, R.B. (2002):* Developmental nicotine exposure and cerebellar Purkinje cell loss: A study of temporal vulnerability. Abstract submitted for the annual meeting of teratology society, Scott Sadle, AZ.
- Chen, W.J.A.; Parnell, S.E. and West, J.R. (1998):* Neonatal alcohol and nicotine exposure limits brain growth and depletes cerebellar Purkinje cells. *Alcohol*. 15(1): 33-41.
- Chez, C. (1991):* The cerebellum . In: *Principles of neural science*. eds. (Kandel, E.R., Schwartz, J.H. and Jessell, T.M.). 3<sup>rd</sup> edition, PP 626 – 646. Elseveir, New York.,
- Cormier, A.; Morin, C.; Zini, R.; Tillement, J.P. and Lagrue, G. (2001):* In vitro effects of nicotine on mitochondrial respiration and superoxide anion generation. *Brain Res.*, May 4, 900 (1): 72-79.
- De Zwart, K.M. and Sellman, J.D. (2002):* Public knowledge and attitudes regarding smoking and smoking cessation treatments. *NZ Med*. May 10; 115 (1153): 219-222.
- Dobbing, J. and Sands, J. (1973):* Quantitative growth and development of human brain-*Arch. Dis. Child.*, 48: 757 – 767.
- Dobbing, J. and Sands, J. (1979):* Comparative aspects of the brain growth spurt. *Early Hum. Dev.*, 3: 79-83.
- Ellenhorn, M.J.; Schonwald, S.; Ordog G. and Wasserberger, J. (1997):* Tobacco products, In: *Ellenhorn's Medical Toxicology, Diagnosis and treatment of human posioning* eds (Ellenhorn M.J., Schonwald S, Ordog G., Wasserberger J.) 2<sup>nd</sup> edition, PP 1110 – 1120. Williams & Wilkins Company, Baltimore, Maryland,

- Ernst, M.; Mollchan, E.T. and Robinson, M.L. (2001): Behavioral and neural consequences of prenatal exposure to nicotine. J. Am. Acad. Child Adolesc Psychiatry, Jun; 40 (6): 630-641.*
- Fonnum, F. and Lock, E.A. (2000): Cerebellum as a target for toxic substances. Toxicol. Lett. 15 (112-139): 9-16.*
- Gabr, M.A.; Mohamed, R.S. and Hassanein, K. (1985): Effect of inorganic lead on the postnatal development of the cerebellum. Assiut Medical Journal, 9: 772-793.*
- Geurts, F.J.; Timmermans, J.; Shigemoto, R. and De Shutter, E. (2001): Morphological and neurochemical differentiation of large granular layer interneurons in the adult rat cerebellum. Neuroscience, 104 (2): 499-512.*
- Goldowitz, D.; Hamre, K.M.; Przyborski, S.A. and Ackerman, S.L. (2000): Granule cells and cerebellar boundaries: analysis of unc 5h3 mutant chimeras. J. Neurosc., Jun 1, 20(11): 4129 – 4137.*
- Haustein, K.O. (1999): Cigarette smoking, nicotine and pregnancy. Int. J., Clin. Pharmacol ther., Sep; 31 (9): 417-427.*
- Katsetos, C.D.; Spandou, E.; Legido, A.; Taylor, M.L.; Zanelli, S.A.; De Chadarevian, J.P.; Christakos, S.; Mishra, O.P. and Delivoria – Papadopoulos, M. (2001): Acute hypoxia induced alterations of calbindin – D 28 K immunoreactivity in cerebellar Purkinje cells of the guinea pig fetus at term. J. Neuropathol Exp. Neurol., May; 60(5): 470 – 482.*
- Klonoff-Cohen, H.S; Edelstein, S.L.; Lefkowitz, E.S.; Srinivasan, I.P; Kaegi, D.; Chang, J.C. and Wiley, K.J. (1995): The effect of passive smoking and tobacco exposures through breast milk on sudden infant death syndrome. JAMA, Mar 8, 273(10): 795 – 798.*
- Komuro, H.; Yacubova, E. and Rakic, P. (2001): Mode and tempo of tangential cell migration in the cerebellar external granular layer. J. Neuroscience, Jan. 15; 21(2): 527-540.*
- Kowalski, E. and Marcinkowski, T. (1998): The amount of DNA in cells of the granular layer of the cerebellum and their susceptibility to hypoxia. Med. Hypotheses, Nov., 51(5): 443 – 444.*
- Lee, C.; Kim, D.W.; Jeon, G.S.; Roh, E.J.; Seo, J.H.; Wang, K.C. and Cho, S.S. (2001): Cerebellar alterations induced by chronic hypoxia: an immunohistochemical study using a chick embryonic model. Brain Res., May, 18; 901 (1-2) 271-276.*

- Lichtensteiger, W.; Ribary, U.; Schlumpf, M.; Odermatt, B. and Widmer, H.R. (1988):* Prenatal adverse effects of nicotine on the developing brain. *Prog. Brain Res.*, 73: 137 – 157.
- Mallard, C.; Loeliger, M.; Copolov, D. and Ress, S. (2000):* Reduced number of neurons in the hippocampus and the cerebellum in the postnatal guinea-pig following intrauterine growth retardation. *Neuroscience.*, 100(2): 327-333.
- Miao, H.; Liu, C.; Bishop, K.; Gong, Z.H.; Neordberg, A. and Zhang, X. (1998):* Nicotine exposure during a critical period of development leads to persistent changes in nicotinic acetylcholine receptors of adult rat brain. *J. Neurochem.*, Feb.; 70 (2) 752-762.
- Mohamed, S.A. (1984):* Postnatal development of the rat cerebellar cortex and the Purkinje cell: A light, electron microscopic and morphometric study. Ph. D. Dissertation, University of Manitoba.
- Murin, L.C.; Ferrer, J.R.; Zeng, W.Y. and Haley, N.J. (1987):* Nicotine administration to rats: methodological considerations. *Life. Sci.*, 40 (17): 1699-1708.
- Nabby, D.W. and Persaud, T.V.N. (1988):* Rat embryogenesis following exposure to alcohol and nicotine. *Act: Ant.*, 131: 122 – 126.
- Opanashuk, L.A.; Pauly, J.R. and Hauser, K.F. (2001):* Effect of nicotine on cerebellar granule neuron development. *Eur. J. Neurosci.*, 13(1): 48-56.
- Sastry, B.V.R. and Chance, M.B. (1994):* The human placental transfer of nicotine and its conversion to cotinine. *Placenta*, 15, 56-61.
- Sidman, R.L and Rakic, P. (1982):* Development of the cerebellum. In: *Histology and Histopathology of the Nervous system* eds (Haymaker W., Aams RD.). Springfield, Thomas. 94-110.
- Slotkin, T.A.; Trauth, J.A.; Mc Cook, E.C. and Seidler, F.J. (2000):* Modeling adolescent nicotine exposure: effects on cholinergic system in rat brain regions. *Brain Res.*, Aug. 4; 873 (1): 18-25.
- Smeyne, R.J.; Chu, T.; Lewin, A.; Bian, F.; Crisman, S.S.; Kunsch, C.; Lira, S.A. and Oberdick, J. (1995):* Local control of granule cell generation by cerebellar Purkinje cells. *Moll Cell Neurosci.*, 6: 230 – 251.
- Sparks, J.A. and Pauly J.R. (1999):* Effects of continuous oral nicotine administration on brain nicotinic receptors and responsiveness to nicotine in mice. *Psychopharmacology*, 141(2): 145 – 153.
- Trask, C.L. and Kosofsky, B.E. (2000):* Developmental considerations of neurotoxic exposures. *Neurol. Clin.*, Aug., 18(3): 541-562.