

## **TRIAL FOR ISOLATION AND CHARACTERIZATION OF POXVIRUS FROM TURKEYS**

**NAKHLA OLFAT E. AND A.M. DAUD**

*Veterinary Serum and Vaccine Research Institute , Agricultural Research Center,  
Ministry of Agriculture – Dokki-Giza-Egypt.*

(Manuscript received 17 Decembre 2003)

---

### ***Abstract***

Turkeys showing lesions of pox infection were subjected to post-mortem examination and samples were collected for isolation of the causative agent. An isolate was successfully recovered from the cutaneous pox lesions in embryonated chicken eggs .The isolate was tested in comparison with virulent fowl poxvirus for pathogenicity in susceptible birds (Turkeys, fowls and ducks).

It was found that it produced pock lesions on the chorioallantoic membrane of ECE and specific takes at the site of inoculation by the wing-web method in fowls and ducks , and generalized proliferative nodules on the unfeathered parts of inoculated turkeys . On the other hand , inoculation of fowl poxvirus in the same birds ( turkeys , fowls and ducks ) induced generalized pox lesions which appeared on turkeys and fowls, while the ducks did not produce any reaction. These results confirmed the identity of the isolate as turkey poxvirus. Further confirmation that the isolate belongs to avian poxviruses was achieved by histopathological examination of samples collected from organs of experimentally infected turkeys and detection of the virus antigen in the organs of experimentally infected turkeys by the indirect fluorescent antibody technique.

### **INTRODUCTION**

Pox viruses are among the largest and most complex viruses of all animals and birds. Avian pox viruses are not known to infect mammals; they have oncogenic properties and can induce neoplastic changes in the lung or skin of infected birds (Buller and Palumbo,1991 and Branson and Kip,1995).

Morbidity rate of avian pox varies from few birds being infected to involvement of the entire flock if a virulent virus is present and no control measures are taken. Birds affected with the cutaneous form of the disease are more likely to recover than those with the diphtheric form involving the respiratory tract (Reed and Fatunmbi, 1994, and Tripathy and Reed,1997).

In turkeys, pox infections are important because the infection can occur in susceptible birds at any age (Tripathy and Reed,1997). In addition, marked retardation of growth development of birds is considered of greater economic importance . It is also characterized by blindness due to cutaneous eye lesions and starvation which causes great losses. The course of the disease in turkey flocks may be 2-3 weeks, and severe outbreaks often last 6,7 or even 8 weeks with high mortalities reaching 50% of the infected birds (Winterfield *et al.*, 1985).

The main goal of the present study is to isolate and identify a local strain of turkey poxvirus as a primary step for preparing a specific vaccine against this important disease.

## **MATERIALS AND METHODS**

### **1.Samples**

Nodular lesions were collected from naturally infected turkeys. The samples are ground with sterile sand by using sterile mortar and pestle. Hank's balanced salt solution was added to make a 10% suspension. The suspension was centrifuged for 10 minutes at 3000 rpm . Antibiotics (penicillin and streptomycin ) were added to the supernatant to give final concentrations of 1000 IU/ml and 1mg/ml, respectively, and the suspension was held at room temperature for 1 hour before inoculation (Boosinger *et al.*, 1982) .

### **2.SPF eggs**

Nine to 12 – day –old specific pathogen free (SPF) embryonated chicken eggs were used for isolation and titration of the causative virus.

### **3.Susceptible birds**

Fifteen Turkeys , 15 fowls and 15 ducks , 30-45 days old , were inoculated for determining the pathogenicity of the isolated virus .

#### **4. Virulent fowl poxvirus**

It was obtained from the Pox Dept., Veterinary Serum and Vaccine Research Institute (VSVRI) , Abbasia, Cairo , Egypt . It was used for the pathogenicity test . Its predetermined titer was  $10^{7.2}$  EID<sub>50</sub>/ml.

#### **5. Reagents for the indirect fluorescent antibody technique**

a. anti-chicken IgG ( Whole Molecule) FITC conjugate product No. F4137 was obtained from Sigma Chemical Co.

b. Fowl pox antiserum was obtained from the Pox Dept., Veterinary Serum and Vaccine Research Institute (VSVRI), Abbasia, Cairo, Egypt.

#### **6. Virus isolation in embryonated chicken eggs (ECE)**

Fifteen embryonated chicken eggs were used . Ten eggs were inoculated with the prepared lesion clear fluid as 0.2ml/egg on the chorioallantoic membrane according to Cunningham (1973) for the detection of specific pock lesions 5-7 days post-inoculation in addition to five non-inoculated controls. This procedure was applied for two passages.

#### **7. Pathogenicity test in susceptible birds**

Fifteen susceptible birds from each of three different avian species (fowls, turkeys and ducks), each was divided into 3 equal groups of 5 birds each. The first group was inoculated by the isolated virus from infected turkeys, the second group was inoculated with virulent fowl poxvirus, while, the third group was kept as non-inoculated control. The inoculation was done by wing-web method.

All bird groups were kept separated under observation for the development of cutaneous lesion within 7-14 days post-inoculation.

#### **8. Titration of the turkey isolate on ECE**

Fifty SPF embryonated chicken eggs were used for titration of the obtained isolate according to Cunningham (1973), and the results were calculated according to Reed and Muench (1938).

#### **9. Histopathological examination**

Tissue specimens were collected from skin 21 days post-infection and from lung, heart and spleen 7-10 days post-infection of the birds in 10% neutral formalin for histopathological examination to reveal cytoplasmic inclusion bodies according to Humason (1979).

#### **10. Indirect Fluorescent antibody technique (IFAT)**

It was done according to the method described by Riggs( 1989).

## RESULTS

### 1. Virus isolation

Inoculation of the prepared lesion extract in ECE revealed compact, proliferative pock lesions on the chorioallantoic membrane that may be focal or diffuse.

### 2. Pathogenicity of the turkey isolate for susceptible bird species

When the isolate was inoculated in susceptible birds, the results were interpreted after Tripathy and Reed (1997) and expressed in Table 1.

Table 1. Pathogenicity of turkey isolate and virulent fowl poxvirus for three different poultry species .

Species \ Pathogenicity	Turkey isolate	Virulent fowl poxvirus	Non-inoculated controls
Turkey	G	G	-
Fowl	L	G	-
Duck	L	-	-

G : Generalized cutaneous lesions on the comb, wattles, and the unfeathered parts of the bird body within 7-10 days post- inoculation.

L : Local takes of pox infection appearing at the site of inoculation.

= Negative reaction .

### 3. Titration of turkey isolate

The titre of the obtained isolate on the chorioallantoic membranc of SPF embryonated chicken eggs was  $10^{6.1}$  EID<sub>50</sub>/ml.

### 4. Histopathological examination

The histopathological features observed in the infected organs are presented in photos 1,2 and 3.

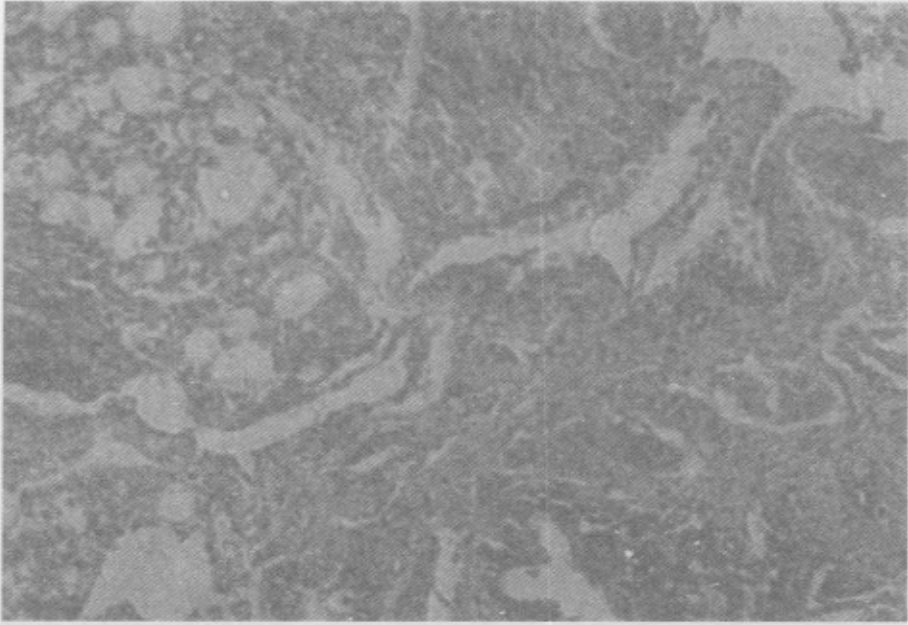


Photo 1: Section of lung from experimentally infected turkey .

The alveoli showing hyperplastic proliferation of epithelial lining and diffuse lymphocytic aggregations. Oval eosinophilic intracytoplasmic inclusion bodies appear in some infected cells. H&E(X 250)




Photo 2: Section of spleen from experimentally infected turkey.

Spleen showing moderate depletion of white pulp with some necrotic changes. H&E (X 125)

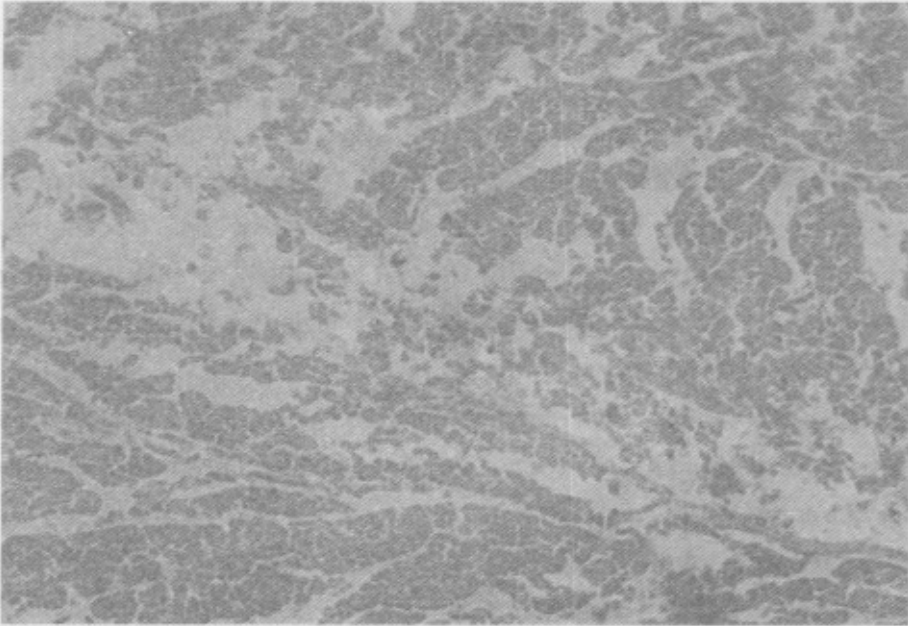


Photo 3: Section of heart from infected turkey.

It showed myocardial degeneration with extensive area of Zenker`s necrosis with infiltration of lymphocytes, plasma cells and macrophages. H&E (X 125)

#### 4. Indirect fluorescent antibody results (IFAT)

Detection of the replicated virus in infected organs ( skin, lung, heart and spleen) appeared as granular greenish yellow fluorescence in the cytoplasm close to the nucleus of the infected cells as shown in photo (4) and the negative control one in Photo (5).

## DISCUSSION

Turkey pox virus is a member of the genus Avipox virus of the Poxviridae family (Tripathy *et al.*, 1981 and Esposito *et al.*,1991). Turkey pox infection appeared to be of great economic importance. Up till now, turkey pox is controlled by vaccination with fowl pox vaccine. In the present study, a trial was made for isolation of the causative agent of turkey pox infection as a step on the way of preparation of a specific vaccine.

Collected skin lesions from naturally infected turkeys yielded after grinding, suspension and centrifugation a clear fluid prepared as previously mentioned by Boosinger *et al.* (1982).

The fluid was used for isolation of the causative agent in ECE and the pathogenicity test in susceptible birds. In ECE, the isolate was inoculated for two passages where the virus produced the typical lesions of pox infection, characterized by focal or diffuse proliferative pox lesions on the chorioallantoic membrane of the inoculated ECE in comparison with the control non-inoculated eggs (Moss, 1990).

Pathogenicity of the virus was also tested in three different bird species (turkey, fowl and duck) ; each species was infected by the isolate and virulent fowl poxvirus through the wing-web method according to Tripathy and Reed (1997).

The results presented in Table 1 showed that turkey and fowl acquired both infections of turkey pox and fowl pox, while, the duck was the only species which produced local nodules on the unfeathered skin when inoculated with turkey pox isolate and gave negative results when inoculated with fowl poxvirus. These results confirm that the isolated virus was turkey poxvirus and are in agreement with those reported previously (Gelenczei and Lasher, 1968 and Tripathy and Cunningham,1984). The susceptibility of ducks to turkey poxvirus and their resistance to fowl poxvirus has been suggested for differentiation between these two closely related viruses.(Tripathy and Reed, 1997).



Further confirmation of the identity of the isolate was achieved by using IFAT on thin sections of skin lesions collected either from the experimentally infected turkeys or ducks, which revealed the presence of granular greenish yellow fluorescence in the cytoplasm of infected cells that was not seen in the control non-infected ducks or turkeys.

The isolate proved by titration in ECE to have a titre of  $10^{6.1}$  EID<sub>50</sub>/ml.

Histopathological examination of the lung from experimentally infected turkeys showed hyperplastic proliferation of epithelial cells with the presence of intracytoplasmic inclusion bodies characteristic of pox infection. Moderate depletion of the white pulp and necrotic changes were seen in the spleen, whereas the heart revealed myocardial degenerative and necrotic changes associated with infiltration with inflammatory cells.

The results obtained from this study revealed the successful isolation of turkey poxvirus from naturally infected turkeys, which could be used for future trials to prepare a specific turkey pox vaccine.

## REFERENCES

1. Boosinger, T.R., R.W., Winterfield, D.S., Feldman, and A.S. Dhillon. 1982. Psittacine poxvirus : Virus isolation and identification, transmission and cross-challenge studies in parrots and chickens. *Avian Dis.*,26:437- 444.
2. Branson,W.R, and C. Kip. 1995. Avian viruses: Functions and control. Poxviridae. Chapter 10: 285-311. Wingers Publishing, Inc., Lake Worth, Florida.
3. Buller, R.M.L. and G.J. Palumbo. 1991. Poxvirus pathogenesis *Microbiol. Rev.*, 55:80-122.
4. Cunningham, C.H. 1973. A Laboratory Guide in Virology. 7<sup>th</sup> ed. Burgess, Minneapolis, MN.
5. Esposito, J. J., D., Daxby, D., Black, S., Dales, G., Darai, K., Dumbell, R., Granados, W.K., Joklik, G., McFadden, B., Moss, R., Moyer, D., Pickup, A., Robinson, H., Rouhandeh, and D. Tripathy. 1991. Family Poxviridae. In R.I.B. Francki; C.M. Fanquet; D.L. Knudson and F. Brown (eds). Classification and nomenclature of viruses. Fifth report of the International Committee on Taxonomy of Viruses. Springer-Verlag Wein, New York, NY; pp.91-102.
6. Gelenczei, E.F. and H.N. Lasher. 1968. Comparative studies of cell-culture propagated avian poxviruses in chickens and turkeys. *Avian Dis.*,12:142-150.
7. Humason, L.D. 1979. Animal tissue technique. 4th Ed.,W.II.Freeman and Co., San Francisco.
8. Moss,B. 1990. poxviridae and their replication. In B.N.Fields, D.M.Knipe, R.M. Chanock; J.L. Melnick; B. Roizman; and R.E. Shope (eds).Virology, 2nd Ed. Raven Pross,New york, pp.2079-2111.

9. Reed, L.J., and H. Muench. 1938. A simple method of estimating fifty percent end points. *Am.J.Hyg.*, 27:493.
10. Reed, W.M., and O.O. Fatunmbi. 1994. Characterization and immunogenicity of "variant " strains of avian poxviruses. *Proc. 131<sup>st</sup> Ann. Meet. Am. Vet. Med. Assoc.*, p.124.
11. Riggs, J.L. 1989. Diagnostic Procedures for viral, Rickettsial and Chlamydial infections. 6<sup>th</sup> ed. American Public Health Association Inc. Washington, D.C. pp.123-134.
12. Tripathy, D.N., and C.H. Cunningham. 1984 Avian pox. In: M.S.Hofstad; H.J. Barnes, B.W; Calnek; W.M. Reid; and H.W. Yoder Jr. (eds). *Diseases of Poultry*, 8<sup>th</sup> ed. Iowa State University Press. Ames, IA, pp.524-534.
13. Tripathy, D.N., and W.M. Reed. 1997. Pox : Diseases of poultry, 10<sup>th</sup> ed. pp.643-659. Calnek, B.W.; Barnes, H.J.; Charles, W.B.; Larry, R.M.; and Saif, Y.M. (eds.), Iowa State Univ. Press. Ames, IA 50014.
14. Tripathy, D.N., L.E., Hanson, and R.A. Crandell. 1981. Pox viruses of Veterinary Importance; diagnosis of infections. Chapter 6 . In E. Kurstak and C. Kurstak (eds). *Comparative diagnosis of viral diseases*, Vol. III. Academic Press, New York, NY, pp. 267-346.
15. Winterfield, R.W., W.M., Reed, and H.L. Thacker. 1985. Infection and immunity with a virus isolate from turkeys. *Poult. Sci.*, 64:2076-2080.

## محاولة لعزل وتوصيف فيروس الجدري من الرومي

ألفت اسطفانوس نخلة ، أحمد محمود داود

معهد بحوث الأمصال واللقاحات البيطرية - مركز البحوث الزراعية - وزارة الزراعة - الدقي - جيزة - مصر .

تم تشريح وجمع عينات من فراخ رومي ظهرت عليها أعراض الجدري، وذلك لعزل الفيروس المسبب وتحديد نوعه وقدرته على إحداث المرض في ثلاثة أنواع مختلفة من الطيور الداجنة (الرومي والدجاج والبط) مقارنة بفيروس جدري الطيور الضاري.

وقد تم عزل الفيروس المسبب للمرض من مستخلص للبثرات الجلدية التي جمعت من الطيور المريضة بالحقن في البيض المخصب على الغشاء اللانتويكي للبيض. كما ظهرت إصابات الجدري على شكل بثرة في مكان الحقن بالمستخلص بطريقة وخز الغشاء الجلدي للجناح في كل من الدجاج والبط، بينما ظهرت بثرات منتشرة في جميع الأماكن الخالية من الريش في الرومي المحقون.

ومن ناحية أخرى أدى حقن فيروس جدري الدجاج الضاري في نفس أنواع الطيور المختبرة (الرومي، الدجاج والبط) إلى ظهور بثرات منتشرة في الأجزاء الخالية من الريش في الرومي والدجاج بينما لم تظهر أية آثار لبثرات على البط المحقون بنفس الفيروس. وقد أكدت هذه النتائج أن الفيروس المعزول هو إحدى السلالات لفيروس جدري الرومي.

كما أشارت نتائج الفحص الباثولوجي لعينات الأعضاء المجمعة من الرومي المصابة بالجدري بعد العدوى الاصطناعية إلى وجود أجسام احتوائية مميزة داخل سيتوبلازم الخلايا المصابة، كما أمكن الكشف عن وجود الفيروس في هذه الخلايا عن طريق الاختبار الفلورسنتي المناعي غير المباشر مما يؤكد على انتماء الفيروس المعزول إلى مجموعة جدري الطيور .