

Animal Health Research Institute, Dokki, Giza

ROTA VIRUS IN LAYING HENS – CASE REPORT

(With 4 Figures)

By

AHLAM A. FARGHLY and LAILA A. TANTAWY

(Received at 24/3/2005)

فيروس الروتا في الدجاج البياض

أحلام عبد الحميد فرغلي ، ليلي عبد الغنى طنطاوى

تم عزل عترة واحدة من فيروس الروتا. تم العزل في بيض خالي من الأمراض وخلايا السزرع النسيجي MA104. ظهر احتقان شديد في الجنين واستدارة في خلايا التشريح النسيجي وتم فحصها بالميكروسكوب الفلورسنت وأظهرت ايجابية. تم التأكد من الفيروس بالميكروسكوب الألكتروني. الحالات المعزول فيها الفيروس كانت مصابة بإسهال شديد وانخفاض في معدل البيض وبالفحص النسيجي لخلايا الأمعاء ظهر تأكل وتكسر في جدار الخلايا ووجود خلايا وحيدة الخلية في جدار الأمعاء.

SUMMARY

An isolate of rotavirus was recovered from laying hens showing severe diarrhea and drop in egg production. It was isolated in MA104 tissue culture and specific-pathogen free eggs by yolk sac inoculation. It showed rounding in tissue culture and green chiny fluorescence and its identity was confirmed by electron microscopy. Histopathological examination showed desquamation and sloughing of the intestinal mucosa as well as mononuclear cell infiltration of the lamina propria.

Key words: *Rota virus, laying hens.*

INTRODUCTION

Rotaviruses are now established as a major cause of enteritis and diarrhea in a wide range of mammalian species including humans (Tziportl, 1985).

Rotaviruses infection in avian species was first reported in 1977 by Bergeland *et al.* who found particles morphologically indistinguishable from rotavirus in intestinal contents of turkey poults with watery dropping and increased mortality. Since then, it has become

apparent that rotaviruses infect many species of domestic birds and love birds (Gough *et al.*, 1988).

As in mammals, rotavirus infection in avian species is frequently associated with outbreaks of diarrhea. Rotaviruses from turkeys and pheasants can infect chickens (Yason and Schat, 1986; Wani *et al.*, 2003). Rotavirus group A cause an infection in birds, gene sequence and other data provide convincing evidence that this virus originated from pigeons (Brisaw *et al.*, 1992).

Rota virus are classified as genus in the family *Reoviridae*, 70 – 75 nm in diameter double standard RNA genome consisting of 11 segments.

Isolation of rotavirus from faeces or intestinal content of chickens, pheasants, ducks and pigeons have been made in primary chick kidney and chick embryo liver culture (Andral *et al.*, 1985; Brisaw *et al.*, 1992). Although chicks rotavirus grow better in (MA 104) (Myers and Shoat, 1989).

In this study intestinal contents from ileum showed orange diarrhea and drop in egg production were taken for trial of isolation.

MATERIALS and METHODS

A Layer farm in Alexandria “Smoha” 9-10 month old showed drop in egg production 60-70% and orange soft diarrhea. Intestinal contents from ileum treated with antibiotic and centrifugated at 3000 rpm for 20 minutes. The supernatant fluid was used for virus isolation in tissue culture (MA 104) and pathogen free egg (Yolk sac), three passages were done. Trypsin (5 microns per ml) was added to media used for cell culture.

Electron microscopy:

Viral suspension from the third passage (MA 104) was centrifuged and supernatant stained with negative stain and examined by electron microscope cover slips emerged in the 3rd tissue culture suspension stain for fluorescent and examined by indirect method (positive serum from D. Hussein A.H.) Faculty of Veterinary Medicine, Cairo University, Virological Section.

Intestinal part stained by haematoxylin and eosin and examined by light microscope.

RESULTS

Tissue culture showed rounding after 24 hours in all of the three passage. Inoculated egg embryo were severely congested. Electron microscope showed virus particle (Fig. 1). Fluorescent microscope showed green fluorescent colouration (Fig. 2).

Histopathological lesions:

The lesion of the intestinal mucosa comprised necrosis of the epithelium sometimes atrophy, desquamation and sloughing of the villi. Shortening of villi could be seen (Fig. 3).

The lamina propria infiltrated with mononuclear cells (Fig. 4) and serosal layer showed thickening and vacuolation.

DISCUSSION

Virus isolated from laying hens in MA104 and this agree with Myer and Schat (1989) and serial propagation in all culture required treatment with trypsin (Kapikin and Canock, 1996). The isolates showed cytopathic effect from the first passage which disagree with McNutly *et al.* (1981) who need 19 passage to show positive result rest in chick liver cell. From this work we concluded that MA104 is faster cell for isolation from hens.

A rotavirus was lethal for chick embryo following yolk sac (6 – 8 day old) inoculation result in death after 3 – 5 days and this agree with Gouph *et al.* (1988).

The disease was characterized by diarrhea, drop in egg production in laying hens and 92 weeks (Jones *et al.*, 1979).

Virus was detected by electron photograph such as McNutly *et al.* (1984).

Histopathological intestinal mucosa comprised necrosis of the epithelium and atrophy and this agree with Meuleman *et al.* (1985), lamina propria infiltrated with mononuclear cells as reported by Yason *et al.* (1987).

ACKNOWLEDGEMENT

We are grateful to Dr. A. Agag and Dr. O. Hussein A.H. for their help.

REFERENCES

- Andral, B.D.; Toquih, R.L.; Hardon, A.; Jestin, M.H.; Metz and Rose, R. (1985):* Le diarehea du dindemant au bian des recherches virales effectures (rotavirus, reo virus, denovirus pseudo picornavirus). *Avian Path.* 14: 147 – 162
- Bergeland, M.E.; Mc Adaragh, J.P. and Stotz, I. (1977):* Rotaviral enteritis in turkey poults. *Proc. 26th West. Poult. Dis. Conf.*, 129 – 130.
- Brisaw, I.T.; Nakagoni, O.; Minamoto, N. and Eichhorn, W. (1992):* Rotavirus 993 / 83 isolated from culture can closely resemble an avian rotavirus. *J. Gen. Virol.*, 37: 1873-1875.
- Gouph, R.E.; Collins, M.S.; Wood, G.W. and Lister, S.A. (1988):* Isolation of a chicken embryo lethal rotavirus from a love bird (*Aga pornis* species). *Vet. Rec.* 122: 363-364.
- Jones, R.C.; Hughes, C.S. and Henry, R. (1979):* Rotavirus infection in commercial laying hens. *Vet. Rec.*, 104: 22.
- Kapikin, A.Z. and Chanock, R.M. (1996):* Rotavirus in D.N. Fields. D.M. Kripe; P.M. Howley; R.M. Chanock; J.L. Melnick; T.P. Monath; B. Roizman and S.E. Stranscend, *Field Virology*. Third Edition, Vol. 2. Lippincott, Raven, Philadelphia, 1687-1708.
- McNulty, M.S.; Allan, C.M.; Tod, J.B.; Mc Ferrand and McCracken, R.M. (1981):* Isolation from chicken of a Rotavirus lacking the Rota virus group antigen. *J. Gen. Virol.*, 55: 405-417.
- McNulty, M.S.; Todd, D.; Alan, G.M.; Mcferran, J.B. and Agerente, J. (1984):* Epidemiology of rotavirus infection in birds chicken recognition of four subgroups. *Arch. Virol.*, 81: 113-121.
- Meulemans, G.; Peeters, J.E. and Halen, P. (1985):* Experimental infection of broiler chickens with rotavirus. *Br. Vet. J.*, 141: 69-73.
- Myers, T.J. and Schat, K.A. (1989):* Propagation of avian rotavirus in primary chicken kidney and MA 104 cell culture. *Avian Dis.*, 3: 578-581.
- Tziport, S. (1985):* The relative importance of enteric pathogenic affecting neonates of domestic mammals. *Adv. Vet. Sci. Comp. Med.*, 29: 103-106.
- Wani, S.A.; Shat, M.A.; Ishad, S.M.; Ashraf, M.A.; Puch, A.S. and Hag, M. (2003):* Detection of mammalian-like group A rotavirus in diarrhea chicken. *Vet. Microbiol.*, 1 (13): 42-49.

- Yason, C.V. and Schat, K.A. (1986): Pathogenesis of Rotavirus infection in turnkeys poults. Avian Pathol., 15: 421-435.*
- Yason, C.V. and Schat, K.A. (1987): Experimental infection of specific pathogen free chickens with avian rotavirus. Avian Dis., 551-556.*
- Yason, C.V.; Summers, D.A. and Schat, K.A. (1987): Pathogenesis of rotavirus infection in various age groups of chickens and Turkeys: Pathology. Am. J. Vet. Res., 927-938.*

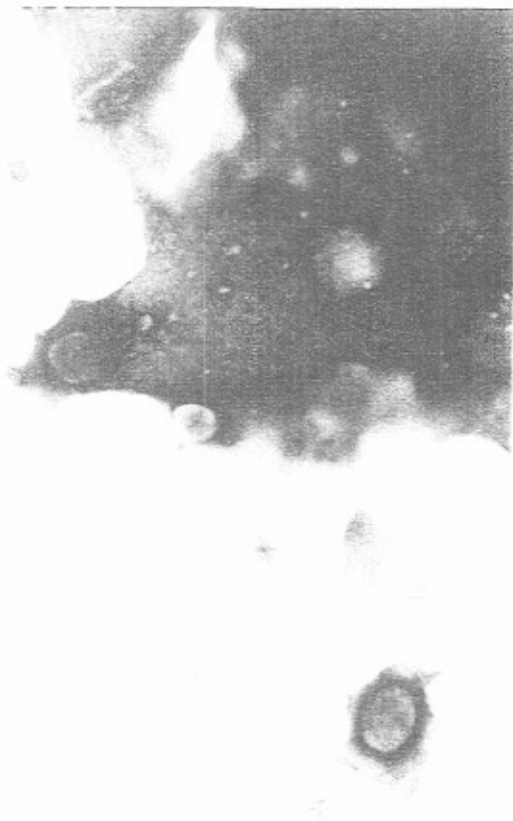

Fig. 1: Virus particle by electron microscope.

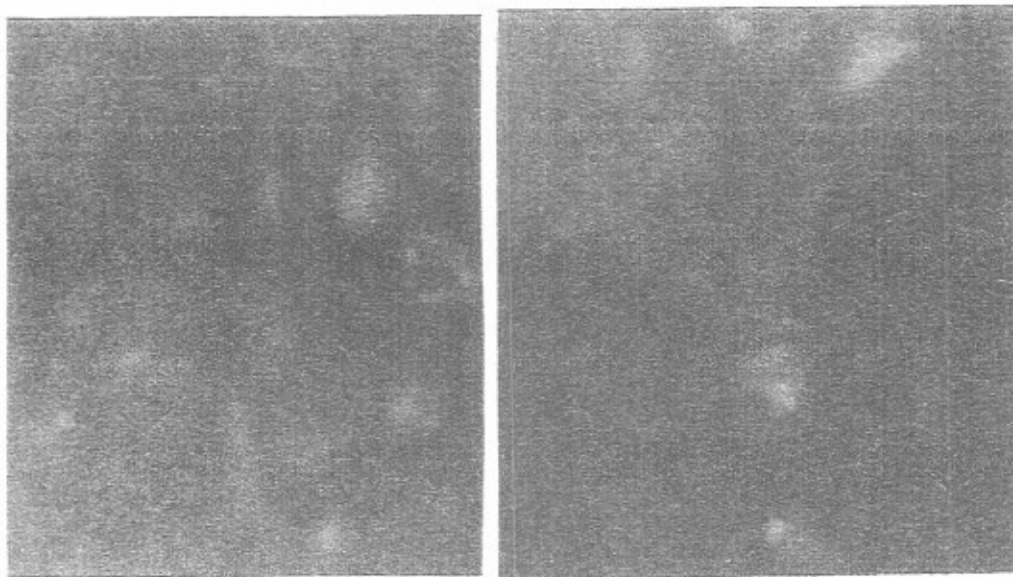


Fig. 2: Tissue culture showing positive fluorescent.

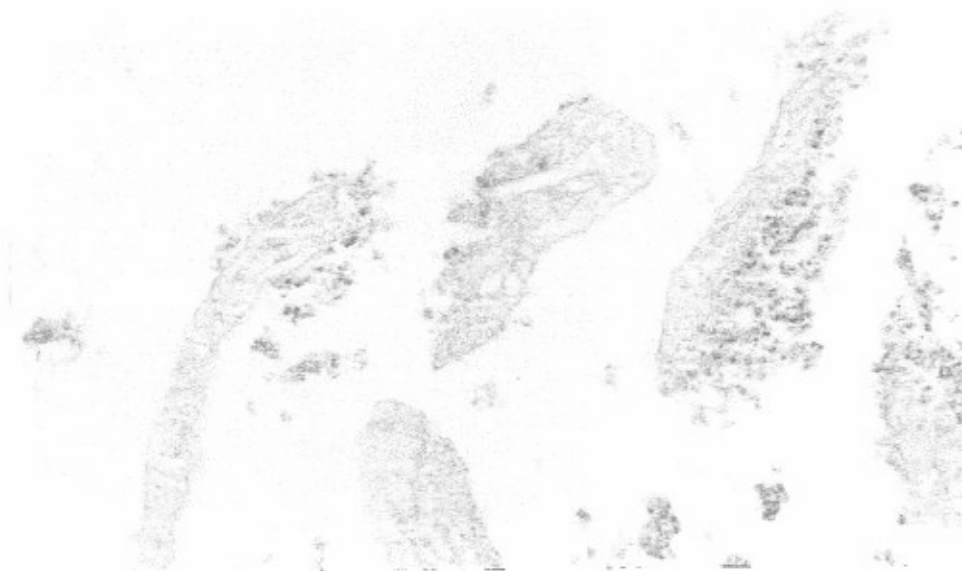


Fig. 3: Lumen of intestine showing sloughing and desquamation necrotic intestinal mucous (H and E X 100).

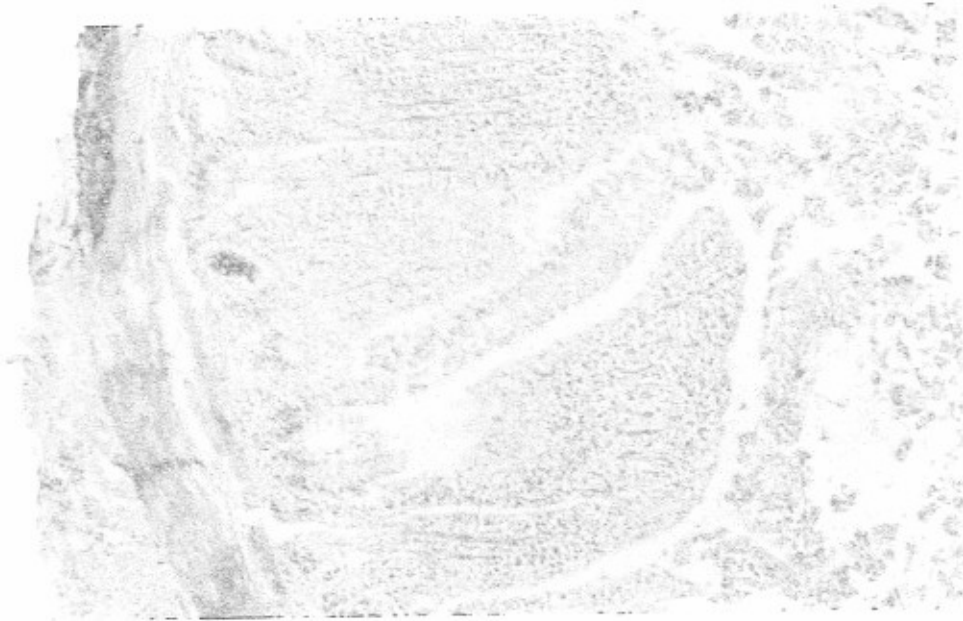


Fig. 4: Lamina propria infiltrated with mononuclear cell (H and E X 100).