

Animal Health Research Institute,  
Assiut Laboratory.

## SOME STUDIES ON LISTERIA SPECIES ISOLATED FROM CHICKEN FLOCKS IN ASSIUT PROVINCE.

(With 4 Tables and 7 Figures)

By

**FATMA A. MOUSTAFA and AZHAR M. ABDEL AZIZ**

(Received at 30/3/2005)

بعض الدراسات عن ميكروبات الليستيريا المعزولة من قطعان الدواجن  
في محافظة أسيوط

فاطمة عبد المجيد مصطفى ، أزهار محمد عبد العزيز

تعتبر ميكروبات الليستيريا من الميكروبات واسعة الإنتشار في الطبيعة ومنها ميكروب الليستيريا مونوسيتوجينس الذي يسبب الإصابة بمرض الليستيريوزيس، ومن هنا كان الاهتمام بالبحث لمعرفة مدى تواجده في بعض مزارع الدواجن بمحافظة أسيوط. وقد تم العزل من أعمار تتراوح من ١-٢٤ أسبوع. ومن عينات أرتبطت بتاريخ مرض معين. وقد أسفرت النتائج عن تواجد الليستيريا بنسبة ١٩,٢% من العينات المفحوصة أما بالنسبة لميكروب الليستيريا مونوسيتوجينس فقد تم عزل ١٤ عترة بنسبة ٦٠,٩% أنطبقت عليها صفات الميكروب المورفولوجية والبيوكيميائية وتم تصنيفه إلى نوع سرولوجي رقم O<sub>1</sub>. تم إجراء العدوى الصناعية بحقن الميكروب في أجنة بيض الدجاج عن طريق الغشاء الكوريوالأنفوس، هذا وقد تم تسجيل الاعراض والافات التشريحية وتم كذلك مناقشتها. كذلك تم إجراء العدوى الصناعية في كتاكيت عمر ٦ أسابيع هذا وقد تم ملاحظة الاعراض وتسجيل الصفات التشريحية ومناقشتها، بأجراء اختبار الحساسية لميكروب الليستيريا مونوسيتوجينس تبين ان الميكروب شديد الحساسية لكل من الأموكساسلين والكلورمفينكول والأميسيلين وحمض النلكسك بينما كان الميكروب مقاوم لكل من سلغات الكولستين وحمض الأوكسالنيك.

### SUMMARY

Listeria infections caused by microorganisms of the genus Listeria, occur worldwide and in a variety of animals, birds and man. In this study isolation of Listeria was done from different ages (1-24- week old) from freshly dead chickens (baby, chick, broilers and layers). Double sample were taken from each bird, one from intestine and the other was pooled samples include liver, heart and spleen. 23 (19.2%) strains of Listeria spp. were obtained, from which 14 strains were identified as *L.*

*monocytogenes* at a percentage of 60.9%. The experimental infection of *L. monocytogenes* in chicken embryo was carried out by chorioallantoic membrane (CAM) route. Intraperitoneal infection of 6 weeks old chicken revealed 25% of birds died during observation period. Signs and postmortem changes were observed and discussed. Contact birds showed depression and inappetance. The in-vitro susceptibility of *L. monocytogenes* isolates to a variety of antibiotics revealed that isolates were highly sensitive to Amoxycillin, Chloramphenicol, Ampicillin, and Nalidixic acid while they were resistant to Colistin sulphate and oxolinic acid.

**Key words:** *Listeria species, chicken*

## INTRODUCTION

*Listeria* has attracted the wide attention of microbiologists in recent years. *Listeria* species are widely spread environmental microorganisms found in soil, water, vegetation and many animal species (Best *et al.*, 1990). Genus *Listeria* is composed of many species of which *Listeria monocytogenes*, *L. innocua*, *L. welshimeri*, *L. seeligeri*, *L. inovanovi* and *L. denitrificans* have been identified (Rocourt and Cossart 1997).

Listeriosis is caused by *L. monocytogenes* which considered the major pathogenic species that under certain conditions can cause serious or even fatal disease in man, animals and fowls (Thamm, 1962). Mortality rate vary from a few to as much as 40%, sudden death may occur in adult chickens while young birds had slow wasting before death (Allen Packer, 1975; Dalton *et al.*, 2004).

Listeriosis in fowl is seen as torticollis, drowsiness and septicemic condition with focal necrosis of the liver, necrosis of the myocardium, pericarditis and occasionally encephalitis (Gross, 1984 and Kurazono *et al.*, 2003).

*L. monocytogenes* was isolated from various poultry species at different incidences. Gitter (1976) isolated 10 isolates of *L. monocytogenes* out of 135 swabs from 68 birds included 62 chickens. Cooper (1989) isolated *L. monocytogenes* in significant numbers from the brain stem of three out of four birds. Petersen and Madsen (2000) isolated *L. monocytogenes* from two of 71 broiler flocks of cloacal swabs from broiler. Njagi *et al.* (2004a) were able to isolate two *L.*

*monocytogenes* and seven *L.* species from the oropharyngeal swab but non from cloacal swabs of chickens.

Antibiotic sensitivity pattern of *L. monocytogenes* was studied by Antunes *et al.* (2002) who recorded that *L. monocytogenes* was resistant to Enrofloxacin and Clindamycin. Njagi *et al.* (2004b) showed that *Listeria* isolates were sensitive to Gentamycin, Kanamycin, Tetracycline, Chloramphenicol and resistant to Ampicillin, Augmentin and Cefuroxime.

Therefore, this work was conducted to cover the following items:

- Isolation and identification of *Listeria* species from different ages of chickens.
- Pathogenicity of *L. monocytogenes* for newly hatched chickens exposed to natural infection.
- Pathogenicity of *L. monocytogenes* to 6-weeks old chickens.
- In vitro sensitivity testing of *L. monocytogenes* against different antibiotics.

## **MATERIALS and METHODS**

### **1- Collection of samples:**

Chickens: One hundred and twenty samples of different ages (1-24 week old) were collected from freshly dead chickens (baby chicks, broilers, layers) from different Chicken farms at Assiut governorate. Tissue samples from intestine, liver, heart and spleen collected from these cases were subjected to bacteriological isolation of *Listeria* organisms.

### **2- Isolation of *Listeria* spp.**

As described by (Gray *et al.*, 1948 and Curtis *et al.*, 1989) samples were collected from each bird, the first one was as intestinal content, while the second one was pooled of liver, heart and spleen. Both samples were aseptically added to *Listeria* enrichment broth (Biolife) and incubated at  $35\pm 1^{\circ}\text{C}$ . After 48h. incubation a loopful of enrichment broth was streaked on the surface of Oxford agar medium and incubated at  $35\pm 1^{\circ}\text{C}$  for 24-48 h.

### **3- Identification of *Listeria* spp.**

Identification and species differentiation was carried out according to Mackie and MacCartney (1962), Finegold and Martin (1982) and Warburton *et al.* (2003) including Gram stain, motility test,

catalase reaction, Voges-Proskauer test, carbohydrate fermentation and the Christie-Atkins-Munch-Peterson (CAMP test).

#### **4- Serotyping of *L. monocytogenes* strains:**

Biochemically identified isolates were serotyped with Listeria O antisera type I (Difco) by using slide agglutination test according to Difco, 1984.

#### **5- Antimicrobial susceptibility testing for *L. monocytogenes*:**

*L. monocytogenes* were tested for their sensitivity and resistance patterns against 11 different antimicrobial agents (Gentamycin, Kanamycin, Amoxycillin, Chloramphenicol, Ampicillin, Enrofloxacin, Colistin Sulphate, Cephadrine, Oxolinic acid, Norfloxacin and Nalidixic acid) by disk diffusion method (Harvey and Gilmour, 2001). All plates were incubated at  $35\pm 1^\circ\text{C}$  for 24 hours and examined for inhibition zones and the results were recorded.

#### **6- Pathogenicity test:**

##### **a. Effect of *L. monocytogenes* on chicken embryos and newly hatched chicks exposed to natural infection:**

Typical morphologically and biochemically suspected colonies were picked up into Tryptose broth and incubated at  $35^\circ\text{C}$  for 18 hours. Amount of 0.2 mL of  $10^5$  CFU of broth culture was inoculated in twenty-11-day old embryonating chicken eggs on chorioallantoic membrane (CAM) and incubated at  $38^\circ\text{C}$  in humidity with frequent turning and twice daily candling. Died embryos were exposed and examined. The survived and hatching chicks were added to 10 birds of the same age. Five birds were kept as non-infected control. The chicks of both groups were examined daily for 15 days, clinical signs and mortality were recorded (Graham *et al.*, 1940; Basher *et al.*, 1984a and Lattmann *et al.*, 1989).

##### **b. Experimental infection of 6 weeks old chickens with *L. monocytogenes*:**

Two groups of 6 weeks old chickens proved by coloacal swab to be free from Listeria. The first group of 20 birds was intraperitoneally infected with 0.5 ml of 18 hour tryptose broth culture of isolated *L. monocytogenes*. Contact group of 10 birds was left in contact with the infected one. Another group of 5 birds was kept as non-infected group control and received 0.5 mL sterile tryptose broth intraperitoneally. All birds were kept under observation for 6 weeks, clinical signs, postmortem lesions and mortalities were recorded (Gross, 1984; Cooper, 1989 and Kurazono *et al.*, 2003).

## RESULTS

Obtained results are recorded in Tables 1-4 and Figures 1-7.

**Table 1:** Incidence of *Listeria* species recovered from the examined chickens.

Source	No. of examined birds	Isolation	Rate of isolation	%	The recovered <i>Listeria</i> species			
					L. monocytogenes		Other <i>Listeria</i> species	
					No.	%	No.	%
Dairoute	40	Intestine	8	20	5	62.5	3	37.5
		Pooled sample	5	12.5	3	60	2	40
El-Kosseia	40	Intestine	5	12.5	3	60	2	40
		Pooled sample	3	7.5	2	66.7	1	33.3
Assiut agriculture farm	40	Intestine	2	5	1	50	1	50
		Pooled sample	-	-	-	-	-	-
Total	120		23	19.2	14	60.9	9	39.1

**Table 2:** Biotyping of *L. monocytogenes* isolated from chickens.

Test	Result
Gram staining	Gram positive, rod, short chains
Motility	Motil - umbrella like growth
Catalase	Positive
Voges proskauer	Positive
Carbohydrate	Positive (acid and no gas)
CAMP test	Hemolysis near staph. Aureus

**Table 3:** Results of pathogenicity of *L. monocytogenes* in experimentally and naturally infected chicks.

Group	No. of infected chicks	Route of infection	Dose of inoculum	Daily deaths post infection										No. of deaths	No. of survivor	Mortality rate
				1	2	3	4	5	6	7	8	9	10			
1	20	Allantoically	10 <sup>5</sup>	-	1	2	-	3	3	-	-	-	6	15	5	75%
2	10	Contact	0	-	-	-	-	-	-	-	-	-	-	3	7	30%
3	5	Control	0	-	-	-	-	-	-	-	-	-	-	-	5	0%

Table 4: Antibiotic sensitivity pattern of the isolated *L. monocytogenes* strains.

Antibacterial agent	No. of strains sensitive	% of sensitivity	Degree of sensitivity of <i>L. monocytogenes</i> isolates
Gentamycin	7/14	50%	-ve
Kanamycin	7/14	50%	-ve
Amoxycillin	14/14	100%	----ve
Chloramphenicol	14/14	100%	----ve
Ampicillin	14/14	100%	----ve
Enrofloxacin	10/14	71.9%	--ve
Cephradine	5/14	35.7%	-ve
Norfloxacin	10/14	71.4%	--ve
Nalidixic acid	14/14	100%	+++ve
Colistin sulphate	0/14	0	-ve
Oxolinic acid	0/14	0	-ve

+++ = highly sensitive  
 ++ = moderately sensitive

+ = weakly sensitive.  
 - = resistance

## DISCUSSION

*Listeria monocytogenes*, the most common causative agent of Listeriosis, is a widespread pathogen and has been also isolated from the gastrointestinal tract of a symptomatic animals and persons as well as the environment (Glass *et al.*, 1995). Chickens, geese, ducks, turkeys and canaries are the most susceptible birds to Listeriosis. Despite the low incidence of infection by this pathogen, its association with high mortality rates (25-30%) makes Listeriosis a serious health problem (Datton *et al.*, 2004).

Results presented in Table (1) declared that the isolation was done from intestine and pooled samples (liver, heart and spleen) at a percentage of 20% and 12.5%, respectively in Dairoute. *Listeria* were isolated from El Kosseia at a percentage of 12.5% and 7.5%, respectively but in Faculty of Agriculture Farm the percentage of isolation was 5%. In this study Isolation was done from different ages (1-24 week old). The relatively higher incidence of *Listeria* spp. may be attributed to that some flocks in Dairoute were suffering from enteritis, fatty liver, drop of

egg production. These results are in agreement with those of Hoffman and Lenarz (1942) and Peperkamp and Jansen (1947) who isolated *L. monocytogenes* from chickens suffering from lymphomatosis and enteritis. On the other hand, in El Kosseiz, the recorded results of isolation in some flocks were associated with Newcastle infections while, coccidiosis was diagnosed in other flocks. The same findings were previously described by Bolin and Turn (1951) who found *L. monocytogenes* in cases of Newcastle disease infections, and Vander Schaaf *et al.* (1956) who isolated the organism from broilers suffered from coccidiosis.

From both intestine and pooled sample from liver, spleen, heart, *L. monocytogenes* and the other Listeria species were isolated at rates of 60.9% and 39.1% respectively. These results were more or less higher if compared with the rates of isolation that obtained by Gitter (1976), Cooper (1989), Petersen and Madsen (2000) and Njagi (2004a).

The results in table (1) revealed that the intestinal specimens showed a higher rate of isolation of *L. monocytogenes* compared with the pooled samples of liver, heart and spleen. These results proved the presence of *L. monocytogenes* in the alimentary tract of healthy birds (Allen Packer, 1975 and Gross, 1984).

The results obtained in the present work showed that *L. monocytogenes* could be isolated from one week old chicks. This may be attributed to the role played by eggs in transmission of infection via shell contamination. Our explanation is in agreement with the observation of Dedie (1955) who suggested that eggs contaminated by fecal material may constitute a source of infection. In the same manner, Petran and Swanson (1993) and Nagah and Enas (1995) who isolated *L. monocytogenes* from the egg shell at a rate of 8.3%, isolated *L. monocytogenes* from the egg shell at the rate and 17.77%, respectively. Asmaa (1997) recovered *L. monocytogenes* and other Listeria species at the rate of 11.7% and 5% respectively.

All tested isolates identified as *L. monocytogenes* gave small gram positive rods cells occur singly in short chains, motile in semisolid agar giving umbrella like growth. Catalase positive, voges-proskauer positive, carbohydrate fermentation positive produce acid with no gas. On CAMP test hemolysis of *L. monocytogenes* was enhanced near *Staphylococcus aureus* streak (Table 2). These results are similar to those reported by Finegold and Martin (1982) and Warburton *et al.* (2003).

Our results concerning the inoculation of *L. monocytogenes* in chick embryos via CAM as shown in (Table 3), revealed that the tested strains were highly pathogenic, causing deaths after 48 hours post-inoculation. Died embryos showed severe congestion of internal organs and necrotic foci on the liver and heart, congestion and curling of embryos and severe enlargement and congestion of yolk sac (Fig. 1). The remaining inoculated chicks died on the 9<sup>th</sup> day post-inoculation, died embryos showed stunting with signs of depression, dullness, ruffled feathers, incoordination of gait and prostration death (Fig. 2). The hatched chicks which died after three days during observation period showed tremor, unilateral and bilateral toe paralysis (Fig. 3). At postmortem examination, there was engorgement of the unabsorbed yolk sac, distention of the gall bladder and congestion of the internal organs.

Contact chicks showed dullness, shivering, muscular tremor and the rate of mortality was 30% after five days. All chicks showed severe congestion in all body muscles and internal organs, necrotic foci on the liver, distention of the gall bladder (Fig. 4). There was congestion of the meninges and oedematous fluid on it (Fig. 5). *L. monocytogenes* was reisolated from dead embryos and contact chicks.

The recovery of *L. monocytogenes* from intestinal contents and various organs (liver, spleen, heart and kidneys) of experimentally and naturally infected chicks is in harmony with findings of Graham *et al.* (1940) and Basher *et al.* (1984a) who explained the pathogenicity of *L. monocytogenes* for newly hatched chicks exposed to natural infection where organism entered through alimentary tract and dissemination followed bacteraemia and toe paralysis were observed in some birds. Lattmann *et al.* (1989) studied the pathogenicity of 10-day old fertilized hen's eggs infected with *Listeria* species and found that *L. monocytogenes* caused death 100% of the infected chicken embryos within 96 hours.

The intraperitoneal infection of broilers aged 6-week old resulted in death rate of 25% during observation period. Nervous signs (torticollis and incoordination) were observed after 7 days of infection. Depression, ruffled feathers and inappetence were also observed (Fig. 6). These clinical signs were only noticed in 12/20 birds (60%). Most of examined birds showed congestion of internal organs, brain, petiole haemorrhages on the proventriculus and thigh muscles, distended gall bladder, pericarditis and airsacculitis (Fig. 7). The same clinical signs



and lesions were described by Allen Packer (1975), Gross (1984) and Cooper (1989).

Contact birds showed depression and inappetence which were the only noticed clinical signs. These results are not similar to those described by Dedie (1955) who did not observe any signs of illness in contact birds. *L. monocytogenes* was reisolated from all diseased and dead birds as well as clinically infected contact birds.

In vitro susceptibility of *L. monocytogenes* isolates to eleven different antibiotics illustrated in Table (5) revealed that 100% of *L. monocytogenes* isolates were sensitive to Amoxycillin, Chloramphenicol, Ampicillin and Nalidixic Acid. 71.4% of isolates were sensitive to Enrofloxacin and Norfloxacin, 50% of isolates were sensitive to Gentamycin and Kanamycin. 35.7% of isolates were sensitive to Cephadrine, while, all isolates were resistant to Colistin sulphate and Oxalinic acid. These results are in difference to those of Antuness *et al.* (2002) who showed that *L. monocytogenes* was resistant to Enrofloxacin and with those of Njagi *et al.* (2004b) who reported that *Listeria* isolates were sensitive to Gentamycin and Kanamycin and resistant to Ampicillin. On the other hand, our results are in agreement with those of Smail (2000) who stated that *Listeria* species were sensitive to Amoxycillin and Ampicillin but were resistant to Gentamycin.

It is noteworthy, to state that *L. monocytogenes* is widely distributed among fowl of different ages and breeds. The organism play a role in many cases especially as secondary invador following viral, parasitic, nutritional disturbances and bacterial diseases. *Listeria* occure normally in alimentary tract of some healthy birds, soil, litter secreation and excretions of carriers or infected chickens. So cleaning, disinfection of houses, equipments and utensils is very important to minimize the infection in poultry farms. Egg shell contamination is considered a major way transmission (Board, 1977). So, hygienic treatment of eggs is very important before setting in incubators because the organism is transmitted to human or animals which can carry this microorganism in their gasterointestinal tract even without symptoms or may retain it for several months, thus constituting potential public health hazard (Farber and Peterkin, 1991). In the meantime, control of Listeriosis could be achieved by awareness of the ubiquity of these organisms and especially of those, environments that favor their multiplication. So collaboration

of medical, veterinary and chicken meat hygienists, farmers and technologists is essential.

## REFERENCES

- Allen Packer, R. (1975):* (Listeriosis) chapter 10 in Isolation and Identification of Avian Pathogens. 1<sup>st</sup> Ed. (Hitchner S.B., Domeomuth, C.H., Purchase, H.G. and Williams, J.E.) Am. Ass. of Avian Pathologist, College Station Texas. pp. 80-83.
- Antunes, P.; Reu, C.; Sousa, J.C.; Pestana, N. and Peixe, L. (2002):* Incidence and susceptibility to antimicrobial agents of *Listeria* spp. and *Listeria monocytogenes* isolated from poultry carcasses in porto, Portugal. *J. Food Prot.*, 65 (12): 1888-93.
- Asmaa, A.A.H. (1997):* Occurrence of *Listeria* species in laying hens. *Assiut Vet. Med. J.* 38 (75): 97-103.
- Basher, H.A.; Fowler, D.R.; Rodgers, F.G.; Seaman, A. and Woodbine, M. (1984a):* Pathogenicity of natural and experimental *Listeriosis* in newly hatched chicks. *Research in Vet. Science* 36 (1): 76-80.
- Best, M.; Kennedy, M.E. and Coates, F. (1990):* Efficacy of a variety of disinfectants against *Listeria* spp. *Appl. Environ. Microbiol.*, 56: 377-380.
- Board, R.G. (1977):* The microbiology of eggs. p. 49-64. In W.J. Stadelman and O.J. Cotterill (eds): *Egg Science and Technology*. AVI Publishing Co., Inc., Westport, Connecticut.
- Bolin, F.M. and Turn, J. (1951):* Non clinical *Listeriosis* of the chicken. *N.D. Agric. Exp. Station Bull.*, 13, 107-108.
- Cooper, G.L. (1989):* An encephalitic form of *Listeriosis* in Broiler chickens. *Avian Diseases* 33: 182-185.
- Curtis, G.D.W.; Mitchell, R.G.; King, A.F. and Griffin, E.J. (1989):* A selective differential medium for the isolation of *L. monocytogenes*. *Lett. Appl. Microbiol.*, 8: 95-98.
- Dalton, C.B.; Gregory, J.; Kirk, M.D.; Stafford, R.J.; Givney, R.; Kraa, E. and Gould, D. (2004):* Foodborne disease outbreaks in Australia, 1995 to 2000. *Commun. D.S. Intell.*, 28 (2): 211-224.
- Dedie, K. (1955):* Beitrag zur Epizootologie der *Listeriose*. *Arch. Exp. Vet. Med.*, 9: 251-264.
- Difco Laboratories (1984):* *Difco manual*. 10<sup>th</sup> Ed., Detroit, MI, pp. 520-524.

- Farber, J.M. and Peterkin, P.I. (1991):* *L. monocytogenes*, a food-borne pathogen. *Microbiol. Rev.*, 55: 476-511.
- Finegold, S.M. and Martin, W.J. (1982):* *Bailey and Scott Diagnostic Microbiology*, 6<sup>th</sup> ed., C.V. Mosby Co. St. Louis. Toronto, London.
- Gitter, M. (1976):* *Listeria monocytogenes* in (oven ready) poultry. *Vet. Rec.* 99 (17) 336.
- Glass, K.A.; Prasad, B.B.; Schyter, J.H.; Uljas, H.E.; Farkye, N.Y. and Luchansky, J.B. (1995):* Effects of acid type and alta TM 2341 on *L. monocytogenes* in a Queso Blanco type of cheese. *J. Food Prot.*, 58 (7): 737-741.
- Graham, R.; Dunlop, G.L. and Levine, N.D. (1940):* *Cornell veterinarian* 30, 268-290.
- Gray, M.L.; Stafseth, H.J.; Thorp, F.; Sholl, L.B. and Riley, W.F. (1948):* *J. of Bacteriology* 55, 471-476.
- Gross, W.B. (1984):* Miscellaneous bacterial disease. In: *Diseases of poultry*, 8<sup>th</sup> Ed. M.S. Hofstad, H.J. Barnes, B.W. Calnek, W.M. Reid and H.W. Yoder, Jr., eds. Iowa State University Press, Ames, Iowa, pp. 257-282.
- Harvey, J. and Gilmour, A. (2001):* Characterization of recurrent and sporadic *L. monocytogenes* isolates from raw milk and non dairy foods by pulsed-field gel electrophoresis, monocin typing, plasmid profiling and cadmium and antibiotic resistance determination. *Appl. Environ. Microbiol.*, 67 (2): 840-847.
- Hoffman, H.A. and Lenarz, C. (1942):* A case of Listeriosis in chickens and an additional case in sheep. *J. Am. Vet. Med. Assoc.* 100: 340-342.
- Kurazono, M.; Nakamura, K.; Yamada, M.; Yonemaru, T. and Sakoda, T. (2003):* Pathology of Listerial encephalitis in chickens in Japan. *Avian Dis.*, 47 (4): 1496-1502.
- Lattmann, C.; Schwarzkopf, A. and Seeliger, H.P. (1989):* Pathogenicity testing of *Listeria* strains isolated from food in fertilized hen's eggs. *Zentralbl Bakteriell Mikrobiol Hyg.*, 270 (3): 400-5.
- Mackie, T.J. and Maccartney, J.E. (1962):* *Handbook of practical Bacteriology*, 10<sup>th</sup> Ed., E. and S. Living Stone Ltd., London.
- Nagan, M.S. and Enas El-Preince (1995):* Prevalence of *Listeria* species in Hen's eggs sold in Assiut city. *Assiut, Vet. Med. J.* 65: 127-131.

- Njagi, L.W.; Muthia, P.G.; Bebora, L.C.; Nyaga, P.N.; Minga, U. and Oiser, J.E. (2004a):* Carrier status for *Listeria monocytogenes* and other *Listeria* species in free range farm and market healthy indigenous chickens and duck. *East Afr. Med. J.*, 81 (10): 529-533.
- Njagi, L.W.; Muthia, P.G.; Bebora, L.C.; Nyaga, P.N.; Minga, U. and Olsen, J.E. (2004b):* Sensitivity of *Listeria* species, recovered from indigenous chickens to antibiotics and disinfectants. *East Afr. Med. J.*, 81 (10): 534-7.
- Peperkamp, C.W. and Jansen, J. (1977):* Listerellosis bij de Kip. *Tijdscher Diergeneesk.*, 72: 389-390.
- Petersen, L. and Madsen, M. (2000):* *Listeria* spp. in broiler flocks: recovery rates and species distribution investigated by conventional culture and the Eia foss method. *Int. J. Food Microbiol.* 30; 58 (1-2): 113-6.
- Petran, R.L. and Swanson, K.M.J. (1993):* Simultaneous growth of *Listeria monocytogenes* and *Listeria innocua*. *J. Food Prot.* 56 (7): 616-618.
- Rocourt, J.A. and Cossart, P. (1997):* *L.monocytogenes*.In:Food Microbiology: Fundamentals and frontiers.pp.337-352, M. P. Doyle; L.R. Beuchat and T.J. Montville (eds.). ASM press, Washington, D.C.
- Smaill, F. (2000):* Antibiotic susceptibility and resistance testing. *Can. J. Gastroenterol.*, 14 (10): 871-875.
- Thamm, H. (1962):* Zur Epizootiologie der Listeriose. *Monatsh Veterinaemed.* 17: 224-370.
- Van Der Schaaf, A.; Vandorssen, C.A.; Donker, Voet, J. and Jaartsvelds, F.H.J. (1956):* Overzicht der onderzoekingen van het uit de praktijk ingezonden ziektmateriaal over het Jaar (1955). *Tijdscher. Diergeneesk* 81, 669-679.
- Warburton, D.; Boville, Ann, Pagotto, F.; Daley Elaine and Chow. Cindy (2003):* The detection of *Listeria* spp. in foods and environmental samples using placom broth. Health Products and Food Branch (HPFB), Ottawa, Ontario.

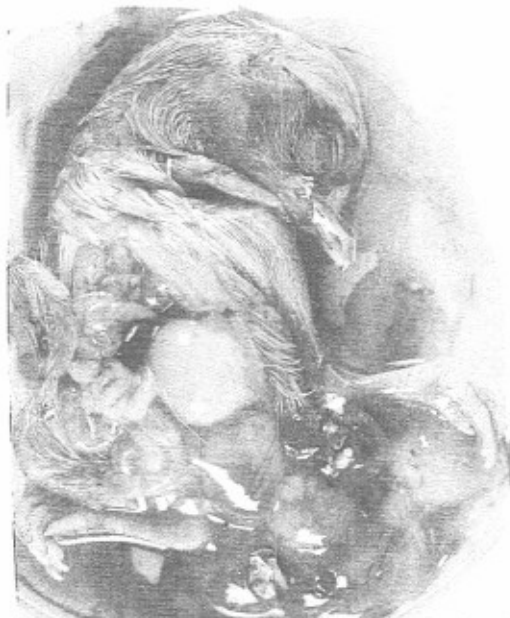

Fig. 1 : *Listeria* infected chicken embryo at 13/14 days showing severe congestion of internal organs, distention of gall bladder, enlargement and congestion of yolk sac.



Fig. 2 : Inoculated chick that died at day 9 post-inoculation showing stunting, depression, ruffled feathers, incoordination of gait and prostration.



Fig. 3 : Hatched chicks expressing bilateral toe paralysis and Tremor ( Right, Middle)- uninfected chick (Left).

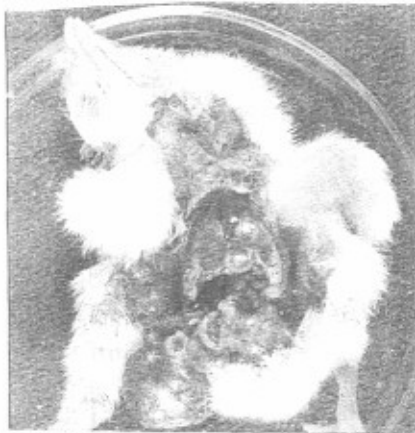

Fig. 4: Experimental and contact chicks showing sever congestion in all body muscles and internal organs.

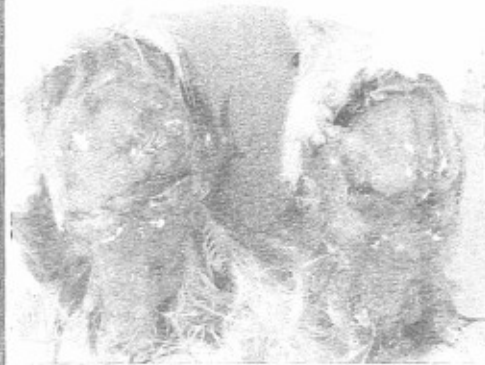

Fig. 5: Experimental and contact chicks showing congested brain and oedematous fluid on the meninges.

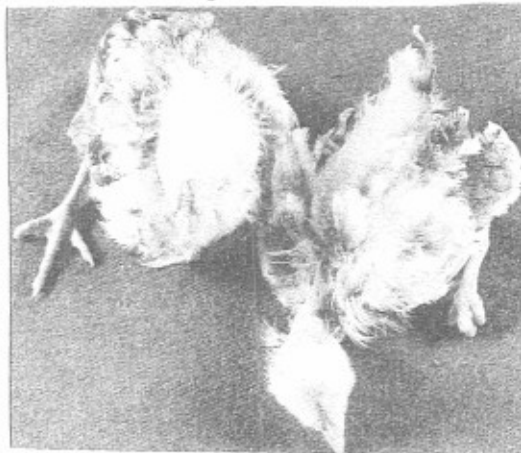


Fig. 6 Intraperitoneally inoculated ckickens showing torticollis, dullness, bilateral toe paralysis and ruffled feathers.

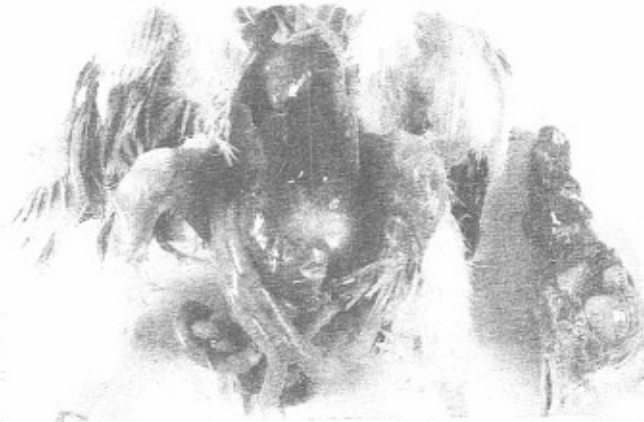

Fig. 7: Intraperitoneally inoculated ckickens showing congestion of internal organs, pericarditis, air sacculitis and brain.