

INFLUENCE OF SOME ANTIOXIDANTS ON HISTOPATHOLOGICAL ALTERATION OF AFLATOXINS.

EI-Daly, E.S.*; Amal A. Abo Hagger; Nabila S. Hassan*** and Y.M. Abdel Shafea****

* Dept. Of Zoology, Fac. of Science, Helwan Univ., Egypt.

** Central Lab. Of Food and Feed, Ministry of Agriculture, Giza, Egypt.

*** Dept. of Pathology, National Research Center, Dokki, Egypt.

ABSTRACT

The present study was designed to evaluate the protective role of vitamin E & selenium (Se), vitamin A, vitamin C, and choline and their combination against the harmful histological effects of aflatoxin in rats. Adult male albino rats, weighing 80-120 g were divided into similar groups. Rats fed 3 aflatoxin doses being 5, 10 and 20 mg/kg diet (3 positive control groups). Aflatoxin plus vitamin E (0.5 mg/kg diet) & Se (5µg/l drinking water), vitamin C (2 g/kg diet), vitamin A (500 mIU /kg diet), choline (3 g/kg diet) and vitamins combination with choline at the same levels mentioned before. Each one from the five pretreatment groups is subdivided into three subgroups according to doses of aflatoxin (treated groups). The negative control group received normal basal diet. Rats received aflatoxins with or without vitamins for 60 days then sacrificed and liver and kidney were taken for histopathological examination.

The histopathological examination of liver of rats treated by aflatoxins revealed vascular dilatation, congestion, edema, hepatic cords disorganization, aggregation of inflammatory cells, pyknotic nuclei and at the highest aflatoxins dose revealed focal necrosis, destruction of bile duct epithelial cells and pleomorphic and necrotic nuclei. The lesions showed increase in severity in a dose dependent manner. However, kidney revealed damaged glomeruli, cloudy swelling in epithelial lining tubules, interstitial hemorrhage and cellular infiltration, beside prominent degeneration in renal tubules and glomeruli at the high doses. The lesions were dose dependent.

The present study suggested that, administration of vitamins and choline resulted in reducing the toxic effects of aflatoxins on liver and kidneys. The best improvements in liver and kidney tissues were shown in groups treated by vitamin E + Se and groups treated by the antioxidants mixture.

Keywords: Aflatoxin - Vitamin A - Vitamin E - Vitamin C – Selenium – Rats – Choline
- Pathological changes – Liver - kidney.

INTRODUCTION

Aflatoxins (AF) are mycotoxins produced primarily by *Aspergillus flavus* (*A. flavus*) and *Aspergillus parasiticus* (*A. parasiticus*). The term mycotoxins is used to describe components or metabolites produced by fungi that are toxic to living organisms (primarily animals and/or man). The term is derived from the Greek word "mykes" meaning fungus and "toxicum" meaning poison or toxin (Goldblatt, 1972). Aflatoxins have been found to be potent hepatotoxins, highly toxic, carcinogenic, teratogenic and mutagenic, which can lead to genetic damage (Wogan, 1966 and 1969 and Goldblatt, 1969). Man and animals live under a certain degree of biological hazard from natural toxicants that occur in food stuffs. During last two decades, an intensive research effort has revealed that mycotoxins are implicated as causative agents of a number of disease syndromes known as mycotoxicosis in animals. Aflatoxins occupy the most important position among mycotoxicosis because of their carcinogenic nature and their frequent wide occurrence under natural condition. The

presence of aflatoxins in animal feed stuff is recognized as one of the most serious health hazard (*Hassanein and Abdel Gawad, 2001*). In rats, *Dwiveddi et al. (1993)* mentioned that, rat liver showed ballooned hepatocytes, degeneration, microvascular fat, focal necrosis, bile duct hyperplasia and proliferation of oval and spindle cells in portal tracts after treatment with a single oral dose (7 mg/kg) of aflatoxin B₁(AFB₁). The same changes were noticed by *Seawright et al. (1993)* who reported that, the male rats treated with AFB₁, 150 µg/ kg body weight for 5 days and for a period of 4 weeks, displayed extensive bile duct hyperplasia. Also *Souza et al. (1999)* mentioned that, intraperitoneal injection of AFB₁ (1 mg/kg) in rats resulted in hepatocellular necrosis and bile duct proliferation. While *Abdeen et al. (2004)* recorded that, treatment of rats by AF mixture for 6 weeks resulted in lymphocytic infiltration hemorrhage, pyknotic nuclei, vacuolar degeneration and increased number of kupffer cells in liver. In addition, *Abdelhamid et al. (2004)* found that, treatment of rats by 1000 ppb aflatoxins for 21 weeks resulted in focal necrotic areas associated with focal mononuclear leucocytic inflammatory cells infiltration surrounding central vein diffuse kupffer cells proliferation and apoptosis in liver. *Abdeen et al. (2004)* reported that, the kidney of rats treated with AF mixture for 6 weeks showed lymphocytic infiltration, hemorrhage, pyknotic nuclei and vacuolar degeneration in cells of epithelium lining of tubules and in glomeruli. Moreover *Abdelhamid et al. (2004)* mentioned that, kidney of rats fed with 1000 ppb aflatoxins for 21 weeks showed disfiguration in the shapes and normal arrangement of epithelial cells lining the renal tubules and the dead neutrophil observed in the both cortical and medullary portions. *Souza et al. (1999)* reported that, the histological changes induced by AFB₁ such as hepatocellular necrosis and bile-duct proliferation were markedly inhibited in animals pretreated with vitamin E. Also *Verma and Nair (2002)* mentioned that, pretreatment of mice with vitamin E (2mg/animal/day) significantly ameliorated aflatoxin induced changes as compared with aflatoxin treatment alone (25-50 µg/animal/day). *Lei et al. (1990)* concluded that selenium at a dose level of 3 ppm had an inhibitory effect on the initiation and promotion stages of AFB₁-induced preneoplastic foci and nodules. Selenium also prevented progression of these nodules to hepatocellular carcinoma ever after cessation of AFB₁ administration. In addition, *Abdelhamid et al. (1995)* mentioned that, vitamin E and selenium were beneficial in detoxification of aflatoxic diets of broiler chicks and cocks fed on 100 and 50 ppb AFB₁ for four and eight weeks, respectively followed by four weeks on AF-free diets. *Sauberlich (1994)* reported that, ascorbic acid is an antioxidant which reacts directly with singlet oxygen, hydroxyl, and superoxide radicals which could be caused by AFB₁. *Netke et al. (1997)* reported that, the administration of vitamin C could favorably modify the metabolism of AFB₁ in guinea pigs. Moreover, *Yousef et al. (2003)* recorded that, ascorbic acid alleviated the negative effect of AFB₁ in rabbits treated orally by 15µg AFB₁+ 20 mg ascorbic acid /kg bw or 30µg AFB₁ +20 mg ascorbic acid /kg bw. Also, *Liu and Zhou (1989)* stated that, vitamin A is a potent biological antioxidant and it significantly prevents alterations induced by aflatoxin in tissue such as liver, kidney of mouse. Also, *Webster et al. (1996)* reported that, vitamin A may control carcinogenesis by manipulating molecular events at the initiation stage. In addition, *Denli et al. (2003)* found that, Japanese quails fed diet supplemented with vitamin A (15,000 IU /kg feed), vitamin A (15,000 IU/kg) + low level of AFB₁ (100g /kg), showed that addition of vitamin A reduced the toxic effects of AFB₁, in the liver and kidney than AFB₁ group. *Gupta et al. (1987)* reported that the rodent chronically fed on choline-devoid (CD) diet showed development of hepatocellular carcinomas. And *Enzmann et al. (1992)* noticed that, decreased activity of glycogen phosphorylase in liver of rats fed a choline-deficient diet.

The present study was conducted to determine the ability of dietary supplements of vitamins (A, C and E), selenium and choline and their combination to

suppress the toxicity of aflatoxins at different doses in pathological changes in liver and kidney of male adult albino rats.

MATERIALS AND METHODS

This study was carried out in the Central Laboratory of Food and Feed, Agriculture Research Center, Ministry of Agriculture, Giza, Egypt.

Production of aflatoxin:

For producing of aflatoxin, the strain of *Aspergillus flavus* NRRL 3145 (from laboratory of mycotoxins, National Research Center, Dokki, Cairo) was grown in synthetic media, namely yeast extract- sucrose broth (YES) containing 2 % yeast extract and 20% sucrose. The substrate was dispensed in conical flasks. The flasks were then autoclaved for 15 minute at 121 °C then cooled and inoculated with spores suspension and incubated for 9 days at 25-29 °C. Aflatoxin concentration was determined using High-Performance Liquid Chromatography (HPLC) according to *Roos et al. (1997)*. The culture contained a mixture of aflatoxin B₁, B₂, G₁ and G₂ at a total 100 ppm.

Animals:

A total of hundred and seventy one adult male albino rats (average weight 100 g) were obtained from Research Institute of Ophthalmology, Giza, Egypt divided to 19 treated groups 9 rats in each group and housed in wire cages (3 animals in each cage) provided with feed and water troughs and feed *ad Libitum*. Water was available for 24 hours daily and cages were kept in a conditioned room.

Diets:

The basal diet was prepared according to (*Dckere et al., 1987*). It contained casein 20%, corn oil 10%, wooden fibers 5%, salt mixture 4%, vitamins mixture 1% and starch 60%. The tested antioxidants and aflatoxin were added to basal diet. The medium added to diet contained a mixture of aflatoxin B₁, B₂, G₁ and G₂ at a total three levels low, medium, high (5, 10, 20 mg/kg diet) respectively. The tested antioxidants were vitamin E + Se, vitamin C, vitamin A, choline and their mixture. The experiment was designed as follow:

i. Pretreatment period (1st 15 days)

Rats were divided into 9 groups according to received diet as follow:

Group 1: untreated basal control diet

Group 2: contaminated control diet at low level (5 mg/kg diet)

Group 3: contaminated control diet at medium level (10 mg/kg diet)

Group 4: contaminated control diet at high level (20 mg/kg diet)

Group 5: basal diet supplemented with vitamin E (0.5 g/kg diet) and Se (5µg/l drinking water).

Group 6: basal diet supplemented with vitamin C (2 g/kg diet).

Group 7: basal diet supplemented with vitamin A (500 mIU /kg diet).

Group 8: basal diet supplemented with choline (3 g/kg diet).

Group 9: basal diet supplemented with combined vitamins and choline (at the same above levels)

ii. Treatment period (the next 45 days)

Each supplemented groups (5, 6, 7, 8 and 9) was divided into three subgroups according to aflatoxin concentration level (low, medium and high).

At the end of experiment rats were scarified and liver and kidney were taken. Samples of each tissue were preserved in neutral formalin solution (10% v/v) for histopathological examination till processing as paraffin blocks and sectioning for Haematoxylin and Eosin staining according to *Culling (1963)*.

RESULTS

Histopathological alterations in liver:

The histopathological examination of liver of treated groups revealed more or less the same pathological lesions but differ in degree of severity. It was obvious that degree of severity depend upon the concentration of aflatoxins. The lesions were more severe in the group treated by aflatoxins alone than in groups treated by aflatoxins plus vitamins (E + Se, C, A) or choline and vitamins mixture plus choline and also higher in groups treated by higher aflatoxins dose when compared by groups treated by lower doses. The highest improvement in liver hepatocytes was found in groups of rats treated with vitamin E +Se and groups treated by choline.

No pathological alterations were observed in liver of male rats of the negative control groups. As their liver showed normal central veins and normal hepatic cords separated by blood sinusoids (Fig. (a) plate 1).

The liver of rats of the positive control groups which treated with low, medium, and high doses of aflatoxins showed that, the severity of lesions was gradually increased by increasing the doses. The lesions were more severe in rats treated by high dose of aflatoxins.

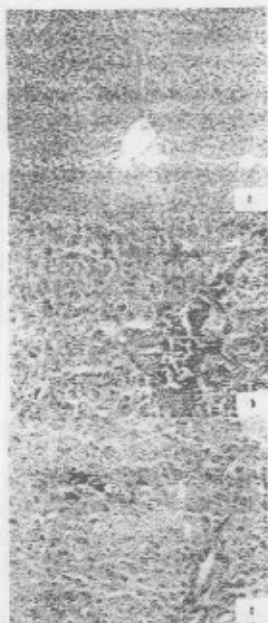


Plate 1

Plate 1, Fig. (b & c) showed the effect of low and medium dose of aflatoxin in rats liver.

Fig. (b) (liver of rat treated with the low dose of AF) showing vascular dilatation, congestion, oedema and disorganization of hepatic cords. (H & E X300).

Fig. (c) (Liver of rat treated with the medium dose of AF) showing congested blood vessels with aggregation of inflammatory cells and presence of some pyknotic nuclei in hepatocytes. (H & E X300).

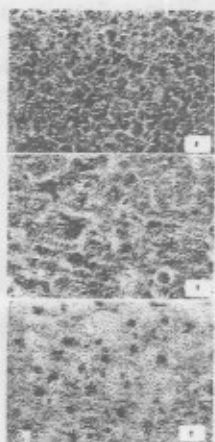


Plate 2: Showing the effects of high dose of aflatoxins on liver of rats.

Fig. (a) (liver of rat treated with the high dose of AF) showing focal necrosis, destruction of bile duct epithelial cells. (H & E X300).

Fig. (b) (liver of rat treated with the high dose of AF) showing pleomorphic and necrotic nuclei in some cells. (H&EX300).

Fig. (c) (liver of rat treated with the high dose of AF) showing pyknotic nuclei in some cells. (H & E X500).

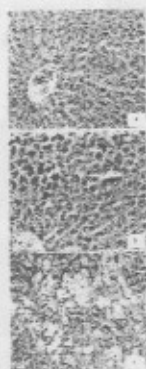


Plate 3: Figs. (a, b& c) showing the effects of vitamin E + Se and different doses of aflatoxin on rats liver.

The treatment of rats by vitamin E + Se resulted in improvement of hepatocytes, especially in low aflatoxin dose.

Fig. (a) (liver of rat treated with vitamin E + Se and the low dose of AF) showing normal hepatocytes architecture. (H&EX300).

Fig. (b) (liver of rat treated with vitamin E + Se and the medium dose of AF) showing normal hepatocytes with increased mitotic figures (in the form of binucleated cells and mitotic division). (H & E X300).

Fig. (c) (liver of rat treated with vitamin E + Se and the high dose of AF) showing bile duct proliferation, ballooning and apoptotic hepatocytes. (H & E X300).

The photomicrographs in **Plate 4, Figs. (a, b& c)** showing the effects of vitamin C and different doses of aflatoxins on liver of rats. Treatment of rats by vitamin C resulting in improvement in liver hepatocytes, especially at the low doses of aflatoxin. Also, the lesions recorded in liver of rats treated by vitamin C and the high dose of aflatoxins was less severer than in liver of the positive control groups.



Plate 4, Fig. (a) (liver of rat treated with vitamin C and the low dose of AF) Showing more or less normal architecture of hepatocytes.(H&EX300).

Fig. (b) (liver of rat treated with vitamin C and the medium dose of AF) showing moderate improvement in hepatocytes architecture. (H&EX300).

Fig. (c) (liver of rat treated with vitamin C and the high dose of AF) showing patches of coagulative necrosis, fatty degeneration and apoptotic cells. (H&EX150).

Plate 5: Figs. (a, b& c) show the effect of vitamin A and different doses of aflatoxin on liver of rats. The liver of rats showed some degenerative changes, which increased by increasing dose of aflatoxins but they were mild comparing with liver of rats of the positive control groups.

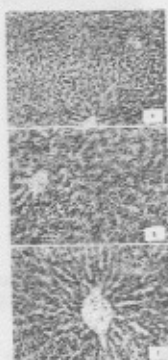


Plate 5, Fig. (a) (liver of rat treated with vitamin A and the low dose of AF) Showing maintenance of cellular integrity in the central area around central vein and vacuolar degeneration and pyknotic nuclei scattered in portal area. (H&EX150).

Fig. (b) (liver of rat treated with vitamin A and the medium dose of AF) Showing moderate improvement in hepatocytes architecture. (H&EX300).

Fig. (c) (liver of rat treated with vitamin A and the high dose of AF) Showing more or less normal hepatocytes architecture and the hyper chromatin condensation also noticed. (H&EX300).

The photomicrograph in Plate 6: Figs. (a, b& c) recorded the pathological alterations in liver of rats treated by choline and different doses of aflatoxins. The liver of these groups showed some pathological alterations which were gradually increased by increasing dose of aflatoxin but these alterations were less in severity than that in the positive control groups.




Plate 6, Fig. (a) (liver of rat treated with choline and the low dose of AF) Showing dilatation of sinusoids, vacuolar degeneration and few improvement in hepatocytes structure. (H&EX300).

Fig. (b) (liver of rat treated with choline and the medium dose of AF) Showing moderate improvement in hepatocytes architecture, dilatation of sinusoids and cloudy swelling in individual hepatocytes. (H&EX150).

Fig. (c) (liver of rat treated with choline and the high dose of AF) Showing more or less normal hepatocytes architecture. (H&EX150).

Plate 7: Figs. (a, b& c) show the effect of vitamins mixture, choline and different dose of aflatoxins on liver of rats. The liver of rats treated by choline showed improvement in hepatocytes which decreased by increasing dose of aflatoxin.



Plate 7, Fig. (a) liver of rat treated with vitamins mixture, choline and the low dose of AF) Showing more or less normal hepatocytes architecture. (H&EX150).

Fig. (b) liver of rat treated with vitamins mixture, choline and the medium dose of AF) Showing marked improvement in hepatocytes architecture. (H&EX150).

Fig. (c) liver of rat treated with vitamins mixture, choline and the high dose of AF) Showing mild improvement hepatocytes architecture. (H&EX150)

Histopathological alterations in kidneys:

The histopathological examination of kidney of treated groups revealed more or less the same pathological lesion but differ in degree of the severity. It was obvious that the degree of severity depended upon the concentration of aflatoxins. The lesions were more severe in the group treated by aflatoxin alone than in groups treated by aflatoxin plus vitamins (E + Selenium, C, A) or choline and vitamins mixture plus choline and also higher in groups treated by the higher aflatoxins dose when compared by the groups treated by the lower doses. All groups treated by vitamin E + selenium and vitamin A showed best results while the groups treated by antioxidants mixture showed more lesions than other antioxidants groups.

No pathological alterations were observed in kidney of male rats of the negative control groups. As their kidney showed normal Malpighian corpuscles surrounded with different cortical tubules (Fig. (a) Plate8).

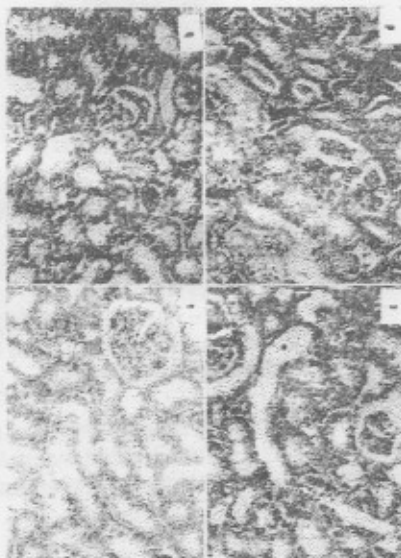


Plate 8

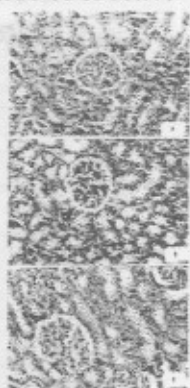Plate 8: Figs. (b, c& d) recorded the pathological alterations in rats' kidney of the positive control groups which treated by low, medium and high doses of aflatoxins. The kidney of rats of the positive control groups treated with low, medium, and high doses of aflatoxins showed that, the severity of lesions was gradually increased by the dose increase. The lesions were more severe in rats treated by the high dose of aflatoxin.

Fig. (b): Kidney of rat treated with the low dose of AF showing glomerular degeneration, degeneration in epithelial lining some of tubules and hyaline casts in lumen of some tubules.(H&EX300).

Fig. (c): Kidney of rat treated with the medium dose of AF showing damaged glomeruli, cloudy swelling in epithelial lining of tubules, interstitial hemorrhage and few cellular infiltration in between tubules. (H&EX300).

Fig. (d): Kidney of rat treated with the high dose of AF showing increased in hemorrhagic spaces and inflammatory cells and also showed prominent degeneration in renal tubules and glomeruli. (H&EX300).

Plate 9: Figs. (a, b& c) showed the effect of treatment of rats by vitamin E+Se and different doses of aflatoxin on kidneys. The kidneys of these groups showed varying degrees of improvement of renal tubules structure.



Plat 9, Fig. (a): Kidney of rat treated with vitamin E + selenium and the low dose of AF showing improvement in glomeruli and renal tubules structure. (H&EX300).

Fig. (b): Kidney of rat treated with vitamin E + selenium and the medium dose of AF showing mild improvement in glomeruli and renal tubules structure. (H&EX300).

Fig. (c): Kidney of rat treated with vitamin E + selenium and the high dose of AF showing marked improvement in glomeruli and renal tubules structure. (H&EX300).

Plate 10: Fig. (a, b& c) recorded the pathological alterations in kidneys of rats treated by vitamin C and different doses of aflatoxins. The kidney of rats treated by vitamin C and the high dose of aflatoxins showed some degenerative changes but these changes were mild than that in the positive control groups.



Plate 10 Fig. (a): Kidney of rat treated with vitamin C and the low dose of AF showing moderate improvement in glomeruli and renal tubules structure. (H&EX150).

Fig. (b): Kidney of rat treated with vitamin C and the medium dose of AF showing some improvement in renal structure, while the renal tubules were dilated and some glomeruli were degenerated. (H&EX150).

Fig. (c): Kidney of rat treated with vitamin C and the high dose of AF showing vacuolar degeneration in tubular epithelial cells lining and degeneration of most of glomeruli. (H&EX150).

Plate 11: Figs. (a, b& c) recorded the alterations in kidneys in rats treated by vitamin A and different doses of aflatoxins. The kidneys of these groups showed marked improvement in renal tubules and renal corpuscles in all aflatoxin doses.



Plate 11, Fig. (a): Kidney of rat treated with vitamin A and the low dose of AF showing improvement in glomeruli and renal tubules structure. (H&EX300).

Fig. (b): Kidney of rat treated with vitamin A and the medium dose of AF showing improvement in renal tubules and corpuscles. (H&EX300).

Fig. (c): Kidney of rat treated with vitamin A and the high dose of AF showing marked improvement in renal tubules and corpuscles. (H&EX300).



Plate 12: Figs. (a, b& c) showed the effect of treatment of rats by choline and different doses of aflatoxins on kidneys. Some pathological changes were recorded in these groups but they were mild comparing with alterations in kidneys of the positive control groups.

Fig. (a): Kidney of rat treated with choline and the low dose of AF showing moderate improvement in glomeruli and renal tubules structure. (H&EX300).

Fig. (b): Kidney of rat treated with choline and the medium dose of AF showing desquamation of epithelial cell lining and dilatation of some renal tubules. (H&EX300).

Fig. (c): Kidney of rat treated with choline and the high dose of AF showing dilatation of renal tubules. (H&EX300).

Plate 13: Figs. (a, b&c) showed the alterations in rats' kidneys treated with vitamins mixture plus choline and different doses of aflatoxins. The kidneys of these groups showed some improvement in renal tubules in low aflatoxin dose and also showed some degenerative changes in higher doses but it is lesser than that in the positive control groups.



- Plate 13, Fig. (a):** Kidney of rat treated with vitamins mixture plus choline and the low dose of AF showing improvement in glomeruli and regenerated and improved renal tubules (H&EX300).
- Fig. (b):** Kidney of rat treated with vitamins mixture plus choline and the medium dose of AF showing improvement in glomeruli, moderate improvement in renal tubules structure while some tubules showed vacuolar degeneration in their epithelial lining (H&EX300).
- Fig. (c):** Kidney of rat (which treated with vitamins mixture plus choline and the high dose of AF showing improvement in glomeruli, improvement in renal tubules and corpuscles while tubules showed prominent increase in vacuolar degeneration in their epithelial lining (H&EX300).

DISCUSSION

In the present investigation, treatment of rats by different doses of aflatoxins caused hepatotoxicity as revealed by histological study. The degree of severity of pathological lesions depends upon the dietary concentration of aflatoxin in diet. Liver showed vascular dilatation, congestion, edema and disorganization of hepatic cords at the low dose of aflatoxins and showed more severe lesions at the higher doses as showed congested blood vessels, aggregation of inflammatory cells and presence of some pyknotic nuclei in hepatocytes in medium aflatoxin dose and focal necrosis, destruction of bile duct epithelial cells, pleomorphic nuclei in some cells and pyknotic nuclei in others at the high dose of aflatoxins. Liver injury by aflatoxicosis was recorded also in various studies and various species (*Abdelhamid et al., 1985, 2002 a, b & c and 2004 a, b & c; Kandil et al., 1991; Rajendran and Sundararasan, 1992; Dwiveddi et al., 1993; Jones et al., 1997; Souza et al., 1999; Hassanein and Abdel Gawad, 2001 and Adbeen et al., 2004*).

Kidney is also affected by aflatoxicosis in dose dependant manner. The kidney of rats treated with the low aflatoxins dose showed glomerular degeneration, degeneration of epithelial lining of tubules and hyaline casts in lumen of some tubules. More severe lesions were found in kidney of rats treated by the higher doses, kidney of rats treated by the medium dose of aflatoxins showed damaged glomeruli, cloudy swelling and interstitial hemorrhage and cellular infiltration, while kidney of rats treated by the highest aflatoxins dose revealed increase in hemorrhagic spaces and inflammatory cells also showed prominent degeneration in renal tubules and

glomeruli. Such alterations were previously recorded also by *Balachandran and Remarkrishnan, (1987)*; *Abdelhamid et al., (1995)* and *Abdeen et al., (2004)* in various animal species.

The toxic effect produced by aflatoxin on organs was explained by *Gutteridge and Halliwell, (1990)* who mentioned that, aflatoxin treatment resulted in enhancement of lipid peroxidation in rats, which is directly related to free radical mediated toxicity. The targets of oxidative damage are usually critical biomolecules such as nucleic acids, proteins, and lipids.

Antioxidants are known to reduce oxidative- radical- induced reaction. Previous studies on the protective effects of antioxidants such as selenium, β carotene, vitamin A and vitamin C, against cytotoxicity and genotoxicity of aflatoxin were mostly focused on the metabolism and detoxification of aflatoxin or formation of AFAB₁- DNA adducts as studies made by *Decoudu et al. (1992)*; *Webster et al.(1996)* and *Yousef et al.(2003)*.

Histopathological examination revealed that vitamin E+Se supplementation reduced toxic effect of aflatoxin on liver and kidneys, especially at the low doses of aflatoxins. The liver showed normal hepatocytes in rats treated by vitamin E + selenium and the low dose of aflatoxins while it showed mild lesions at the medium and high doses of aflatoxins which were less severer than in liver treated by the aflatoxin alone.

Kidneys of rats treated by vitamin E + Selenium showed improvement of renal tubules at all doses. The protective effect of vitamin E and selenium was previously recorded in many studies. Vitamin E was reported as an important antioxidant by *Gunstone et al., (1986)* and *Smith et al., (1986)* who recorded the inhibitory effect of vitamin E on the oxidation of various compounds including polyunsaturated fatty acids. Vitamin E is suggested to produce its protective role through inhibition of lipid peroxidation. *Minnunni et al. (1992)* mentioned that vitamin E had anticarcinogenic properties as it protects the cell lipids from oxygen damage. Also, *Shen et al. (1994)* and *Swierczynski et al. (1997)* reported that vitamin E could protect cell against lipid peroxidation and consequently against cell damage and perhaps, also tumor development. Moreover, vitamin E was recorded to inhibit histological changes induced by AFB₁ such as hepatocellular necrosis and bile duct proliferation by *Abdelhamid et al., 1985, 2002 a, b& c and 2004 a, b& c and Souza et al., 1999*.

The biological influence of selenium noted in the present study could be attributed to the fact that selenium is an important antioxidant which protects cells against damage caused by free radicals and hydro- or lipoperoxidation (*McDowell, 1989*). Selenium had antioxidants properties against neoplasm development as well as inhibitory effect on aflatoxin activity catalase (*Gosh et al., 1991*). Also, *Lei et al. (1990)* reported that selenium had an inhibitory effect on the initiation and promotion stages of AFB₁ – induced preneoplastic foci and nodules.

Histopathological examinations revealed that vitamin C supplementation reduce toxic effect of aflatoxin on liver and kidney, especially at the low aflatoxins dose. Whereas liver and kidneys of rats' groups treated with vitamin C and aflatoxins showed some degenerative changes but were less in severity than that in groups treated by aflatoxins alone. The beneficial influence of vitamin C noted in the present study can be attributed to the fact that vitamin C is an important natural antioxidant which inhibits lipid peroxidation (*Machlin and Bendich, 1987 and Sato et al., 1990*). Also, *Knight et al.,(1993)* and *Sauberlich,(1994)* stated that vitamin C is naturally occurring free radical scavenger, and its presence assisted various other mechanisms in decreasing numerous disruptive free radical process from taking place and react directly with singlet oxygen, hydroxyl and superoxid radicals which could be caused by aflatoxin. Vitamin C also had antimutagenic effect and inhibits carcinogen- induced

cell transformation (*Ibric et al., 1991 and Kushida et al., 1992*). Moreover, vitamin C suppressed the binding of aflatoxin to hepatocyte DNA (*Herbaczynska-Cedro et al., 1995*).

Histopathological examinations revealed that vitamin A supplementation reduce toxic effect of aflatoxins on liver and kidney, especially at the low aflatoxins dose. Whereas liver and kidneys of rats' groups treated with vitamin A and aflatoxin showed less severe lesions and less degenerative changes than that administered by aflatoxin alone. The results are in accordance with *Denil et al. (2003)* who found that the addition of vitamin A in diet reduced the toxic effect of AFB₁ on the liver and kidney function enzymes in Japanese quails. The protective effect of vitamin A against carcinogenicity induced by aflatoxin was reported by *Firozi et al. (1987)* who recorded that vitamin A suppresses aflatoxin metabolic activity in rat liver microsomes. *Bhattacharya et al. (1989)* and *Liu and Zhou (1989)* mentioned that vitamin A is a potent antioxidant prevents alterations induced by aflatoxin in tissues such as liver and kidney. *Decoudu et al. (1992)* reported that vitamin A reduces DNA damage in AFB₁ treated rats and *Yu et al. (1994)* reported that vitamin A is a potent inhibitor of the formation of AFB₁-DNA adducts which is essential step in AFB₁ induced hepatocarcinogenesis. The role of vitamin A in reducing effect of aflatoxin could also attributed to one or more of the following: selective inhibition of the metabolic activation pathway, scavengering of the reactive intermediate, and/or interaction with DNA binding to protective from reactive intermediates (*Ioannides et al., 1990*).

Histopathological examinations revealed that choline supplementation minimize alteration in liver and kidney produced by aflatoxins especially lat the low aflatoxins dose. Whereas liver and kidneys of rats groups treated with choline and aflatoxin showed less degenerative changes than that recorded in rats treated by aflatoxin alone. The protective mechanism of choline could be attributed to results obtained by *Chandar et al. (1987)* who reported that feeding of rats on choline- devoid diet resulted in increase liver cell proliferation and liver cell death.

In the present study, histopathological examinations revealed that vitamins mixture and choline supplementation minimize alteration in liver and kidney produced by aflatoxins especially at the low aflatoxins dose. Whereas liver and kidneys of rats groups treated with vitamin mixture + choline and aflatoxin showed less degenerative changes than that recorded in rats treated by aflatoxin alone.

REFERENCES

- Abdeen, A. M.; Abdel Hady, E. K. ; Mansy, S. E. ; Abd-Allah, G. A. and Omar, N. A. (2004). Histopathological and morphological studies on the influence of some aflatoxin liver, kidneys and testes of albino rat. *Histology and Histochemistry* (44) C: 53-75
- Abdelhamid, A.M., A.E. Abdel-Khalek, A.I. Mehrm and F.F. Khalil (2004). An attempt to alleviate aflatoxicosis on Nile tilapia fish by dietary supplementation with chicken-hatchery by-products(egg shell) and shrimp processing wastes (shrimp shells) on : 2- Clinical, blood and histological parameters. *J Agric. Sci. Mansoura Univ.*, 29:6175-6196.
- Abdelhamid, A.M., A.M. Ahmed and Kh.M. El-Melegy (2004). An attempt to alleviate the histological alterations of some internal organs of rats fed on aflatoxin contaminated diets. *J. Agric. Sci. Mansoura Univ.*, 29: 2355-2370.
- Abdelhamid, A.M., I. El-Shawaf, S.A. Elayoty, M.M. Ali, and I. Gamil (1985). Effect of low level of dietary aflatoxins on baladi rabbits. *J. Agric. Sci. Mansoura Univ.* 10: 1159-1174 (IVth Inter. Symp. Of Vet. Lab. Diag. June 2-6, 1986, Amsterdam, edited by G.H. A. Borst et al., 1986, Utrecht, Netherland, pp: 151-154) (*Nut. Abst. & Rev.* 1987, 3498) (*Arch. Anim. Nutr.*, Berlin 40:517-537, 1990).

- Abdelhamid, A.M.; Kandil, W.M.; Arief, H.S.M. and Dorra, T.M. (1995). Effect of some dietary supplements to aflatoxic diets of chicks. III- On the histopathology. J. Agric. Sci. Mansoura Univ., 20: 3251-3259.
- Abdelhamid, A.M. F.F.M. Khalil, Ml. Ei- Barbary, V.H. Zaki, and H.S. Husien (2002). Feeding Nile tilapia on Biogen to detoxify aflatoxic diets. Proc. 1st Ann.Sc. Conf. Anim. & Fish Prod., Mansoura, 24 & 25 Sep., pp: 207-230.
- Abdelhamid, A.M., F.I. Magouz, M.F.E. Salem, A.A. Mohamed, and M.K. Mohsen (2002). Effect of dietary graded levelsof aflatoxin B1 on growth performance and biochemical, chromosomal and histological behavior of Nile tilapia, *Oreochromis niloticus*. Proc. 1st Ann. Sc. Conf. Anim. & Fish Prod., Mansoura, 24& 25 Sep., pp:231-250.
- Abdelhamid, A.M., M.A. Ragab and A.F. El-Shaieb (2002).The use of Tafla or aluminosilicate for alleviating toxic effects of aflatoxin-contaminated diets of growing rabbits. Proc. 1st Ann. Sc. Conf. Anim. & Fish Prod., Mansoura, 24 & 25 Sep., pp: 389-413
- Balachandran, C. and Ramakrishnan, R. (1987). An experimental study on the pathology of aflatoxicosis in broiler chicken. Indian Vet. J. 64: 911-914.
- Bhattacharya, R.K.; Prabhu, A.L.; and Aboobaker, V.S. (1989). In vivo effect of dietary factors on the molecular action of aflatoxin B1: role of vitamin A on the catalytic activity of liver fractions. Cancer Lett., 44: 83-88.
- Chandar, N.; Amenta, J.; Kandala, J.C. and Lombardi, B. (1987): Liver cell turnover in rats fed on choline-devoid diet. Carcinogenesis, 8: 669- 673.
- Culling, C. F. A. (1963): Handbook of histopathological techniques.2nd Ed., Butterworth and Co., London.
- Dckere, A. M. E.; Verplanke, J. C.; Blonk, G. C. and Van Nielen, G. L. (1987): Effects of type and amount of dietary fat on rabbit and rat lymphocyte proliferation in vitro. The J. Nut. 118 (1): 11-18.
- Decoudu, S.; Cassand, P.; Daubeze, M.; Frayssinet, C. and Narbonne, J. F. (1992): Effect of vitamin A dietary intake on *in vitro* and *in vivo* activation of aflatoxin B₁. Mutat. Res., 269: 269-278.
- Denli, M.; Kemal C. and Ferda O. (2003): Effect of vitamin A supplementary in the feed to reduce toxic effects of aflatoxin B₁ on Japanese Quails (*Coturnix coturnix Japonica*) International Journal of poultry science, 2(2):174-177.
- Dwiveddi, Y.; Rastogi R.; Mehrotra R.; Garg, N.K. and Dhawan B.N. (1993). Picroliv protects against aflatoxin B₁ acute Hepatotoxicity in rats. Pharmacol. Res. 27: 189-199.
- Firozi, P.F.; Aboobaker, V.S. and Bhattacharya, R.K.(1987). Action of vitamin A on DN_a adduct formation by aflatoxin B₁ in a microsome catalysed reaction. Cancer Lett., 34: 213-220.
- Goldblatt, L.A. (1969). Aflatoxin. Acadmic press, New York
- Goldblatt, L.A.(1972). Implication of mycotoxins Clin. Toxicol. 5:453-464
- Gosh, R.C.; Ghauhan, HVS; Jha, G.J. (1991): Supperation of cell-mediated immunity by purified aflatoxin B₁ in broiler chicks. Vet. Immunol. Immunopath., 28: 165-172.
- Gunstone, D.; Frank, J.; Hardwood, L. and Fred, B.P. (1986). The lipid Handbook. Chapman and Hall Ltd: London
- Gutteridge, J.M.C. and Halliwell, B.(1990):The measurement and mechanism of lipid peroxidation in biological systems. Trends Biochem. Sci., 15:129-135.
- Hassanein, A.M.M. and Abdel Gawad, A.M. (2001): Histological and ultra structural studies on the effect of aflatoxin B₁ on the liver of rabbits. Egypt. J. Zoo., 37: 379-392.

- Herbaczynska-Cedro, K.; Cedro, K.; Wasek, W.; Panczenko - Kresowska, B. and Wartanowicz M. (1995). Supplementation with vitamin C and E suppresses leukocyte oxygen free radical production in patients with myocardial infarction. *Eur. Heart J.*, 16: 1044-1049.
- Ibric, L.L.V.; Petrson, A.R. and Sevanion, A. (1991): Mechanisms of ascorbic acid-induced inhibition of chemical transformation in C3H/10T1/2 cells. *Am. J. Clin. Nutr.*, 54: 1236-1240.
- Ioannides, C.; Ayrton, A.D.; Keele, A.; Lewis, D.F.V.; Flatt, P.R. and walker, R. (1990). Mechanism of in vitro antimutagenic action of retinol. *Mutagenesis*, 5: 257-262.
- Jones, T.C.; Hunt, R.D. and King, N.W. (1997): *Veterinary pathology*. Lea & Febiger. Philadelphia.
- Kandil, W.M.; Sirag, S.M.; Abdelhamid, A.M. and Dorra, T.M. (1991): Histological studies on mycotoxicoses in broiler breeder hens. *Mansura Medical J.*, 21: 193.
- Knight, J.A.; Blaylock, R.C. and Searles, D.A. (1993). The effect of vitamins C and E on lipid peroxidation in stored erythrocytes. *Ann. Clin. Lab. Sci.*, 23: 51-56.
- Kushida, H.; Wakabayashi, K.; Suzuki, M. and Takahashi, S. (1992): Suppression of spontaneous hepatocellular carcinoma development in C3H/He NCrj mice by lipophilic ascorbic acid, 2-o-octa deylascorbic acid (CV-3611). *Carcinogenesis*, 13: 913-915.
- Lei, D.N.; Wang, L. Q.; Ruebner, B.H.; Hsieh, D.P.H.; Wu, B.F.; Zhu, C.R. and Du, M.J. (1990): Effect of selenium on aflatoxin hepatocarcinogenesis in the rat. *Biomed. Environ. Sci.*, 3(1): 65-80.
- Liu, X.L. and Zhou, Y.Z. (1989). The effect of aflatoxin B₁ on vitamin A status and on microsomal mixed function oxidase in male mouse. *Zhonghua Yu Fong Yi Xue Za Zhi*, 23: 218-225.
- Machlin, L. and Bendich, A. (1987): Free radical tissue damage: protective role of antioxidant nutrients *FASEB J.*, 1: 441-445.
- Mc Dowell, L.R. (1989): *Vitamins in animal nutrition comparative aspects to human nutrition: vitamin E* Academic press: London, 23-131.
- Mehrotra, M. L. and Khanna, R. S. (1973). Aflatoxicosis in Angora rabbits. *Indian Vet. J.* 50: 620-622.
- Minnunni, M.; Walleb, U.; Muller, O.; Pfeifer, A. and Aeschbacher, H.U. (1992): Natural antioxidants as inhibitors of oxygen species induced mutagenicity. *Mutation Res.*, 269: 193-200.
- Netke, S.P.; W.M. Roomi; C. Taso and A. Niedzwiecki (1997). Ascorbic acid protect guinea pigs from acute aflatoxin toxicity. *Toxicol. Appl. Pharmacol.*, 143: 429 - 435.
- Rajendran, M.P.; Sundararajan, A. (1992): Clinico-pathology of aflatoxin toxicity in cattle. *Ind. Vet. J.*, 69: 115-117.
- Roos, A. H.; Van der Kamp, H. J. and Marley, E. C. (1997): Comparison of immunoaffinity columns with Florisil/ C18 columns for the determination of aflatoxins in animal feed and maize. *Mycotoxin Research*, 13: 1-10.
- Sato, K.; Niki, E. and Shimasaki, M (1990): Free radical mediated chain oxidation of low density lipoprotein and its synergistic inhibition by vitamin E and Vitamin C. *Arch. Biochem. Biophys.*, 279: 402-405.
- Sauberlich, H. (1994). Pharmacology of vitamin C. *Annu. Rev. Nutr.*, 14: 371-391.
- Seawright, A. A.; Snowden, R. T.; O'Lubuyide, I. O.; Riley, J.; Judah, D. J. and Neal, G. E. (1993). A comparison of the effect of aflatoxin B₁ on the livers of rats and duck hepatitis B virus-infected and non-infected ducks *Hepatology*, 18(1): 188-197.
- Shen, H.M.; Shi, C.Y.; Lee, H.P. and Ong, C.N. (1994): Aflatoxin B₁ induced lipid peroxidation in rat liver. *Toxicology and Applied pharmacology*, 127: 1, 145-150.

- Smith, E.L.; Hill, R.L.; Lehman, I.R.; Lefkowitz, R.J.; Handler, P. and white, A. (1986): Principles of Biochemistry, Mammalian Biochemistry. McGraw-Hill: London, 760.
- Souza, M.F.; Tome, A. R. and Rao, V.S.N.(1999): Inhibition by the bioflavonoid ternaftin of aflatoxin B₁-induced lipid peroxidation in rat liver. J.pharmacy and pharmacology, 51:2,125-129.
- Swierczynski, J.; Kochan, Z. and Mayer, D. (1997). Dietary α -tocopherol prevents dehydroepiandrosterone-induced lipid peroxidation in rat liver microsomes and mitochondria. Toxicol. Litt., 91: 129-136.
- Verma, R.J. and Nair, A. (2002). Effect of aflatoxins on testicular steroidogenesis and ameliorated by vitamin E. Food chem.. Toxicol., 40: 669-672.
- Webster, R.P.; Gawde, M.D. and Bhattacharya, R.K.(1996). Effect of different vitamin A status on carcinogen induced DNA damage and repair enzymes in rats. In vivo, 10: 113-118.
- Wogan, G.N. (1966). Chemical nature and biological effects of the aflatoxins. Bacterial rev. 30: 460-470.
- Wogan, G.N. (1969). Naturally occurring carcinogens in foods. Prog. Expth. Tumor. Res., 11: 134-162.
- Yousef, M.I.; Salem, M.H.; Kamel, K.I.; Hassan, G.A. and El-Nouty, F.D. (2003). Influence of ascorbic acid supplementation on the haematological and clinical biochemistry parameters of male rabbits exposed to aflatoxin B₁. J. of Environmental Science and Health. 38(2): 139 – 209.
- Yu, M.W.; Zhang, y.D.; Blaner, W.S. and Santella, R.M. (1994). Influence of vitamins A,C,E and beta-carotene on aflatoxin B₁ binding to DNA in woodchuck hepatocytes. Cancer, 1: 596-604.

تأثير بعض مضادات الأكسدة علي التغيرات النسيجية المرضية للأفلاتوكسينات

عزت صدقي الدالي* ، أمل عبد العزيز أبو حجر**، نبيله صلاح حسن*** و ياسر محمد عبد الشفيق***

- * قسم علم الحيوان- كلية العلوم- جامعه حلوان
- ** المعمل المركزي للاغذية والأعلاف-مركز البحوث الزراعيه
- *** قسم الباثولوجي- للمركز القومي للبحوث

استهدفت هذه الدراسة تقييم الدور الواقي لفيتامين هـ + السلينيوم، فيتامين ج، الكولين و خليط منهم ضد التغيرات الهستوباثولوجية الحادثة بواسطة الافلاتوكسين في الجرذان. قُسمت الجرذان الي مجموعات و عولمت متساوية، بثلاث جرعات من الافلاتوكسينات (منخفضة، متوسطة،عالية) بالإضافة الي فيتامين هـ + السلينيوم، فيتامين ج، الكولين و خليط منهم. تسببت المعاملة بالانلاتوكسينات في وجود تغيرات باثولوجية في كبد الجرذان حيث وجد بها اتساع في الأوعية الدموية ، احتقان ، فقد في تنظيم خلايا الكبد ، تجمع للخلايا الالتهابية ، تخثر في بعض الخلايا ، هدم في الخلايا المبطنة للقنوات المرارية و تغيرات في النواه تشمل تعدد أشكال النواه في بعض الخلايا و تخثرها في البعض الآخر و زيادة في اللون . أما في الكلى فكان هناك تهمد في أنسجة الكلى، و تنكس استسقاقي في الخلايا المبطنة لأنابيب الكلى، و نزف بين الأنابيب، و ارتشاح لبعض الخلايا، و تخثر في انسجه الكلى في جرعه الانلاتوكسينات المرتفعة، و عموما كانت شدة الأعراض متناسبة مع زيادة جرعة الافلاتوكسينات. أدت المعاملة بفيتامين هـ + السلينيوم، فيتامين ج، الكولين و خليط منهم الي تقليل التأثير السام للأفلاتوكسينات على تركيب أنسجة الكبد و الكلى. وكانت افضل النتائج في المجموعات المعاملة بفيتامين هـ + السلينيوم وخليط الفيتامينات مع الكولين.