

STUDIES ON BOVINE FIELD SKIN LESIONS IN FAYOUM GOVERNORATE

LAMIA, A. AHMED*, OMYMA, M. EL-DESAWY* and A. T. MOHAMED **.

*Department of virology, Animal Health Research Institute, Dokki, Giza.

**Director of Animal Health Research Institute, Dokki, Giza.

Received: 18.10. 2004

Accepted: 14. 12. 2004

SUMMARY

In this study an outbreak in Fayoum Governorate during summer 1998 showed skin lesions, fever (40-41°C) which resembled clinical manifestation of lumpy skin disease (LSD). The skin lesion in a form of firm rounded skin nodules which covered with erected hair.

15 cases among cattle herd have been recorded, samples from all suspected diseased animals were taken. The samples were inoculated on chorio-allantoic membrane (CAM) of embryonated chicken egg (ECE) aged 9-11 days, for several passages and in MDBK tissue culture for isolation. Confirmatory tests were carried out by using standard specific antisera against LSD virus using agar gel immunodiffusion test AGID, immunoperoxidase and immunofluorescent. The positive lesions of CAM (pock lesion) were collected on 10% neutral formalin buffer for histopathological

examination.

INTRODUCTION

Lumpy skin disease (LSD) is a serious skin disease of cattle caused by a single strain of capripox virus which known as Neethling virus. The disease was first described as pseudo-urticaria in northern Rhodesia (now Zambia) in 1929 (MacDonald, 1931 and Morris, 1931).

LSD is characterized by nodular cutaneous eruptions, lymphadenitis dysaglectia and less frequent oedema of one or more limbs (Haig, 1957). The outbreak of the disease is frequently emerging in Africa and some countries in Middle East.

LSD was reported for the first time in Egypt in 1988 through cattle imported from Somalia (Fayed et al., 1988; Anonymous, 1988). In 1989

the disease was spread rapidly and caused several outbreaks in different Governorate (Suez, El-Tal El-Kabir in Ismailia Governorate [highest incidence of the disease] and El-Sharkia).

Several local isolates of LSD were identified during an outbreak of the disease in Menia, Assuit and Upper Egypt (El-Allawy et al., 1992).

The office international des epizooties (OIE, 1989) considered LSD one of the list A disease, which are communicable diseases considered to have the potential for very serious economic loss (Anon, 1985).

Control of LSD in Egypt depends on application of sheep pox virus SPV (Romanian strain, Michael et al., 1996). Several studies suggested that we need to develop an attenuated cell culture vaccine from LSD (Sewell and Bracklesby, 1990).

A trial for production of inactivated LSD virus vaccine from Ismailia strain 88 by using 2% (2-bromo ethylamine hydrobromide BEI) and adjuvanted with *Nigella sativa* oil is safe, sterile and highly immunogenic either when used for priming or boosting the animal primed with SPV vaccine (Omya, 2001).

MATERIAL AND METHODS

Material

15 skin lesion samples were collected during sum-

mer 1998 in dairy cattle farm in Fayoum Governorate and submitted for investigation at Department of Virology, Animal Health Research Institute, Dokki, Giza, Egypt.

1. Samples: skin nodules were collected from dairy infected cattle on glycerol buffer for virus isolation and identification.

2. Antisera

a. Reference antiserum against LSD virus was kindly supplied by Virology Department, Faculty of Veterinary Medicine, Cairo University.

b. Fluorescent antibovine immunoglobulin prepared in rabbit (Difco, USA).

3. Virus: Reference LSD virus was kindly supplied by Virology Department, Faculty of Veterinary Medicine, Cairo University.

4. Reagent: DAB substrate solution was used for immunoperoxidase test: 3-3-diamino-benzidine tetrahydrochlorid 50 ml
Tris HCl 50mM (pH 7.6) 50 ml

5. Tissue culture: MDBK cells were used for virus isolation and identification (immunoperoxidase and immunofluorescent test).

Methods

1. Sample preparation: 15 skin lesion samples were collected from diseased cattle and prepared according to Ali and Obeid, (1977).

2. Virus isolation:

a. Egg inoculation: 0.2 ml from the prepared samples was inoculated via chorioallan-

toic route of 9-11 day old fertile eggs using 3 eggs for each sample. Four passages were applied. Inoculation of ECE was done according to the technique described by Van Rooyen et al. (1969).

b. Tissue culture: the prepared samples were inoculated three blind passages into confluent sheet of MDBK cell lines, then observed daily for evidence of any cytopathic effect, the propagation is carried out according to House (1989).

3. Virus identification

a. Agar gel immunodiffusion test (AGID): the test was applied according to Brian and Hillar (1996).

b. Indirect peroxidase test (IPT): the test was applied on the infected tissue culture cells according to Atulk (1988).

c. Indirect immunofluorescent test (IFT): the test was carried out on the infected tissue culture cells according to Gardner and Quillin (1980).

4. Post mortem examination: the CAMs were examined for any changes then collected on 10% neutral formalin buffer for histopathological examination.

5. Histopathological examination: specimens from CAM were collected and immediately fixed in 10% neutral formalin buffer and processed according to Carlton (1963).

RESULTS

I. Virus isolation:

a. Post mortem examination of BCE: typical pock lesion was found on the harvested CAM. 4 days post infection, as shown in Fig. (1).

b. Tissue culture: cytopathogenicity on MDBK cell culture was observed after 3-4 days which characterized by cell rounding, shrinking and finally cell detachment leaving large irregular halls in cell sheet.

II. Virus identification

1. Agar gel immunodiffusion (AGID)

A purified agar is used as a matrix and the reactant simply diffused through the gel towards each other (polyclonal antibody and samples), the immunoprecipitation process involved the formation of whitish line as positive result. 2 out of 15 samples were positive by using AGID.

2. Indirect immunoperoxidase technique (IPT):

IPT was applied on infected MDBK tissue culture cells, the positive result revealed brown granules in the infected cells with different intensity as shown in fig. (2). 5 out of 15 samples were positive by using IPT.

3. Indirect immunofluorescent technique (IFT):

IFT was applied on the infected MDBK tissue culture cells the positive results revealed intracytoplasmic fluorescent granules in the cyto-

plasm of the infected cells with variant intensity as shown in fig. (3). 6 out of 15 samples were positive by using IFA.

Histopathological examination:

In the infected CAM, the main picture was extensive hyperplasia in the majority of ectodermal and endodermal epithelium layers forming projection outside the layers. Vaculation was also observed in many cells pushing the nucleus towards the cell membrane. The mesodermal layer was infiltrated with inflammatory cells mainly plasma cells associated with oedema as shown in fig. (4). Intracytoplasmic homogenous inclusion bodies were found in the endothelial cells.

DISCUSSION

Lumpy skin disease (LSD) is caused by poxvirus belonging to the family Poxviridae, genus Capri. It is an African disease, which was first introduced in Egypt as an exotic disease. During 1988, the disease was widely spread and during five month period in the year 1989, it spread through thirteen governorates of Egypt. Since it is an arthropod born disease, so the outbreaks mostly occurred in summer months. LSD is characterized by the formation of firm circumscribed nodules in the skin and subcutaneous tissue. The skin nodules may cover the whole of the animal's body.

The disease caused enormous economic losses in virgin as well as in endemic area. Damage of the hides and infertility alongside with the mortalities and act of vaccination and control programs also count for the economical loss. The control strategy of LSD was based on the use of the live attenuated strains of Capri-pox viruses (Carn, 1993). Several researchers have used the sheep pox virus vaccines and the results showed that these vaccines were sufficiently related to the LSD to induce cross protection (Davis, 1976). The application of the sheep pox vaccine against LSD during outbreaks was successful to control LSD infection.

In this study, the post mortem examination of CAM revealed the presence of pock lesion, 4 days post infection which agreed with Abd El-Rahim et al. (2002). Pock lesions in CAM were only appeared in 7-9 days embryos incubated at 33.5 and 35°C for 5 to 6 days (Van Rooyen et al., 1969).

Cytopathogenicity on MDBK cell culture revealed rounding, shrinking and finally cell detachment leaving large irregular cavities in cell sheet at 3-4 day post inoculation, which agreed with that recorded by Woods (1988) and El-Allawy et al. (1992), while Hanan (2000) recorded the same results in MDBK cell culture, on the other hand the same passage of virus in BHK and Vero could not reveal a clear CPE even in 7 day post infection.

Diagnosis of positive isolates by using AGID test revealed that 2 out of 15 samples were positive by using AGID indicating that the test is less sensitive for the diagnosis or need more concentration of the isolates, Munz and Owen (1966) reported that it had not yet been possible to demonstrate agglutination or agar gel precipitation with Neethling type virus. IPT applied on the infected MDBK tissue culture cells revealed that 5 out of 15 samples were positive, this coincided with that recorded by Holm-Jensen (1981) and El-Bagoury (1990) where they used infected MDBK cell culture with LSD for IPT giving maximum reaction which appeared in positive samples as intense reddish brown colouration. Results of IFT applied on the infected MDBK tissue culture cell showed that 6 out of 15 samples were positive.

The result gives clear evidence that immunoperoxidase technique well correlated and go in parallel manner with IFT for detection of LSD virus in MDBK cells. This agrees with Ohman et al. (1981) and El-Bagoury (1990). The histopathological examination of the infected CAM revealed extensive hyperplasia in the majority of ectodermal and endodermal layers beside infiltration with inflammatory cells in mesodermal layer due to viral infection and multiplication which indicated by detection of intracytoplasmic inclusion bodies in the endothelial cells, this result agreed with Abd El-Rahim et al. (2002).

The above mentioned results proved that the examined samples were LSD virus and throw light on some pathogen aspects of the disease.

Sheep pox vaccine was applied through the country once it proved its efficacy in experiment done in Serum and Vaccine Research Institute, Abbassia, as it give sufficient cross-protective immunity to safe guard cattle against sever LSD virus challenge (Saber et al., 1993 and Michael et al., 1991). In spite of its efficacy there was an outbreak of LSD in El-Menia Governorate during the summer session of 1998 (Abd el-Rahim et al., 2002) and also from the result of the present study which reported sporadic cases of LSD in Fayoum governorate, so the preparation of specific vaccine against LSD is essential for controlling the disease and prevention of economic losses of the disease, this agrees with Mervat (1999) who inactivated LSDV after adaptation on (MA-104). She found that double oil emulsion inactivated LSD vaccine was more effective than alhydrogel inactivated LSD vaccine. Also agrees with the recent study for application of locally prepared inactivated LSDV vaccine from Ismailia strain 88, inactivated with 2% BEI and adjuvated with *Nigella Sativa* oil is safe, sterile and highly immunogenic either when used for priming of susceptible animals or for boosting of animals primed with sheep pox vaccine with it (Omyma, 2001). So we can prevent the appearance of the disease again in Egypt.

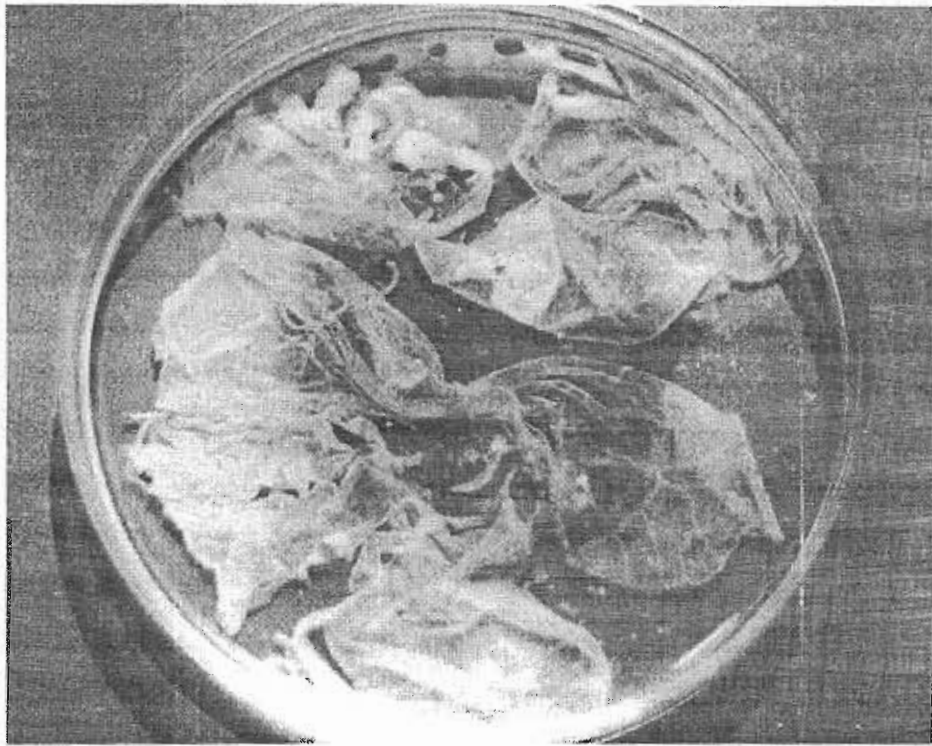


Fig. (1): Typical pock lesion on the harvested CAM

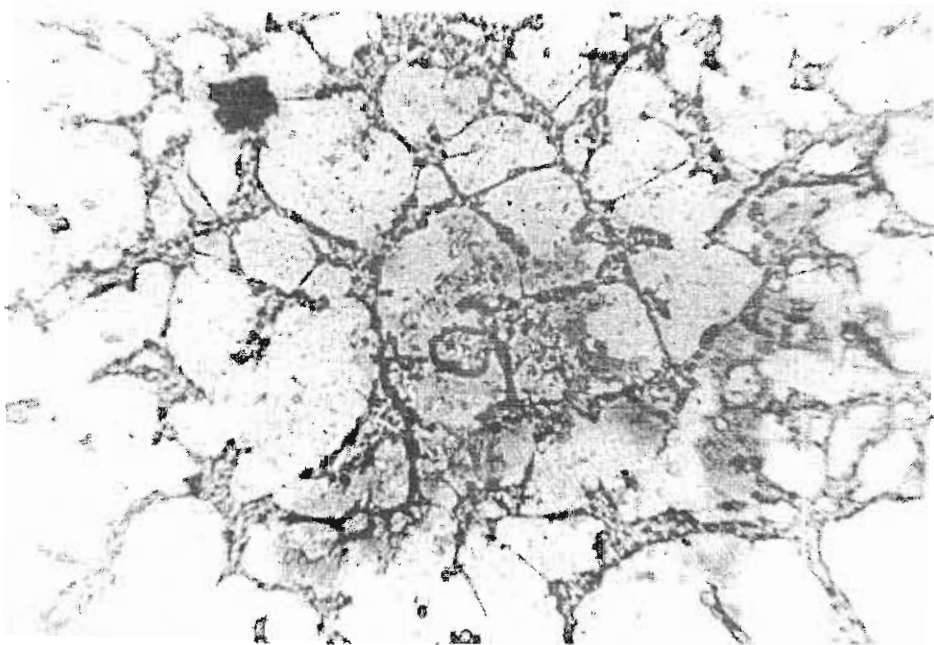


Fig. (2): Intracytoplasmic brown granules in the infected cells (IPT)

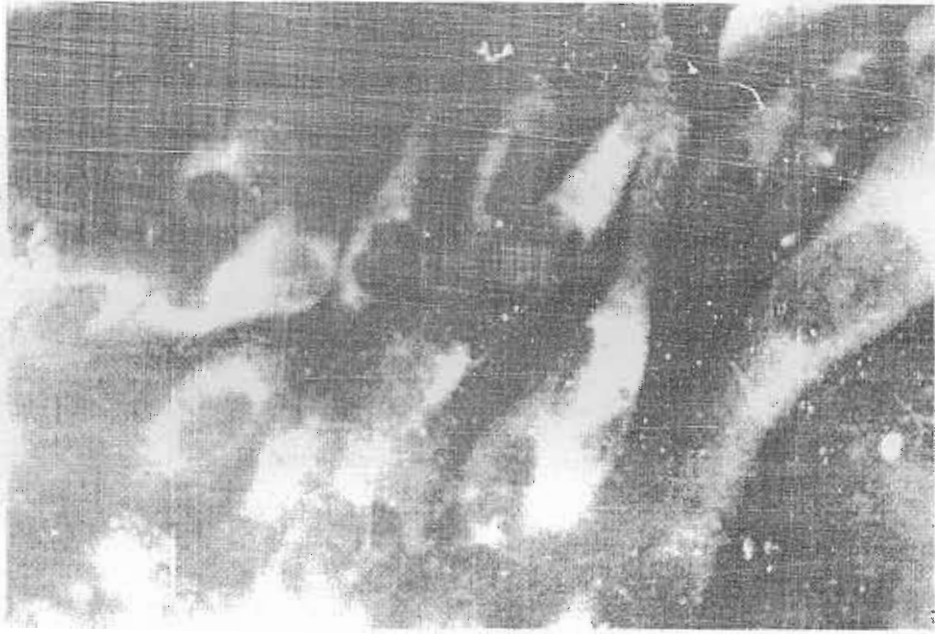


Fig. (3): Intracytoplasmic fluorescent granules in the infected cells (IFA)

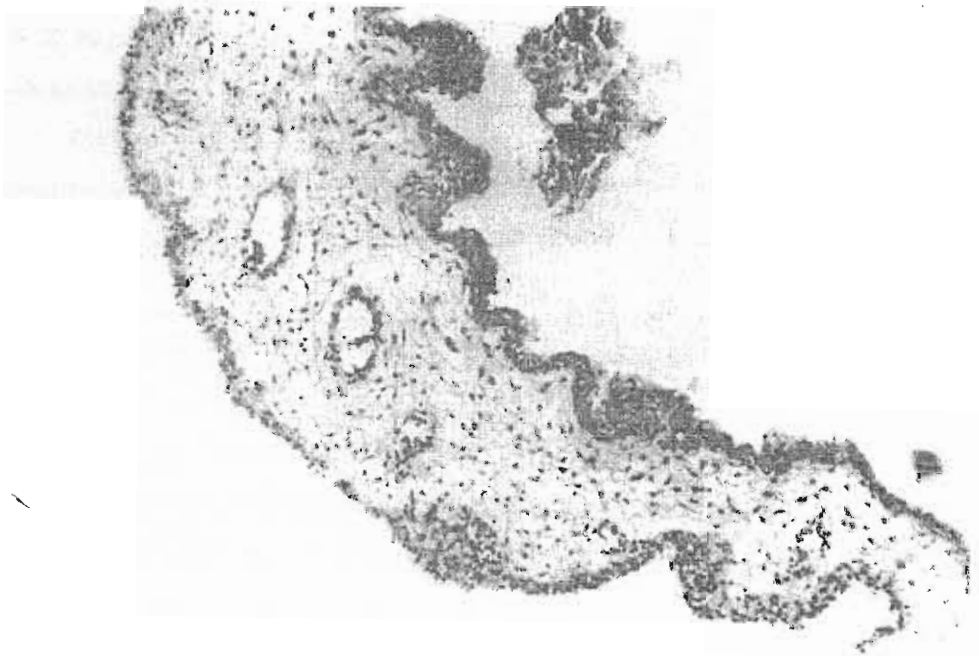


Fig. (4). Hyperplasia of the epithelial lining the ectoderm and endoderm

REFERENCES

- Abd El-Rahim, I. H. A.; Ballal, S. E. and Hussein, M. (2002): An outbreak of lumpy skin disease among cattle in Upper Egypt (el-Menia Governorate). *Minufya Vet. J.* 2 (1): 185-195.
- Ali, B. H. and Obeid, H. M. (1977): Investigation of the first outbreak of lumpy skin disease in the Suddan. *Br. Vet. J.* 133: 184-189.
- Anon (1985): In *World Animal Health Statistics, 1985 vol. I. No. I. New animal disease outbreaks.* PG Office International Des Epizooties, Paris, France.
- Anonymous (1988): *Lumpy skin disease. OIE Disease Information, Paris, France. Vol. I No. I.*
- Atulk, B. H. A. V. (1988): *Diagnostic immunopathology.* R. B. Calvin and A. R. B. Hanond (Eds.) R. C. Mccluske, R. A. Ven Press, New York.
- Brian, W. J. and Hillar, O. (1996): *Virology method manual.* Chapter 18, pp. 325-356. Academic Press, Inc. San Diego, USA.
- Carlton, H. M. (1963): *Histological techniques.* 4th ed. New York, London and Toronto, Oxford University Press.
- Carn, V. M. (1993): Control of capripoxvirus infections vaccine. 11: 1275-1279.
- Davis, F. G. (1976): Characteristics of a virus causing a pox disease in sheep and goat in Kenya with observation on epidemiology.
- El-Allawy, T. A.; El-Tarabili, M. A.; Morad, M. I. and Sedek, S. R. (1992): Isolation and identification of lumpy skin disease from Upper Egypt. *Assuit Vet. Med.* 28 (55): 279-289.
- El-Bagoury, G. F. (1990): Evaluation of some recent virological techniques in the diagnosis of bovine viral diarrhoea mucosal disease complex (BVD/MD). Ph.D V. Sc. Thesis, Fac. Vet. Med., Moshtohor, Zagazig University.
- Fayed, A. A.; Saber, M. S.; Moussa, a. A. and Reda, I. M. (1988): Epidemiology of lumpy skin disease in Egypt. Fourth annual report on the scientific progress of PI-480 project, grant No. TG-FG 216, -project No. PB-APHISD, October 1988 - September, 1989.
- Gardner, P. S. and Quillin, J. Mc. (1980): *Rapid virus diagnosis and application of immunofluorescence.* 2nd ed. Butter worth, London.
- Haig, D. A. (1957): Lumpy skin disease. *Bull. Epizot. Dis. Afr.* 5: 421-430.
- Hanan, A. F. (2000): Studies on intradermal allergic skin test of lumpy skin disease virus in cattle. Ph.D V. Sc. (Virology) Thesis, Fac. Vet. Med., Cairo University.
- Holm-Jensen, M. (1981): Detection of antibodies against hog cholera virus and bovine viral diarrhoea virus in porcine serum. A comparative examination using C. F.; PLA and NPLA assay *Acta vet. Scand.* 22: 85-98.
- House, J. A. (1989): Unpublished information. USDA, APHIS, FADDL, Green Port, NY 1944.
- MacDonald, R. A. S. (1931): Pseudourticaria in cattle. Dept. Anim. Hlth, Government of Northern Rhodesia. *Ann. Report*, pp. 20-21.
- Mervat, I. I. (1999): Preliminary studies on inactivated lumpy skin disease virus vaccine. Ph.D V. Sc. Thesis, (Virology) Fac. Vet. Med. Cairo University.
- Michael, A. Salama, S. A.; Soliman, S. M.; Mousa, A. A.; Bachoum, M. E.; Barsoum, G. W.; Osman, A. O. and Nassar, M. I. (1991): The determination of the immune state of cattle to lumpy skin disease in Egypt. *J. Egypt. Vet. Med. J., Giza. Vol.53, No. 1 (2005)*

- Vet. Med. Assoc. 51 (2): 427-434.
- Morris, J. P. A. (1931): Pseudourticaria. Annual Report of the Dept. Anim. Hlth, Government of Northern Rhodesia. Pp. 12.
- Munz, E. K. and Owen, N. C. (1966): Electron microscopic studies on LSD type "neethling" onderstepoort. J. Vet. Res. 33 (1): 3-8.
- Office International Des Epizooties (OIE) (1989): Lumpy skin disease. Manual Vol. I (A/007): 1-5.
- Ohman, H. B.; Jensen, M. H.; Sorensen, Dalsgaard, K. (1981): Demonstration of BVD virus antigen in cryostat and paraffin section of bovine tissues by the immunoperoxidase technique. Acta Path. Microbiol. Scand. Sect. c, 89: 281-285.
- Omya, M. El-Desawy (2001): Studies on lumpy skin disease virus vaccines. Ph.D V. Sc. Thesis, Fac. Vet. Med. Beni-Suef branch, Cairo University.
- Saber, M. S.; Rafie, E. K.; Moussa, A. A.; Shalaby, M. A.; El-Sanosi, A. A.; Sami, A. M.; Hassan, H. B.; Aly, M. M.; Mousa, H. A. and Reda, I. M. (1993): The present immune status for lumpy skin disease (LSD) in some Egyptian Governorates. 2nd Sci. Cong. Egypt. Society for Cattle Disease. 5-7 December 1993, Assuit, Egypt.
- Sewell, M. M. H. and Bracklesby, D. W. (1990): Handbook on animal disease in the tropics. 4th ed. Bailiere, Tindall, London, Philadelphia, Toronto, Sydney, Tokyo, 326-329.
- Van Rooyen, P. J.; Munz, E. K. and Weiss, K. E. (1969): The optimal conditions for the multiplication of Neethling-type lumpy skin disease virus in embryonated eggs. Onderstepoort J. Vet. Res. 36 (2): 165-174.
- Woods, J. A. (1988): Lumpy skin disease. A review. Trop. Animal. Hlth. Prod. 20: 11-17.