

Dept. of Parasitology
Faculty of Medicine, Assiut University

**LIGHT MICROSCOPIC STUDY OF THE EFFECT
OF FLUBENDAZOLE, PRAZIQUANTEL
AND COMBINATION OF BOTH DRUGS
ON ADULT *SCHISTOSOMA MANSONI***
(With 14 Figures)

By

**LAILA A. OMRAN; FATMA G. SAYED;
SALMA M. ABDEL RAHMAN and AMAL M. ABDO**

(Received at 25/12/2005)

دراسة بالميكروسكوب الضوئي لتأثير الفلوبندازول والبرازيكونتل
والعقارين معا على ديدان الشيستوزوما مانسوناي

ليلى علي موسى عمران ، فاطمة جلال سيد ، سلمى محمد عبد الرحمن ،
أمل محمد عبده

إن الجمع بين العلاج بالعقاقير ووسائل الوقاية يمكن أن يخفض من الإصابة بمرض البلهارسيا. تم إجراء هذه الدراسة على ٦٠ من فئران التجارب البيضاء المعدية بسركاريا الشيستوزوما مانسوناي ، وقد قسمت الفئران إلى ٤ مجموعات (مجموعة ضابطة، مجموعة معالجة بعقار الفلوبندازول، مجموعة معالجة بعقار البرازيكونتل، مجموعة معالجة بالعقارين معا). وتم تقييم تأثير العلاج على كل من ديدان الذكر والأنثى بعد ١، ٢، ٣ أسابيع من العلاج. وقد تم تجميع الديدان عن طريق الضخ من خلال الوريد الباطني والمعوي كما تم صبغ الديدان بصبغة الكارمين الحامضية وتم فحصها بالميكروسكوب الضوئي.

SUMMARY

It is considered that combination of chemotherapy with other control measures can reduce transmission and morbidity of schistosomiasis. This study was done using 60 albino mice infected with cercariae of *Schistosoma mansoni*. Mice were divided into 4 groups (control, flubendazole treated, praziquantel treated and combination of both drugs). The effect of treatment was evaluated on male and female worms after (1, 2&3 Week Post Treatment). Worms were collected by perfusion of portal vein and mesenteric veins separately, stained with acetic acid alum carmine and examined by light microscope.

Key words: *Schistosoma mansoni*, light microscopy, Flubendazole, Praziquantel.

INTRODUCTION

Morphological descriptions of adult male and female *Schistosoma mansoni* with light and electron microscopy were reported by Race *et al.* (1971); Hockley (1973); Sneft *et al.* (1978); Schmidt (1992) and Joes *et al.* (1997).

The objective of chemotherapy is to cure individual patient by eradication of infection with convenient, well tolerated tools for control of schistosomal morbidity in human (Younis & Khalil, 1998). Despite the fact that safe and effective chemotherapy of schistosomiasis has become increasingly available in endemic areas, the prevalence continues to increase worldwide (Webbe & Jordan, 1993).

Treatment of *S. mansoni* with Praziquantel either alone or combined with other drugs was reported by Shalaby *et al.* (1991); Mansoury (1997) and Shuhua *et al.*, (2000). However, drug resistance to praziquantel was discussed recently by Ismail, *et al.* (2000) and Cioli and Pica-Mattocchia (2003).

The effect of the broad spectrum antihelmintic drug Flubendazole on *S. mansoni* infection in mice was evaluated by Nessim *et al.*, (2000).

Combination of different chemotherapeutics was known long ago to obtain a better response with smaller doses of each drug, thus reducing the likelihood of side effects (Burger, 1970).

This work aimed to study the effect of different drugs (Praziquantel and Flubendazole) either alone or combined with each other as treatment of *S. mansoni* in experimentally infected mice using light microscopy.

MATERIALS and METHODS

I. Experimental infection of mice: (Standen, 1963)

This study was done using 60 albino mice weighing 25-30 gms. 8-9 weeks old. They were divided into 4 groups:

Group (1) 15 mice: each mouse was infected with 60 cercariae of *S. mansoni* and not received treatment (control).

Group (2) 15 mice: each mouse was infected with 60 cercariae, of *S. mansoni* and after 8 weeks the mice were treated with Flubendazole as a single oral dose (100 mg/kg body weight).

Group (3) 15 mice: Each mouse was infected with 60 cercariae of *S. mansoni* and after 8 weeks the mice were treated with Praziquantel in a single oral dose (300 mg/kg body weight).

Group (4) 15 mice: Each mouse was infected with 60 cercariae of *S. mansoni* and after 8 weeks the mice were treated with combination of both drugs (Praziquantel 150 mg/kg and Flubendazole 50 mg/kg). Both drugs were administrated orally using stomach tube.

5 mice were sacrificed from each group at 9, 10&11 weeks post infection (1, 2&3 weeks post treatment).

II. After 8 weeks post infection mice were subjected to the following:

- 1- Faecal examination for *S. mansoni* eggs by using the modified Kato technique (Katz *et al.*, 1970).
- 2- Worm load was determined by perfusion of liver portal vein, mesenteric veins separately (Smither & Terry, 1965). Worms were examined and sex was identified.
- 3- Staining of adult worms of *S. mansoni*: Adult worms were washed in saline, fixed in 70% alcohol and stained with acetic acid alum carmine.

RESULTS

Group 1: (Control)

The normal morphological characters of adult male and female are illustrated in (Fig.1&2).

Group (2.a): Treated by Flubendazole (100 mg/kg) and examined (1 W.P.T.):

Male: The effect is mainly on the tegument. The tubercles (T) are absent in some areas on the dorsal surface. The testes (ts) are not affected. The oral and ventral suckers (os,vs) appear flabby with loss of normal morphology (Fig. 3).

Female: The ovary (ov) appears narrow and short with average size (280 X 78 μ). The uterus (ut) is devoid from eggs or contains one. The vitelline glands (v.g.) appear normal to some extent (Fig. 4).

Group (2.b): Treated by Flubendazole (100 mg/kg) and examined after (2 W.P.T.):

The effect of Flubendazole on this group is the same as the previous group.

Group (2.c): Treated by Flubendazole (100 mg/kg) and examined after (3 W.P.T.):

Male: The effect of the drug showed the testes with abnormal distribution and the suckers are flabby (Fig. 5). The tegument showed decrease in number of tubercles on the dorsal surface (Fig.6).

Female: The ovaries appear narrower and shorter than the females in the previous group (the mean size is 250 X 62 μ). The intestine (int) is empty and the vitelline glands appear to be affected and atrophied (Fig.7).

Group (3.a): Treated by Praziquantel (300 mg/kg) and examined after (1 W.P.T.):

Male: The effect of Praziquantel appears mainly on the tegument with loss of most tubercles on the dorsal surface. The suckers are not affected. The testes show abnormality in their number and distribution (Fig.8, 9).

Female: The size of ovary is mildly affected (Fig.10).

Group (3.b): Treated by Praziquantel (300 mg/kg) and examined after (2 W.P.T.):

Male: The effect of Praziquantel is the same as the previous group.

Female: No female worms are found in this group.

Group (3.c): Treated by Praziquantel (300 mg/kg) and examined after (3 W.P.T.):

Male: The effect of Praziquantel on this group is the same as the previous group.

Female: No female worms are found in this group.

Group (4.a): Treated by combination of Flubendazole (50 mg/kg) and Praziquantel (150 mg/kg) and examined after (1 W.P.T.):

Male: The oral sucker for some extent shows loss of the normal morphology, the ventral sucker is destructed. The testes decrease in number (Fig.11). The effect appears on the tegument in the form of loss of tubercles in multiple areas of the dorsal surface (Fig.12).

Female: There is severe atrophy of the ovary, the average size (130 X 40 μ). The vitelline follicles disappear, the intestine appears empty from any pigments (Fig.13).

Group (4.b): Treated by combination of Flubendazole (50 mg/kg) and Praziquantel (150 mg/kg) and examined after (2 W.P.T.):

Male: The effect of combined drugs on this group is nearly the same as the previous group.

Female: No female worms are found in this group.

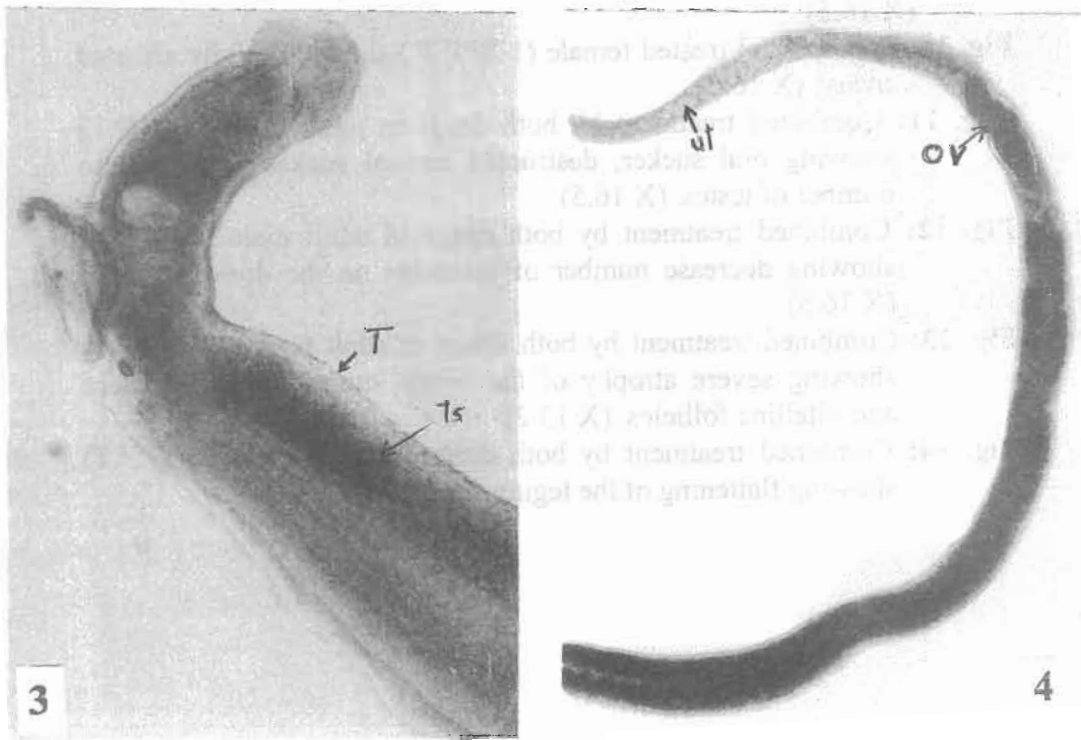
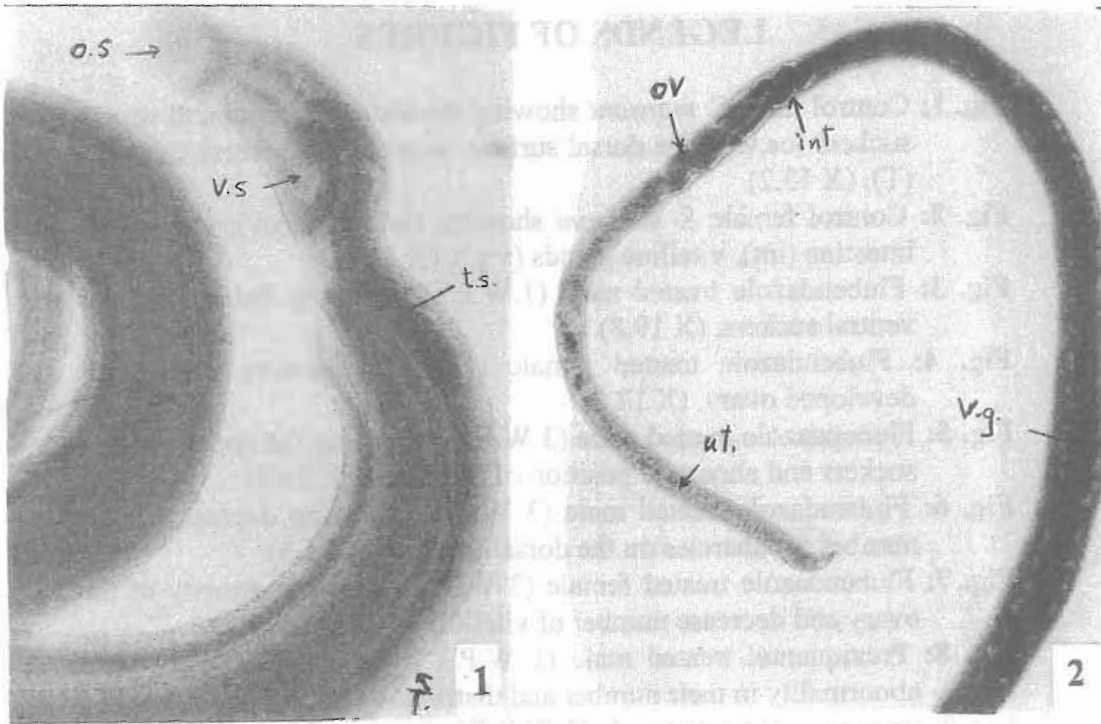
Group (4.c): Treated by combination of Flubendazole (50 mg/kg) and Praziquantel (150 mg/kg) and examined after (3 W.P.T.):

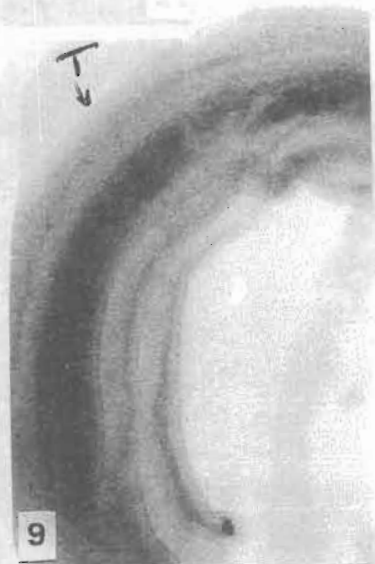
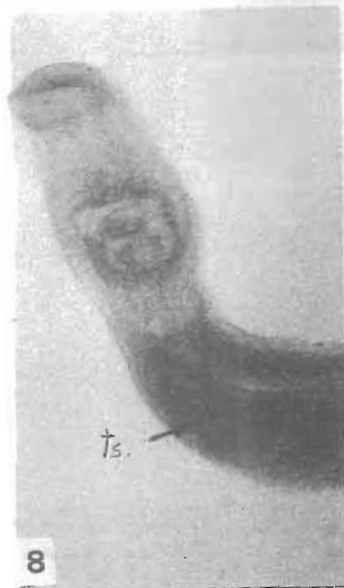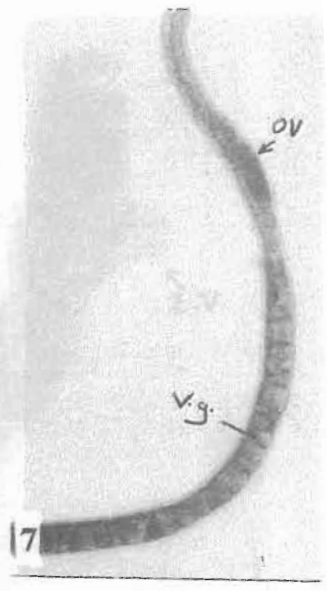

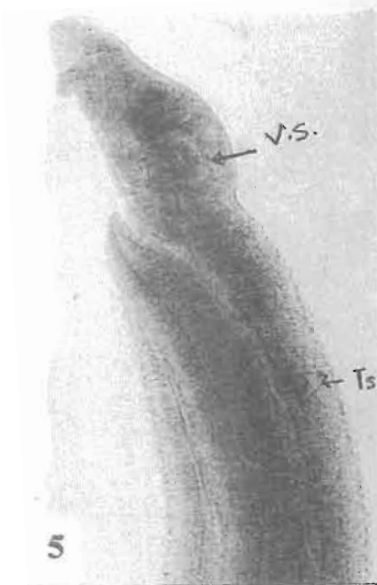
Male: There is marked flattening of the tegument and the testes showed abnormal distribution (Fig.14).

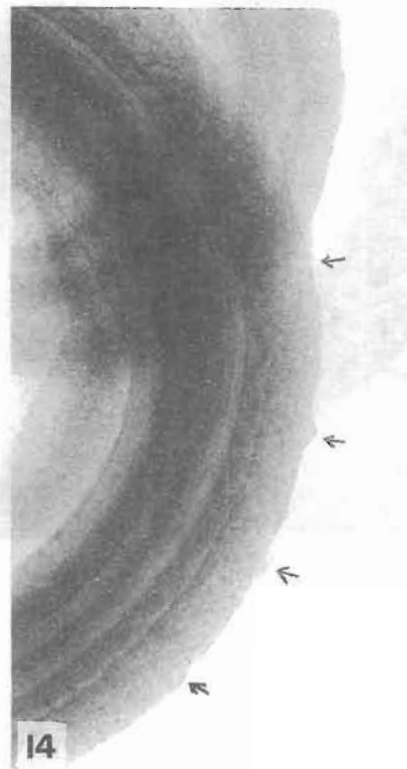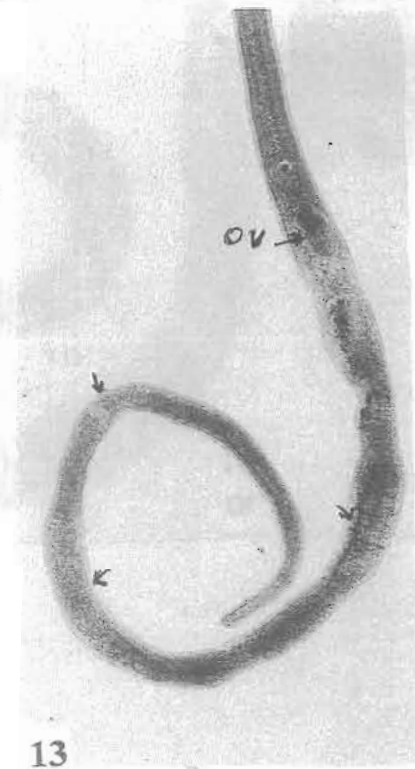
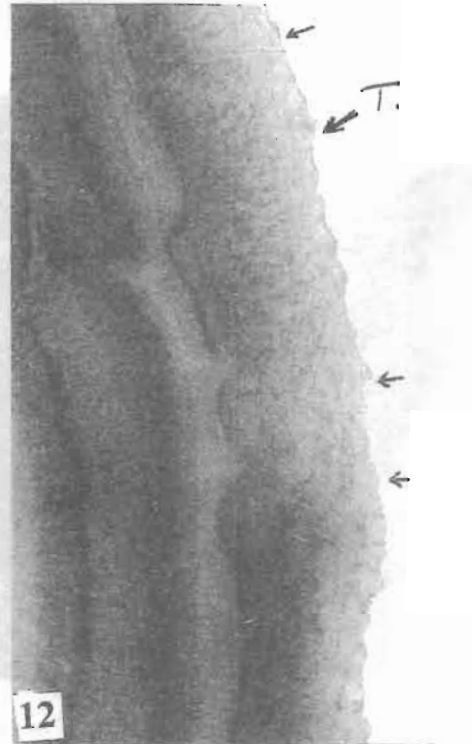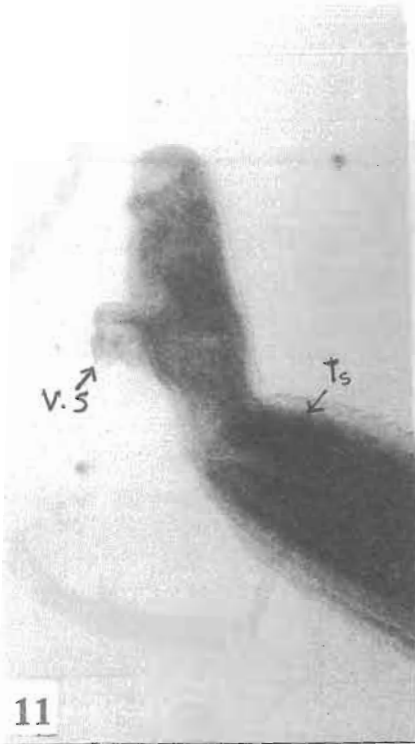
Female: No female worms are found in this group.

LEGENDS OF FIGURES

- Fig. 1:** Control male *S. mansoni* showing the testes (ts), oral and ventral suckers (os,vs). The dorsal surface is covered by coarse tubercles (T). (X 13.2)
- Fig. 2:** Control female *S. mansoni* showing the ovary (ov), uterus (ut), intestine (int), vitelline glands (v.g.). (X 13.2)
- Fig. 3:** Flubendazole treated male (1.W.P.T.) showing flabby oral and ventral suckers. (X 19.8)
- Fig. 4:** Flubendazole treated female (1W.P.T) showing moderately developed ovary. (X 13.2)
- Fig. 5:** Flubendazole treated male (3 W.P.T.) showing the appearance of suckers and abnormal position of the testes. (X 19.9)
- Fig. 6:** Flubendazole treated male (3 W.P.T.) showing decrease in the number of tubercles on the dorsal surface. (X 16.5)
- Fig. 7:** Flubendazole treated female (3 W.P.T.) showing atrophy of the ovary and decrease number of vitelline glands. (X 13.2)
- Fig. 8:** Praziquantel treated male (1 W.P.T.) showing the testes with abnormality in their number and distribution. (X 16.5)
- Fig. 9:** Praziquantel treated male (1 W.P.T.) showing flattened tegument. (X 16.5)
- Fig. 10:** Praziquantel treated female (1 W.P.T.) showing mildly affected ovary. (X 16.5)
- Fig. 11:** Combined treatment by both drugs in adult male (1 W.P.T) showing oral sucker, destructed ventral sucker and decrease number of testes. (X 16.5)
- Fig. 12:** Combined treatment by both drugs in adult male (1 W.P.T) showing decrease number of tubercles on the dorsal surface. (X 16.5)
- Fig. 13:** Combined treatment by both drugs in adult female (1 W.P.T) showing severe atrophy of the ovary, empty intestinal caeca and vitelline follicles. (X 13.2)
- Fig. 14:** Combined treatment by both drugs in adult male (3 W.P.T) showing flattening of the tegument. (X 33)







DISCUSSION

The morphological changes among recovered worms that received Flubendazole (100 mg/kg) are investigated for the first time by light microscope. Male worms showed absence or poorly developed tuberculation, flabby suckers and sometimes decrease the number of testes.

Female worms showed atrophy of the ovaries and vitelline follicles with empty intestine. These morphological changes were apparent after (1&3W.P.T.).

Similar results were obtained by Leroy *et al.* (1978) and Aboul-Atta *et al.* (1989) when using Oltipraz, which revealed damage of the reproductive organs especially of female worms with interruption of egg laying process.

Tadros *et al.* (1979) using Oxamniquine reported similar morphological changes in *S. mansoni* worms. The authors attributed these changes, to interference of Oxamniquine with the enzymatic activities of the worms or to the toxic effect of the drug on the gonads and vitelline glands. Otubanjo (1981) reported that Astiban produced testicular damage of male *S. mansoni* as a result of interference with the enzymatic activities of the worms, and also due to the interference with feeding.

The paralytic effect of Flubendazole was observed in the present work where the male suckers were affected. This agreed with Aboul-Atta *et al.*, (1989) who reported that Oltipraz showing paralysis on adult male and female *S. mansoni* manifested by affection of male suckers and empty intestine. In the present work, loss of cuticular tuberculation was detected in male worms. Tadros *et al.*, (1979) suggested that fragility of *S. mansoni* worms was due to reduction in the size of the worms together with the disturbed cuticle.

The morphological changes among recovered worms that received Praziquantel (300mg/kg body weight) were investigated by light microscope. Male worms showed absence or poorly developed tuberculation. Shuhua *et al.*, (2000) reported that treatment with Praziquantel, for 4 or 24 hours, caused tegumental damage to *S. mansoni*. Pax *et al.*, (1978) declared that Praziquantel produced marked spastic paralysis of male *S. mansoni* due to rapid rise in tension of musculature. They added that the drug could act by stimulating the uptake of sodium and inhibiting the uptake of potassium. Tadros *et al.*, (1979) reported hepatic shift of *S. mansoni* worms after Oxamniquine

therapy in infected mice. They attributed this to the paralysing effect of the drug on the musculature. They also added that the paralysis, seemingly affected on the attachment of the suckers and feeding process, which led to empty alimentary canals of both sexes.

Regarding adult females, the size of ovary was mildly affected after (1W.P.T.) while at (3W.P.T.) the females were completely absent. These results indicate the effect of the drug on the whole worm; similar results with Oltipraz were obtained by Leroy *et al.*, (1978).

As can be seen from our results, the effect of Flubendazole on suckers was more pronounced than that of Praziquantel. In the gynaecophoric canal both drugs had affected it. The effect on the tegument was more marked with Praziquantel than Flubendazole and for these reasons the combination of the two drugs have its importance.

In the present work, morphological changes of worms recovered after treatment with combination of Praziquantel and Flubendazole were examined for the first time by light microscope. The female worms showed severe atrophy of ovaries, the vitelline follicles disappeared and the intestines were unpigmented. At (3W.P.T.) the females were completely absent. These results indicate the effect of combined drugs on the whole worm especially the genital system. Male worms showed absent or poorly developed tuberculation. The ventral sucker was destructed and finally the testes showed abnormal distribution. Shaw and Brommer (1983) and Botros *et al.*, (1989) reported synergistic activity on adult *S. mansoni* treated by combined low doses of Praziquantel and Oxamniquone. The combination regimen was most effective 4 h post infection.

In this work, Praziquantel and Flubendazole were tested combined in doses equivalent to half the curative dose of each. These doses were chosen by the authors as being small enough to give moderate killing of schistosomes allowing any potentiating effect to be detected when both doses were given concurrently. At the same time it was not too small to have detectable effect.

The parasitological criteria used in assessment revealed that combined low doses of Praziquantel and Flubendazole were superior to either of the drugs alone in their full doses.

REFERENCES

- Aboul-Atta, M.A.; Hassan, Z.A. and El-Ahl, S.S. (1989):* Oltipraz treatment in experimental schistosomiasis mansoni induced by high dose oral therapy in mice. *J. Egypt. Soc. Parasitol.*, 19(1).
- Ismail M.M.; Farghaly, A.M.; Dyab, A.K.; Afify, H.A. and El-Shafei M.A. (2002):* Resistance to praziquantel, Effect on drug pressure and stability test. *J. Egypt. Soc. Parasitol.* 2002. Aug, 32(2): 589 – 600.
- Katz, N.; Coelho, P.M. and Pellegrino, J. (1970):* Evaluation of kato quantitative method through the recovery of *S. mansoni* eggs added to human faeces. *J. Parasitol.*, 56: 1032 – 1036.
- Leroy, J.P.; Barreau, M.; Cartel, C.; Jeanmart, C.; Meser, M. and Benazet, F. (1978):* Laboratory studies of 35972 RP, a new schistosomocidal compound. Current chemotherapy (W. Ciegenthaler and R. Luthy, eds.) In: proceed 10th Int. Congr. Chemotherapy 1, Am. Soc. Microbiol. Washington, D.C. 148–150.
- Mansoury, S.T. (1997):* Effect of two trematocidal drugs on the morphology and tegumentary ultrastructure of *Schistosoma mansoni*. *J. Egypt. Soc. Parasitol.*, 27(1): 233 – 241.
- Marshall, I. (1995):* Schistosomiasis. In: Gillespie & Hawkey (Ed). *Medical Parasitology, a practical approach.* Oxford University Press, Oxford New York, 191 – 208.
- Pax, R.; Bennett, J.L. and Fetterer, R. (1978):* Abenzo-diazepine derivative and praziquantel: Effects on musculature of *S. mansoni* and *S. japonicum*. *Naunyn-Schmiedeberg's Arch. Pharmacol.* 304: 309 – 315.
- Shalaby, I.M.; Banaja, A.A. and Ghandour, A.M. (1991):* Scanning electron microscopy of the tegumental surface in vivo treated *Schistosoma mansoni* Saudi-Arabian geographical strain with Oxamniquine and Praziquantel. *J. Egypt. Soc. Parasitol.*, 21(3): 397 – 810.
- Shuhua, X.B.; Binggu, S.; Chollet, J. and Tannor, M. (2000):* Tegumental changes in Adult *Schistosoma mansoni* harboured in mice treated with praziquantel enantiomers. *Acta Trop.*, 18. 76(2): 107 – 117.
- Smithers, S.R. and Terry, R.J. (1965):* The infection of laboratory hosts with cercariae of *S. mansoni* and the recovery of adult worms. *J. Parasitol.*, 55: 695 – 700.

- Standen, O.D. (1963):* Experimental infection of mice. The role of snail antigens in the immunity of schistosomiasis of albino mice. Ms thesis, Med. Lab.Nation. Research Center, Cairo.
- Tadros, M.B.; Mikhail, E.G. and Gaber, A. (1979):* Changes in the structure of *S. mansoni* worms induced by oral oxamniquine therapy in experimental animals. J. Egypt. Soc. Parasitol. 9: 25 – 37.
- Webbe, G. and Jordan, P. (1993):* Control. In: Jordan P., Webbe g., Sturrock. R.F. (eds), Human Schistosomiasis CAB International, UK, p. 405 – 452.
- Younis, T.A. and Khalil, H.H. (1998):* Chemotherapy of schistosomiasis present and past. J. Egypt. Soc. Parasitology, Vol. 28, No. 1, April, 293 – 299.