

Department of Parasitology,
Animal Health Research Institute, Dokki, Giza.

**STUDY ON SOME PARASITES AFFECTING HOUSE
SPARROWS *PASSER DOMESTICUS NILOTICUS*
IN CAIRO GOVERNORATE, EGYPT**

(With 2 Tables and 4 Figures)

By

OMIMA A. IBRAHIM

(Received at 11/3/2006)

دراسة لبعض الطفيليات التي تصيب العصافير في محافظة القاهرة - مصر

أميمة إبراهيم أحمد

أجريت هذه الدراسة لتحديد معدل ووصف الطفيليات التي تصيب عدد ١٧٩ عصفورة تم اصطيادهم من أماكن مختلفة من محافظة القاهرة. وقد كان المعدل العام للإصابة بالطفيليات في هذه العصافير ٦٦,٥%. وأوضحت الدراسة أن الديدان الشريطية كانت أكثر الطفيليات إنتشاراً ٣٢,٤% تليها الأوليات المعوية ٢٩,١% ثم أوليات الدم ١٨,٩%. وقد سجلت هذه الدراسة نوعين من الديدان الشريطية وهي اليتينا إيكينوبثريدا ٢٥,٧% وكتوتينيا أنفانديبولم ٦,٧% إلى جانب نوع من الأوليات المعوية وهي الأيزوسبورا إجبينتيا ونوع آخر من أوليات الدم وهي هيموبروتيس باسريس ١٨,٩%.

SUMMARY

This study was done to determine the prevalence and description of parasites infesting 179 house sparrows (*Passer domesticus niloticus*) randomly captured from different localities in Cairo Governorate. The allover rate of parasitic infestation among the examined sparrows was 66.5%. The present investigation revealed that cestodes were the highest prevalent parasites (32.4%) followed by enteric protozoa (29.1%) and finally blood protozoa (18.9%). These sparrows were found to be infested with two species of cestodes which were *R. echinobothrida* (25.7%) and *C. infundibulum* (6.7%). Moreover, one species of enteric protozoa was *Isospora egyptia* (29.1%) and one species of blood protozoa was *Haemoproteus passeris* (18.9%).

Key words: *Parasitology, parasites, sparrows, passer domesticus niloticus.*

INTRODUCTION

House sparrows *Passer domesticus niloticus* are well known to be the most abundant resident free living birds in Egyptian town and villages. Like other birds house sparrows could be infected with large number of parasitic diseases. Beside their natural existence between some domestic birds outdoors and the flying ones as pigeons on trees, in grain stores and inside the pigeon lofts, they can easily enter different poultry farms by the aid of its small size. By this way infected house sparrows could be a source of parasitic infection to these birds by direct or indirect means. For this reasons, they may be act as a disseminator of parasites among wild and domestic birds when they come in contact with them (Badawy, 2000).

The present investigation was achieved to study the parasites infesting house sparrows at Cairo Governorate with regard to their prevalence, taxonomy and the role played by these sparrows in transmitting some parasitic infection to the domesticated birds.

MATERIALS and METHODS

One hundred and seventy nine house sparrows *Passer domesticus niloticus* were randomly captured from different localities in Cairo Governorate.

External examination of each bird was carried out, the feathers and unfeathered parts of the body of each sparrow were inspected by naked eyes with the aid of a hand lens and bright light for external parasite.

Blood smears were obtained from wing vein of each alive bird and from the heart blood of the freshly sacrificed one. The smear were dried, fixed, stained with Giemsa stain and examined by the oil immersion lens for detection of blood parasites. The recorded parasites were identified according to Levine (1985).

The crop, proventriculus, gizzard, intestine and trachea of each bird were thoroughly examined for the presence of helminths either macroscopically or microscopically. The obtained helminths were washed, fixed and mounted according to Kruse and Pritchard (1982). The specimens were identified according to Wardle and Mcleod (1952) and Yamaguti (1961).

Mucosal scrapping from the different parts of the intestine as well as the intestinal contents were collected from each sparrow and examined for the detection of the enteric protozoa by preparation of

unstained fresh smears either directly with one drop of normal saline or by concentration flotation technique, therefore, for sporulation unsporulated oocysts incubated in a clean glass Petri-dish containing 2.5% solution of potassium dichromate at 27°C (Levine 1985). Moreover, for the detection of *Cryptosporidium* species, mucosal scraping smears from the conjunctiva, nasal sinuses, trachea, different parts of the intestine (duodenum, jejunum, ileum, colon and cloaca) and bursa of fabricius when found were stained with the modified Ziel-Neelsen staining technique and examined under the oil immersion lens (Henriksen and Pohlenz, (1981).

RESULTS

The present study was carried out on 179 house sparrows *Passer domesticus niloticus* examined for ectoparasites, helminths and protozoa (blood and enteric protozoa).

External examination revealed that all birds were negative for ectoparasites.

Table (1) shows that the over all incidence of parasitic infestation in the examined sparrows was 66.5% (119 out of 179) which was classified as 52.5% (94 out of 179) single infection while, 14% (25 out of 179) mixed infection. These examined sparrows were found to be infected with helminths mainly cestodes 32.4% (58 out of 179) and the protozoa 48% (86 out of 179) classified into enteric protozoa 29.1% (52 out of 179) and blood protozoa 18.9% (34 out of 179).

The results in table (2) show that the rate of cestodes infection was the highest one among the recorded parasites (32.4%). There were two species of cestodes identified as *Raillietina echinobothrida* 25.7% (46 out of 179) and *Choanotaenia infundibulum* 6.7% (12 out of 179). As well exhibits that *Isospora species* was the only enteric protozoa detected in the present study with an infection rate of 29.1% (52 out of 179). On the other hand, no *Cryptosporidium* were found in any stained mucosal scraping smears. The blood protozoa recovered from this investigation was *Haemoprotus species* 18.9% (34 out of 179).

***Raillietina echinobothrida* (Megnin, 1981):-**

These worms were collected from the small intestine, were robust worms. The scolex had four rounded suckers with 8-15 rows of hooks. The rostellum was large containing more than 200 hooks in tow rows (Fig. 1a). Mature segment was broader than longer. The genital pore was in the posterior half of the segment. The cirrus sac was large and best seen in the mature segment. The testes arranged in median and

surrounding the genital gland (Fig. 1b). The gravid segment in which the eggs were found in egg capsules with 6-12 eggs per each (Fig. 1c).

Choanotaenia infundibulum (Bloch, 1779):-

These tape worms were white in colour collected from the small intestine. The scolex was triangular with pointed anterior end containing distinct rostellum armed with a single row of about 18 large hooks (Fig. 2a). Mature segment was bell-shaped. The genital pore was irregularly alternate at the anterior third of the segment (Fig. 2b). The gravid proglottid was longer than broader and the uterus broke up to egg capsules, each one contained single. The gravid proglottid was characterized by two distinctive elongated filaments at two poles of the segment (Fig. 2 c).

Isospora species:-

The oocysts was identified as *I. passerum* (Scholtyseck, 1954). The unsporulated oocysts were spherical or semispherical in shape with double wall measuring 18-27 μ (average 23.8 μ) (Fig 3a). There were no micropyle or oocyst residual body in the sporulated one which had two pear shaped sporocysts with 4 sporozoites (Fig 3b) and sporulation time was 24 hours.

As well, *Haemoproteus species* (Kruse, 1890) were detected in blood film. They were elongated or sausage-shaped with variable numbers of dark pigment granules, partially encircled the host cell nucleus (Fig. 4).

Table 1: Infestation rates of the different types of parasites recovered from examined sparrows.

Number of examined birds		179	
	Infested birds	No.	119
		%	66.5
Birds have single infection	Total	No.	94
		%	52.5
	Cestodes	No.	39
		%	21.8
	Enteric protozoa	No.	37
		%	20.7
	Blood protozoa	No.	18
		%	10.1
Birds have mixed infection	Total	No.	25
		%	14
	Cestodes & enteric protozoa	No.	9
		%	5
	Blood & enteric protozoa	No.	6
		%	3.4
	Blood protozoa & cestodes	No.	10
		%	5.6

Table 2: Prevalence of different species detected among the examined house sparrows.

Parasitic species	No. of infested birds	%
* Cestodes	58	32.4
<i>R. echinobothrids</i>	46	25.7
<i>Choanotaenia infundibulum</i>	12	6.7
*Protozoa	86	48
Enteric protozoa (<i>Isospora</i>)	52	29.1
Blood protozoa (<i>Haemoproteus</i>)	34	18.9

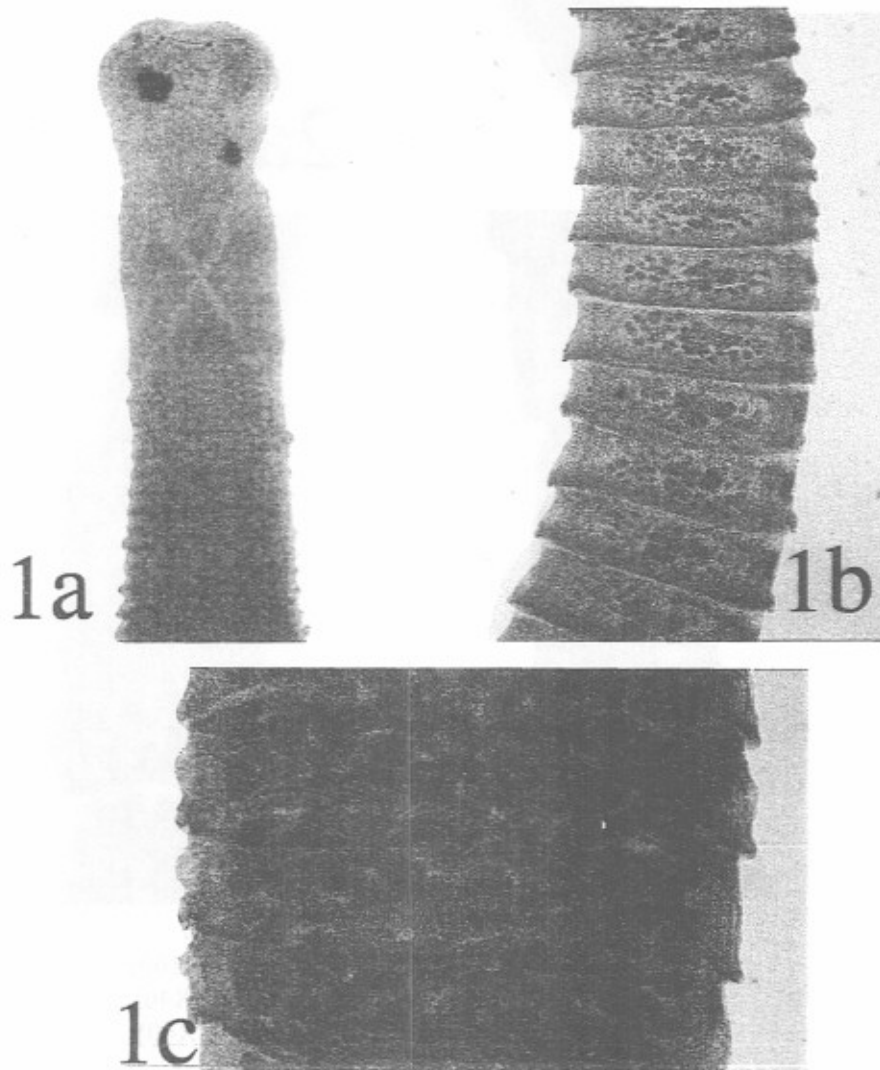


Fig. 1: *Raillietina echinobothrids*
a- Scolex (X160) b- Mature segment (X40) c- Gravid segment (X40)




Fig. 2: *Choamotaenia infundibulum*

- | | |
|-------------------|--------|
| a- Scolex | (X160) |
| b- Mature segment | (X40) |
| c- Gravid segment | (X40) |

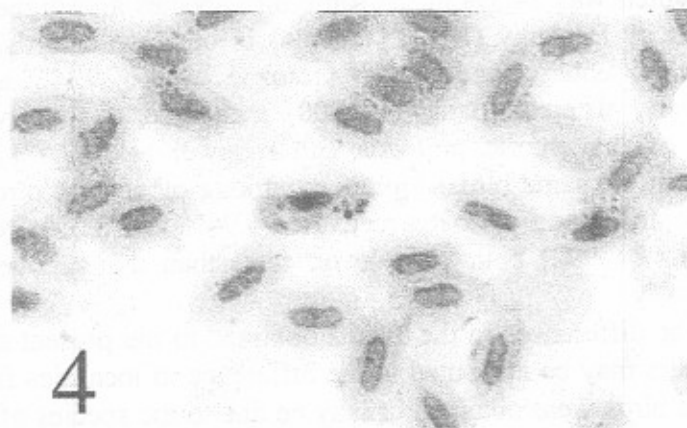
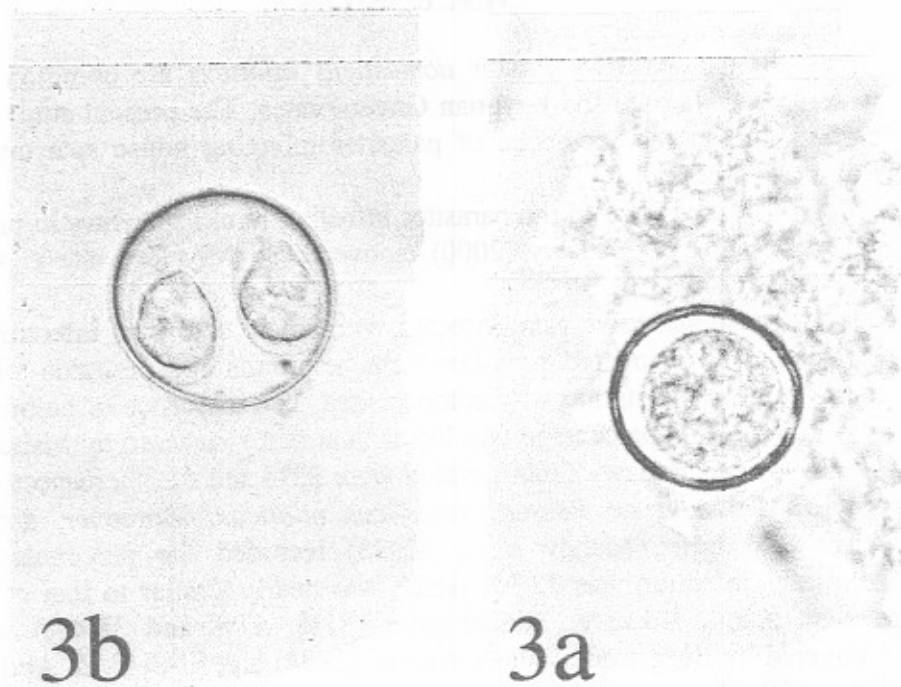


Fig. 3: *Isospora aegyptia*

- a- Unsporulated oocyst (X1000)
- b- Sporulated oocyst (X1000)

Fig. 4: *Haemproteus passeris* (X1000)

DISCUSSION

House sparrows *Passer domesticus niloticus* are common and wide spread through the Egyptian Governorates. The present study was carried out on the incidence of parasites infecting house sparrows at Cairo Governorate.

The incidence of the parasites infecting house sparrows in present study was 66.5%. Badawy (2000) recovered slightly low rate at Giza Governorate (64.3%).

These sparrows were infected with single or mixed infection of parasites. The recovered parasites were helminths and protozoa while, there were no infestation with ectoparasites. The incidence of helminths was 32.4%. This percentage was lower than that recovered by Mahdy *et al.* (1994) and Badawy (2000) which were 35% and 41.3% respectively at Giza Governorate *Passer domesticus niloticus*. Moreover, among other wild birds, Mahdy *et al.* (1995) recorded the percentage of helminths infection was 32.3% which was nearly similar to that of the present study. However, higher rates (81%, 57% and 38.4%) were recovered by Borgsteade (1989), Ahmed (1994) and El-Seify & Abd El-Fattah (1996) respectively.

The incidence of protozoa infecting house sparrows in the present investigation (48%) was higher than that recovered by Badawy (2000) which was 34.5% in the same bird species and higher than that recovered by Desouky (1992) (15.28%) in other wild birds. Likewise, the rate of enteric and blood protozoa were 29.1% and 18.9% respectively, whereas Badawy (2000) recovered a slightly low rate (26.8%) of the enteric protozoa and a lower rate (7.7%) of blood protozoa in the same birds. Moreover, among other wild birds, the rate of enteric and blood protozoa recovered 6.94% and 8.33% respectively by Desouky (1992) both were lower rates than that recovered in the present study.

The differences in the results obtained in the present studies and those others may be attributed to the difference in localities from where examined birds were obtained or may be due to the species of examined birds.

Two species of cestodes were recovered in the present study, *Raillietina echnobothrida* and *Choanotaenia infundibulum* with infection rates of 25.7% and 6.7% respectively. Their morphological characteristics coincided with that mentioned by Wardle and Mclead (1952). The first species has been considered the most pathogenic tape

worms infecting chicken, while the second one has low pathogenicity and the house sparrows could be considered as disseminator of them to chickens.

Concerning the enteric protozoa, the recovered *Isospora species* in the present investigation agreed morphologically with that of *I. passerum* (Scholtyseck, 1954) and *I. aegyptia* (Abd EL-Aal, 1981). Since most *Isospora species* unlike *Eimeria* are not specific (Petraik, 1982), house sparrows may be a source of *Isospora* infection to the domesticated birds as well as the wild ones.

Peirce (1976) recovered *Passerine haemoproteids* in *Passer domesticus niloticus* he referred it as *Haemoproteus passeris*. For this the *Haemoproteus species* recovered in the present study belonged to *H. passeris* as known, the species of *Haemoproteus* are family specific, hence the recovered parasite could be transmitted only to all birds of the same family (*Passeriforms*).

We could concluded from the present investigation that house sparrows could be infected with several species of parasites, some of which were recovered before from the domesticated birds and others either were not host specific or has wide host range. This clearly exhibited that house sparrows could play an important role in the transmission, spreading and epidemiology of certain parasitic diseases to the domesticated birds throughout their wide uncontrolled existence and contact with them, especially, in poultry farms and pigeon lofts. A great attention should be paid by the farmers and owners of poultry farms to control their existence and contact with birds and their relations.

REFERENCES

- Abd El-Aal, Z. (1981):* Studies on certain protozoan parasites of the common house sparrows in Egypt. M. V. Sc. Thesis, Fac. of Sci. Ain Shams Univ.
- Ahmed, M.M. (1994):* Helminth parasites of some wild birds. M. V. Sc. Thesis, (parasitology), Fac. Vet. Med. Zagazig Univ.
- Badawy, B.A. (2000):* House sparrows (*passer domesticus niloticus*) as a source of some parasitic diseases to the domesticated birds at Giza Governorate, Egypt, Assiut Vet. Med. J. 42 (84).
- Bloch, M. (1779):* Cited by Reid, W. M. (1991): Cestodes and Trematodes In: Diseases of Poultry. 9th ed., 1991, B. W. Calnek (Ed.) Iowa State Univ. Press, Ames, Iowa, USA.

- Borgsteed, F.H.M. (1989):* Helminth parasites of wild birds in the Netherland. 2nd Europ. Symp. Avian Med. Surg. (March, 8-11, Utrsch Netherland).
- Desouky, A.A. (1992):* Protozoal parasites of some wild birds. M. V. Thesis, Fac. Vet. Med., Zagazig Univ.
- El-Seify, M.A. and Abd El-Fattah, M. (1996):* Some studies on helminths of wild birds in Kafr El-Sheikh Governorate, Egypt. 7th Sci. Cong. 17-19 Nov. Fac. Vet. Med., Assiut Egypt 314-356.
- Hassan, M.G. and Abd El-Aal, A.A. (1999):* Studies on helminth parasites infesting some wild birds in Suez Canal area and Sini. Peninsula. Assiut Vet. Med. J., 40 (80): 107-118.
- Heriksen, S.A. and Pohlenz, J.E.L. (1981):* Staining of Cryptosporidia by a modified of Ziel-Neelsen technique. Act. Vet. Scand, 22,; 594-596.
- Kruse, W. (1890):* Cited by Desouky, A. A. Y. (1992): Protozoal parasites of some wild birds. M. V. Sc. Thesis, Fac. Vet. Med., Zagazig Univ.
- Kruse, G.O.W. and Pritchard, M.H. (1982):* The collection and preservation of animal parasites. University Ob. Nebraska Press, Nebraska, USA.
- Livine, N.D. (1985):* Veterinary protozoology. 1st Ed. Ames, Iowa State University Press.
- Mahdy, O.A.; Mousa, W.M. and Negam El-Din, M.M. (1994):* Some helminth parasites of domestic sparrow (*Passer domesticus nilotica*) at Giza province, Egypt. J. Egypt Vet. Med. Assoc., 54 (1): 31-40.
- Mahdy, O.A.; Badawy, B.A. and El-Assaly, T.N. (1995):* Studies on some helminths infesting pigeons (*Columba livia domestica*) and doves (*Streptopelis serngaleniss aegyptiancea*) with a record of a new species of Houttuynia at Giza, Egypt. Beni Suef Vet. Med. Res. 5: 103-116.
- Megnin, L. (1881):* Cited by Reid, W.M. (1991): Cestodes and Trematodes: In: Diseases of Poultry. 9th ed., 1991, B. W. Calenk (Ed.), Iowa State University Press, Ames, Iowa, USA.
- Peirce, M.A. (1976):* Haemoproteid parasites of Passer species. Parasitology, 73: 407-415.
- Petrak, M.L. (1982):* Diseases of cage aviary birds. 2nd Ed. LEA and Febriger Philadelphia USA.

- Scholtzseck, E. (1954):* Untersuchungen über die bei einheimischen vogelartigen vorkommen den coccidien der Gattung Isospora. Arch. Protistenk., 100: 91-112.
- Wardle, R.A. and McLeod, J.A. (1952):* The zoology of tape worms. Published for the University of Manitoba by the University of Congress Catalog Card Number 52-5324.
- Yamaguti, S. (1961):* Systema helminthum vol. III parts I and II. The nematodes of Vertebrates. Interscience Publ. New York.