

Dept. of Surgery,
Fac. Vet. Med., Assiut University.

OTOSCOPY IS A GOOD TECHNIQUE FOR DIAGNOSIS OF EAR DISEASES IN SMALL ANIMALS

(With 12 Figures)

By

MAGDA M. ALI

(Received at 8/3/2007)

تنظير الأذن تقنية حديثة لتشخيص أمراض الأذن في الحيوانات الصغيرة

ماجدة محمود على

هدفت هذه الدراسة الى إلقاء الضوء على استخدام منظار الأذن في الحيوانات الصغيرة لمعرفة الشكل المنظاري الطبيعي والباثوأكلينيكي لأجزاء الأذن المختلفة، بالإضافة إلى مقارنة استخدام منظار الأذن مع الأشعة كطريقة أخرى لفحص الأذن. وقد أجريت هذه الدراسة على عدد عشرة حيوانات سليمة بالنسبة لاصابات الأذن وعشرون حيوانا مصابا ظهرت عليهم أعراض مرضية بالأذن مثل خروج إفرازات من الأذن، آلام، هز للرأس وحكة بمنطقة الأذن. فحصت كل الحيوانات تحت تأثير التخدير الكلي وتم إجراء فحص بالأشعة للأذن قبل الفحص المنظاري، أجرى الفحص الإشعاعي لمنطقة الأذن في اتجاه شعاعي أمامي خلفي والفم مفتوح وكذلك آخر جانبي، وقد أظهر هذا الفحص تغيير في شكل وزيادة في سمك جدار الأذن الداخلية في الحيوانات المصابة. أما التنظير فتم إجراؤه والحيوان في وضع جانبي وقد أمكن فحص شكل ولون جدار الأذن الخارجية بالإضافة إلى فحص طبلة الأذن من حيث الشكل واللون والسمك في الحيوانات السليمة والمصابة وقد أفاد استخدام منظار الأذن في إزالة الإفرازات في حالات التهابات الأذن. وقد تميز جدار الأذن الخارجية باللون الوردى مع وجود بعض الشعر داخل قناة الأذن، وظهرت طبلة الأذن كجدار رقيق شفاف يفصل الأذن الخارجية عن الأذن الوسطى في الحيوانات السليمة. أما في الحيوانات المصابة فقد أظهرت الدراسة امكانية استخدام منظار الأذن لتشخيص التهابات الأذن الخارجية والوسطى، تشخيص وإزالة الأجسام الغريبة من الأذن، هذا بالإضافة إلى تشخيص حالات حلم الأذن في القطط. وقد خلصت هذه الدراسة إلى أن استخدام منظار الأذن يعد وسيلة جيدة وفعالة عن الفحص بالأشعة العادية وذلك لإمكانية توصيف الشكل الطبيعي، تشخيص العديد من أمراض الأذن، وكذلك استخدامه في إزالة الأجسام الغريبة من قناة الأذن

SUMMARY

The present study aimed to illustrate the normal and pathological otoscopic appearance of the different ear structures and to compare otoscopy with radiography in their efficient use as diagnostic methods for ear diseases. The present study was performed on 10 healthy animals admitted to the clinic for other surgical affections (5 dogs and 5 cats) and 20 patients (10 Dogs and 10 cats), which showed clinical signs of

ear diseases such as aural exudates, pain, shaking the head and rubbing the ear. All animals were examined under the effect of general anesthesia. Radiography was done only in diseased cases but otoscopy was performed in both healthy and diseased animals. Radiographic changes in the interior bulla (Osseous bulla) were clear only in 9 animals. These changes varied according to the disease from radiodensity to complete replacement of the tympanic cavity with bone. Otoscopy of healthy animals showed that the ear canal was covered with glistening rose-red cutaneous layer, which contained hair in some dogs. The tympanic membrane was thin transparent glistening membrane, separating the horizontal portion of the external ear canal from the tympanic cavity. However, otoscopy of diseased animals was helpful in diagnosis of otitis externa, otitis media, enlarged sebaceous glands, ear mite, and also for diagnosis and removal of foreign bodies from the ear canal. Otoscopy could not be done in cases with chronic otitis externa and complete obstruction of the external ear canal with polyps. In comparison to radiography, otoscopy was more accurate in diagnosis of ear diseases and in examination of the tympanic membrane. This in addition to removal of foreign bodies from the ear, irrigation of the ear, removal of exudates and debris, which help in treatment.

Key words: *Endoscopy, ear, otitis, small animals*

INTRODUCTION

Managing certain types of ear diseases can be a frustrating experience. Failed therapy, however, often follows false diagnosis. An accurate diagnosis leading to effective management of ear diseases is not simple task. It requires good information about anatomy of the ear, obtaining a complete history, performing complete physical examination and proper sampling for microbiological and histopathological examinations (Bardavid, 1999).

Inflammation of the external ear canal (otitis externa), is one of the most common problems that small practitioners face. Chronic or neglected cases often lead to otitis media, which has been reported to occur in as many as half of the patients already affected with chronic otitis externa (Woody and Fox, 1986 b., Little *et al.*, 1991, Gotthelf 2000 and Shell, 2000). Radiographic changes of the osseous bulla are helpful in establishing a diagnosis of otitis media. However, these changes may occur later and in a patient affected with acute otitis media, the radiographic view may appear normal. Radiography can not give information about the intensity of the tympanic membrane and is not

helpful in diagnosis of otitis externa (Seim, 1993). Neoplasia of the middle ear and inflammatory polyps were seen otoscopically by Seim (1993) and could not be diagnosed radiographically.

The use of video-otoscopy for diagnosis of otitis in small animals is a new diagnostic technique, and can also be successfully used to obtain proper samples from the depth of the ear canal or the tympanic membrane for microbiological and histopathological examinations (Little and Lane, 1989, Kraft, 1993 and Gotthelf, 2000).

The present study was conducted to examine the ears of healthy and diseased dogs and cats by using otoscopy and to compare this technique with radiography as another diagnostic method.

MATERIALS and METHODS

The present study was carried out on 10 healthy animals (5 dogs and 5 cats) which were admitted to the clinic for other affections than ear diseases and 20 patients (10 Dogs and 10 cats). All patients were presented with clinical signs of ear diseases such as aural exudates, pain, shaking the head and rubbing the ear. All animals were anaesthetized before examination.

Anaesthesia

In dogs, premedication was made with atropine sulphate 0,05 mg/kg i.v., and Diazepam 1,0 mg/ kg i.v. Induction of anaesthesia was done using ketamine 3,0 mg/kg i.v., and xylazine 0,3 mg/kg i.v. However, in cats premedication was done with Tilest[®] 500 in a dose rate of 10 mg/kg i. m. and Atropine sulfate[®] 0,3-0,05 mg/kg i.v. Induction was made with ketamine 5 mg/kg i.m. and xylazine 1 mg/kg i.m.

Endoscopic examination

After induction of anaesthesia, the animal was lied on lateral recumbency with the ear to be examined upward. The ear pinna was slightly stretched to allow straightening of the ear canal. The otoscope (Richard Wolf Medical Instruments) was slowly and carefully introduced into the vertical ear canal. At the binding site of the vertical ear canal into the horizontal one, the pinna was more stretched to allow easy entrance of the otoscope deeply for examination of the tympanic membrane.

In some diseased cases, which contained a lot of exudates in the ear canal, which obscure vision of the tympanic membrane, the ear canal was first gently irrigated with warm water or saline to remove the exudates and debris. In diseased cases with narrowing of the ear canal especially in cats an 0°, 2,7 mm \odot endoscope was used in examination

of the ear canal. Oral and pharyngeal examinations was performed with an 110° endoscope (Richard Wolf Medical Instruments) were performed to rule out an abscess or mass associated with eustacian tube.

Radiographic examination

Radiography was performed only in diseased animals. Three radiographic projections (Lateral, ventro-dorsal and with opened mouth) were made for each animal. The radiographs were taken with patient anaesthetized and the skull was protected.

RESULTS

Normal otoscopic appearance

The external ear canal appeared otoscopically in healthy animals rose red in color, glistening and contains hair in some dogs. It has a funnel shape, which narrowed distally (Fig. 1). The tympanic membrane (ear drum) separated the external ear from the middle ear. It was transparent, glistening membrane, thin in the center and thick peripherally. The loose pars flaccida appeared otoscopically opaque, pink or white with small branching blood vessels. The outline of the manubrium of the malleus was visible through the tympanic membrane (Fig. 2).

Diseased animals

Radiography

In the 20 patients radiography was made to examine the ear canal and the osseous bulla before otoscopy. In 11 patients (6 dogs and 5 cats) of the examined patients, there were no clear radiographic changes in the ear canal and/or the osseous bulla. In 4 patients (2 dogs and 2 cats), which were suffering from sever otitis externa, and otitis media radiographic examination of the ear revealed presence of radiodense tympanic cavity and ear canal (Fig. 3). In 5 patients (2 dogs and 3 cats), which were suffering from chronic otitis extrena with extension of inflammation to the middle ear, the ear canal and tympanic cavity were completely replaced with bone (Fig. 4). Evaluation of the tympanic membrane radiographically was not available in all examined patients.

Otoscopy

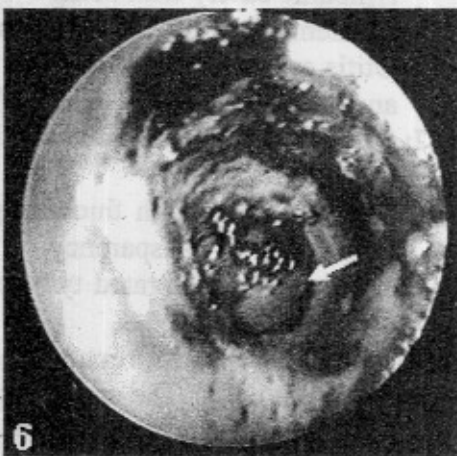
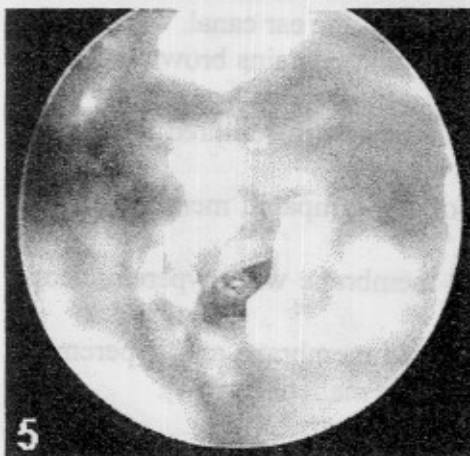
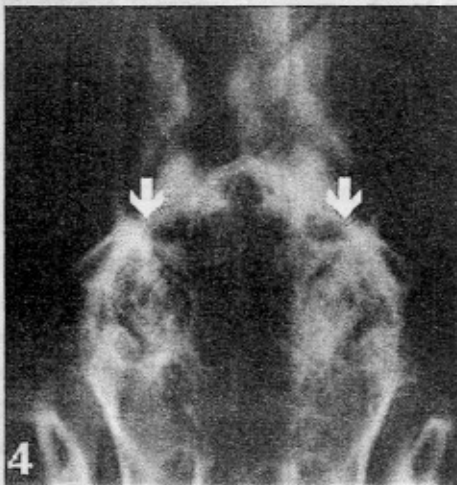
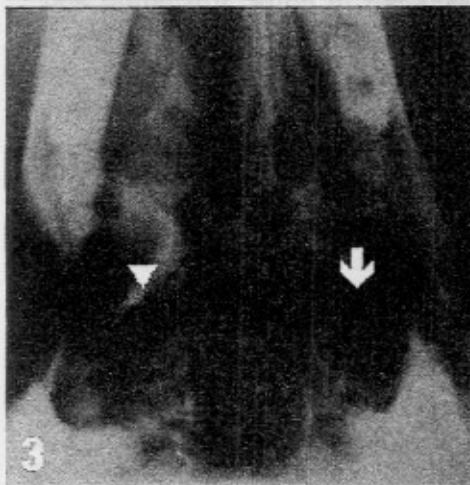
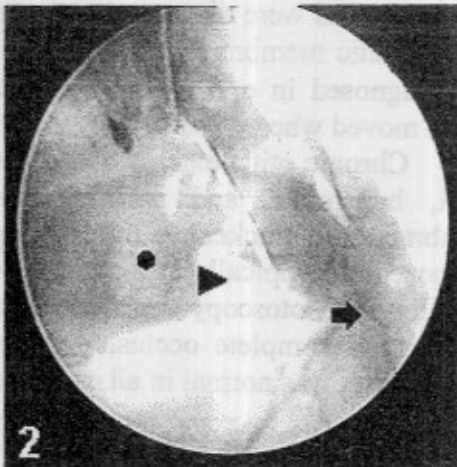
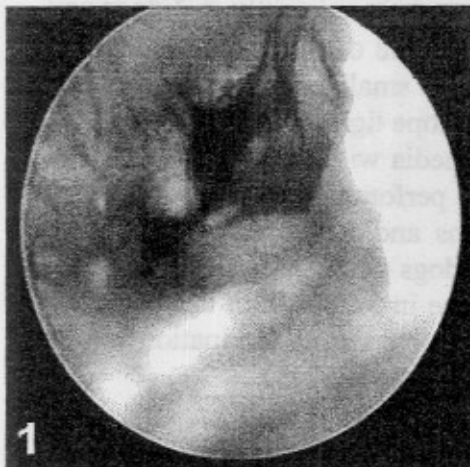
All examined animals which showed clinical signs of ear diseases, contained pathologic changes otoscopically. In the 11 animals which showed no radiographic changes, there were acute otitis externa and otitis media in 7 patients (5 dogs and 2 cats). The ear canals of these animals were filled with exudates which varied from creamy purulent to brown colored (Fig. 5& 6). The tympanic membrane was perforated in 6 patients (Fig. 7) and inflamed and thickened in 2 patients (Fig. 8).

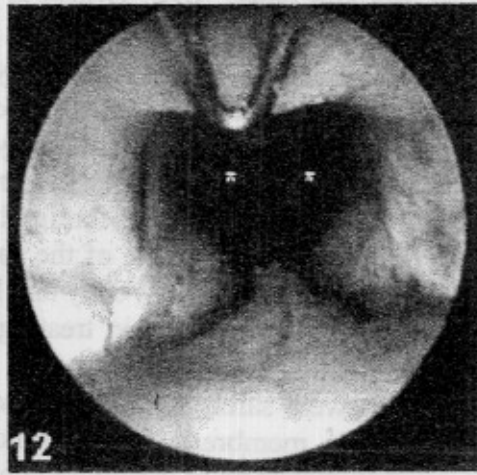
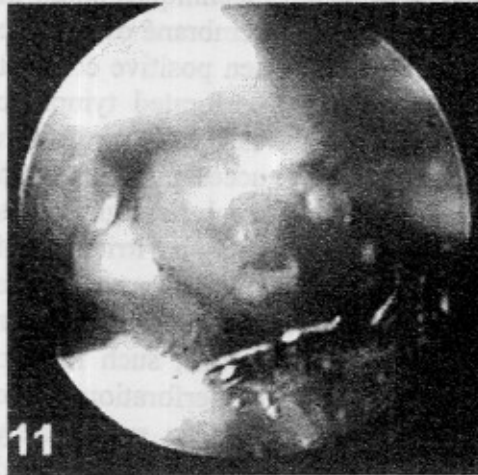
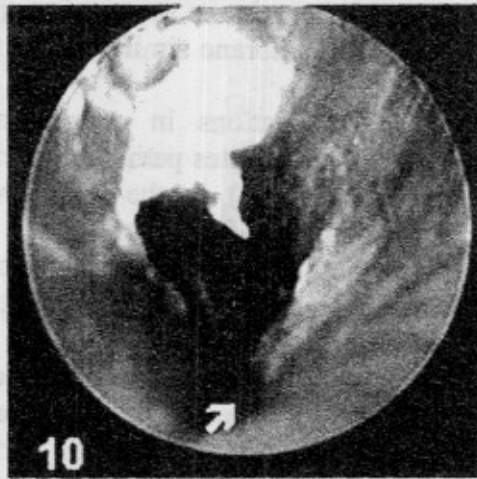
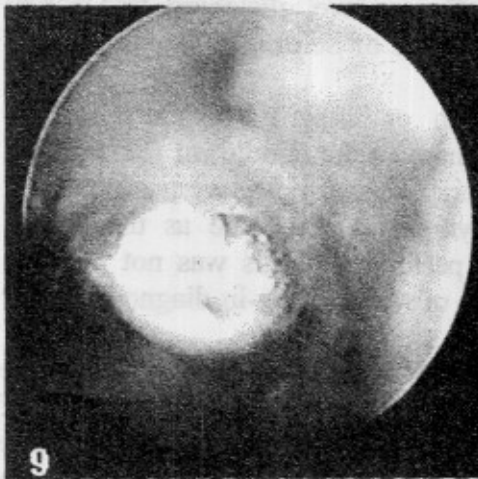
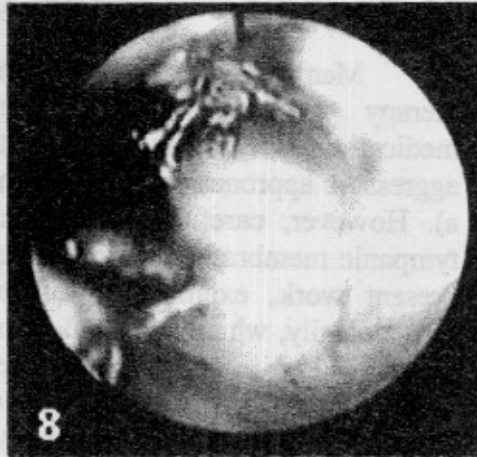
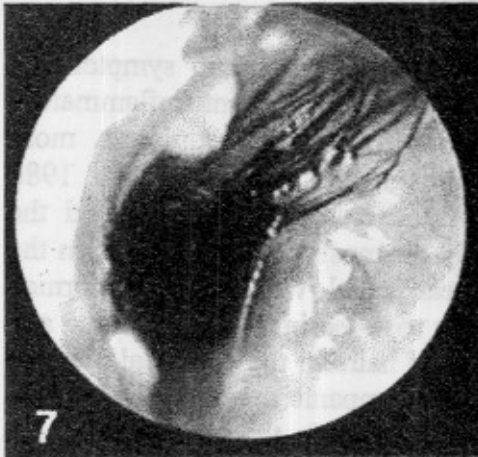
Foreign bodies were diagnosed and removed otoscopically in 3 dogs and the tympanic membrane was perforated in one of these cases. Ear mite was diagnosed in one cat; it was seen as small cream-colored mites, which moved when warmed with the otoscope light.

Chronic otitis externa and otitis media with narrowing of the ear canal, hyperemia, and proliferations, perforation of the tympanic membrane and thickening of its margins and/or shrinkage of it were diagnosed otoscopically in 6 patients (4 dogs and 2 cats) (Figs. 9& 10& 11). However, otoscopy could not be done in 3 dogs with chronic otitis externa and complete occlusion of the ear canal. Examination of the nasopharynx was normal in all examined animals (Fig. 12).

LEGENDS OF FIGURES

- Fig. 1:** The normal external ear canal rose red in color, glistening and contains some hairs
- Fig. 2:** Normal tympanic membrane, transparent, glistening, thin in the center, and thick peripherally. Notice the pars flaccida (arrow head), small branching blood vessels (arrow) and the outline of the manubrium of the malleus (circle).
- Fig. 3:** Ventrodorsal projection of the osseous bulla of a dog with unilateral otitis externa, and otitis media. Notice the normal thin appearance of the wall of the osseous bulla, the air density of the tympanic cavity (arrow) and the thickened (radiodense) tympanic cavity of the affected side (arrow head).
- Fig. 4:** Ventrodorsal projection of the osseous bulla of a dog with bilateral chronic otitis media. Notice the obliteration of the tympanic cavity with bone.
- Fig. 5:** Purulent otitis externa with narrowing of the ear canal.
- Fig. 6:** Otitis externa with narrow ear canal that contains brown exudate and abscess at its depth (arrow).
- Fig. 7:** Purulent otitis externa and otitis media with ruptured tympanic membrane.
- Fig. 8:** Otitis externa with thickening of the tympanic membrane and absence of its transparency
- Fig. 9:** Thickened proliferated tympanic membrane with hyperemic ear canal.
- Fig. 10:** Otitis media with ruptured tympanic membrane and hyperemia of the ear canal. The manubrium of the malleus (arrow).
- Fig. 11:** Hyperemia and proliferations in the ear canal.
- Fig. 12:** Normal endoscopic appearance of the nasopharynx and nasopharyngeal openings (*).





DISCUSSION

Many animals with ear diseases will respond to symptomatic therapy with antibiotics, parasiticide, and anti-inflammatory medications. However, persistent or severe cases require a more aggressive approach with resolve of a diagnosis (Woody and Fox, 1986 a). However, careful examination of the external ear canal and the tympanic membrane is helpful in early diagnosis of ear diseases. In the present work, examination of the ear canal was easily performed otoscopically, which appeared normally rose-red in color, glistening and contained hair in some dogs. Presence of hairs in the ear canal may act as obstacle for good visualization of the tympanic membrane, so that it must be removed to allow better visualization. In the present study the tympanic membrane appeared normally concave, glistening, transparent and thin membrane similar to the findings of Seim (1993) and Gotthelf (2000).

Alterations in color, tension or integrity of the tympanic membrane indicates pathological changes in the middle ear (Seim, 1993 and Shell, 2000). In the present work, otoscopy was very efficient in determination of changes in the tympanic membrane as thickening, congestion of the blood vessels or perforation. This was not possible radiographically which make the use of radiography in diagnosis of ear diseases not accurate.

Other techniques as tympanometry, palpation of the tympanic membrane and positive contrast canalography were used in diagnosis of ear diseases associated with perforation of the tympanic membrane (Little and Lane, 1989, Trower *et al.*, 1998). These techniques could in some cases result in rupture of an intact tympanic membrane or leakage of the contrast material into the tympanic cavity when positive contrast canalography used in cases which have already perforated tympanic membrane. In the present study otoscopy was not only useful in examination of the tympanic membrane, but successfully used in detection and removal of foreign bodies in the ear canal. Foreign bodies were recorded to be one of the causes of otitis externa and irritation of the ear canal in dogs (Woody and Fox, 1986 b). Removal of such foreign bodies is the first step in treating otitis externa occurred in such cases (Shell, 2000). Under the control vision of the otoscope, such foreign bodies were safely removed without complication by perforation of the tympanic membrane during removal. Otoscopy was also successfully used in diagnosis of ear mite in one cat; the mite appeared cream-colored

and small in size, which moved when exposed to otoscope light, these results agreed with those reported by Woody and Fox (1986 b).

Radiography is usually used to determine the extent of ear disease and in establishing a diagnosis of otitis media (Woody and Fox 1986b, Krahwinkel 1993 and Seim 1993). However, according to Krahwinkel (1993) and Seim (1993) the radiographic changes occur usually later and radiography fail often to demonstrate extension of the disease to the middle ear even when present. This was in agreement with our results because in 11 cases of the examined patients, radiography revealed no clear pathological changes in the ear canal or the tympanic membrane. However, the case history, physical examination and otoscopy, revealed presence of acute otitis externa with extension of the inflammation to the middle ear (otitis media) in 7 of these cases.

CONCLUSION

In conclusion otoscopy appeared to be an accurate diagnostic technique in examination of the ear canal and the tympanic membrane. It is a good diagnostic tool used for diagnosis of many ear diseases particularly otitis externa, otitis media, diagnosis and removal of foreign bodies in the ear canal and ear mite. However otoscopy could not be used in cases with chronic otitis externa which are accompanied with sever proliferations and complete occlusion of the ear canal due to obstruction of the ear canal.

REFERENCES

- Bardavid, A. (1999):* Was tun bei chronischer Otitis? Aktueller Stand der chirurgische Otitisbehandlung, *Kleintiermedizin*, 6, 250-253.
- Gotthelf, I.N. (2000):* Diagnose der Otitis media beim Hund, *Watham Focus*, 10, (3), 24-30.
- Kraft, W.J. (1993):* Endoskopie des Nasenrachenraumes bei Hund und Katze, *Tierärztliche Praxis* 21, 498-500.
- Krahwinkel, D.J. (1993):* External ear canal In: Slatter D., (ed.), *Textbook of small animal surgery Vol. 2, 2nd Ed.* W. B. Saunders Co., Philadelphia, pp 233-235.
- Little, C.J. and Lane, J.G. (1989):* An evaluation of tympanometry, otoscopy and palpation for assessment of the canine tympanic membranc, *Vet. Rec.*124, 5-8.

- Little, C.J.; Lane, G.; Gibbs, G. and Person, G.R. (1991):* Inflammatory middle ear diseases of the dog: The clinical and pathological features of Cholestoma, a complication of otitis media, *Vet. Rec.* 6, 319-322.
- Seim, H.B. (1993):* The Ear In: Text book of small animal surgery. Vol. 2, Sec. 14. Ed D. Slatter, W.B. Saunders Co., Philadelphia, pp 1545-1550.
- Shell, L.G. (2000):* Otitis media and otitis interna In: Saunders manual of small animal practice. 2nd. Eds R.G. Sherding and S.J. Birchard W.B. Saunders, Philadelphia. pp. 435- 442.
- Trower, N.D.; Grgory, S.P.; Renfrew, H. and Lane, G. (1998):* Evaluation of canine tympanic membrane by positive contrast canalography, *Vet. Rec.* 142, 78-81.
- Woody, B. and Fox, S.M. (1986 a):* Laying the groundwork for disease management. *Vet. Medicine* 81, 607-614.
- Woody, B. and Fox, S.M. (1986 b):* Otitis externa: Seeing past the signs to discover the underlying cause. *Vet. Medicine* July, 616-624.