

The efficacy of live infectious bursal disease vaccines in commercial 10 days old chicks.

**M. M. Amer¹, K. M. El-Bayomi², Wafaa A. Abdel-Ghany¹, M. A. Kotkat²,
Sherein S. Abdel-Gaied³, M. A. Shakal¹**

¹*Poultry diseases department, Faculty Veterinary Medicine, Cairo University, Egypt.*

²*Poultry diseases department, National Research Center, Dokki and* ³*Pathology department, Faculty Veterinary Medicine, Cairo University, Egypt.*

The efficacy of four infectious bursal disease virus (IBDV) vaccines including intermediate (D78) and intermediate plus (228E, IBD-Blen and Bursa-Vac+) were compared in priming vaccination of 10 days commercial old male layer chicks. There were different parameters were measured for testing these vaccines including; the immunogenic efficacy, the effect on performance, organ (bursa, spleen, and proventriculus) body weight index as well as histopathological examination of bursa, spleen, proventriculus and thymus. Chick was received a dose of 10^2 EID₅₀ from one IBDV vaccine out of 228E, IBD-Blen or Bursa-Vac+, while D78 dose was 10^4 EID₅₀. The results cleared out that all the tested vaccines passed through the maternal derived antibodies $2480.133 + 156.3$. All vaccines stimulate antibody formation as measured by ELISA test. The used vaccines not affect markedly body weight and feed intake, as there were no significant differences between the control group and the vaccinated ones in the mean body weight and the feed conversion rate. Furthermore, the bursa: body weight index of vaccinated groups were generally less than those of control one at all intervals, while the spleen and proventriculus: spleen: body weight index of vaccinated groups was higher than control on at the end of the observation period. The used vaccines induced histopathological changes in bursa, spleen, proventriculus and thymus glands. These results indicated that all tested vaccine are of value in vaccination of commercial chicks from vaccinated breeders.

Infectious bursal disease (IBD) was firstly reported in Gumboro area, Delaware, USA (Cosegrove, 1962) since the mid 1950s, then it rapidly spread all over the world (Faragher, 1972; Okoye, 1984; Saif *et al.*, 2003). IBD becomes a disease of a great concern as it induces severe economic losses for poultry industry due to immunosuppression (Allan *et al.*, 1972; Faragher *et al.*, 1974), deaths ranged 3-3% (Bygrave and Fragar, 1970) or even 100% (Chettle *et al.*, 1989; El-Batrawi, 1990; Van den Berg *et al.*, 1991; Eterradossi *et al.*, 1992), growth retardation (Mcilroy *et al.*, 1989) and increased condemnation rate at processing as a result of muscular haemorrhages (Saif *et al.*, 2003). The most susceptible age for IBD virus (IBDV) infection in chickens is 3-6 weeks old and the virus causes severe immunosuppression due to destruction of lymphoid organs (mainly the bursa of fabricius) and some other lymphoid organs (Mazzariegos *et al.*, 1990). The first appearance of variant IBDV strains was in 1984 and the very virulent (vv) IBDV strains was in

1989 (Rosenberger and Cloud, 1986; Rosenberger *et al.*, 1987; Saif *et al.*, 2003), as these strains can infect the birds less than 3 weeks of age inducing subclinical infection without signs or macroscopic bursal lesions, however, the infection at this time causes severe immunosuppression (Winterfield *et al.*, 1983). The IBDV is very stable in the environment and difficult to be destroyed by the standard methods of sanitation and disinfection (Winterfield *et al.*, 1983). So prevention of infection in chicken based mainly on vaccination as established by Saif *et al.* (2003). There are two types of IBD vaccines; inactivated and living ones. Inactivated vaccine is used for vaccination of adult hens to protect the progeny at the first three weeks of age (O'Brien, 1976; Wyeth and Cullen, 1978; Eidson, 1980; Naqi *et al.*, 1983; Box, 1988; Bruce *et al.*, 1992). Live vaccines are essentially intended for prevention of IBDV infection in young chickens. Living vaccinal strains of IBDV vary in virulence from mild, intermediate, intermediate-plus to hot and its use on the level

of maternal antibodies (Thronton and Pattison, 1975; Naqi *et al.*, 1980 and 1983; Giambrone and Clay, 1986; Tsukamoto *et al.*, 1995). Both mild and intermediate live vaccinal strains of IBDV are neutralized by maternal antibodies (Rinaldi *et al.*, 1974; Winterfield and Thacker, 1978; Weyth and Chettle, 1990; Tsukamoto *et al.*, 1995), but the intermediate strain vaccines are superior to mild vaccines in induction of immunity in the presence of maternal antibodies (Mazzariegos *et al.*, 1990). Chicks with high maternal immunity may require hot IBDV strain vaccines to induce active immunity (Winterfield *et al.*, 1980); however, this strain can induce immunosuppression (Thronton and Pattison, 1975; Muskett *et al.*, 1979; Henry and Williams, 1980; Thangavelu *et al.*, 1998). Chicks with low or no maternal immunity can be protected by using live mild or intermediate IBDV vaccinal strains (Solano *et al.*, 1986).

Although both live and inactivated vaccines have been developed to control IBD in intensively grown poultry production, difficulties may occur in implementing these vaccines in combination with efficient sanitary measures under field conditions. Such difficulties may explain why IBD-induced immunosuppression is still frequently encountered and represents a major threat to the control by vaccination of other infectious diseases affecting intensively grown poultry farms (Lasher and Shane, 1994). So, this work was carried out to investigate the effect of live IBDV vaccines intermediate (D78) and intermediate plus (228E, IBD-Blen and Bursa-Vac+) strains on the immunogenic response, the bird's performance, organ (bursa, spleen, proventriculus): body weight index as well as histopathological changes of 14 days old male layer chicks that have maternal antibodies to IBDV.

Materials and methods

Experimental chickens. One day old, 185 male layer type (LCL) chicks obtained from El-Wady poultry company, Giza, Egypt were used. The birds were floor reared on separate disinfected rooms and commercial starter balanced ration. Feed and water were given ad libitum.

Infectious bursal disease (IBD) vaccines. The following commercial Freeze dried live intermediate strains of IBDV were used: Nobilis Gumboro strain (D78), batch number, 06808lj01. Intervet International, B. V. Boxmeer, Holand. Intermediate plus vaccine, Nobilis Gumboro strain (228E), batch number, 06802Gj01.

Intervet International, B. V. Boxmeer, Holand. Intermediate plus vaccine strain (2512) IBD-Blen, batch number, 2707N2DKA, Phylaxia, Sanofi Vet. Biol. Co. Ltd, Hungary under USA License. Intermediate plus vaccine strain (G603) Bursa-Vac+, batch number, 341/06, Shering-Plough Animal Health, Millsboro, Delaware, USA

Titration of the used IBD vaccines. The viral IBD vaccinal strains were propagated on the chorioallantoic membrane of 10-11 days old specific pathogen free embryonated chicken eggs (ECEs) obtained from free farms (Koum Osheim, El-Fayoum, Egypt). The inoculation was done according to (Villegas and Purchase, 1989), the titer was expressed as 50% embryo infective dose (EID₅₀) per ml and it was calculated as Reed and Meunch (1938).

Determination of the antibody titers to IBD vaccines. At day old, just before immunization (0 hour) at 10 days of age and also at 17, 24, 31, 36 and 41 days old representing 7, 14, 21, 26 and 31 days post vaccination (PV) the antibody titers were assessed using commercially available Enzyme linked immunosorbent assay (ELISA) kits (IDEXX, 1 DEXX Drive, Westbrook, Marine 04092 USA, US Vet. License number 313, product code 5040. ELISA test was carried out according to the manufacturer instructions as following:

Preparation of samples. Test samples were diluted 5 hundred fold (1:500) with sample diluents prior to being assayed. Tips were changed for each sample and samples thoroughly mixed prior to dispensing into the coated figure.

Test procedure. One hundred μ l of undiluted positive control were dispensed into appropriate wells of the figure, and then the figure was incubated for 30 minutes at room temperature. Each well was washed with approximately 350 μ l of distilled or deionized water for 3-5 times, 100 μ l of goat anti-chicken horseradish peroxidase conjugate was dispensed into each well followed by incubation for 30 minutes at room temperature. Each well was washed again with approximately 350 μ l of distilled or deionized water for 3-5 times. One hundred μ l of TMP substrate was added to each well. The figure was incubated for 15 minutes at room temperature and finally 100 μ l of stopping solution was dispensed into each well to stop the reaction. ELISA reader (Dynatech MR-700) was blank with air and absorbance values were measured and recorded at 650 nm wavelength.

ELISA reading. The difference between the positive control mean and negative control mean (PCx-NCx) should be greater than 0.075. The negative control mean absorbance should be less or equal to 0.150. The relative level of antibodies in serum samples were determined by calculating serum samples to positive (S/P) ratio.

Interpretation of results. Serum samples with S/P ratios of less than or equal to 0.2 was considered negative. S/P ratios greater than 0.2 (titer greater than 396) was considered positive and indicated vaccination or other exposure to IBDV.

Vaccination of chicks. After titration of the used vaccines, each chick/group was received 102 EID₅₀/ 0.1 ml for each 228E, IBD-Blen and Bursa-Vac+ live intermediate plus IBDV vaccines, but a dose of 10⁴ EID₅₀/ 0.1ml was given for live intermediate D78 IBDV vaccine. The chicks were vaccinated at 10 days of age via eye instillation.

Determination of the organ. body weight index. The bursa index was calculated according to Sharma *et al.*, (1989) Chicks with bursa : body weight index lower than 0.7 was considered suffering from bursal atrophy (Lucio and Hitchner, 1979). Similarly, the spleen and proventriculus: body weight index were measured.

Experimental design. A total of 185, day old commercial male layer (LCL) chicks that possessed maternal antibodies to IBDV were used. The birds were floor reared and given feed and water ad libitum. At the first day of life, 10 birds were randomly selected then sacrificed and the sera were collected to determine the titer of maternal antibodies. The birds were vaccinated at 5 days of age against Newcastle disease using HB1 via eye drop method. At 10 days of age, 15 blood samples were collected from the wing veins and the sera were separated for determination of the titer of antibodies at the (0 hour) just before immunization (pre immunization) then these birds were weight, at the same time the amount of feed intake was calculated. The remaining (175) chicks at 10 days old were randomly divided into 5 equal separate groups in clean and disinfected rooms; each group was consisted of 35 chicks. Chicks of group (1) were kept as non-vaccinated control. While each chick of group 2, 3, 4 and 5 were received IBDV vaccine 228E, D78, IBD-Blen, and Bursa-Vac+, respectively via eye drop instillation. All the groups were observed after vaccination for signs and mortalities.

Furthermore, individual blood sample for serum after recording of body weight were of control and vaccinated group at 17, 24, 31, 36 and 41 days old (7, 14, 21, 26 and 31 PV). The weekly group feed was determined. Three birds / group at the previous intervals were randomly selected and each bird was weighed, sacrificed and weight of its bursa, spleen and proventriculus was detected to calculate the organ/ body weight index. Moreover, bursa, spleen, proventriculus and the thymus collected for histopathological examination and lesion score.

Histopathological examination. The Collected bursae, spleens, Thymus glands and proventriculus were fixed in 10% formol saline and subjected to histopathologicak preparation and examination as described by Bancroft and Steven (1996). The severity of lymphoid lesions was scored (0-4) as described by Sharma *et al.*, (1989).

Statistical analysis. The obtained results were statistically compared and evaluated according to Steel and Torrie (1960).

Results and Discussion

In this study, we directed our work to investigate the immunogenicity of the most popularly used IBDV vaccines (intermediate and intermediate plus strains) in the presence of maternal antibodies. The selected IBDV vaccines were representative for the phylogenetic study for grouping of IBDV vaccines (Dolz *et al.*, 2004). In the other hand Mato *et al.*, (2004) grouped field IBD viruses according to vaccine.

In this study, no clinical signs or mortalities was observed in control non-vaccinated group and the vaccinated ones. Along the whole observation period after vaccination till the end of the experiment and this result may indicating the safety of the used living IBDV vaccines. Similarly Edgar and Cho (1973); Roasales *et al.*, (1989); Thangavelu *et al.*, (1998); Eterradosi *et al.*, (2004) ; Sultan *et al.*, (2006) found that using of live IBDV vaccines could protect the birds from development of clinical signs and mortalities.

The result of serological response to IBDV vaccines was illustrated in Table (1). The result showed that the maternal antibody titer to IBDV in used day old chicks was (4477.4 ± 462.1), this titer waned to reach (2480.13 ± 156.3) at 10 days of age (pre immunization). At 7, 14, 21, 26 and 31 days PV, there was an elevation in the antibody titers of all vaccinated groups in comparison with the titer just before immunization. However, the antibody titer was

gradually decline in the control non-vaccinated group till the end of the experiment. ELISA titers resulted from vaccination with IBDV vaccine (D78) were the lowest at all intervals while the titers of IBDV vaccine (228E) were the highest. This result revealed that all the used live IBDV vaccines were non immunosuppressive and were able to induce antibody levels in chickens with maternal IBDV antibodies in the absence of IBDV. Such result confirmed the findings of Marquardt *et al.*, (1980); Briggs *et al.*, (1986); Solano *et al.*, (1986) ; Van den Berg and Meulemans, (1991). Also, this result was in accord with this reported by Abdel-Alim and Kawkab (2006) who found that live intermediate plus IBDV vaccines were immunogenic with better immune response in eye drop vaccinated groups.

Concerning the results of the mean body weight and the feed conversion rate in the control non-vaccinated and vaccinated groups at 7, 14, 21, 24, 26 and 31 days PV (Table 1), there was no significant differences between the control non-vaccinated group and the vaccinated ones. Moreover, there were no differences between the vaccinated groups in the measured parameters (Naqi *et al.*, 1980).

The results of the bursa, spleen and proventriculus: body weight index were showed in Table (2) and Fig. (1, 2 and 3). The bursa: body weight index of vaccinated groups were generally less than those of control one at all intervals (Table 2 and Fig.1) and this indicated that the used vaccines caused atrophy of the bursa (bursa: body weight index less than 0.7). This result confirmed the results of Ide and Stevenson, (1973); Mazzariegos *et al.*, (1990); Van den Berg, (1991 ; Eterradosi *et al.*, (1992) who reported that intermediate strains of IBDV vaccines were sufficient to induce a significant reduction in bursa: body weight ratio until 33 dpv. IBDV vaccine (Bursa-Vac+), followed by (228E) induced the mildest effect on bursa when compared with the other vaccines (D78 and IBD-Blen). This revealed that the severity of bursal lesions was more in the intermediate strains of IBDV vaccine than intermediate plus vaccines (Thangavelu *et al.*, 1998).

Table (2) and Fig. (2) showed that the spleen: body weight index of vaccinated groups was higher than control non-vaccinated group till the end of the observation period (31 days PV) except (IBD-Blen) vaccinated group which showed spleen: body weight index lower than

the control and vaccinated groups indicating splenic atrophy.

The proventriculus: body weight index of vaccinated groups was higher than control non-vaccinated group at the end of the experiment (31 days PV) (Table 2 and Fig. 4) and that may be due to the inflammatory reaction of the used IBV vaccines in the proventriculus.

Histopathological examination of tissue sections of birds vaccinated with IBDV vaccine (D78) revealed undetectable changes in bursal tissue at all intervals. No lesions were detected in the proventriculus firstly, followed by submucosal leucocytic infiltration along the whole intervals (Fig.4a). Spleen tissue showed congestion (Figure 4b) and mild necrosis in follicles (Fig.4c). Thymus section showed congested medulla (Fig. 4d) then became apparently normal till the end of experiment.

Birds vaccinated with IBDV vaccine (228E) showed histological lesions in spleen in the form of congestion firstly (Fig. 5a) followed by congestion and necrosis along the observation period (Fig.5b). Thymus tissue showed vacuolated cortical cells (Fig.5c) and focal haemorrhages in medulla (Fig. 5d). The Proventriculus showed submucosal edema and fibrosis (Fig. 5e) accompanied with edema and congestion (Fig. 5f).

Samples for histopathology from IBDV vaccine (IBD-Blen) vaccinated group showed that bursal lesions were seen as interfollicular congestion with slight cortical necrosis (Fig.6a). Spleen showed congestion, haemorrhage and necrotic germinal center (Figure 6b) as well as congestion and focal haemorrhagic areas (Fig.6c). Thymus glands revealed only slight medullary necrosis (Fig.6d). The Proventriculus sections showed submucosal haemorrhage and connective tissue proliferation (Fig.6e) moreover, submucosal congestion, edema and fibrosis were also seen (Fig. 6f).

Examined sections of Bursa-Vac+ vaccinated chicks showed only bursal focal interfollicular haemorrhagic areas (Fig.7a). Spleen showed congestion and haemorrhagic areas in between follicles (Fig.7b) also massive necrosis in the white pulbs and germinal centers of most lymphoid follicles were seen along all the intervals PV (Fig.7c). Thymus glands showed slight medullary necrosis and haemorrhages in medulla (Fig.7d). The proventriculus early after vaccination showed submucosal fibrosis with heterophils infiltration

Table (1): Results of mean body, feed intake and feed conversion rates and ELISA test of birds vaccinated with different IBDV vaccines

Gr. No.	Vaccine	DPV*	Body weight /gm	Feed intake /gm	*F. C. R.	ELISA test	
						No of samples	Mean \pm SD
1	Control Negative	0	90.5 \pm 0.66	95	1.04	15	2480.133 \pm 156.3
		7	167.8 \pm 24.6	243.31	1.45	15	1878.3 \pm 253.1
		14	258.1 \pm 33.6	474.92	1.84	15	1231.133 \pm 142.5
		21	325.1 \pm 5.03	690	2.13	15	962.26 \pm 127.0
		24	372.5 \pm 10.6	815	2.18		
		26	420.0 \pm 14.1	924	2.20	15	312 \pm 70.5
		29	455.0 \pm 21.2	1114.75	2.45		
		31	497.5 \pm 17.7	1283.07	2.57	6	205.8 \pm 19.44
2	228E	0	90.5 \pm 0.66	95	1.04		
		7	168.3 \pm 24.6	274.32	1.63	15	2594.2 \pm 148.9
		14	250.0 \pm 33.6	495	1.98	15	3294.2 \pm 215.7
		21	324.5 \pm 5.03	707.41	2.18	15	3547.4 \pm 137.4
		24	347.5 \pm 10.6	778.4	2.24		
		26	390.5 \pm 14.1	885.30	2.27	8	3969.3 \pm 165.2
		29	442.5 \pm 21.2	1101.82	2.49		
		31	496.0 \pm 17.7	1280	2.58	5	3790.8 \pm 206.6
3	D78	0	90.0 \pm 0.66	95	1.04		
		7	160.3 \pm 11.0	262.89	1.64	15	2432 \pm 130.2
		14	259.3 \pm 21.5	523.78	2.02	15	2986.3 \pm 167.4
		21	320.0 \pm 15.0	710.40	2.22	15	3384.8 \pm 112.9
		24	387.5 \pm 24.7	871.87	2.25		
		26	430.0 \pm 14.1	971.80	2.26	8	3602.5 \pm 163.3
		29	470.0 \pm 14.1	1156.20	2.46		
		31	500.0 \pm 21.2	1275	2.55	5	3572.6 \pm 253
4	IBD Blen	0	90.0 \pm 0.66	95	1.04		
		7	157.6 \pm 9.1	263.19	1.67	15	2536.6 \pm 137.6
		14	223.6 \pm 1.5	456.14	2.04	15	3102.5 \pm 167.07
		21	289.0 \pm 5.6	635.80	2.20	15	3482.8 \pm 120.9
		24	342.5 \pm 11	770.62	2.25		
		26	382.5 \pm 3.5	868.27	2.27	8	3771.5 \pm 114.05
		29	437.5 \pm 3.5	1093.75	2.50		
		31	493 \pm 14.1	1272	2.58	5	3631.4 \pm 180.3
5	Bursavac	0	90.0 \pm 0.66	95	1.04		
		7	166.3 \pm 2.5	274.39	1.65	15	2578.2 \pm 136.5
		14	237.0 \pm 3.6	464.52	1.96	15	3200 \pm 159.3
		21	305.0 \pm 5.0	661.85	2.17	15	3551.1 \pm 117.4
		24	347.5 \pm 3.5	778.40	2.24		
		26	385.0 \pm 7.07	870.10	2.26	8	3922.6 \pm 121.12
		29	445.0 \pm 7.1	1103.60	2.48		
		31	495.0 \pm 7.1	1272	2.57	5	3704.3 \pm 171.9

*F.C.R: Feed conversion rate.

** DPV= Days Post vaccination.

Table (2): Results of mean bursa, spleen and proventriculus weights of birds vaccinated with different IBDV vaccines

Gr. No.	Vaccine	*DPV	Bursal		Spleen		Proventriculus	
			Ratio x 10 ⁻⁴	Index	Ratio x 10 ⁻⁴	Index	Ratio x 10 ⁻⁴	Index
1	Control Negative	0	28.6 ± 5.50	1.0 ± 0.0	10.3 ± 0.57	1.0 ± 0.0	85.3 ± 5.85	1.0 ± 0.0
		7	48.6 ± 6.02	1.0 ± 0.0	18.0 ± 5.19	1.0 ± 0.0	83.6 ± 3.51	1.0 ± 0.0
		14	55.6 ± 2.08	1.0 ± 0.0	17.3 ± 4.93	1.0 ± 0.0	67.6 ± 4.50	1.0 ± 0.0
		21	49.0 ± 1.0	1.0 ± 0.0	14.6 ± 0.57	1.0 ± 0.0	65.6 ± 0.57	1.0 ± 0.0
		24	45.0 ± 2.82	1.0 ± 0.0	26.5 ± 2.12	1.0 ± 0.0	60.0 ± 9.89	1.0 ± 0.0
		26	48.0 ± 0.0	1.0 ± 0.0	29.5 ± 2.12	1.0 ± 0.0	65.5 ± 4.94	1.0 ± 0.0
		29	47.5 ± 2.12	1.0 ± 0.0	19.5 ± 0.70	1.0 ± 0.0	54.0 ± 1.41	1.0 ± 0.0
2	228E	31	42.0 ± 1.41	1.0 ± 0.0	18.5 ± 0.70	1.0 ± 0.0	43.0 ± 2.82	1.0 ± 0.0
		7	42.3 ± 0.57	0.87 ± 0.01	13.6 ± 2.08	0.8 ± 0.12	70.0 ± 1.0	0.83 ± 0.01
		14	40.40 ± 1.0	0.71 ± 0.02	19.3 ± 1.15	1.13 ± 0.06	67.6 ± 0.06	1.01 ± 0.01
		21	37.6 ± 0.57	0.76 ± 0.01	16.6 ± 0.57	1.10 ± 0.04	59.6 ± 0.57	0.89 ± 0.01
		24	36.0 ± 1.41	0.79 ± 0.03	20.5 ± 0.70	0.78 ± 0.02	64.0 ± 0.0	1.06 ± 0.0
		26	35.0 ± 1.41	0.74 ± 0.02	21.0 ± 0.0	0.75 ± 0.0	66.0 ± 2.82	1.04 ± 0.04
		29	30.0 ± 0.0	0.63 ± 0.0	25.5 ± 0.7	1.27 ± 0.03	60.5 ± 0.70	1.14 ± 0.01
3	D78	31	24.5 ± 0.70	0.62 ± 0.02	29.5 ± 0.70	1.73 ± 0.04	56.5 ± 0.70	1.31 ± 0.01
		7	45.6 ± 2.51	0.94 ± 0.05	12.0 ± 1.0	0.7 ± 0.06	76.3 ± 1.15	0.90 ± 0.01
		14	43.3 ± 2.08	0.77 ± 0.03	14.3 ± 0.57	0.84 ± 0.03	74.6 ± 2.08	1.11 ± 0.03
		21	34.7 ± 0.58	0.70 ± 0.01	17.6 ± 1.52	1.17 ± 0.10	62.3 ± 0.57	0.93 ± 0.01
		24	31.5 ± 0.70	0.69 ± 0.02	27.0 ± 0.0	1.03 ± 0.0	58.0 ± 2.82	0.96 ± 0.04
		26	27.0 ± 1.41	0.57 ± 0.02	31.0 ± 1.41	1.10 ± 0.05	60.5 ± 0.70	0.96 ± 0.01
		29	20.5 ± 0.70	0.43 ± 0.01	23.5 ± 0.70	1.18 ± 0.03	48.5 ± 0.70	0.91 ± 0.01
4	IBD Bien	31	21.0 ± 1.41	0.53 ± 0.03	21.5 ± 0.70	1.26 ± 0.04	44.0 ± 0.0	1.02 ± 0.0
		7	47.3 ± 2.52	0.98 ± 0.06	13.3 ± 0.58	0.78 ± 0.03	81.7 ± 8.02	0.97 ± 0.09
		14	42.0 ± 3.46	0.74 ± 0.06	20.6 ± 1.15	1.21 ± 0.06	69.3 ± 2.08	1.03 ± 0.02
		21	37.7 ± 3.51	0.76 ± 0.07	22.0 ± 0.0	1.46 ± 0.0	64.6 ± 0.57	1.34 ± 0.64
		24	29.0 ± 1.41	0.64 ± 0.02	21.5 ± 0.70	0.82 ± 0.02	58.0 ± 1.41	0.96 ± 0.02
		26	28.0 ± 0.0	0.59 ± 0.0	17.5 ± 0.70	0.62 ± 0.03	56.0 ± 1.41	0.8 ± 0.02
		29	26.0 ± 1.41	0.55 ± 0.02	13.0 ± 0.0	0.65 ± 0.0	45.0 ± 0.0	0.84 ± 0.0
5	Bursavac Plus	31	21.10 ± 0.70	0.55 ± 0.02	13.0 ± 0.0	0.76 ± 0.0	50.0 ± 0.0	1.16 ± 0.0
		7	50.0 ± 0.0	1.04 ± 0.0	16.0 ± 1.0	0.94 ± 0.06	76.0 ± 0.0	0.90 ± 0.0
		14	46.7 ± 1.15	0.83 ± 0.01	16.7 ± 0.58	0.98 ± 0.03	78.0 ± 0.0	1.16 ± 0.0
		21	36.7 ± 0.58	0.74 ± 0.01	17.7 ± 0.58	1.17 ± 0.04	58.0 ± 0.0	0.87 ± 0.0
		24	34.5 ± 0.71	0.76 ± 0.01	19.5 ± 0.71	0.75 ± 0.02	61.0 ± 0.0	1.01 ± 0.0
		26	34.0 ± 0.0	0.72 ± 0.0	20.0 ± 0.0	0.71 ± 0.0	59.0 ± 0.0	0.93 ± 0.0
		29	31.0 ± 1.41	0.67 ± 0.02	20.5 ± 0.71	1.03 ± 0.03	51.5 ± 0.71	0.97 ± 0.01
		31	25.25 ± 1.41	0.67 ± 0.04	23.0 ± 0.0	1.35 ± 0.0	48.0 ± 0.0	1.10 ± 0.01

* DPV= Days Post vaccination.

Fig. (1): Bursal ratio of birds vaccinated with different IBD vaccines

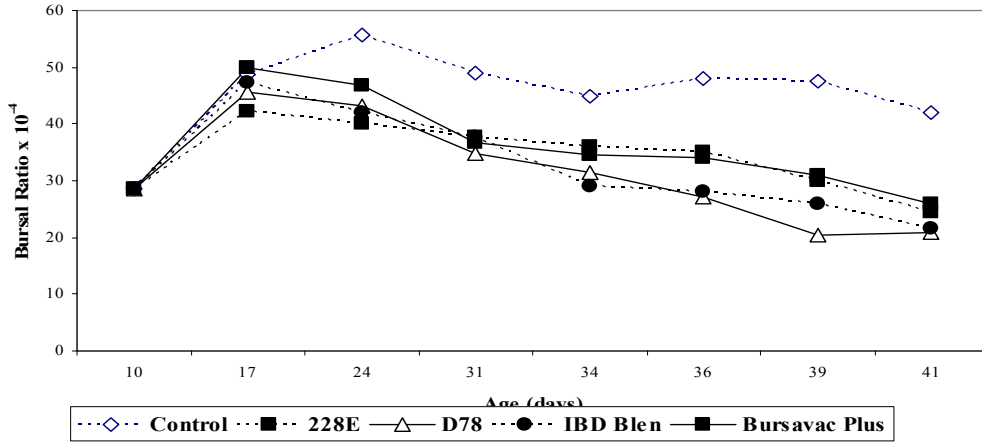


Fig. (2): Spleen ratio of birds vaccinated with different IBD vaccines

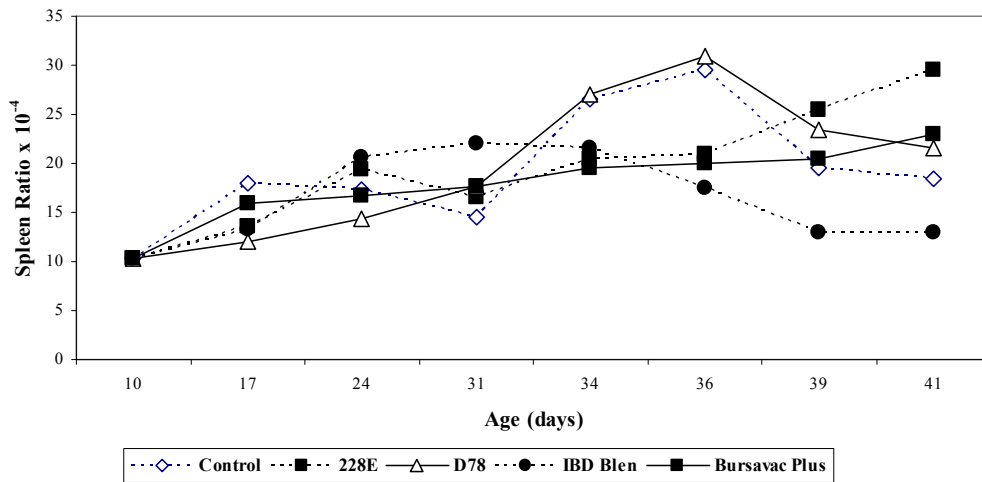
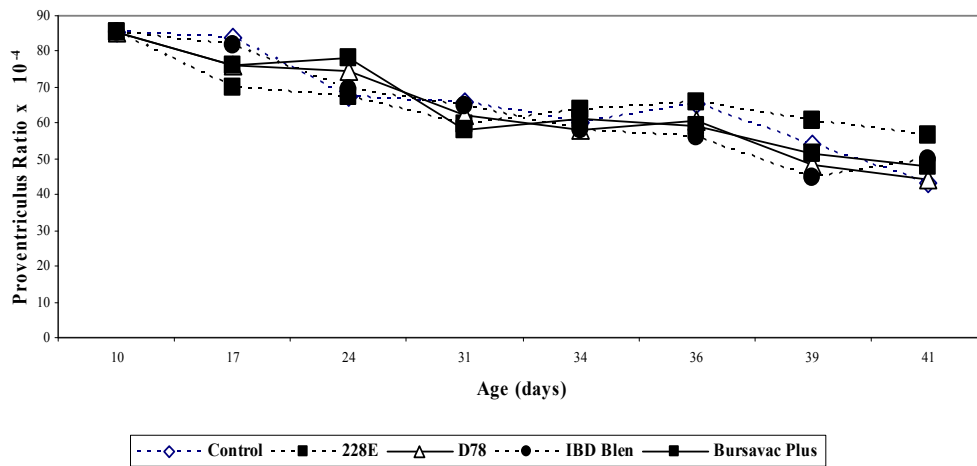


Fig. (3): Proventriculus ratio of birds vaccinated with different IBD vaccines



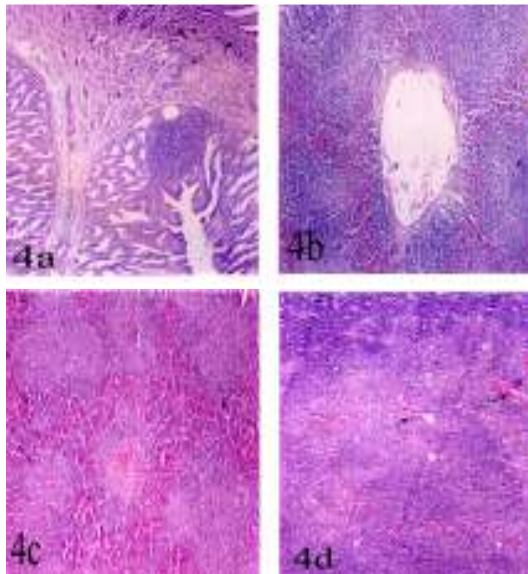


Fig. (4): Sections of chickens vaccinated with D78 (x100) showing:
 a) Proventriculus showing leucocytic infiltration (arrow) (Lesion score: 2)
 b) Spleen showing congestion (Lesion score: 2)
 c) Spleen showing necrosed follicles (Lesion score: 2)
 d) Thymus showing congested medulla (arrow) (Lesion score: 1)

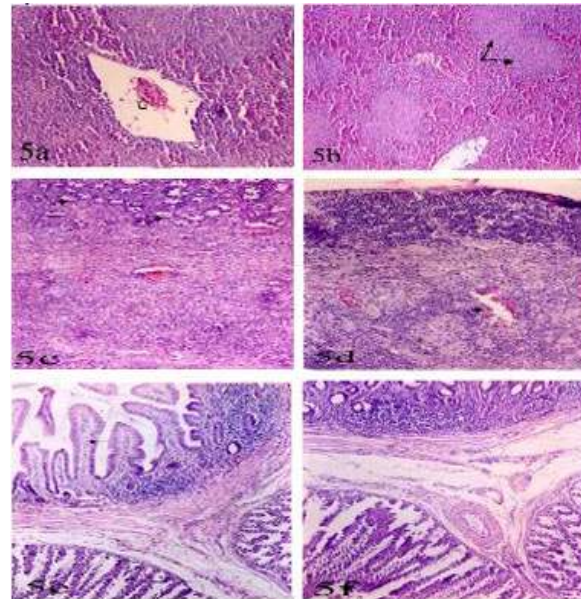


Fig. (5): Sections of chickens vaccinated with 228E vaccine (H & E)
 a) Spleen showing congestion (c) x200 (Lesion score: 1)
 b) Spleen showing congestion and necrosis (arrow) (x100) (Lesion score: 2)
 c) Thymus showing vacuolated cortical cells (arrow) (x 200) (Lesion score: 2)
 d) Thymus showing focal medullary hemorrhage (arrow) (x200) (Lesion score: 2)
 e) Proventriculus showing submucosal edema and fibrosis (x100) (Lesion score: 2)
 f) Proventriculus showing edema and congestion (x00) (Lesion score: 2).

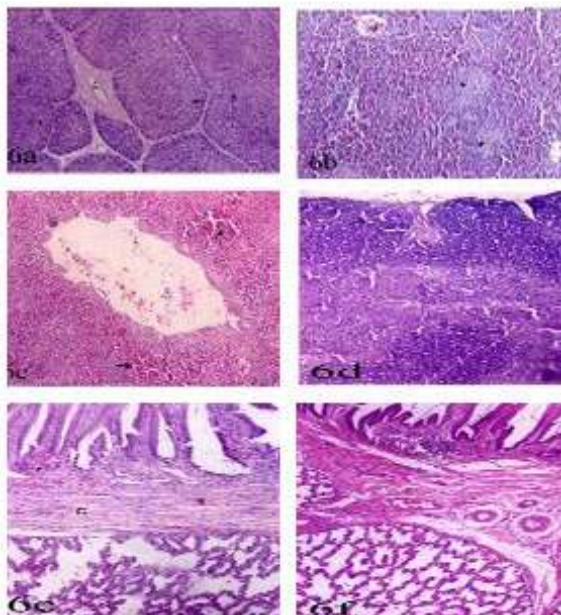


Fig. (6): Sections of chickens vaccinated with IBD-Blen vaccine (H & E):
 a) Bursa: congestion (c) and slight necrosed follicular cortex (arrow) (x100) (Lesion score: 1).
 b) Spleen showing necrosed follicles (arrow) (x100) (Lesion score: 2).
 c) Spleen: hemorrhage (arrow) (x 100) (Lesion score: 1)
 d) Thymus showing slight medullary necrosis (x100) (Lesion score: 1)
 e) Proventriculus showing submucosal hemorrhage (arrow) and connective tissue proliferation (c) (x 100) (Lesion score: 2).
 f) Proventriculus showing congestion and fibrosis (x100) (Lesion score: 2).

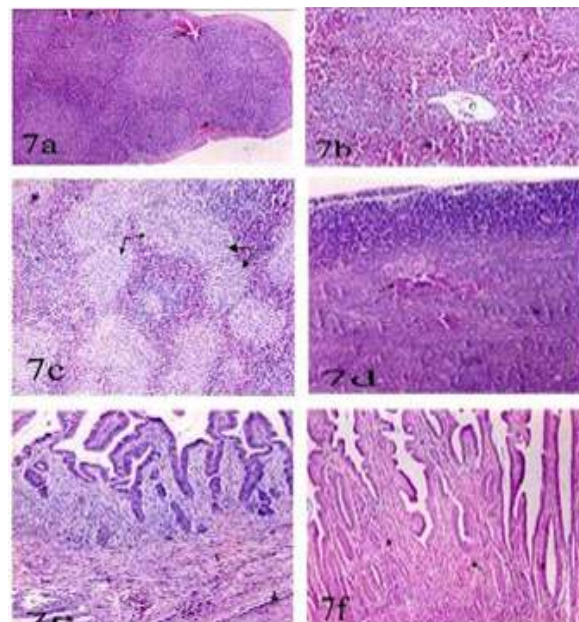


Fig. (7): Sections of chickens vaccinated with bursa-Vac+ vaccine (H & E) (x100):
 a) Bursa showing focal hemorrhagic areas (arrow) (Lesion score: 1).
 b) Spleen showing congestion (c) and hemorrhage (arrow) (Lesion score: 1).
 c) Spleen showing necrosed follicles (arrow) (Lesion score: 2).
 d) Thymus showing hemorrhagic area (arrow) (Lesion score: 1).
 e) Proventriculus showing fibrosis (f) and heterophilia (Lesion score: 2).
 f) Proventriculus showing heterophilia (arrow) (Lesion score: 2).

(Fig.7e) while heterophilic infiltration was seen in the lamina propria later till the end of experiment (Fig. 7e). Histopathological changes in the bursae were recorded previously by El-Sergany *et al.*, (1974). Splenic congested lesions due to these vaccines were observed by Ley *et al.*, (1983); Nunoya *et al.*, (1992); Hassan *et al.*, (1996), while necrosis was found by Okoye and Uzoukwu (1981); El-Manakhly and Bekheit (1992). In the other hand, the detected lesions observed in the thymus sections were shown by Sharma *et al.*, (1989); Goodwin *et al.*, (1996); Goodwin and Hafner (1997); Shaban (2004); Amer *et al.*, (2007). Microscopic lesions observed in the proventriculus were seen by Shaban (2004) and Amer *et al.*, (2007).

The results of the histopathological examination of the bursae, spleens, thymus glands and proventriculus from vaccinated birds indicated that the used living IBDV vaccines were strong enough to cause pathological lesions in the lymphoid organs (Thornton and Pattison, 1975; Ide, 1979; Thangavelu *et al.*, 1998; Mona, 2002).

Comparing results of examined sections clearly pointed out that the IBDV followed by D78, bursavac plus and 228E affecting tissue of vaccinated chickens.

These findings indicating that the used vaccines have a severe effect on vaccinated 14 days chicks having maternal antibodies as measured by conversion rate, organ; body weight ration and index as well as histopathological findings.

Our results pointed out that the commercially used IBDV vaccines passed through the protective maternal derived antibody titer of vaccinated chicks inducing high antibody titers as measured by ELISA, detectable variation in the measured organ: body weight index as well as lymphoid organ tissue damage when compared with non-vaccinated group. These results may be attributed to the strong vaccinal IBDV strains or unrelatedness between the vaccinal antigen and the maternal derived antibodies.

References

- Abd El-Alim, G. A. and KawKab, A. Ahmed (2006):** Efficacy and pathogenicity of three live infectious bursal disease vaccines (intermediate plus strains) in commercial native chickens breed in Egypt. *Vet. Med. J., Giza.* 54, (3): 649-669.
- Allan, W. H.; Faragher, J. J. and Cullen, G. A. (1972):** Immunosuppression of the infectious bursal disease agent in chicken immunized against Newcastle disease. *Vet. Rec.*, 90: 511-512.
- Amer, M. M.; El-Bayomi, K. M.; Kotkat, M. Abd-A; Wafaa A. Abd El-Ghany; Shakal, M. Abd El-S. and Sherein S. Abd El-Gaied (2007):** Isolation, molecular characterization and pathogenicity studies of infectious bursal disease field virus isolates. in press *Procc.of the 5th scientific conf. Facult. Vet. Med., BeniSuef Nniveristy* 6-9 sept.
- Bancroft, J. and Steven, A. (1996):** "Theory and Practice of Histopathological technique" 4th Ed., Churchill, Livingstone, NY, London, San Francisco, Tokyo.
- Box, P. (1988):** Antibody profile of broiler breeder and their progeny immunized with bursal-derived or embryonic origin killed infectious bursal disease vaccine. *Proc. Western Poultry Dis. Conf.*, 37: 21-24.
- Briggs, D. J.; Whitfill, C. E.; Skeeles, J. K.; Story, I. and Reed, K. D. (1986):** Application of positive negative ratio method of analysis to quantitative antibody response to infectious bursal disease virus using a commercially available ELISA. *Avian Dis.*, 30 (1): 216-218.
- Bruce, I. H.; Butcher, G. D.; Miles, R. D. and Rossi, A. F. (1992):** Subclinical infectious bursal disease in an integrated broiler production operation. *J. Vet. Diag. Invest.*, 4: 406-411.
- Baygrave, A. C. and Fragher, J. T. (1970):** Mortality associated with Gumboro disease. *Vet. Rec.*, 758-759.
- Chettle, N. J.; Smart, J. C. and Wyeth, P. J. (1989):** Outbreak of virulent infectious bursal disease in east Anglia. *Vet. Rec.*, 125: 271-272.
- Cosegrove, A. S. (1962):** An apparently new disease of chickens- avian nephrosis. *Avian Dis.*, 6: 385-389.
- Dolz, R.; Majo, N.; Ordonez, G.; Ponsa, F.; Biarnes, M. and Porta, R. (2004):** Molecular characterization of infectious bursal disease virus isolated in Spain ab. 707., XXII world's Poult. Congress, June 8-13 Istanbul. Turkey.
- Edgar, S. A. and Cho, Y. (1973):** Immunization of chickens for the control of infectious bursal disease. *Poultry Sci.*, 52: 492-497.
- Eidson, C. S. (1980):** Vaccination of breeder chickens and their progeny with a live or with an inactivated oil emulsion infectious bursal disease virus vaccine. *Develop. Biol. Stand.*, 51: 251-261.
- El-Batravi, A. M. (1990):** Studies on severe out breaks of infectious bursal disease.1-the natural and experimental disease. *Proceed. of 2nd Scientific Conf. Egypt. Vet. Poultry*, 339-252.
- El-Manakhly, E. M. and Bekheit, A. B. (1992):** The pathology of broilers experimentally infected with infectious bursal disease virus and vaccination against Newcastle disease. *Egypt. J. Comp. Pathol. Clin. Pathgol.*, 5 (1): 55-64.
- El-Sergany, H. A.; Ann, Moursi.; Saber, M. S. and Mohammed, M. A. (1974):** A preliminary investigation on the occurrence of Gumboro disease in Egypt. *Egypt. J. Ve. Sci.*, 11-17.
- Etteradossi, N.; Picault, J. P.; Druin, P.; Michele Guittlet; Rolande L'hospitalier; and Bennejean; G. (1992):** Pathogenicity and preliminary antigenic characterization of 6 infectious bursal disease virus strains isolated in France from acute outbreaks. *J. Vet. Med. B.*, 39: 683-691.
- Etteradossi, N.; Gauthier, C.; Reda, I.; Comte, S.; Rivallan, G.; Tonquin, D.; Bionesson, C.; Lamande, J.; Jestive, V.; Morine, Y.; Cazaban, C. and Borne, B. M. (2004) :** Extensive

- antigenic changes in a typical isolate of very virulent infectious bursal disease virus with an antigenically classical live vaccine. *Avian Pathol.*, 33 (4): 423-431.
- Faragher, J. T. (1972):** Infectious bursal disease of chickens (review). *Vet. Bull.*, 42 (6): 361-369.
- Faragher, J. T.; Allan, W. H. and Wyeth, P. J. (1974):** Immunosuppressive effect of infectious bursal agent on vaccination against Newcastle disease virus. *Vet. Rec.*, 95: 385-388.
- Giambone, J. J. and Clay, R. P. (1986):** Evaluation of immunogenicity, stability, pathogenicity and immunodepressive potential of 4 commercial live infectious bursal disease vaccines. *Poultry Sci.*, 65: 1287-1290.
- Goodwin, M. A.; Hafner, S.; Bounous, D. I.; Latimer, K. S.; Player, E.C.;**
- Niagro, D.; Campagnoli, R. P. and Brown, J. (1996):** Viral proventriculitis in chickens. *Avian Pathol.*, 25: 369-379.
- Goodwin, M. A. and Hafner, S. (1997):** Transmissible viral proventriculitis. In: *Diseases of Poultry*, 10th Ed. Calnek, B.W.; Barnes, H. J.; Beard, C. W.; Reid, W. M. and Yoder, Jr. H. W. Iowa State University Press, Ames, IA. Pp: 1034-1038.
- Hassan, M. K.; Al-Natour, M. Q.; Ward, L. A. and Saif, Y. M. (1996):** Pathogenicity, attenuation and immunogenicity of infectious bursal disease virus. *Avian Dis.*, 40: 567-571.
- Henry, C. W. and Williams, W. P. (1980):** The detrimental effect of vaccinating parentally immune broilers with a modified live virus vaccine for infectious bursal disease. *Avian Dis.*, 24 (4): 1021-1026.
- Ide, P. R. (1979):** Infectious bursal agent vaccination of chicks from infectious bursal agent vaccinated dams. *Canad. Vet. J.*, 20 (2): 35-40.
- Ide, P. R. and Stevenson, R.G. (1973):** Infectious bursal disease in New Brunswick. *Cand. J. Comp. Med.*, 37: 347-355.
- Keck, L. D.; Skelles, J. K. and McNew, R. W. (1993):** Antibody detection in hatched chicken sera and egg yolk samples by commercial ELISA kits for NDV, IBV, infectious bursal disease and Avian Reo virus. *Avian Dis.*, 37: 825-828.
- Lasher, H. N. and Shane, S. M. (1994):** Infectious bursal disease. *World's Poultry Sci. J.*, 133-166.
- Ley, D.H.; Yamamoto, R. and Bickford, A.A. (1983):** The pathogenesis of infectious bursal disease: Serologic, histopathologic and clinical chemical observations. *Avian Dis.*, 27 (4): 1060-1085.
- Lucio, B. and Hitchner, S. B. (1979):** Infectious bursal disease emulsified vaccine: effect upon neutralizing antibody levels in the dam. *Avian Dis.*, 23: 466-478.
- Marquardt, W. W.; Johnson, R. B.; Odenwald, W. and Schlottob, B. A. (1980):** An indirect enzyme linked immunosorbent assay (ELISA) for measuring antibodies in chickens with infectious bursal disease virus. *Avian Dis.*, 24: 375-385.
- Mato, T.; Lomniczi, B. and Palya, V. (2004):** Molecular characterization of Hungarian field isolates and vaccinal infectious bursal disease virus strains. *Ab. 725, XXII WPC (2004) 8-13 June Istanbul, Turkey.*
- Mazzariegos, L. A.; Lukert, P. D. and Brown, J. (1990):** Pathogenicity and immunosuppressive properties of infectious bursal disease intermediate strains. *Avian Dis.*, 34: 302-308.
- McIlory, S. G.; Goodall, E. A. and McCracken, R. M. (1989):** Economic effects of subclinical infectious bursal disease on broiler production. *Avian Pathol.*, 18 (3): 465-475.
- Mona, M. A. (2002):** Studies on epidemiology and vaccination for prevention of Gumboro disease in chickens. Ph.D. Thesis. Fac. Vet. Med., Cairo Univ. (Beni-Suef branch).
- Naqi, S. A.; Marquez, B. and Shahin, N. (1983):** Maternal antibodies and its effect on infectious bursal disease immunization. *Avian Dis.*, 27 (3) 623-630.
- Naqi, S. A.; Millar, D. L. and Grumbles, L. C. (1980):** An evaluation of 3 commercially available infectious bursal disease vaccines. *Avian Dis.*, 24 (1): 233-240.
- Nunoya, T.; Otaki, Y.; Tajima, M.; Hiraga, M. and Saito, Y. (1992):** Occurrence of acute infectious bursal disease with high mortality in Japan and pathogenicity of field isolates in SPF chickens. *Avian Dis.*, 36: 597-609.
- Okoye, J. O. A. (1984):** Infectious bursal disease of chickens. *Vet. Bull.*, 54 (6): 425-436.
- Okoye, J. O. A. and Uzoukwu, A. (1981):** An outbreak of infectious bursal disease among chickens between 6 and 20 weeks old. *Avian Dis.*, 25 (4): 1034-1038.
- O'Brien, A. (1976):** Infectious bursal disease of chickens and vaccination. *Vet. Rec.*, 20: 260-261.
- Reed, L. J. and Muench, H. (1938):** A simple method of estimating fifty per cent end point. *Amer. J. Hyg.*, 27: 493-497.
- Rinaldi, A.; Cessi, D.; Cervio, G. and Lodetti, E. (1974):** Attenuation of infectious bursal disease virus and vaccination trials under laboratory and field conditions. *Avian Pathol.*, 3 (1): 51-57.
- Roasales, A. G.; villegas, P.; Lukert, P. D.; Fletcher, O. J. and Brown, J. (1989):** Immunosuppressive potential and pathogenicity of recent isolates of infectious bursal disease virus in commercial broiler chickens. *Avian Dis.*, 33: 724-728.
- Rosenberger, J. K. and Cloud, S. S. (1986):** Isolation and characterization of variant infectious bursal disease viruses. *J. Amer. Vet. Med. Ass.*, 189: 357.
- Rosenberger, J. K.; Cloud, S. S. and Metz, A. (1987):** Use of infectious bursal disease virus variant vaccines in broilers and broiler breeders. *Proc. 36th West Poultry Dis. Conf.*, 105-109.
- Saif Y. M.; Barnes, H. J.; Fadly, A. M.; Glisson, J. R. and Swayne, D. E. (2003):** Infectious bursal disease, in *Poultry Diseases*, 11th Ed., Iowa State Press, Iowa.
- Shaban, K. S. (2004):** Studies on avian infectious proventriculus disease. Ph.D. Thesis. Fac. Vet. Med., Cairo Univ.
- Sharma, J. M.; Dohms, J. E. and Metz, A. L. (1989):** Comparative pathogenesis of serotype-1 and variant serotype-1 isolates of infectious bursal disease virus and their effect on humeral and cellular immune competence of SPF chickens. *Avian Dis.*, 33: 112-124.
- Snedeker, C.; Wills, F. K. and Moulthrop, I. M. (1967):** Some studies on the infectious bursal agent. *Avian Dis.*, 11: 519-528.
- Solano, W.; Giambone, J. J.; Williams, J. C.; Lauerman, L. H; Panagala, V. S. and Garces, C. (1986):** Effect of maternal antibodies on timing of initial vaccination of young white leghorn chickens against infectious bursal disease virus. *Avian Dis.*, 30: 648-652.
- Steel, R. G. D. and Torrie, J. H. (1960):** Principles and procedures of statistics. McGraw-Hill Book Comp. Inc. New York, Toronto, London, PP. 99-131.
- Sultan, H. A.; El-Balal, S.; Hussein, H. A. and Abdel Razeq, A. (2006):**

Development of early protection induced by intermediate and intermediate plus infectious bursal disease virus (IBDV) vaccines against very virulent IBDV (vvIBDV). Proceedings of the 7th Sci. Conf. of the Egypt. Vet. Poult. Asso. (pp. 227-238). Cairo, Egypt.

Thangavelu, A.; Dhinakarraj, G.; Elankumaran, S.; Murali Manohar, B.; Koteswaran A. and Venugopalan, A. T. (1998): Pathogenicity and immunosuppressive properties of infectious bursal disease virus field isolates and commercial vaccines in India. Tropical Anim. Health and Prod., 167-176.

Thornton, D. H. and Pattison, M. (1975): Comparison of vaccines against infectious bursal disease virus. J. Comp. Pathol., 85: 597-610.

Tsukamoto, K.; Tanimura, N.; Kakita, S.; Ota, K.; Masc, M.; Imai, K. and

Hihara, H. (1995): Efficacy of 3 live vaccines against highly virulent infectious bursal disease virus in chickens with or without maternal antibodies. Avian Dis., 39: 218-229.

Van den Berg, T. P. and Meulemans, G. (1991): Acute infectious bursal disease in poultry: protection afforded by maternally derived antibodies and interference with live vaccination. Avian Pathol., 20 (3): 409-421.

Van den Berg, T. P.; Gonze, M. and Meulemans, G. (1991): Acute infectious

bursal disease in poultry, isolation and characterization of a highly virulent strain. Avian Pathol., 20: 133-143.

Villegas, P. and Purchase, G. (1989): Titration of biological suspension. In: Laboratory Manual for the

Isolation and Identification of avian pathogens. 3rd ed. American Association of Avian Pathologists. H. G. Purchase, L. H. Arp., C. H. Domermuth and J. E. Pearson eds. Kenell/Hunt publishing company, Iwo, USA. Pp. 186-190.

Winterfield, R. W. and Thacker, H. L. (1978): Immune response and pathogenicity of different strains of infectious bursal disease virus applied as vaccines. Avian Dis., 22 (4): 721-731.

Winterfield, R. W.; Dhillon, A. S.; Thacker, H. L. and Alby, L. J. (1980): Immuneresponse of white leghorn chicks from vaccination with different strains of infectious bursal disease virus and in the presence of maternal antibodies. Avian Dis., 24 (1): 179-188.

Winterfield, W. R.; Fadly, A. M. and Bickford, A. (1983): Infectivity and distribution of infectious bursal disease virus in chickens, persistence of the viruses and lesions. Avian Dis., 16: 622-632.

Wood, G. W.; Muskett, J. C. and Thronton, D. H. (1983): Use of inactivation oil emulsion vaccine in breeder chickens to prevent immunosuppression in progeny chicks. Res. Vet. Sci., 35: 114-115.

Wyeth, P. J. and Chettle, N. J. (1990): Use of infectious bursal disease vaccine in chicks with maternally derived immunity. Vet. Rec., 126: 577-578.

Wyeth, P. J. and Cullen, G. A. (1978): Transmission of immunity from inactivated infectious bursal disease oil emulsion vaccinated parent chickens to their chicks. Vet. Rec., 102: 362-363.

كفاءة لقاحات التهاب غدة فبريشس المعدي الحية في تحصين كتاكيت تجارية عمر ١٠ يوم

تناولت هذه الدراسة مقارنة استخدام أربعة من اللقاحات الحية المستخدمة في تحصين كتاكيت الدجاج تجارية عمر ١٠ يوم تحتوي أمصالها على أجسام مناعية ضد مرض التهاب غدة فبريشس المعدي من الأم وهي (D78, 228E, IBD-Blen and Bursa-Vac+) . استخدمت اللقاحات بالتقطير في العين في اليوم الرابع عشر من العمر وبجرعة 102 EID₅₀ للقاح IBD-Blen or Bursa-Vac+ و 10⁴ EID₅₀ للقاح D78 . استخدمت المعايير التالية للمقارنة: تحديد الاستجابة المناعية بقياس الأجسام في أمصال الكتاكيت المحصنة باختبار الـ ELISA test ، قياس معدلات التحويل الغذائي الأسبوعي، وكذا الأوزان الأسبوعية النسبية لغدة فبريشس والطحال والمعدة الغددية إلى الجسم. تم إجراء الفحص النسيجي المرضي لعينات دورية من غدة فبريشس و الطحال و المعدة الغددية والغدة الليموسية لبيان الآثار المرضية الناتجة عن فيروس اللقاح. أوضحت النتائج ان كل اللقاحات المستخدمة كانت قادرة على تجاوز المناعة الامية في الكتاكيت والمقدرة بمتوسط ١٣٣، ٢٤٨٠٠ + ١٥٦،٣ ، لم يوضح تأثيرا معنويا للقاحات على معدلات الأوزان او استهلاك العلف او معدلات التحويل بين المجموعات المحصنة او بينها وبين المجموعة الضابطة الأوزان النسبية للكتاكيت المحصنة كانت أعلى من المجموعة الضابطة مع تفاوتات التأثير فيما بينها. كما كان للقاحات المستخدمة آثارا نسيجية مرضية تدميري متفاوتة فيما بينها على أنسجة الأعضاء والغدد التي فحصت و مما سبق يتضح أن اللقاحات المختبرة لها كفاءة في تحصين الكتاكيت التجارية المنتجة من امهات محصنة.