

## **HEMATOLOGICAL EFFECTS AND ULTRASTRUCTURAL CHANGES OF *IN VIVO* EXPOSURE TO SOME MALATHION FORMULATIONS IN ALBINO RATS**

Saleh, A. A.<sup>a</sup> and S. E. M. Shalby<sup>b</sup>

<sup>a</sup> Pesticides Dept., Fac. Agric., Mansoura Univ.

<sup>b</sup> Pests and Plant Protection Dept., National Research Centre, Dokki, Cairo, Egypt

Email: sh\_shalbynrc@yahoo.com

### **ABSTRACT**

The purpose of the present study is to investigate the potential toxic effects of some malathion formulations (malatox, malason, agrothion and nasrathion) that have the same active ingredient on some vital biochemical components and ultrastructural changes of nuclei of liver and kidney tissues of albino rats.

Obtained data indicated that malatox and nasrathion caused significant decrease in WBCs count (-46.6 and -25.9% below normal level), while malason caused significant increase (+10.5%) after 30 days of treatment, which returned to the normal levels after 7 days of recovery, except in case of nasrathion (-10.4%). All malathion formulations caused significant decrease in RBCs count after 30 days of treatment without recovery to the normal level at the end of experiment. The highest effect was noticed in agrothion treated rats (-38.3 %) after 7 days of recovery and malatox after 30 days of treatment. Similar effects were noticed on hemoglobin values and platelets count of treated rats without recovery to the normal levels.

Data clearly revealed that the tested malathion formulations induced significant elevation in transaminase enzymes (AST and ALT) activity after 30 days of treatment, without recovery to the normal level, except in case of ALT activities of agrothion treated rats (+2.7%). Administration of oral doses (100 mg / kg. b.w.) of tested malathion formulations didn't cause significant effects on creatinine (Cr) concentration. But in malatox treated rats there was a significant increase in Cr concentration after 30 days of treatment (+62.5 %) without returning to the normal levels at the end of experiment (+42.9%). The same trend was observed on urea concentration of the 30 days of treatment, while after 7 days for recovery, malatox, nasrathion and agrothion caused significant increase and decrease in this vital component concentration (+46.9, +28.0 and -21.9 %, respectively).

No sharp variations were noticed between different malathion formulations in liver cells treated rats. The results so far obtained indicated histo- and cytopathological alterations by electron microscope due to the effect of compounds when compared with to the control ones. Some sections poorly differentiated hepatocellular showing marked polymorphis of the nuclei, irregularity of the chromatin and prominent nucleoli in treated rats with malatox when compared with control. Also, in treated rats with malason, agrothion and nasrathion showed the numbers of nuclei and their content in different section by many powers of vision, results show no differ significant difference and all treatment did not induce or genotoxicity.

Kidney sections of different formulations of malathion (a.i) treated animals, revealed many phases of degenerative changes when compared with those of control. Electron microscope appeared, poorly differentiated cells containing a cytoplasmic indentation or inclusion filled with brush border material and showed also, that cytoplasm is filled with prominent granular, endoplasmic reticulum containing some dense flocculum material. Also, electron micrograph appeared, poorly differentiated in nuclei and no

changes in their content such as nucleolus or chromosomes (chromatid and centomere). So, from the doses applied during 30 days results conclude that all tested malathion formulations don't show any genotoxicity in treated animals.

**Keywords:** Malathion, formulations – *In Vivo* – liver functions – kidney functions – nuclei – ultrastructure.

### INTRODUCTION

Pesticides are usually applied in the formulated form where the active ingredient is mixed with organic solvent, emulsifier and other additives to enhance their water miscibility and penetration. Pesticide formulations are, therefore, the process of transforming a pesticidal chemical into a product, which can be applied by practical methods to permit its effective, safe and economical use. However, it has been reported that formulation may cause an increase or decrease in the toxicity of the active ingredient (El-Sebae, 1985 and Abdel-Rahim *et al.*, 1994). Also, the World Health Organization has emphasized that the final toxic classification of any pesticide is intended to be by its formulation (Anonymous, 1991).

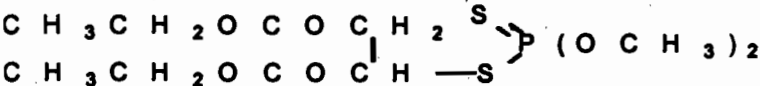
Generally, several hundreds of pesticides have the same active ingredient but differ in the formulation used to control insects. These pesticides probably differ in their speed of action, uptake, metabolism, elimination and toxicity (Anwar 1997). The organophosphorus insecticide malathion is one of the most frequently used insecticides and is widely used to control Coleoptera, Diptera, Hemiptera, Hymenoptera and Lepidoptera in a wide range of crops, including cotton, pomes, soft and stone fruit, potatoes, rice and vegetables. Also, it is used extensively to control major arthropod disease vectors (Culicidae) in public health programmes, ectoparasites (Diptera, Acari, Mallophaga) of cattle, poultry, dogs and cats, human head and body lice (Anoplura), household insects (Diptera, Orthoptera), and for the protection of stored grain (Anonymous, 2004).

In the current study, some blood contents and ultrastructural examinations of hepatocellular injury and renal affection are investigated as biomarkers for the evaluation of exposure to some malathion formulations ( malatox, malason, agrithion and naserlethion) having the same active ingredient.

### MATERIALS AND METHODS

**I-Insecticides used:**

- 1- Malatox was obtained from El-Helb for Pesticides & Chemicals Co.
- 2- Malason was obtained from Kafer El-Ziat for Pesticides and Chemicals Co.
- 3- Agrothion was obtained from Agrochem Co.
- 4- Naserlathion was obtained from El- Naser Co. for intermediate chemicals.



The insecticides used have the same active ingredient (malathion E.C.57 %)

## **II- Experimental animals:**

The present study was performed on 50 adult male albino rats of average weight (80-100 g). Animals were obtained from the General Organization of Serum and Vaccine (Helwan Farm), Cairo, Egypt. These animals were clinically healthy and housed in hygienic conditions and fed on balanced diet. Rats were acclimatized under the test conditions for two weeks before insecticide treatment. The animals were allocated into five groups. The 1<sup>st</sup> was considered as a control, while, the other four groups were treated by 100 mg/kg b.w. a.i. (rather tolerance dose) day after two days for one month with four tested formulations ( malatox, malason, agrithion and naserlathion). The insecticide was withdrawn for 7 days to allow recovery from toxicity. Toxicants were administrated by a convenient stomach tube. After 30 days of treatment and 7 days science the last dose, blood samples were collected in two tubes. The first contained heparin (7.5 I.U./ ml, according to Schalm, 1986) for haematological investigations, while the another sample was collected in a clean tube for biochemical analysis.

## **III- Haematological study:**

Red blood cells (RBCs) counts, white blood cells (WBCs) counts, haemoglobin (Hb) value and platelet counts were determined according to Schalm (1986) method.

## **IV- Biochemical analysis:**

The activities of aminotransferases (AST and ALT) were determined calorimetrically according to Reitman and Frankel (1957) method. Blood serum urea and creatinine concentrations were measured according to the method of Coulombe and Farreau (1963), and Henry (1974), respectively. All obtained data were statistically analyzed using " F " test at 0.05 level (Snedecor and Cochran, 1980).

## **V- Specimen preparation for transmission electron microscope:**

In preparing specimen for transmission electron microscopy, virtually every step of the procedure affected the quality of the find electron micrographs. Tissue preparation for transmission electron microscopy could be divided into major steps. Most fixation protocols developed subsequently are modification of the two steps. A primary fixative was developed that combined glutaraldehyde and low concentration of formaldehyde (up to 4%). A secondary fixative using osmium tetroxide solution that is reduce with ferro cyanide, was introduced to enhance preservation of the membrane and glycogen. After fixation samples were washed using the same buffer which utilized in the fixation mixture they were dehydrated in ascending grades of ethanol (30% for 30 min., 50 % for 30 min., 70 % for 30min. and 100. % 2 changes of 30 min.). Samples were carried out in cold, the dehydration was also completed at 0 to 4 C. Samples were put after dehydration in propylene oxide, pure for 30-60 min., propylene oxide – Epon mixture (1:1) for 30-60 min., and resin mixture for 30-60 min. Final embedding was most conveniently done in polyethylene capsules in troghs with preformed molds. The capsules containing the embedding mixture and tissue blocks were polymerized in an oven for 2-3 days at 60 C. When polymerized, the blocks were very hard and ready for sectioning.

Semithin sections (0.5  $\mu$ m thick section) were cut by ultramicrotome to select suitable areas for ultrathin sectioning for electron microscopy. When an area for fine structural examination has been selected from the thick section, the block face must be retrimmed to a size suitable for ultramicrotomy. Generally, the suitable thin for electron microscope is 800  $\text{\AA}$  ( $\text{\AA} = 0.001 \mu\text{m}$ ). After that, sections collecting from trough of ultramicrotome onto a specimen grid made of copper. A grid of this type offers a sufficiently large mesh width (85 $\mu$ m) that gives an adequate field of low magnification as well as a relatively good heat dissipation. The grid with section was dried by placing it on a piece of filter paper. Thin sections were stained with uranyl acetate solution to produce a general increase in contrast. The grids were examined by Electron microscope. Type JEM. 1200 EX11.

## RESULTS AND DISCUSSION

### I-Effect on some blood components:

Data presented in Table (1) indicate a decrease in white blood cells (WBCs) count in malatox, naserlathion and agrithion treated rats (- 46.6, - 25.9 and -3.5 % below the normal level ) after 30 days of treatment, respectively. After 7 days of recovery, reduction in WBCs count was found in case of malatox (-11.5 %) and agrithion (-1.9 %), while in case of naserlathion an increase was observed (-35.2 % below the normal level). On the other hand, malason formulation caused an increase in WBCs count (+10.5 and +17.3 % above normal level) after 30 days of treatment and 7 days of recovery, respectively.

Table(1): Effect of some malathion formulations on WBCs, RBCs counts, Hemoglobin values and Platelets counts of albino rats

Treatments		Malatox	Malason	Agrothion	Naserlathion	Control	LSD 5 %
White blood cells ( $10^3$ /ml)	30 days	3.1 d (-46.6)	6.4 a (+10.3)	5.6 b (-3.5)	4.3 c (-25.9)	5.8 b	0.4335
	7d. recovery	4.6 b (-11.5)	6.1 a (+17.3)	5.1 ab (-1.9)	3.4 c (-10.4)	5.2 ab	1.091
Red blood cells ( $10^9$ /ml)	30 days	3.3 c (-31.3)	3.9 b (-18.8)	4.0 b (-16.7)	4.3 b (-10.4)	4.8 a	0.4534
	7d. recovery	4.0 b (-14.9)	3.3 c (-29.8)	2.9 c (-38.3)	3.4 c (-27.7)	4.7 a	0.4612
Hemoglobin values (g/dl)	30 days	9.7 d (-32.2)	11.2 c (-217)	11.8 bc (-17.5)	12.3 b (-14.0)	14.3 a	0.697
	7d. recovery	11.8 b (-5.6)	10.7 c (-14.4)	8.1 d (-35.2)	7.3 e (-41.6)	12.5 a	0.6468
Platelets ( $10^6$ /ml)	30 days	161.0 b (-10.6)	150.0 c (-16.7)	140.0 d (-22.2)	135.0 d (-25.0)	180.0 a	9.819
	7d. recovery	160.0 e (-23.8)	175.0 d (-16.7)	185.0 c (-11.9)	190.0 b (-9.5)	210.0 a	4.21

Each figure between brackets represents the percentage of content as check.

In the same table, obtained data revealed that malatox, malason, agrithion and naserlathion treatment caused significant reduction in red blood cells (RBCs) count (-31.3, -18.8, -16.7 and -10.4 % below the normal level) after 30days of treatment, respectively. After 7 days of recovery, these values were increased except in case of malatox (-14.9 %).

The obtained data (Table 1) clearly indicated that the hemoglobin values and platelets count had the same trend as previously mentioned in case of RBCs count after 30 days of treatment. After 7 days of recovery, malatox and malason treated rats showed a decrease in the percent of reduction of hemoglobin values to -5.6 and -14.4 %, while malatox increased the reduction of platelets count (23.8 % below the normal level). On the contrary, treated rats by agrithion and naserlethion caused an increase in the reduction of hemoglobin values (-35.2 and -41.6 %), at the same time, a decrease in the reduction of platelets count (11.9 and 9.5 % below the normal level) was noticed. The reduction of Hb content as well as RBCs counts may be attributed to the toxic effect of the insecticide, and with the chronic pesticides exposure and malignant tumors of animals organs (Hoffman *et al.*, 1991). Mitema and Masha (1984) observed that the average value of Hb, RBCs and WBCs counts were increased in cattle poisoned with organophosphorus insecticides. Also, El-Maghraby (2004) reported that  $1/5$  and  $1/10$  LD<sub>50</sub> of malathion and its metabolite induced the activity of some blood content of treated mice, the maximum inhibition was observed after 10 days of treatment. All treated mice returned to their normal statement after one week recovery period.

#### **II- Biochemical adverse aspects related to liver and kidney functions:**

Data presented in Table 2, revealed that all malathion tested formulations caused a significant increase in ALT activity when compared with each other and with untreated animals. The highest increase was noticed in malatox treated rats (87.7% above normal level), while lower increase was noticed in case of agrothion (+25.9 %) after 30 days of treatment. After 7 days of recovery, the activity of ALT gradually decreased but returned to the normal levels.

The same trend was observed in AST enzyme, the rate of increase was different according to treatment. Obtained data showed that naserlathion and malatox caused high increase in AST activity (81.8 and 80.3 % above normal level, respectively) after 30 days of oral administration, while malason and agrothion caused slight increase (+40.3 and +36.4 %, respectively). After the end of recovery period, AST activity have less positive values but didn't return to the normal level probably. Liver damage caused by cyclic heptopeptides lead to profound changes in the pathophysiology of liver enzymes including ALT and AST, also the effect on the two enzymes was considered useful tool in hepato-toxic studies. The severity of liver damage occurred due to the oxidative shock in hepatocytes which not only inhibited the liver enzymes ALT and AST but also significantly suppressed all other enzymes involved in liver functions (Guzman *et al.* 2003 and Li *et al.* 2003). Al-Qarawi *et al.* (1999) found higher concentration of serum AST of the Najdi sheep treated orally with malathion at repeated dose levels of 25 mg/kg/day for 21 days and a single oral dose at 50 mg/kg/ days.

Table(2): Effect of some malathion formulations on ALT, AST activities, Creatinine and Urea concentrations of albino rats.

Treatments		Malatox	Malason	Agrothion	Naseriathion	Control	LSD 5 %
ALT activity (U/ml)	30 days	75.3 a (+87.3)	53.8 c (+33.8)	50.6 d (+25.9)	65.3 b (+62.4)	40.2 e	0.662
	7days fo recovery	54.2 a (+46.5)	45.0 b (+21.6)	38.0 c (+2.7)	53.0 a (+43.2)	37.0 c	1.734
AST activity (U/ml)	30 days	59.5 a (+80.3)	46.3 b (+40.3)	45.0 b (+36.4)	60.0 a (+81.8)	33.0 c	1.545
	7days fo recovery	48.0 a (+52.4)	36.0 c (+14.3)	40.0 b (+27.0)	48.0 a (+52.4)	31.5 d	1.929
Creatinine concentration (mg/dl)	30 days	1.3 a (+82.5)	0.9 b (+12.5)	0.9 b (+12.5)	0.8 b (0.00)	0.8 b	0.179
	7days fo recovery	1.0a (+42.9)	0.6 b (-14.3)	0.6 b (-14.3)	0.9 a (+28.6)	0.7 b	0.186
Urea concentration (mg/dl)	30 days	51.0 a (+54.5)	41.0 ab (+24.2)	27.7 b (-16.1)	37.0 ab (+12.1)	33.0 b	17.37
	7days fo recovery	47.0 a (+46.9)	33.0 c (+3.1)	25.0 d (-21.9)	41.0 b (+28.0 b)	32.0 c	1.68

Each figure between brackets represents the percentage of content as check.

In the same Table, the obtained results indicated that malatox treated rats caused significant increase in blood creatinine content as compared with other formulations and control (+62.5 % ) after 30 days of treatment, while malason and agrothion showed non significant increase in the same vital component (+12.5 %). At the same time, no changes were noticed in treated rats by naseriathion as compared with non treated rats. Blood creatinine in case of malatox continued higher than normal(+42.9 %), also, naseriathion treated rats showed significant increase (+28.6 %) after 7 days of recovery, while the contrary obtained with malason and agrothion showed lower negative values ( non significant ) than normal (-14.3 %). Generally, the elevation of creatinine is considered a biomarker for renal damage and may be attributed to liver function.

At the same respect, obtained data revealed that there are significant differences in urea concentration between malatox treated rats on one side and other malathion formulations and control on the other side after 30 days of treatment. Malatox caused high increase in urea (+54.5 %) after 30 days of treatment, this value decreased gradually to 46.9 % above normal level after 7 days of recovery. The corresponding figures in case of malason and naseriathion were +24.2 and +12.1 % at 30 days and reached to +3.1 and +28.1 % after 7 days of recovery, respectively. On the other hand, urea concentration was negative in agrothion treated rats at 30 days of treatment (-16.1 %) or 7 days of recovery (-21.9 %). On the other hand, elevation in urea may be due the disturbance in protein metabolism. Gupta and Paul (1978) emphasized that spraying buffalo calves daily with 1 % and 5 % malathion as an ectoparasiticide – daily for 28 days caused a significant increase of serum urea.

Our results are in agreement with those found by Saleh (1997), who reported that technical and formulated chlorpyrifos caused considerable effects on RBCs, WBCs counts, Hb, and transaminases activities in

comparison with control. These increases or decreases were higher in case of formulated chlorpyrifos than the technical form. Also, similar effects were obtained by Abdel-Rahim *et al.*(1994), who found that the technical and formulated malathion reduced total Hb and caused high increase in GOT and GPT activities. In the same respect, data obtained by Shalby (2006) indicated that treated rats by lufenuron and profenofos caused significant changes in blood content, liver and kidney functions which returned to normal levels at the end of recovery periods.

### III- Histopathological studies:

No sharp variations were noticed between different malathion formulations in the hepatocyte cells of treated rats, the results so far obtained indicate histo- and cytopathological alterations under the effect of compounds when compared with those of the control ones by light and electron microscopy.

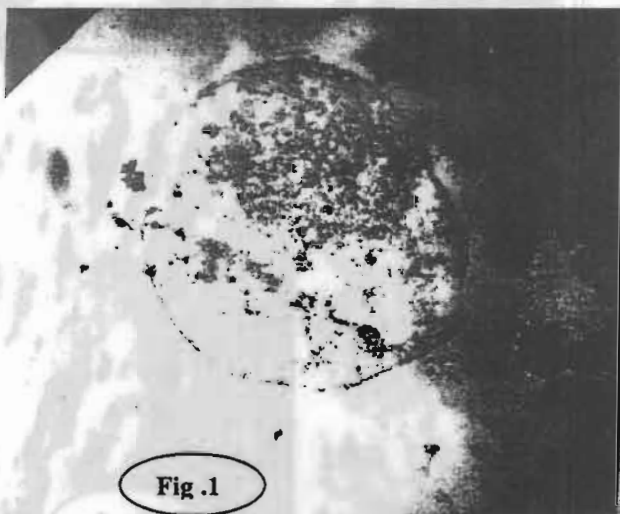
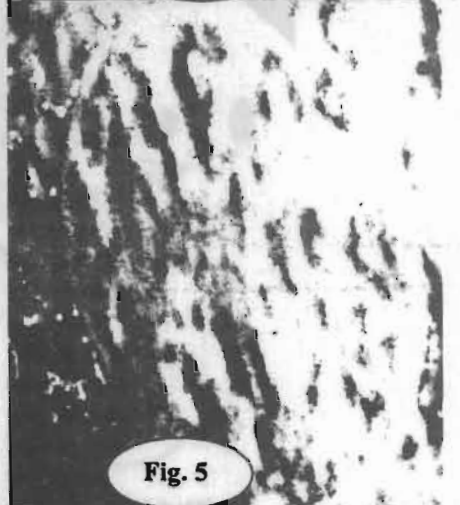
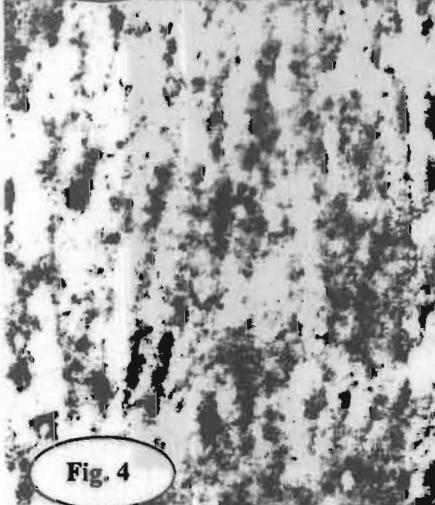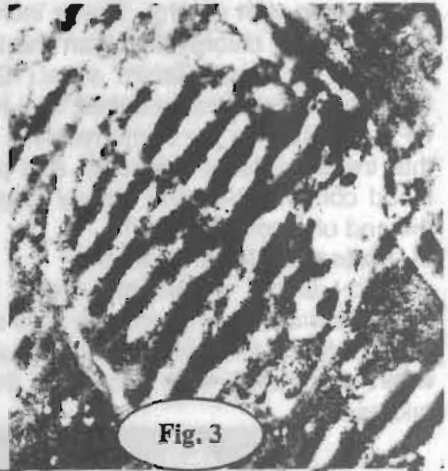

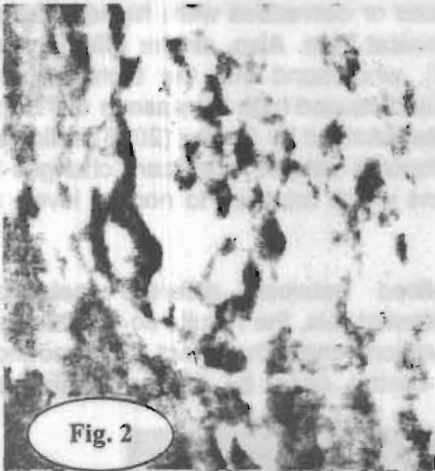
Fig.1

Fig(1): Liver of control rats (X 10 x10<sup>3</sup>).

Histologically, marked reduction in the size of the cells, vacuolation, pyknosis of nuclei and necrosis of numerous cells were observed. Cytopathologically, Golgi bodies lost their normal distribution net-like structure and were fragmented into faintly stained discrete particles which disappeared progressively from the cells with prolonged treatment. Mitochondrial elements were swollen and coalesced together forming few large massive bodies which became hardly visible in cytoplasm. Lysosomes lost their normal distribution and some of them were ruptured.



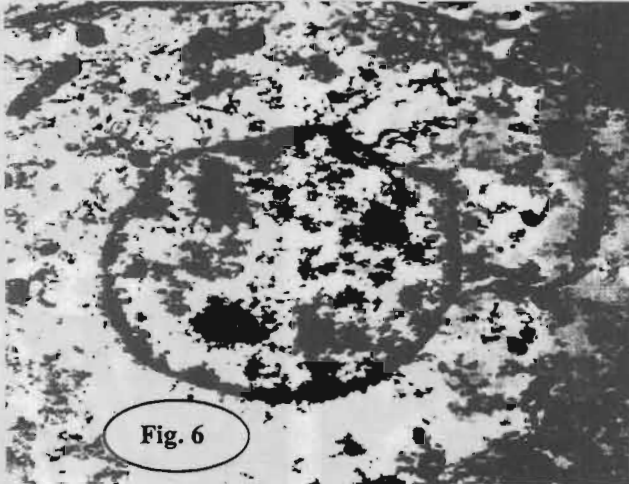
Figure, 2 Liver of treated rats by malatox showing polymorphism of nuclei, irregular of the chromatin and prominent. Figures 3,4 and 5 liver of treated rats by malason, agrothion and naserlathion, respectively, showing no differ significantly in numbers of nuclei and their contains.

On the other hand, some sections poorly differentiated hepatocellular showing marked polymorphis of the nuclei, irregularity of the chromatin and prominent nucleoli in rats treated with malatox Fig(2) when compared with control Fig (1). Also, rats treated with malason, agrothion and naserlathion showed the number of nuclei and their content in different sections by many powers of vision, results appeared no significant difference and all treatments did not induce genotoxicity, Figs(3,4 and 5). The marked increase in serum transaminase activities in response to pesticides manifests their potential hepatotoxic actions as hepatic necrosis accompanied by abnormal increase in serum level of transaminase (El-Garawany *et al.*, 1990)



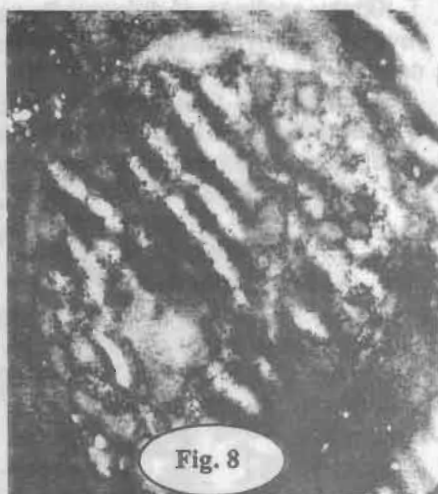
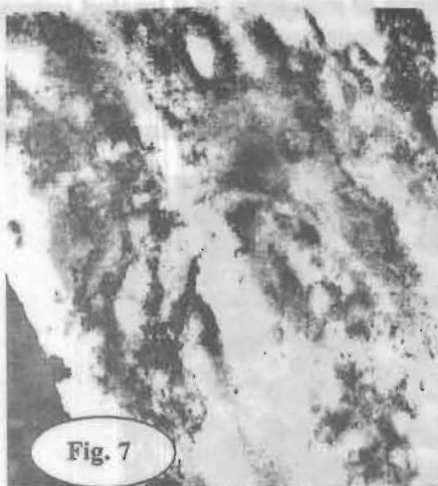Kidney sections of different formulations of malathion (a.i) treated animals, revealed many phases of degenerative changes as compared with those of control.

Histologically, these changes appeared in form of cloud swelling, hydropic degeneration and detached cells. In the cloud swelling phase, the epithelial cells lining the affected tubules became swollen.



**Fig(6): Kidney of untreated rats (X 8x10<sup>3</sup>)**

Cytopathology showed that, the structure of Golgi bodies were demonstrated in renal cells. Formulations application caused serious damage and fragmented these bodies in the form of small particles most of which disappeared from the living cell few remnants scattered in cytoplasm. The normal mitochondria of renal cells were markedly swollen under the effect of insecticides and in some cases, they coalesced together into large bodies. Lysosomes showed a different pattern of localization in the various types of renal cells. Some cells were loaded with lysosomes and others were rather poor. Electron microscope showed poorly differentiated cells containing a cytoplasmic indentation or inclusion filled with brush border material. It also showed, that cytoplasm was filled with prominent granular, endoplasmic reticulum containing some dense flocculam material. Also, electron micrograph appeared, poorly differentiated nuclei and no changes in their content such as nucleolus or chromosomes (chromatid and centromere, Figs ,7,8,9 and 10 ). These changes might due to epithelial necrosis in the renal tubules that were associated with nuclear and chromatin changes (Janssen, 1984). Our results are in agreement with those obtained by Farrag and Shalby (2007), who reported that treated rats by lufenuron and profenofos caused venous congestion in the liver and focal necrosis of hepatocytes in the portal and periportal areas. Many of the hepatocytes were pale-stained and a few exhibited early vacuolation. Also, several cells showed histological features of necrosis. The kidney exhibited inflammatory cell infiltration, congestion and hypercellularity of the glomeruli.



Figures 7, 8, 9 and 10: Kidney of treated rats by malatox, malison, agrothion and naserlathion, respectively, showing poorly differentiated in nuclei and no changes in their contain such as nucleolus or chromosomes.

Data obtained by Abd El-Rahman and Zaki (1992) revealed that in malathion treated mice there damage was in the bile ductules and blood capillaries of the liver. Also, data revealed the lining cells of some renal tubules were completely degenerated and the nuclei of the degenerated renal cells were obviously pyknotic. So, at the doses applied during 30 days, results concluded that all tested malathion formulations didn't show any genotoxicity in treated animals.

Generally, obtained data illustrate the different effects of tested malathion formulations on rats. The high influences of orally formulated malathion may

be due to the synergistic effect of the formulation with the active ingredient. Accordingly, the tested formulations have the same active ingredient, so the different effects may be due to the different inactive ingredient of each compound. There were significant differences between the four formulations of malathion in their effect on the blood content, transaminase activities (AST and ALT), urea and creatinine concentrations. These differences may be due to the differences of the additives. Also, toxic impurities in the pesticide products might be formed during the manufacturing process, during storage, or after opening the sealed pesticide container ( Aly and Abd-El-Rahman, 2004).

## REFERENCES

- Abd El-Rahman, M.F. and Z. T. Zaki (1992): Cytotoxic actions of malathion on renal and hepatic tissues of mice. *J. Egypt Ger. Soc. Zool.*, 8(C) :105-114.
- Abdel-Rahim, E.A.; M.M. Rashed and Ebsam A. Mahmoud (1994): Biochemical studies on the effect of pure and formulated malathion on haemoglobin fractions, cytochrome-c-system and growth rate of albino rats by dermal and oral administration. *Crop Health Conf.*, March 21-24, Fayoum, Egypt, pp. 72.
- Al-Qarawi, A.A.; O.M. Mahmoud; E.M. Haroun; M.A. Sobaih and S.E. Adam (1999): Comparative effects of diazinon and malathion in Najdi sheep. *Vet. Hum. Toxicol.*, 41(5): 287- 289.
- Aly, N. M. and S. M. Abd-El-Rahman (2004): Effect of certain pesticides on some enzymes of chick embryos. *J. Agric. Sci. Mansoura Univ.*, 29(11): 6605 – 6616.
- Anonymous (1991): Guidelines to the WHO recommended classification of pesticides by hazard. *IPCS*, pp.39.
- Anonymous (2004): *The Pesticide Manual*, version 3.1, 2004-05, Thirteen Ed. Editor: C D S Tomlin.
- Anwar, W. A. (1997): Biomarkers of human exposure to pesticides. *Environmental health perspectives*, Supplement 4, June 1997.
- Coulombe, J.J. and L. Farreau (1963): A new simple semi-micro method for colourimetric determination of urea. *Clin. Chem.* 9: 102-108.
- El-Garawany, A.A.; H.A. Samaan and M. Sadek (1990): Comparative hepatorenal toxicity of some commonly used chemical environmental pollutants. *Egypt J. Pharm. Sci.*, Vol. 30, No.e-4, pp. 331-336.
- El-Maghraby, S. (2004): Comparative toxicity of malathion and its metabolite (O,O-Dimethyl phosphorodithio) propionic acid ethyl ester towards mice. *Bull. NRC, Egypt*, Vol. 29(6): 669-680.
- El-Sebae, A.H. (1985): Management of pesticide residues in Egyptian environment. *Appropriate waste management for developing countries*. Kriton Curi.,(Ed) Plenum Publishing Corp, pp. 563.
- Farrag A.H. and Sh.E.M. Shalby (2007): Comparative histopathological and histochemical studies of IGR, lufenuron and profenofos insecticide on albino rats. *J. Appl. Sci. Res.*, 3(5): 377-386.

- Gupta, R.C. and B.S. Paul (1978): Influence of malathion (O,O- dimethyl dithiophosphate of diethyl mecaptosuccinate) on some biochemical and haematological parameters during dermal subacute toxicity study in buffaloes (*Bubalus bubalis*). Ind. J. Anim. Sci., 48(6): 428- 431.
- Guzman, R.E.; P.F. Solter and M.T. Runnegar (2003): Inhibition of nuclear protein phosphatase activity in mouse hepatocytes by the cyanobacterial toxin microcystin-LR. Toxicon. 41(7): 773-782.
- Henry, R.J. (1974): Clinical chemistry, Principles and Technics, Harber and Row Publ., NY, pp. 197
- Hoffman, D.J.; W. J. Spann, L. J. Lecaptain, C. M. Bunch and B. A. Rathner (1991): Developmental toxicity of phenyl ether herbicide in nesting. American J. Toxi. And Environ. Health, 26 (2): 201.
- Janssen, W. (1984): Forensic Histopathology. Spring- Verlag, Berlin, NY, pp. 314-315.
- Li, X.; Y. Liu; L. Song and J. Liu (2003): Response of antioxidant systems in the hepatocytes of common carp (*Cyprinus carpio*) to the toxicity of microcystin-LR. Toxicon. 42(1): 85-90.
- Mitema E.S. and J.B. Masha (1984): Organophosphate poisoning in cattle: A report of clinical cases. Vet. Med., 79: 111- 114.
- Reitman, S. and Frankel, S. (1957): A colourimetric method for determination of serum glutamic oxaloacetic and glutamic pyruvate transaminases. Amer. J. Clin. Path., 28: 26-33.
- Saleh, Amal Y. (1997): Toxicological influence of technical and formulated chlorpyrifos on blood fractions, respiratory cytochrome- c- system and growth rate of male albino rats (*Rattus norvegicus*). J. Agric. Sci. Mansoura Univ., 22 (7): 2483-249.
- Schalm, O.W. (1986): Veterinary Hematology. 4<sup>th</sup> Ed., Lea and Fibiger, Philadelphia, pp.21-86.
- Shalby, Sh.E.M. (2006): Comparative haematological and hepatorenal toxicity of IGR, lufenuron and profenofos insecticide on albino rats. J. Egypt Soc. Toxicol., Vol.34 (Jan.): 85-98.
- Snedecor, G.W. and W.G. Cochran (1980): Statistical Methods. 7<sup>th</sup> (Ed). State university press, Ames, Iowa.

**تأثير بعض مكونات الدم والتركييب الدقيق لكبد و كلى الفئران البيضاء نتيجة التعرض**

**In Vivo لبعض مستحضرات مييد الملاثيون**

**عادل عبد المنعم صالح<sup>1</sup> و شحاته السيد محمد شلبي<sup>2</sup>**

**١- قسم المبيدات - كلية الزراعة - جامعة المنصورة**

**٢- قسم أفات ووقاية النبات - المركز القومي للبحوث- دقي - القاهرة- مصر**

في الأونة الأخيرة زادت عدد المستحضرات التجارية للمبيد الواحد والتي تحتوي على نفس تركيز المادة الفعالة والمتجة من شركات مختلفة ومن المؤكد اختلاف المواد المضادة من مستحضر لأخر مما يؤدي إلى اختلاف الكفاءة الابادية لهذه المستحضرات عند استخدامها في مكافحة الآفات الموصى باستخدامها على الرغم من احتواءها على نفس تركيز المادة الفعالة ومن المرجح اختلاف تأثيرها السام على حيوانات التجارب.

لذلك يهدف هذا البحث إلى دراسة الأثر السام لأربعة مستحضرات شائعة الاستخدام لمبيد الملاثيون ( الملاتوكس، الملاسون، الاجروثيون والنصرلاثيون) والتي تحتوي على نفس تركيز المادة الفعالة (٥٧ %) على الفئران البيضاء. تم تقسيم حيوانات التجارب إلى خمسة مجموعات (بكل منها ١٠ فئران) الأربعة الأولى منها تعاملت بـ ١٠٠ مجم / كجم من وزن الجسم لكل مستحضر من المستحضرات السابقة ( جرعة كل يومين لمدة شهر) وتركت المجموعة الخامسة كمجموعة ضابطة. أخذت عينات من دم الحيوانات بعد ٣٠ يوم من المعاملة وذلك لدراسة تأثير المركبات المختبرة على بعض مكونات الدم (عدد كرات الدم الحمراء RBCs والبيضاء WBCs ونسبة الهيموجلوبين Hb وعدد الصفائح الدموية Platelets count ) ونشاط انزيمي الترانس امينز (AST and ALT activities) وتركيز الكرياتينين واليوريا كذلك أخذت عينات من الكبد والكلى للفئران المعاملة لدراسة مدى للتغير في بعض التركيبات الدقيقة لهذه الأنسجة باستخدام الميكروسكوب الالكتروني ثم تركت الفئران بدون معاملة لمدة ٧ أيام بعد آخر جرعة، ثم أخذت عينات من الدم لدراسة مدى استشفاء هذه الحيوانات.

وكانت أهم النتائج كالآتي:

١. حدوث نقص معنوي في عدد كرات الدم البيضاء في الفئران المعاملة بالملاتوكس والنصرلاثيون (-٤٦,٦% و-٢٥,٩%) بينما حدث العكس في المعاملة بالملاسون (+١٠,٣%) بعد ٣٠ يوم من المعاملة، ثم عادت إلى المستوى الطبيعي بعد فترة الاستشفاء ما عدا تلك المعاملة بالنصرلاثيون (-١٠,٤%).
٢. كل المركبات المختبرة أدت إلى نقص معنوي في عدد كرات الدم الحمراء بعد ٣٠ يوم من المعاملة ولم تعد إلى المعدل الطبيعي خلال فترة الاستشفاء، أعلى تأثير لوحظ في الفئران المعاملة بالاجروثيون بعد ٧ أيام من توقف المعاملة (-٣٨,٣%) ثم المعاملة بالملاتوكس بعد ٣٠ يوم من المعاملة (-٣١,٣%)، نفس الاتجاه السابق لوحظ في تأثير للمركبات السابقة على نسبة الهيموجلوبين وعدد الصفائح الدموية، حيث حدث نقص معنوي في كل المعاملات بعد ٣٠ يوم من المعاملة مع عدم العودة إلى المعدلات الطبيعية بعد فترة الاستشفاء.
٣. حدوث زيادة معنوية في نشاط انزيمي الترانس امينز (AST & ALT) في كل المعاملات بعد ٣٠ يوم من المعاملة مع عدم العودة إلى المعدلات الطبيعية بعد فترة الاستشفاء ما عدا تلك المعاملة بالاجروثيون حيث انخفض نشاط انزيم ALT إلى مستواه الطبيعي بعد فترة الاستشفاء (+٢,٧%).
٤. حدوث زيادة معنوية في تركيز الكرياتينين في الفئران المعاملة بالملاتوكس (+٦٢,٥%) بعد ٣٠ يوم من المعاملة مع عدم العودة إلى المعدل الطبيعي بعد فترة الاستشفاء (+٤٢,٩%)، بينما لم يحدث تغير معنوي في باقي المعاملات. لوحظ نفس التأثيرات على تركيز اليوريا بعد شهر من المعاملة ولكن بعد فترة الاستشفاء حدث زيادة معنوية في معاملات الملاتوكس والنصرلاثيون (+٤٦,٩% و+٢٨,٠%) بينما حدث نقص معنوي في الفئران المعاملة بالاجروثيون (-٢١,٩%).
٥. أظهر الفحص الميكروسكوبي لكبد الفئران المعاملة حدوث موت موضعي لبعض الخلايا كذلك فقدت أجسام جولجي والليسوسومات التوزيع الطبيعي لها، انتفاخ الميتاكوندريا واتحادها لتكوين أجسام كبيرة كذلك وجد أن الأنوية أخذت أشكالاً متعددة وعدم انتظام الكروماتيد. وقد وجد أن الملاتوكس أكثر تسائيراً من باقي المستحضرات الأخرى.
٦. كذلك أظهر فحص كلى الحيوانات المعاملة بالميكروسكوب الالكتروني أن كل المعاملات أدت إلى حدوث تحطم وموت موضعي للخلايا، كذلك حدوث تحطم وتجزئة أجسام جولجي وتحولها إلى أجسام صغيرة. انتفاخ الميتاكوندريا واتحادها معاً وكونت أجسام كبيرة كما أن بعض الخلايا تحتوي على عدد كبير من الليسوسومات والبعض الآخر يحتوي على عدد قليل، كذلك وجد في بعض المعاملات احتواء الشبكة الاندوبلازمية على خيوط كثيفة. أيضاً أظهر الفحص الميكروسكوبي الالكتروني حدوث تغير طفيف في الأنوية ومحتوياتها مثل للنويات والكروموسومات.