

## **DERMOID CYSTS IN DONKEYS**

**A.M. ABU-SEIDA and KAWKAB A. AHMED\***

Dept. of Surgery, Anaesthesiology and Radiology, Cairo Univ. Giza, 12211, Egypt.

\* Dept. of Pathology, Faculty of Veterinary Medicine , Cairo Univ., Giza, 12211 Egypt.

**Received:** 20.10.2006.

**Accepted:** 16.12.2006.

### **SUMMARY**

Dermoid cyst was recorded in five donkeys at the ventral aspect of the cranial third of the neck just caudal to the larynx. All cases were congenital. The cyst appeared as painless, fluctuating, movable circumscribed swelling containing coffee-coloured fluid, hair tufts and greyish greasy scales. The clinical, ultrasonographical and histopathological findings were described. Careful surgical excision of the cyst was curative in all cases.

---

### **INTRODUCTION**

Dermoid cyst is a rare developmental anomaly often congenital or hereditary, manifested by focal reduplication of the entire skin structure, including epidermis and adnexa.

It was recorded in goats and camels at the antero-ventral aspect of the upper third of the neck near to the jugular vein (Gamlem and Crowford, 1974; Purohit et al., 1989; Ramadan, 1994 and Fouad et al., 2001), in horses at the temporal region (Mason, 1974) and in cattle at the periorcular region (Adams et al., 1983).

The cyst may be solitary or multiple, monocular or multilocular. It usually presents at the head or neck regions containing hair tufts and coffee coloured fluid (Ramadan, 1994 and Abu-Seida, 1998).

This study records, for the first time clinical, ultrasonographical and histopathological findings of dermoid cysts in five donkeys.

## MATERIALS AND METHODS

During the period between December 2002 and October 2006, five donkeys were admitted to the veterinary clinic at Faculty of Veterinary Medicine Cairo University for the presence of soft, fluctuating, painless swelling located at the upper third of the neck. The history and findings of the physical examination were reported. Aseptic exploratory puncture of the swelling was carried out. The observed swellings were examined ultrasonographically using 5MHz<sub>2</sub> convex probe after application of the ultrasound coupling gel.

Careful surgical excision of the swellings was performed under deep narcosis achieved by intravenous administration of 10% solution of chloral hydrate at a dose of 5 grams per 50Kg body weight.

The excised swellings were aspirated and the amount of fluid was measured. The interior of the swellings was examined and all findings were reported.

For histopathological examination, specimens from the swellings were fixed in 10% neutral buffered formalin, processed by conventional paraffin embedding technique, sectioned and stained with haematoxylin and eosin.

## RESULTS

The affected animals (3 males and 2 females) were 4-8 years old. Their weight ranged between 150-250Kg.

All cases has a common history of a slowly growing painless swelling which had been present since birth. It was hard in the beginning then it softened by the time. The swellings seemed to cause little inconvenience to the animals.

In all cases the swelling was present at the ventral aspect of the cranial third of the neck just caudal to the larynx (Fig. 1a&b).

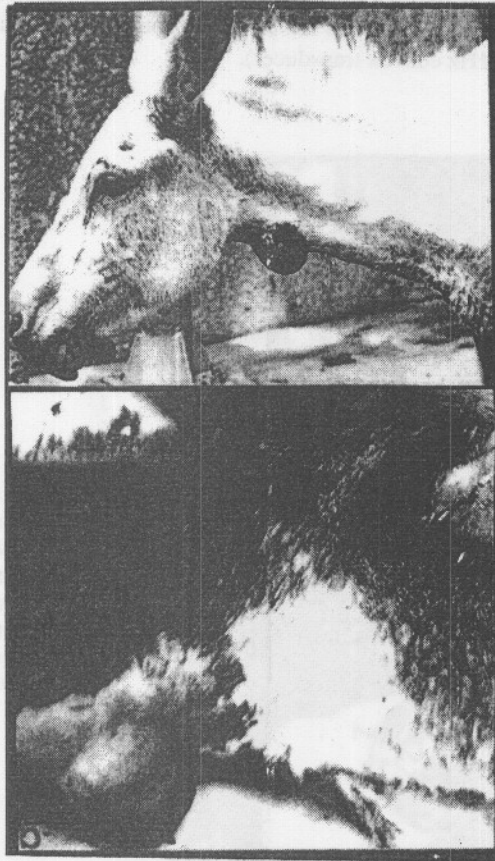
The clinical examination revealed soft, fluctuating, painless, clearly defined, freely movable circumscribed swelling of 5-10cm diameter. The skin over the swelling was normal in all cases. Exploratory puncture yielded brown thin fluid without bad odour except one cyst which had greyish white pus. Ultrasonographically, the cyst appeared as a sac surrounded with hyperechoic thick capsule and contained a mixture of anechoic areas and hyperechoic irregular masses (Fig.2).

Surgical excision of the cyst was curative in all cases without any recurrence during a period of 6-12 months postoperative.

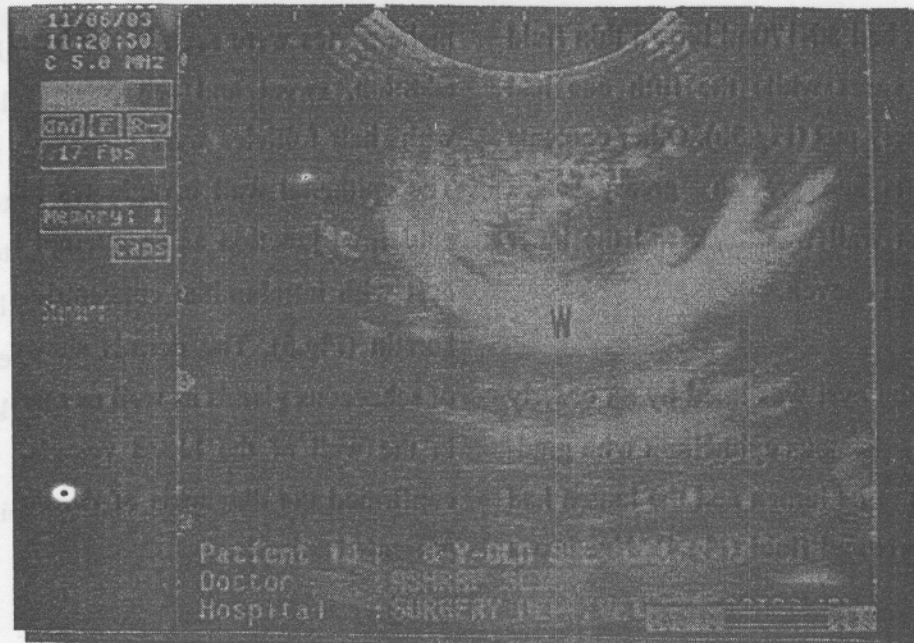
The excised cysts had 50-170ml brown thin fluid (Fig.3a) in four cases while the fifth one had greyish white watery pus (Fig.3b). Other contents included hair tufts and greyish greasy scales (Fig.3c). The cyst wall was thick and the inner lining was grey and uneven.

Microscopically the cyst was lined by an orderly wall of stratified squamous epithelium with gradual keratinization at its lumen and the lumen had parts of hair, debris and fluid (Fig.4). Numerous

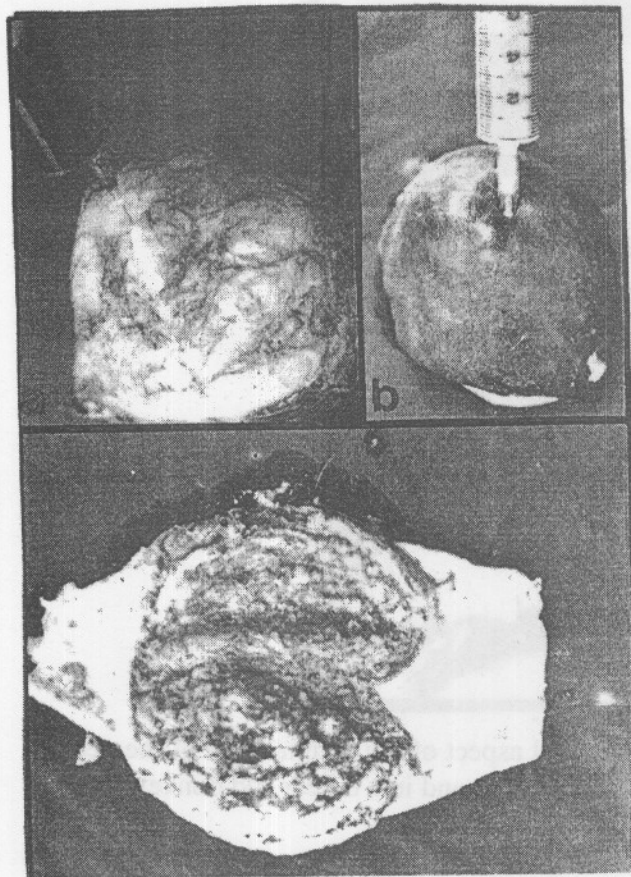
melanocytes were seen in the basal cell layer. In addition, sweat and sebaceous glands together with hair follicles were observed in the dermis. The epithelial wall invaginates into the dermal-epidermal junction as an attempt to form a new cyst with intraluminal concentric laminations of keratin (Fig.5). The dermis showed hyperplasia of sebaceous glands as well as marked thickening in the wall of the blood vessels. These results confirmed the diagnosis of dermoid cysts in the presented animals.



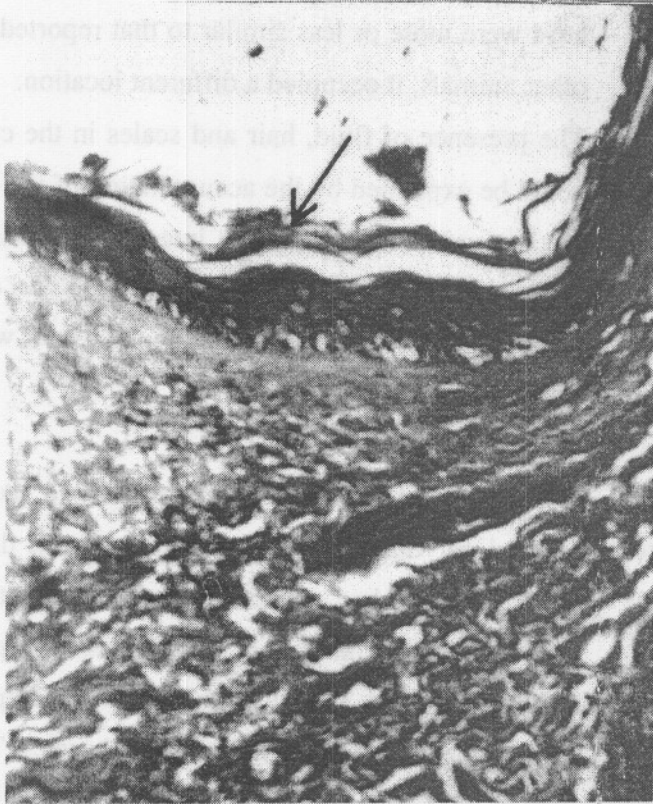
**Fig. 1:** Dermoid cyst at the ventral aspect of the cranial third of the neck in an 8-year-old she-donkey (a) and in a 6-year-old donkey (b).



**Fig.2:** Ultrasonogram of the cyst showing anechoic areas of fluid separated by hyperechoic masses of hair and scales and surrounded with thick hyperechoic wall (W) (5-MHz convex transducer).

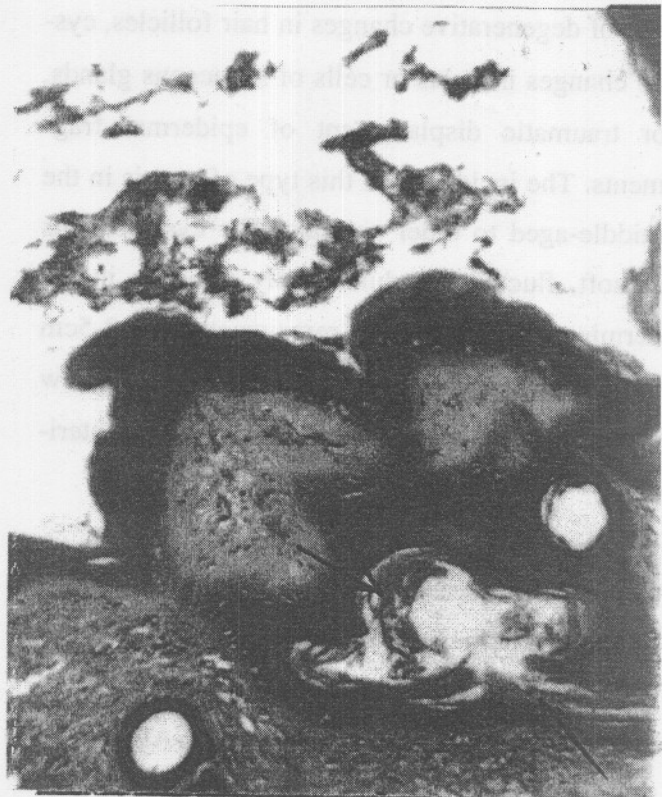

**Fig.3:** (a) Aspiration of coffee-coloured fluid from the excised cyst.  
 (b) Aspiration of greyish white pus from an infected excised cyst.  
 (c) The interior of the cyst showing uneven greyish skin, hair tufts and greasy scales.



**Fig.4.** Photomicrograph of the cyst wall showing stratified squamous epithelium and gradual keratinization . (H & E stain x 100).

**Fig.5.** Photomicrograph of the cyst wall showing invagination of the epidermis into the dermis to form a daughter cyst with characteristic intraluminal keratin laminations (arrows) (H&E stain x 100).



## DISCUSSION

Although dermoid cysts have been reported in most of the domestic animals, no data are present in the available literature regarding this lesion in donkeys.

Dermoid cyst develops as a result of aberration in the folding of the ectoderm and blastoderm in the embryo. However, it also develops by traumatic implantation of the epidermis (Jubb et al., 1985). Congenital epithelial dysplasia is the most widely proposed cause. The donkeys in this study were genetically unrelated and hence an inherited cause seems unlikely.

In contrast, epidermal cysts are probably the result of degenerative changes in hair follicles, cystic changes in ducts or cells of sebaceous glands, or traumatic displacement of epidermal fragments. The incidence of this type of cyst is in the middle-aged to older animals. The cyst presents as soft, fluctuant nodule, freely movable in the dermis. The size usually remains static (0.2-5cm in diameter). The cyst contains tan-yellow caseous material representing sebaceous material.

The present report documents dermoid cyst in identical locations in five donkeys. Only one cyst was observed in each donkey. Meanwhile, bilateral cysts were recorded in camels (Abu-Seida, 1998).

Although the contents of the dermoid cyst in donkeys were more or less similar to that reported in other animals, it occupied a different location.

The presence of fluid, hair and scales in the cyst could be explained by the accumulation of the secretion and sheddings of the internal skin inside the cyst. Aspiration of pus from one case was explained by entering of infection by the owner who tried to evacuate the cyst.

Ultrasonographic examination proved a good method for diagnosis of dermoid cysts in donkeys. The cyst had an heterogenous echopattern as it contained a mixture of anechoic areas representing the fluid and hyperechoic masses representing the accumulated hair tufts and scales. The wall of the cyst was thick and hyperechoic as it is lined with skin.

The surgical excision of the cyst was the radical treatment, however, careful blunt dissection was essential to separate the cyst from the surrounding vital structures. Similar findings were mentioned by Ramadan (1994) in camels.

Histopathology was a confirmatory method for diagnosis of dermoid cyst revealing wall lined with well differentiated skin. The invagination of epidermis into dermis resulted in a new cyst (daughter cyst) hence multilocular appearance. The mother cyst may be seen. In conclusion, dermoid cyst in donkeys should be encountered among the other neck swellings including

moid cyst in donkeys should be encountered among the other neck swellings including abscesses, hematomas and tumors. Ultrasonography is a good method for the differential diagnosis.

## REFERENCES.

- Abu-Seida, A. (1998): Studies on surgical skin affections in ruminants M.V.Sc. Thesis, Cairo Univ. P 66.
- Adams, S., Horstman, L. and Hoerr, F. (1983): Periocular dermoid cyst in a calf. *J.Am. Vet. Med. Assoc.*, 11:1255.
- Fouad, K., Gohar, H., Sheta, E., El-Mahdy M. and Abu-Seida, A. (2001): Dermoid cysts in camels. *J. of Egypt. Vet. Med. Assoc.*, 61 (6): 255-260.
- Gamlem, T. and Crowford, T. (1974): Dermoid cysts in identical locations in a doe and her kid. *Veterinary Medical Small Animal Clinician*, 72: 626-627.
- Jubb, K., Kennedy, P. and Palmer, N. (1985): *Pathology of Domestic Animals*. 3rd. ed. New York, Academic Pres: 639-640.
- Mason, B.J. (1974): Temporal teratomata in the horse. *Vet. Rec.*, 95: 226-228.
- Purohit, N., Chouhan, S., Dudi, P. and Vayas, U (1989): Dermoid cyst in camels. *Br. Vet. J.*, 145:89-90.
- Ramadan, R.O. (1994): *Surgery and Radiology of the Dromedary camels* 1<sup>st</sup> ed. Aljaward Printing Press, Kingdom of Saudi Arabia. 198-199.

## الحويصلة الجلدانية فى الحمير

أشرف محمد عبدالرحمن أبوسعدة\* ، كوكب عبدالعزيز أحمد\*\*

\* قسم الجراحة والتخدير والأشعة - كلية الطب البيطرى - جامعة القاهرة

\*\* قسم الباثولوجيا - كلية الطب البيطرى - جامعة القاهرة

فى هذه الدراسة تم تسجيل الحويصلة الجلدانية فى خمسة حمير وذلك فى الإتجاه البطنى للثالث القحفى للرقبة خلف الحنجرة مباشرة. وقد كانت كل الحالات تشوهات خلقية.

وقد ظهرت الحويصلة كورم محدود، مترجرج، غير مؤلم ويحتوى على سائل بنى وخصلات شعر وقشور. وقد شفيت هذه الحالات جميعاً بعد الإستئصال الجراحى للحويصلات.

هذا وقد تم فى هذه الدراسة مناقشة نتائج الفحوص الحقلية وبالموجات فوق الصوتية والنسجية.