

## PATHOLOGICAL AND IMMUNOHISTOCHEMICAL STUDIES ON BRUCELLA MELITENSIS IN COWS

EL-NESR, KH. A. MAHDY, E. SHALABY, A. and DEEB, S.

Dept. of Pathology, Faculty of Veterinary Medicine, Beni Suef Univ.

Received: 12.3.2007.

Accepted: 16.3.2007.

### SUMMARY

The present study was carried out on 48 brucella positive- slaughtered cows, 37 animals from the Experimental Station belonging to the Faculty of Veterinary Medicine Beni Seuf University and 11 animals from a private farm at Ehnasia, Beni Seuf governorate. The pathological study revealed the presence of individual variations with respect to organs affected, extension and severity of lesions. Granulomatous reactions were detected in lymphoreticular tissues and also in the liver, kidneys, lungs and udder. Epithelioid cell and giant cell granulomas were predominating in the lymph nodes and liver and tuberculous-like granulomas were found in the kidneys and lung. By immunostaining, *Brucella melitensis* could be detected in organs and lymph nodes.

**Key Words:** Histopathology, *Brucella melitensis*, Immunohistochemistry, Cattle, Granuloma.

### INTRODUCTION

As stated by Jones and Hunt (1998), bovine brucellosis is a bacterial disease usually caused by *Brucella abortus*, less frequently by *B. melitensis*, and rarely *B. suis*. The tendency of the organism to circulate throughout the body in the blood at one stage and to localize in certain organs at a later stage is typical, but differs between species. In bovines, the placenta, mammary gland, supra- mammary lymph nodes in cows and the testicles and epididymis in bull are common sites of localization of *B. abortus* lesions. Abdel-Hafees et al. (1996) found acute lymphadenitis associated with sinus catarrh with neutrophils, plasma cells, and macrophages and sever congestion of the lymph nodes in cattle infected with brucellosis. Activation of lymphoid follicles and cortical lymphocytic depletion with

granulomatous foci were observed by Doghiem et al. (1995). Brucellosis caused by *Brucella melitensis* is considered as one of the highly important cattle disease in Egypt (Ali, 1998).

Immunohistochemistry was used for detection of brucella microorganisms in different animal species; cows (Meador et al., 1986; Perez et al., 1998 and Sozmen et al., 2004), sheep and goat (Yazicioglu, 1997 and Meador et al., 1986).

The present work deals with the pathological changes in the parenchymatous organs and lymphoid tissues which associated with spontaneous infection with this strain of brucella affecting a herd of cattle in an experimental station belonging to the Faculty of Veterinary Medicine Beni Seuf, Egypt. Detection of infection by immunohistochemical reaction was carried out.

## **MATERIAL AND METHODS**

### **Animals:**

A total number of 48 cows, serologically positive for brucellosis., 37 from the experimental station belonging to the Faculty of Veterinary Medicine Beni Seuf University, and 11 cows from a private farm at Ehnasia Beni Seuf province,. These animals were

tested against brucellosis using Rose Bengal and Tube agglutination tests. The serodiagnosis was carried out by the official veterinary authorities in a program called (Brucella Test and Slaughter program). Out of these animals, 3 cows only were pregnant. No abortions were recorded.

### **1- Pathological samples:**

After slaughtering, postmortem examination was carried out and gross lesions were recorded. Tissue specimens were collected from slaughtered, serologically brucella positive cows; the specimens included lymph nodes (prescapular, prefemoral, retropharyngeal, submaxillary, bronchial, mediastinal, mesenteric, popliteal, and supramammary), liver, lung, heart, kidneys, spleen, uterus, ovaries, and placenta in addition to one foetus of the slaughtered pregnant animals. The samples were fixed in 10 % formalin solution and processed by conventional method. Paraffin sections, 5-7 $\mu$  were prepared and stained by Hematoxylin and eosin according to Bancroft and Stevens (1996).

### **2- Preparation of specific antiserum:**

*Brucella melitensis* antigen (Veterinary Serum and Vaccine Research Institute, Abbasia, Egypt) was used for this purpose. The antigen (1 ml) was inoculated subcutaneously in the

neck of a rabbit; two booster doses were given 1 week interval. Blood was collected 4 weeks after inoculation, and serum was separated and stored until needed.

### **3-Immunohistochemical study:**

Indirect Avidin-Biotin Complex technique (ABC) (Dako Envision kit K4011 from Santa Cruz, sc-5565, USA) was applied to tissue sections showing reaction related to brucellosis according to Falini et al., (1983) and Sozmen et al., (2004).

## **RESULTS**

Gross pathological examination revealed no much change. Lymph nodes, especially supramammary, and spleen were relatively enlarged. The livers of two cases were hyperaemic and inflamed, the lung of these cases were enlarged and edematous and showed isolated areas of hepatization. One kidney was inflamed and showed nodules that had caseous foci. The udder appeared reddened and inflamed. Histopathological findings are summarized in tables 1-3.

### **Lymph nodes:**

The lymph nodes of most cases showed varying degrees of lymphoid hyperplasia. In some of these cases, the germinal centers of lymphoid follicles were wide and

showed the feature of sky star as an indication of active phagocytosis, and surrounded by narrow or wide zone of mature lymphocytic layer.

Sinus catarrh characterized by mild to severe infiltration with lymphocytes admixed with plasma cells, histiocytes and occasionally epithelioid cells observed in the paracortical areas of subcapsular (Fig. 1), trabecular, and medullary sinuses. The lymph spaces within the lymph nodes were dilated and filled with mononuclears.

Granulomatous reactions of different patterns were observed in examined lymph nodes. Diffuse infiltration by herds of plasma cells and histiocytes was found in the cortical area of some lymph nodes. Epithelioid cell granulomas were characteristically seen in most of the lymph nodes (Fig. 2). These granulomas characterized by aggregates of polyhedral epithelioid cells with foamy cytoplasm and vesicular ovoid or spherical nuclei. Some of the bronchial and mediastinal lymph nodes showed phagocytic activity and may be laden with fine particulates which impart them a dark color. Epithelioid cells showed the tendency to form giant cells in some cases. Single isolated giant cell (Fig. 3) or giant cell granulomas consisted of groups



of epithelioid cells and giant cells which may stand alone in the cortical parenchyma. Granulomas were also occasionally found in the germinal centers of lymphoid follicles.

#### **Liver:**

The hepatocytes showed degenerative changes (vacuolar degeneration) and minimal necrobiotic changes. Karyomegaly was seen in some hepatocytes. The hepatic cords were dissociated due to presence of edematous fluid. In most cases, active proliferation of Von Kupffer cells was common. Diffuse or multifocal infiltrates with mononuclear cells, mainly lymphocytes and plasma cells, were seen all over the hepatic parenchyma of a few cows (Fig. 4). In other cases, epithelioid cells were found in aggregates intermixed with lymphocytes forming microgranulomas within the sinusoids, sometimes associated with giant cells (Fig. 5 & 6), these granulomas were diffusely distributed in the hepatic parenchyma. Infiltration of the portal triads with lymphocytes was occasionally seen. The fetal liver showed mild degenerative changes. Lymphangioma was seen in five cases.

#### **Kidneys:**

The histopathological alterations of most cases consisted of vacuolar degeneration of the lining epithelium of the renal tubules with mild pyknosis. Focal interstitial nephritis was found in other cases. Granulomatous reaction was seen in only 2 cows at the corticomedullary junction of the renal tissue in the form of multiple typical granulomas (Fig. 7), some of the granulomas consisted mainly of cellular reaction comprising epithelioid cells and/or giant cells and lymphocytes with central area of caseous necrosis with minimal calcification and encapsulation (Fig. 8), in some granulomas, liquefaction could be seen. In other areas the reaction was in the form of multifocal areas each consisted of epithelioid cells accumulation and/or giant cells admixed with lymphocytes without caseation (Fig. 9). Cellular reaction comprising epithelioid cells, giant cells, polymorphs, and lymphocytes that encircled the necrosed center was also seen in some granulomas (Fig. 10). Some granulomas showed agglomeration and were surrounded by a thin fibrous connective tissue capsule, peripherally, the connective tissue fibers underwent hyalinization. The glomeruli of the affected



areas showed marked atrophy and dilatation of the Bowman's spaces and many were destroyed. The blood vessels were surrounded by leucocytic infiltration. The renal tubules showed vacuolar degeneration and very mild necrobiotic changes. Tubulonephrosis and hyaline casts were found in some renal tubules. Other areas of the kidney showed focal interstitial nephritis.

#### **Lungs:**

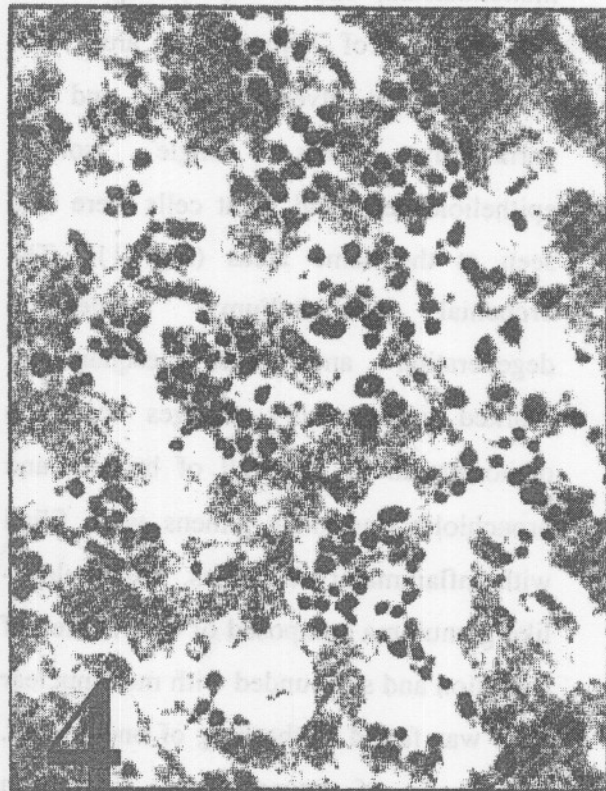
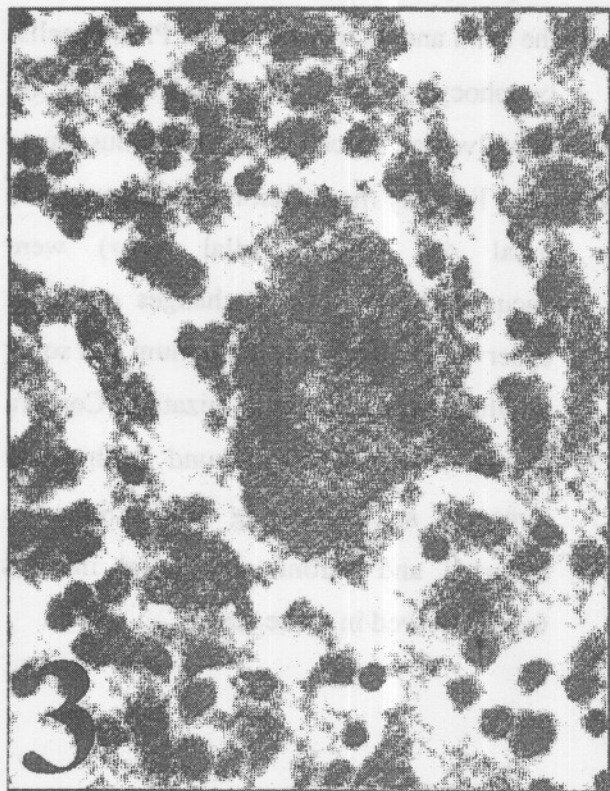
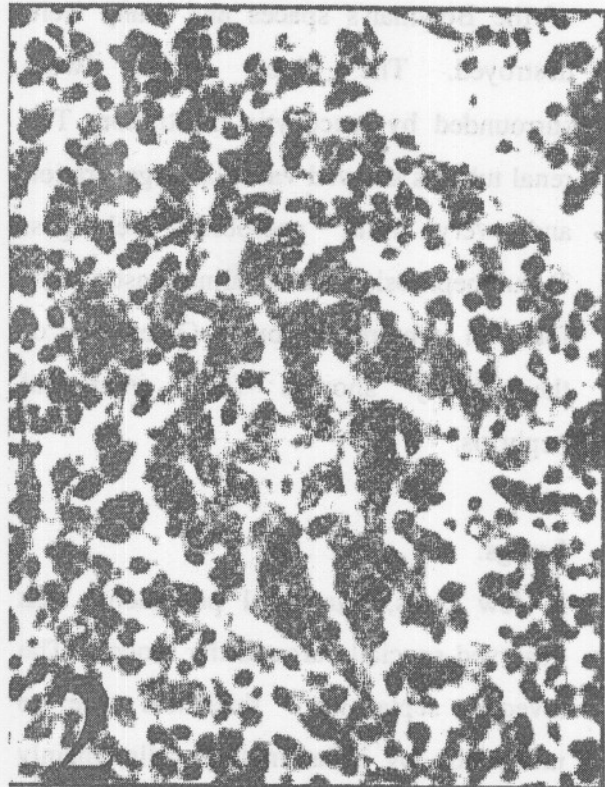
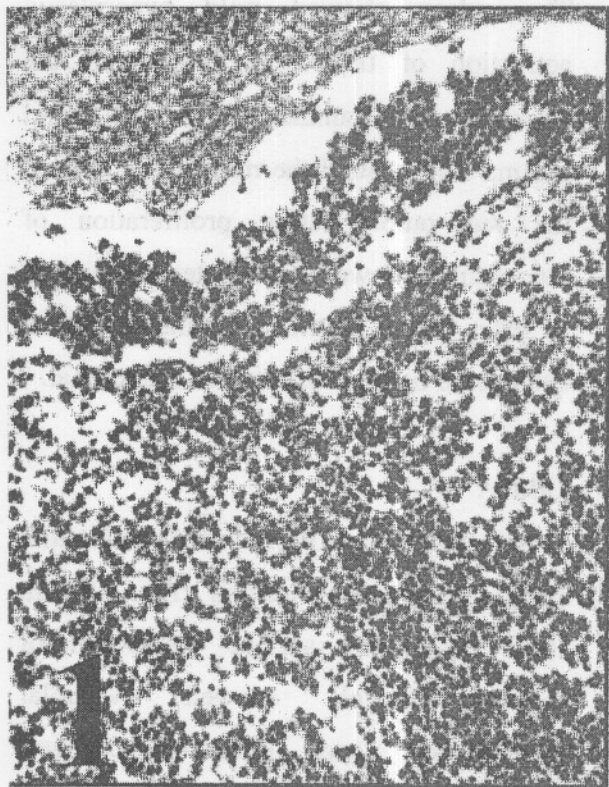
In few cows, interstitial pneumonia was observed specially around the bronchi. The alveolar septa were thickened due to infiltration by inflammatory cells, mainly mononuclears, and few polymorphs with the presence of hemorrhagic areas and edema in the alveolar spaces and the perialveolar areas. Single isolated epithelioid cells and giant cells were also seen at the same areas (Fig. 11). The bronchial epithelium underwent degeneration and was desquamated. Marked inflammatory changes could be demonstrated in the wall of bronchi and bronchioles and their lumens were filled with inflammatory exudates. Tuberculous-like granuloma composed of central area of caseation and surrounded with mononuclear cells was found in the lung of one animal. The lungs of fetuses were free from pathological alterations.

#### **Spleen:**

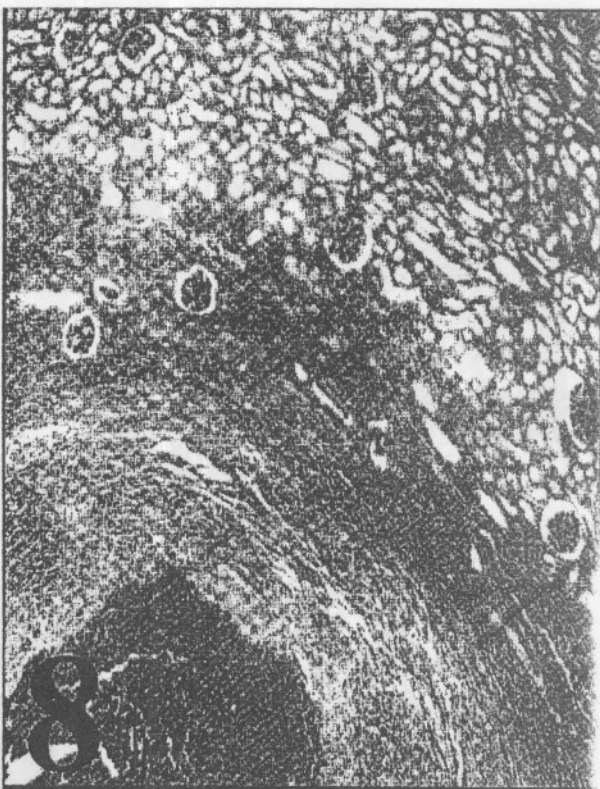
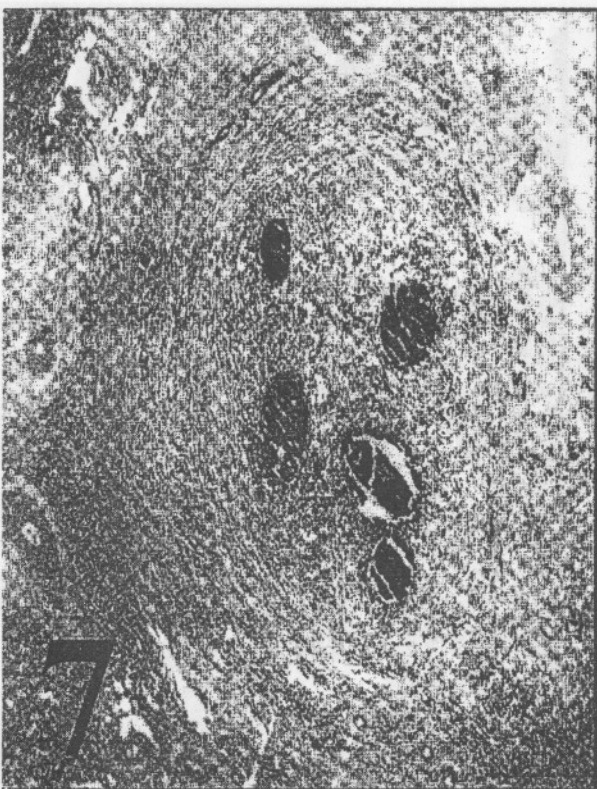
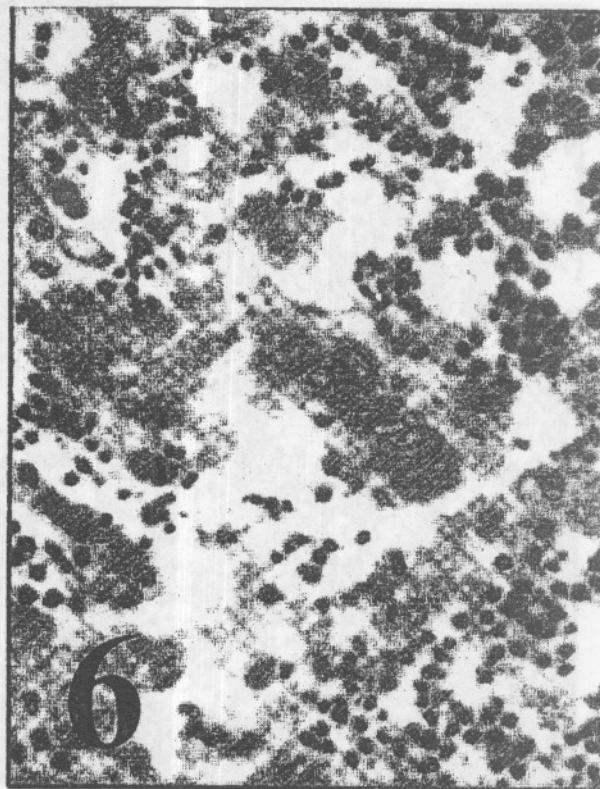
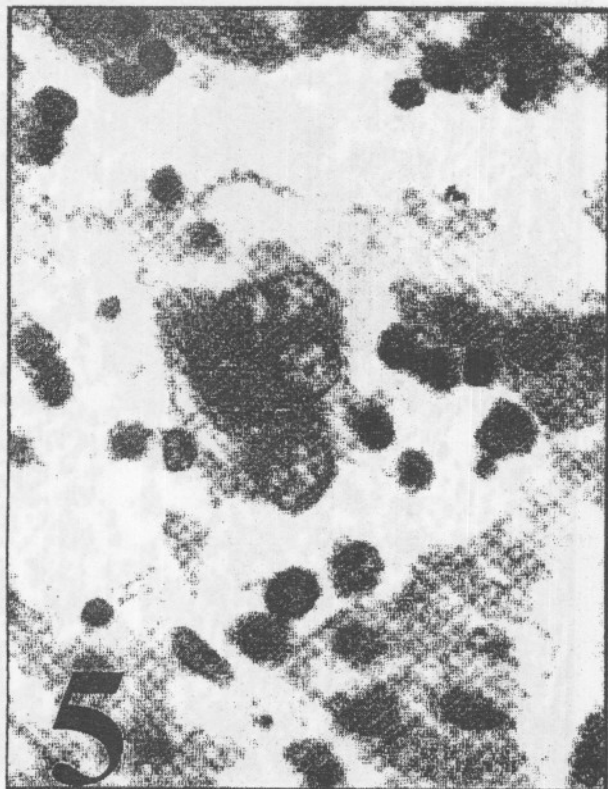The spleen showed mild hyperplastic activation of the white pulp with the presence of abundant histiocytes and plasma cells around the medullary cords of the red pulp. Active proliferation of reticulum cells was a characteristic picture in most cases. Epithelioid cells and giant cells could be demonstrated in one animal.

#### **Udder:**

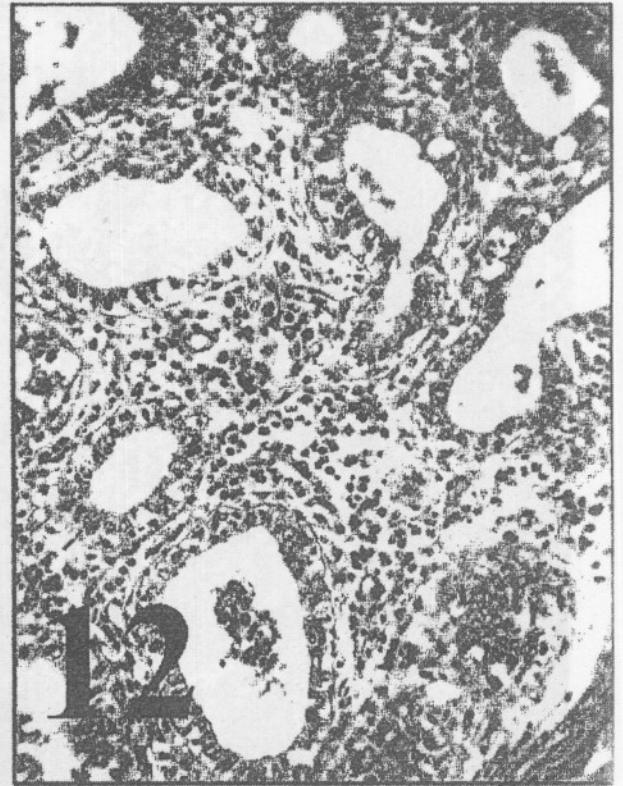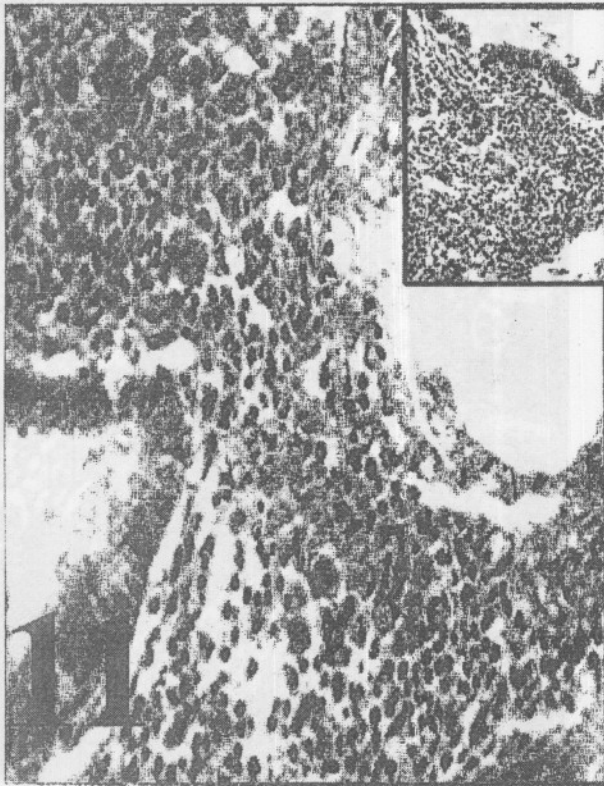
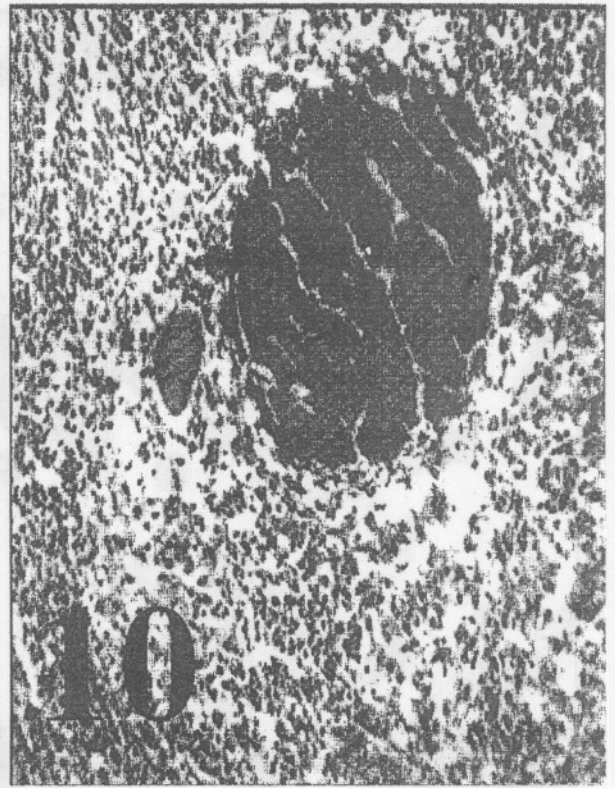

Some cases had pronounced interstitial lymphoplasmacytic mastitis (Fig. 12). In these cases, the surface epithelium of lactating acini showed vacuolar degeneration and pyknotic changes. Polymorphs were frequently found within the acini and lactiferous ducts. Plasma cells, lymphocytes and histiocytes infiltrated the interalveolar spaces. The lactiferous ducts were lined by more than two cell layers, the basal one (myoepithelial layer) were vacuolated. Metaplastic changes could be observed in lactiferous epithelium and some of which underwent keratinization. Corpora amylicia was clearly found within the lumen of some lactating acini. Subacute catarrhal and chronic interstitial mastitis were observed in some cases.

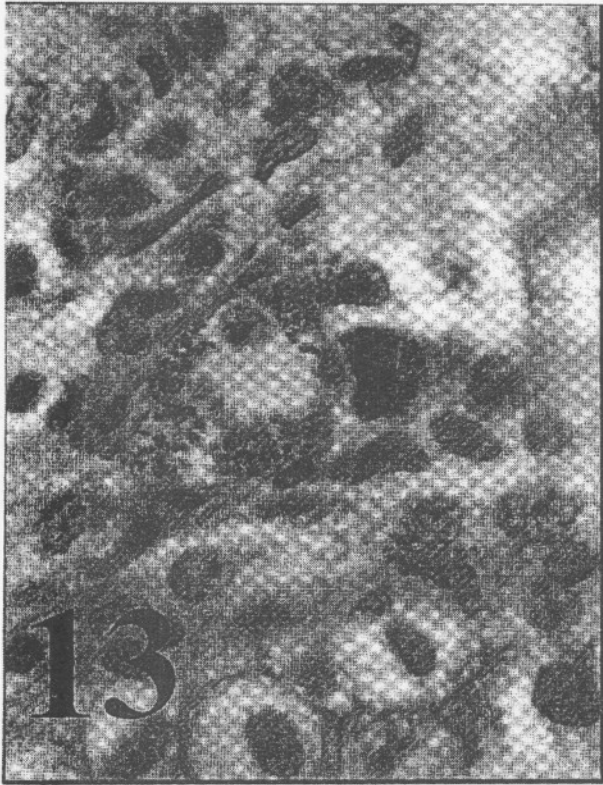




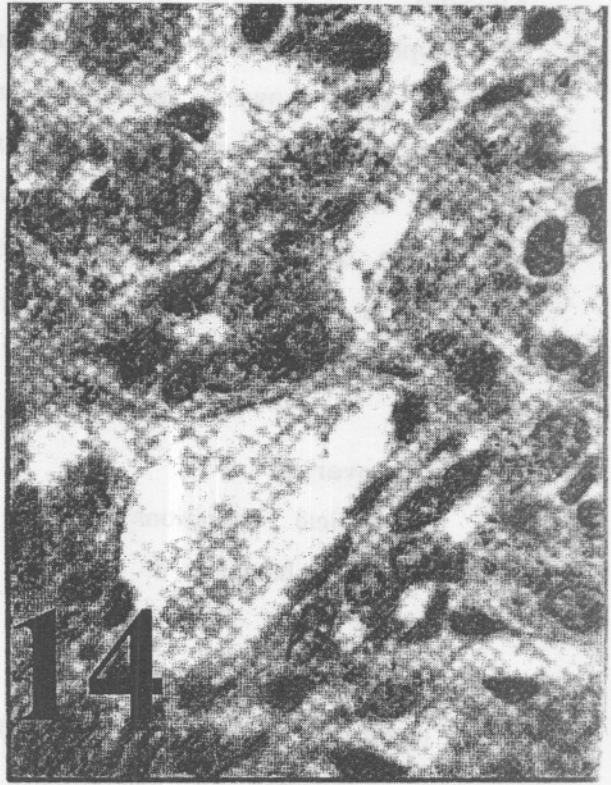








13



14

### **Uterus:**

The uterine tissue showed the presence of inflammatory exudate. The surface and glandular epithelium showed vacuolar degeneration and necrotic changes. Large numbers of mononuclear cells, mainly macrophages, lymphocytes and plasma cells were found in stratum compactum and granulosum of the endometrium. Periglandular cuffing and /or fibrosis were seen in some areas. Oedema of the endometrium was found in a few cases.

### **Placenta:**

The trophoblasts and intervening uterine epithelial cells showed degenerative and necrotic changes and disintegration. Presence of necrotic debris and fibrinous exudate in the placental matrix. Few mononuclear cells infiltrated the placental tissue.

### **Heart and ovaries:**

No pathological alterations related to brucellosis could be detected.

### **Immunohistochemical study:**

ABC technique revealed positive staining reaction manifested by the presence of finely granular yellowish brown deposits in areas invaded by the microorganism especially in the lymph nodes, lung, liver

and kidney. In the lymphoid tissue, brucellar antigen was localized both intracellular mainly within macrophages that appeared large, dense and filled with immunostain deposits. In the kidneys, the renal epithelium and the mononuclear cells in the typical granulomas were immunoreactive for brucella (Fig. 13). In the liver the microorganism was demonstrated within the kupffer cells, mononuclear cells, intrasinusoidal and also within hepatocytes (Fig. 14).

### **DISCUSSION**

Pathological examination of our cases revealed the presence of individual variations with respect to organ affected, extension and severity of lesions. The characteristic pathological changes in *Brucella melitensis* - infected cases were in the form of granulomatous reactions in the lymph nodes, liver, and lungs, in addition to lymphoplasmacytic mastitis in the udder.

Brucellosis is a widely distributed disease affecting animals and man. In cattle, lesions were commonly described to occur in the lymph nodes and spleen, uterus, and placenta in cows and in the testes, epididymis and seminal vesicles of bull (Jones and Hunt, 1998). Lesions in cattle



were also recorded in the skin (Nagalotimath et al., 1985), joints (Johnson et al., 1994, Bracewell and Corbel, 1980) and in the fetus (Lopez et al., 1984, Rhyan et al., 2001). In sheep, *B. ovis* infection characteristically involves the tail of epididymis; primary infection does not occur in the testicles (Jones and Hunt, 1998). *B. abortus* infection was occasionally reported in dogs; the lesions attributed to infection include arthritis, orchitis, epididymitis and abortion.

In horses, *B. bovis* has been isolated from necrotizing and purulent lesions involving the ligamentum nuchae (Jones and Hunt, 1998). In man, brucellosis is associated with lesions in the spleen (Carazo et al., 2005), liver (Carazo et al., 2005, Lorenz, 1978, Wildhirt, 1968), bone and joints (Fowler et al., 2004, Taliani et al., 2004, Audin et al., 2005), heart (Alhyar et al., 2005), brain and meninges (Koussa and Chemaly, 2003, Koussa et al., 2003), skin (Trunnell et al., 1985) and eye (Oppermann et al., 1971). In monkey, the liver, kidney, spleen, testes and epididymis showed lesions (Mense et al., 2004). However, wolves experimentally infected with brucella did not show lesions 50 days post-infection (Tessaro and Forbes, 2004).

Brucella infection was recorded in cattle, buffalo, sheep, goat (Ali, 1998), camel (Hegazy et al., 1998) and equines (Esmat, 1996). Brucellosis is considered a systemic disease affecting any organ or system and when a specific organ is involved, it is called focal or localized infection (Young, 2000).

In infected animals, different pathological patterns were recorded in the lymphoreticular tissues and parenchymatous organs including macrophage cell granuloma, epithelioid cell granuloma, giant cell granuloma and tuberculous - like granuloma (Ali 1998).

Progress of brucellosis and invasion of the blood stream will result in localization of the organism in tissues rich in reticulo-endothelial cells as lymph nodes and spleen, as well as udder. Abortion as a result of gravid uterus infection usually occurs during the third trimester of pregnancy without premonitory signs (El-Sergani et al., 1994).

In consistence with the results of Ali (1998), epithelioid cell granuloma and giant cell granuloma were predominating in the lymph nodes of brucella infected animals. Some of the epithelioid cells showed poor

phagocytic activity. Sinus catarrh, comprising lymphocytes, plasma cells and histiocytes, was frequently observed in most nodes, which were associated or not with epithelioid cells and /or giant cells. Lymphoid hyperplasia was found in some cases, some of which underwent depletion.

In the liver, the pathological changes were in the form of multifocal lymphocytic infiltration, which diffusely distributed all over the hepatic parenchyma. Epithelioid cells were intrasinusoidally present without necrosis in a few cases. Young et al. (1979) reported that poorly formed hepatic granuloma, composed of leucocytic infiltration with or without necrosis, was demonstrated in mice infected with *Brucella melitensis*. In contrast to *Brucella abortus* infected mice, well formed hepatic granuloma could be detected. They argued

that to the rapid elimination of *Brucella melitensis* from spleen and liver of infected animals than *Brucella abortus*. Also the persistence of acquired cellular immunity during *Brucella abortus* infection correlated closely with the ability of the organism to stimulate granuloma formation, as well, continued activation of macrophages by

sensitized T-lymphocytes. Generally, granulomas were more frequently found in infections with *Brucella abortus* compared to *Brucella melitensis* (Akhtar, 1989).

In this study and in consistent with the result of Meador et al. (1986 and Sozmen et al. (2004), the specific granular yellowish brown immunohistochemical staining was detected mainly in the macrophages cytoplasm in the different organs and lymphoid tissue and within the cytoplasm of the hepatocytes and renal epithelium.

In conclusion, different types of reactions against *Brucella melitensis*, like *B. abortus*, were found not only in the lymphoid tissue but also in other organs like the liver, kidney and lungs. Changes may depend upon the stage of infection as well as species differences. However, failure to detect lesions in the heart during the present study, and in one or other organ by other investigators may be related to that the lesions were overlooked due to their microscopical size and missing of getting samples grossly. We recommend the disposal of the liver, kidneys and lungs of brucella-positive slaughtered animals in addition to spleen, testicles, uterus, udder and mesentery

**Table (1) : Type and incidence of pathological changes in lymph nodes and spleen.**

Organs Pathological changes	Lymph nodes		spleen
	No of Ls	No. of cases	
Hyperplasia of lymphoid follicles	23	13	6
Sinus catarrh	30	15	-
Macrophage cell granuloma	21	17	1
Epithelioid cell granuloma	38	14	2
Giant cell granuloma	20	10	1
Tuberclous like granuloma	-	-	-

**Table (2) : The pathological changes in the liver and kidneys.**

Organs Pathological changes	Liver	Kidneys
Degenerative changes	16	12
Focal leucocytic infiltration	5	6
Epithelioid cell granuloma	2	2
Giant cell granuloma	2	2
Tuberculous like granuloma	-	2



**Table (3) : The pathological changes in lung , udder and heart.**

Lungs		Udder		Heart	
Pathological changes	No. of cases	Pathological changes	No. of cases	Pathological changes	No. of cases
Perbronchial pneumonia	3	Lymphoplasmacytic mastitis	2	Sarcocystes	10
Bronchitis & bronchiolitis	3	Subacute catarrhal mastitis	2	-	-
Pneumonia	1	Chronic interstitial mastitis	1	-	-
Oedema	3	-	-	-	-
Epithelioid & giant cell reaction	1	-	-	-	-
Tuberculous like granuloma	1	-	-	-	-

## List of figures

- Fig. 1:** Lymph node of a cow infected with brucella melitensis showing sinus catarrh (H&E- X 100)
- Fig. 2:** Lymph node of a cow infected with brucella melitensis showing epithelioid cell aggreagation (H&E- X 400).
- Fig. 3:** Lymph node of a cow infected with brucella melitensis showing giant cell granuloma (H&E- X 400).
- Fig. 4:** Liver of infected cow showing multifocal areas of mononuclear cell infiltrations (H&E- X200).
- Fig. 5 and 6:** Liver of infected cow showing epithelioid and giant cells (H&E- X200).
- Fig.7:** Kidney of infected cow showing large typical granuloma containing multiple areas of necrosis (H&E-X40).
- Fig. 8:** Kidney of infected cow showing granuloma with central caseation surrounded with cellular reaction (H&E-X40).
- Fig.9:** Kidney of infected cow showing cellular reaction comprising mononuclear cells, epithelioid and giant cells (H&E-X40).
- Fig.10:** Kidney of infected cow showing granuloma with central caseation and calcification encircled with mononuclear cells, epithelioid and giant cells (H&E-X40).
- Fig. 11:** Lung of infected cow showing peribronchial mononuclear cell infiltration and giant cell (upper right corner) (H&E- X200).
- Fig. 12:** Udder of a cow infected with brucella showing lymphoplasmacytic mastitis (H&E- X 200).
- Fig.13:** Kidney of infected cow showing positive immunohistochemical reaction within renal epithelium and macrophages. (Avidin – Biotin Complex , X1000)
- Fig.14:** Liver of infected cow showing positive immunohistochemical reaction within hepatocytes and intrasinusoidal mononuclear cells. (Avidin – Biotin Complex , X1000)

## REFERENCES

- Abdel-Hafeez, M.M.; Abdel Kader, A.H.; Bastawara, F.A.; El Ballat, S. and Hamedy, M.R. (1995): Bacteriological and pathological studies on *Br. melitensis* in dairy farm 3<sup>rd</sup>. Sci. Cong. Egypt. Soc. Assuit, Egypt.; 266 – 270
- Akhtar, M. (1989): Histopathological features in: Brucellosis by Madkour, M.M. Buterworts, London.
- Alhyari, A.R., Bakri,F.G., Al-Mousa,E.N., and Al-Samdy, M.M. (2005): Successful treatment of brucella endocarditis Saudi.Med.J., 26 (3): 473-5.
- Ali, Kh. A. (1998): Granulomatous inflammatory reactions in lymphoreticular tissue and parenchymatous organs. N.V.Sc. Thesis, Cairo University Beni Seuf.
- Audin, M., Fuat-Papir,A., Savas,L., Reyhan, M., Pour Baghar, A., Turunc, T.Y., Ziya - Demiroglu, Y., Yologlu ,N.A., and Aktas,A. (2005): Scintigraphic findings in osteoarticular brucellosis Nucl. Med. Commun., 26 (7): 639-47.
- Bancroft, J.D. and Stevens, A. (1996): Theory and Practice of Histological Technique. Churchill liveingstone, New York.
- Bracewell, C.D., and Corbel, M.J. (1980): An association between arthritis and persistent serological reactions to *Brucella abortus* in cattle from apparently brucellosis-free herds. Vet. Rec., 106 (5): 99-101.
- Carazo, R. C. ; Para, M.; Villares, J. ; Garcia, C. ;Calvente, M. ; and Bentitaz, M. (2005): Hepatosplenic brucelloma : Clinical presentation of imaging features in six cases. Abdom. Immag., 30(3) : 291-6.
- Doghiem, E.K.; El-Gibaly, S.; Nafady, A. Mousa, A.A. , Hamada, A.A. and Mountsr, M.A. (1995): Morpho;ogical and immunological studies on sheep and goats infected with brucellosis. 3<sup>rd</sup>. Sci. Cong. Egypt. Soc. Of Cattle dis., 3-5 Dec. 1995 , Assuit Egypt.
- El-Sergani, M.; El-Gibaly, S. And Afify, M (1994) : Pathological changes in bovine brucellosis. Egypt. J. Comp. Path. & Clinic. Pathol., 7(1): 1-14.
- Esmat, M. (1996): Some studies on brucellosis in horses. The scientific Congress, 17-19 Nov. 637-644 Assiut Univ. Egypt
- Fallini, B. ; Taylor, C.R. and DPhil, M. (1983): New developments in immunoperoxidase techniques and their application. Arch. Pathol. Lab. Med., 107:105-117
- Fowler, T.P., Keener, J., and Buckwalter,J.A., (2004): *Brucella* osteomyelitis of the proximal tibia: A case report Iowa Orthop. J., 24: 30-2.
- Hegazy, A.A.; El-Shazly, M.; Wahbah, M.A. and Amer, H.A. (1998) Pathological and serological studies on brucellosis in she camel. Egypt. J. Comp. Path. & Clinic. Pathol., 11(2): 23-32.
- Johnson, B., Mosier, D.A, Morton, R.J., and Confer, A.W. (1994): Experimental *Brucella abortus* strain 19 arthritis in young cattle. J. Vet. Diagn. Invest., 6 (1): 56-61.
- Jones,T.C. and Hunt,R.D. (1998): Veterinary Pathology 6<sup>th</sup>. Ed. Williams & Wilkins A Waverly Company
- Koussa, S and Chemaly, R. (2003): Neurobrucellosis presenting with diffuse cerebral white matter lesions. Eur. Neurol., 50(2) : 121 -3.
- Koussa, S.; Tohme, A. and Ghayad E. (2003) :Neurobrucellosis and therapeutic responses in 15 patients. Rev. Neurol., 159(12):1148-55 (abstract).



- Lopez, A., Hitos, F., Perez, A., and Navarro-Fierro, R.R. (1984): Lung lesions in bovine fetuses aborted by *Brucella abortus*. *Can. J. Comp. Med.*, 48 (3): 275-7.
- Lorenz, G. (1978): Bioptic liver changes in brucellosis. *J. Zbl. Allg. Pathol.*, V 122 (3): 256-62,
- Meador, V.; Tabatabai, L.B. ; Hagemoser, W.A. and Deyoe, B.L. (1986): Identification of *Brucella abortus* in formalin - fixed embedded tissue of cows, goat, and mice with Avidin-Biotin peroxidase complex immunoenzymatic staining technique. *Am. J. Vet. Res.*, 47: 2147-2150.
- Mense, M.G.; Borechel, R.; Wilhelmsen, C.L. ;Pitt, M.L. and Hoover, D.L. (2004): Pathologic changes associated with brucellosis experimentally induced by aerosol exposure in rhesus macaques (*Macaca mulatta*). *Am. J. Vet. Res.*, 65(5):644-52
- Nagalotimath, S.J., Hemashettar, B.M., and Patil, C.S. (1985): Subcutaneous nodules in brucellosis. *Indian. J. Pathol. Microbiol.*, 28 (3): 225-8.
- Oppermann, A., Royer, J., Joubert, L., Pageaut, G., and Carbillet, J.P. (1971): Ocular brucellosis (a proposal of a case) *Ann. Anat. Pathol. (Paris)*, B, 16(4): 499-502
- Perez, J.; Quezada, M.; Lopez, J. Casquet, O. ; Sierra, M. and De Las Mulas, J.M. (1998): Immunohistochemical detection of *Brucella abortus* antigens in tissue from aborted bovine fetuses using a commercially available polyclonal antibody. *J. Vet. Diagn. Invest.*, 10: 17-21.
- Rhyan, J.C, Gidlewski, T, Roffe, T.J., Aune, K., Philo, L.M., and Ewalt, D.R. (2001): Pathology of brucellosis in bison from Yellowstone National Park. *J Wildl Dis.*, 37 (1): 101-9.
- Sozmen, M.; Erginosy, S.; Genc, O. ; Beytut, E. and Ozcan, K. (2004): Immunohistochemical and microbiological detection of *Brucella abortus* in aborted bovine fetuses. *Acta Vet. Brno*, 73:465-472.
- Taliani, G., Bartoloni, A., Tozzi, A., Bartalesi, F., Corti, G. and Paradisi, F. (2004) : Lumbar pain in married couple who likes cheese: brucella strikes again. *Clin. Experiment. Rheumatol.*, 22 (4): 477-80.
- Tessaro, S.V. and Forbes, L.B. (2004): Experimental brucella abortus infection in wolves. *J. Wildl. Dis.*, 40 (1): 60-5.
- Trunnell, T.N, Waisman, M., and Trunnell, T.L. (1985): Contact dermatitis caused by *Brucella*. *J. Cutis.*, 35 (4): 379-81.
- Wildhirt, E. (1968): Granulomatous hepatitis. *Introduction Wien. Z. Inn. Med.*, 49 (4): 139-40.
- Yazicioglu, O. (1997): Pathological and immunoperoxidase studies of the fetal lesions of ovine brucellosis. (Abstract) *Ankara Univ. Vet. Fak. Derg.*, 44: 291 - 307.
- Young, E.J. (2000): *Brucella* species in: Mandell GJ, Bennet, JE, and Dolin, R. principle and practice of infectious disease. Churchill Livingstone New York.
- Young, E.J.; Gomez, C.; Yawn, D. and Musher, D. (1979) : Comparison of *brucella abortus* and *brucella melitensis* infections of mice and their effect on acquired cellular resistance. *Infect. Immun.*, 26(2): 680-685.

# دراسات باثولوجية ومناعية هيستوباثولوجية على مرض البروسيلة ميليتنسز

## في الأبقار

خالد على احمد على النسر ، عماد احمد مهدى ، عادل شلبي ، صلاح ديب

قسم الباثولوجى - كلية الطب البيطرى جامعة بنى سويف

أجريت هذه الدراسة على 48 بقرة (37 حيوان من المحطة الاختبارية بكلية الطب البيطرى- جامعة بنى سويف و 11 حيوان من مزرعة خاصة باهناسيا بمحافظة بنى سويف) جميعها كانت إيجابية للبروسيلة باستخدام الاختبارات السيرولوجية. كشفت الدراسة الباثولوجية عن وجود اختلافات فردية فيما يتعلق بالأعضاء وأيضا شدة الإصابة وامتدادها. وقد وجدت أورام حبيبية فى الأنسجة الليمفاوية وأيضا فى الكبد والكلى والرتتين والضرع. كانت حبيبات الخلايا الشبيهة بالخلايا الطلانية وأيضا الخلايا العملاقة سائدة فى العقد الليمفاوية والكبد ، بينما وجدت الحبيبات الشبيه بدرنات السل فى الكلى والرتتين. تم الكشف عن الميكروب فى الأعضاء والعقد الليمفاوية باستخدام تفاعل الصبغة المناعية.