

EFFECTS OF CHITOSAN ON EXPERIMENTAL FROG WOUND HEALING IN DONKEYS (*EQUUS ASINUS*) AND ASSOCIATED CHANGES OF HEMATOLOGICAL AND HISTOLOGICAL PROFILES

***ABOU-EL-ELLA, A.G.; **FATHHLLA, S. I.; **ABEDEL-RAHMAN, H. A. and ***MINAMI, S.**

*Dept. Surgery Faculty Vet. Med., (El-Sadat branch), Menofia Univ., Egypt

**Dept. Physiol., Faculty Vet. Med., (El-Sadat branch), Menofia Univ., Egypt

***Dept. Surgery Faculty of Agriculture, Tottori University, Japan

Received: 12.3.2007.

Accepted: 16.3.2007.

SUMMARY

The clinical, radiographic, and histological effect of chitosan on the healing process of experimentally induced central frog deep wounds as well as the accompanied hematological changes were studied in 6 female adult donkeys. All operated lesions healed satisfactory without any clinical or radiographic signs of infection. The grade of lameness was greatly improved and the regenerated soft tissues filled the frog wound within one week after chitosan treatment. Thin covering layer of horny tissues formed two weeks later while the whole wound closed within eight weeks after chitosan treatment. The hematological profile revealed that the coagulation parameters after local chitosan application greatly enhanced hemostasis through striking increase of platelets count which were reflected on the marked reduction

of PT and APPT in all tested donkeys post-operatively in comparison with pre-operative standards. Generally, no considerable differences were recorded between pre-operative and days post-operative (PO) up to 14 days for the values of hemogram (Hb, RBCs, PCV and blood indices), fibrinogen, total protein and glucose. The obtained levels of ALT and AST at 3 days PO showed a significant elevation and returned to the preoperative levels after 7 days PO. Histological examination proved the efficacy of the regenerative power of chitosan as both the epidermal and dermal layers showed newly formed capillaries with acanthosis and polyp formation in the prickle cell layer of the epidermis and connective tissue core formation in the dermis. From this study, it can conclude that chitosan is an excellent dry dressing

material for treatment of open hoof wounds as it stops bleeding, prevents wetting, alleviates the intensity of pain, reduces the risk of contamination and enhances both the regeneration and cornification of the hoof.

Keywords: Chitosan, Hoof, Coagulation, hemogram, Biochemistry, Histology, Donkes

INTRODUCTION

Chitin is a polymer of N-acetyl-D-glucosamine and D-glucosamine are biosynthesized in nature forming the extraskelton of crustaceans and insects as well as components of fungal cell wall (Okamoto, et al., 1992 ; Illum, 1998). Chitosan “chemically modified chitins” is a polysaccharide comprising copolymers of glucosamine and N-actylglucosamine. It is derived by partial deacetylation of chitin from crustacean shells (Okamoto, et al., 1995). Chitosan enhances the functions of inflammatory cells such as polymorphonuclear leukocytes, macrophages and fibroblasts; thus, it promotes granulation and organization (Ishihara, et al., 2001; Uneo, et al., 2001; Okamoto, et al., 2002). It was found that chitosan have potent immunological activities through complement activation that will induce host defenses against various surgical and/or anesthetic stresses (Nishimura

the intensity of pain, reduces the risk of contamination and enhances both the , et al., 1984 and 1987; Iida, et al., 1987; Minami, et al., 1997; Suzuki, et al., 2003). Chitosan epidermal growth factor gel formulation decreased the wound healing period, accelerated epidermal regeneration and stimulated granulation tissue formation (Alemdarglu, et al., 2006).

Wounds of the hoof generally heal slowly due to the high incidence of contamination, difficulty in contraction of the hoof wounds and inelasticity of the epithelial tissues. The difficulty of contraction of the hoof wounds was attributed to that all soft tissues of the foot are attached to bone or rigid connective tissues (Richardson and Pascoe 1986; White and Moore 1990). The frog is the most important shock absorbing structure of the hoof. Its W-shaped cross-section and its elastic horn allow the frog to yield the pressure forces when contacting the ground and so dissipates much of the resulting impact. The digital cushion deep to the frog complements this shock absorbing function (White and Moorem, 1990; Konig and Liebich, 2004).

Although the efficacy of chitosan for treatment of wounds in small animals has been approved for more than 15 years (Okamoto, et al., 1992 and 1995; Illum, 1998), the role of chitosan in the treatment of hoof wounds is not studied up till now.

This urged us to evaluate the chitosan efficacy on the healing process of experimentally induced frog wounds in donkeys. In addition,

MATERIALS AND METHODS

Materials: Chitosan was supplied by Sunfive Co., Ltd. (Tottori, Japan).

Animals:

Six apparently healthy female donkeys (*Equus asinus*) were used in this study. The mean of body weight was 200.0 ± 20.0 Kg ($x \pm$ SEM) and the age average was 5.0 ± 0.8 yr ($x \pm$ SEM). The animals were selected from a population of donkeys that maintained at the faculty of veterinary medicine, Menofia University for student training and research. All donkeys were free from of known respiratory or digestive disorders. They were housed in 5 x 5 m acclimatized box stalls during the experimental period. These donkeys did not show lameness or visible abnormalities in their hoofs at the side selected for the experiment. The donkeys were sprayed with external insecticide, dewormed and vaccinated against tetanus one week before experimental period. The donkeys were fed twice daily with barley, corn and hay based diet, supplemented with bran, ground limestone and general mineral/vitamin supplement. Water was available *ad libitum* at all time.

coagulation, hemogram, biochemical and histological profiles were also studied before and after chitosan treatment.

2.3. Experimental design

One day before experiment, blood samples were obtained to estimate the hematological parameters before experimental wound operations. Animals were fasted 12h before the experiment. For each animal, 18-gauge canulae was inserted in the jugular vein under local anesthesia.

The operated animals were sedated by intravenous injection of 2% xylazine hydrochloride (Xyla-Ject; ADWIA, Egypt) in a dose of 1 mg/kg body weight (Bwt). Then they were narcotized in the recumbent position by intravenous infusion of 10% Chloral hydrate (BDH Laboratory supplies, England) in a dose of 5g / 50 kg Bwt. In three animals the right fore hoofs were used for the experiment while the right hind ones were used in the rest of animals. All operations were performed under the effect of bilateral palmer/planter nerve blocks using 2% lidocaine hydrochloride (El-Debiky Pharma, Egypt). Each hoof received one, square, full thickness wound of the frog (1×1 cm²) at the central zone of the frog. The depth of the wounds was reached to the level of the navicular bone.

All operated hoofs were treated once with one gram of chitosan and the wounded areas were covered with non-adherent occlusive cotton pad. Hoof bandages were applied and the wounds were inspected at three and seven days post-operatively for judgment of the healing process. Then the hoof bandages were changed weekly for three successive weeks after disinfection of the operated areas with povidine iodine (Betadine -the Nile Co, Egypt). Hoof plates were applied to all operated animals at four weeks post-operatively and left in position until the end of the experiment (two months post-operatively).

The grade of lameness was measured 24 hours post-operatively, and prior to each dressing and given the following locomotion score; 1: normal, 2: slight lameness without noticeable hip hitching or head nodding, 3: lameness with noticeable hip hitching or head nodding, 4: bearing weight at the toe and 5: no weight bearing.

Radiographic examination of the operated hoofs were performed soon after surgery, four and eight weeks post-operatively.

Blood sampling

Venous blood were sampled by jugular vein puncture 24h pre-operative and 3, 7 and 14 days post-operative (OP) and chitosan treatment. Four vacuum collecting tubes were used, one silicone-coated (for serum), one containing sodium fluoride (for glucose), and 1

EDTA coated [for hemogram (red blood corpuscles = RBCs, and platelet count, hemoglobin= Hb and packed cell volume=PCV)] and one containing sodium citrate [0.11M-for coagulation assays (prothrombin time=PT, activated partial prothrombin time=APPT and fibrinogen level)]. Also, determination of fibrinogen levels is very important diagnostic tool as an unspecific inflammatory marker (Hulten, et al., 2002; Jacobsen, et al., 2005). The tube of sodium citrate vacutainer was not over- or under-filled in order to ensure the correct anticoagulant-to-blood ratio: 1 part anticoagulant per 9 parts blood.

Hemogram and coagulation assays were carried out within one hour of collection. The other tubes were centrifuged immediately after collection at 900 g for 15 min. The obtained plasma (except citrated one) and serum were stored at -20°C pending other blood parameters assays.

Blood analysis

The levels of PT and APPT and fibrinogen, aspartat aminotransferase (AST), alanine aminotransferase (ALT), total protein, glucose and hemoglobin were determined spectrophotometrically using commercial kit according to the instructions of the manufacture (Bio-Merieux Laborator Reagents and Products, France). Hematocrit was determined using micro-hematocrit

method. Blood platelets and RBCs were counted manually by using hemocytometer method. Mean corpuscular hemoglobin (MCH), mean corpuscular volume (MCV) and mean corpuscular hemoglobin concentration (MCHC) were calculated according to Coles (1986).

Histological studies

After the experimental period, operated donkeys were euthanatized by using 10% chloral hydrate in a dose of 17g / 50 kg Bwt (Milks, 2002) to obtain autopsy specimens from the healed operated areas. The specimens were fixed in 10% formol saline solution for ten hours at least then washed in tap water for 12 hours. Serial alcohol (methyl, ethyl and

RESULTS

Clinical findings

No adverse reactions were recorded in donkeys after experimental frog wounds or chitosan treatment throughout the experimental period (2months). Bleeding was obviously seen during surgery (Fig.1a) and stopped spontaneously soon after topical application of chitosan (Fig.1b). Three days post operatively chitosan was seen forming a thick compact layer that completely sealed the frog wound (Fig. 1 c) and after removal of the superficial layer of the chitosan seal a blood impregnated area of chitosan was appeared (Fig.1d). The frog wound

absolute) were used for dehydration of the tissue samples. Tissue specimens were cleared in xylene and embedded in paraffin. The paraffin blocks were sectioned at 3-micron thickness by slide microtome. The obtained tissue sections were collected on the glass slides for histological examination by the light microscope after staining by hematoxylin and eosin stain (Banchroft, et al., 1996).

Statistical analysis

The recorded values were expressed as means \pm S.E.M. The significance of differences between the pre-operative and post-operative and chitosan treatment were tested by Duncan's test using the 7.5 version of the SPSS (1996) statistics programmed package running on Windows.

was completely filled with granulation tissue one week post-operatively in all operated animals (Fig. 2a). Focal areas of cornification started to invade the granulating tissues at one week post-operatively, became numerous and thicker at the peripheral area of the operation wound two weeks later (Fig. 2b) and formed a thin layer covering the whole wound at three weeks post-operatively (Fig. 2c). The thickness of the newly formed horny material progressed until the whole wound of the frog was filled at two months pos-operatively (Fig. 2d).

The grade of lameness (Table1) was five in all animals 24 hours post-operatively, and it had

noticeably improved (grade three and two) during the following three weeks. Two weeks after application of a hoof-plate and until the time of euthanasia, all operated animals' walked normally. The radiographic examination of the operated animals soon after surgery confirmed the depth of the lesion as it was reached to the level of the navicular bone (Fig. 5). The progress of the healing process was evaluated radiographically four weeks later and the operated area retained its normal soft tissue radiographic density while a noticeable horny tissue wound was observed (Fig. 6). The frog defects were completely filled with horny materials eight weeks post-operatively and non of the operated areas showed any signs of bone infection along the whole time of the experiment (Fig. 7).

Hematological findings

As shown in tables one and two, generally no significant differences ($P>0.05$) for the values of hemogram and glucose were recorded between pre-operative and days post-operative up to 14 PO. The obtained levels of ALT and AST at 3 days PO showed a significant elevation ($P<0.05$) relative to pre-operative, 7PO and 14PO values (Table 1).

Coagulation profile in donkeys of the present study, revealed that the local application of chitosan have a pronounced effects on enhancement of hemostatic parameters which were reflected on the striking increase ($P<0.05$) of platelets count at 3, 7 and 14 PO

(count = 417, 497 and 652, respectively) in comparison with pre-operative standards (count =317- table1). This result was reflected on the picture of PT, APPT and fibrinogen levels. The obtained levels of PT at 3 days PO were reported a significant decline ($P<0.05$) relative to pre-treatment, 7PO and 14PO ones (Table1). At the same time, the APPT scores of the post-operative days up to 14 days were recorded a marked drop ($P<0.05$) comparative to pre-operative one (Table1). No considerable differences ($P>0.05$) were recorded between pre-operative and days post-operative up to 14 PO for the values of fibrinogen and total protein concentrations (Table 1).

Gross anatomic and Histological findings

The gross anatomic picture showed an area of firm newly formed tissues extending from the base of the navicular bone to the center of the frog (Fig. 6a). Histological examination revealed that the digital cushion area showed an intact avascular-fibroelastic network formation (Fig. 6b). The stratum germinativum layer of the corium of the frog was intact while the adjacent epidermal and dermal layers showed newly formed capillaries with acanthosis and polyps formation in the prickle cell layer of the epidermis and connective tissue core formation in the dermis (Fig. 6c&d).

Table 1: The grade of lameness for the operated donkeys after topical chitosan treatment.

Time of PO examination	Grade of lameness				
	One	Two	Three	Four	Five
24 hours					6
3 days			2		4
1 week			5		1
2 weeks		4	2		
4 weeks		5	1		
6 weeks	6				
8 weeks	6				

Numbers = Number of lame donkeys; PO = Post-Operative

Table 2: Coagulation and biochemical profiles in chitosan treated donkeys.

	Pre-operative	3PO	7PO	14PO
PT	13.59	12.29	13.56	13.60
	±	±	±	±
(seconds)	0.01 ^a	0.32 ^b	0.17 ^a	0.17 ^a
APPT	61.58	57.14	57.71	58.73
	±	±	±	±
(seconds)	1.47 ^a	1.13 ^b	0.44 ^b	0.54 ^{ab}
Platelets Count				
	316.67	416.67	496.67	651.67
	±	±	±	±
(10³/mm³)	26.29 ^c	46.38 ^{bc}	50.77 ^b	23.44 ^a
Fibrinogen	555.00	536.17	447.50	595.00
	±	±	±	±
(mg/dl)	78.73 ^a	83.85 ^a	65.62 ^a	94.37 ^a
Total protein	6.04	5.66	5.49	5.88
	±	±	±	±
(g/dl)	0.11 ^a	0.14 ^a	0.26 ^a	0.22 ^a
ALT	6.27	7.77	6.50	5.72
	±	±	±	±
(U/L)	0.16 ^b	0.65 ^a	0.18 ^{ab}	0.59 ^b
AST	7.75	21.00	8.45	7.75
	±	±	±	±
(U/L)	0.47 ^b	1.06 ^a	0.55 ^b	0.30 ^b
Glucose	111.17	100.00	110.67	98.50
	±	±	±	±
(mg/dl)	7.40 ^a	3.67 ^a	6.77 ^a	2.85 ^a

Mean ± SE (n=6)

Means having different superscripts are significantly different at $P < 0.05$.

PO = Post-Operative

PT = Prothrombin Time,

APPT = Activated Partial Prothrombin Time.

Table 3: Effects of chitosan on the hemogram of treated donkeys.

	Pre-operative	3PO	7PO	14PO
Hb (g/dl)	13.20 ± 0.86 ^a	12.82 ± 0.27 ^a	12.52 ± 0.93 ^a	12.74 ± 0.61 ^a
PCV (%)	29.77 ± 0.30 ^a	28.77 ± 0.54 ^a	29.27 ± 1.08 ^a	29.50 ± 1.28 ^a
RBC_s (10⁶ x mm³)	5.90 ± 1.47 ^a	5.50 ± 1.13 ^a	6.41 ± 0.44 ^a	6.19 ± 0.54 ^a
MCH (pg)	22.81 ± 2.16 ^a	24.14 ± 2.47 ^a	19.69 ± 1.58 ^a	20.97 ± 1.58 ^a
MCV (fl)	51.06 ± 2.16 ^a	53.51 ± 3.51 ^a	45.95 ± 2.11 ^a	48.41 ± 3.26 ^a
MCHC (%)	44.41 ± 3.09 ^a	44.70 ± 1.57 ^a	42.54 ± 1.56 ^a	43.16 ± 0.66 ^a

Mean ± SE (n=6),

PO= Post-Operative

Means having different superscripts are significantly different at $P < 0.05$.

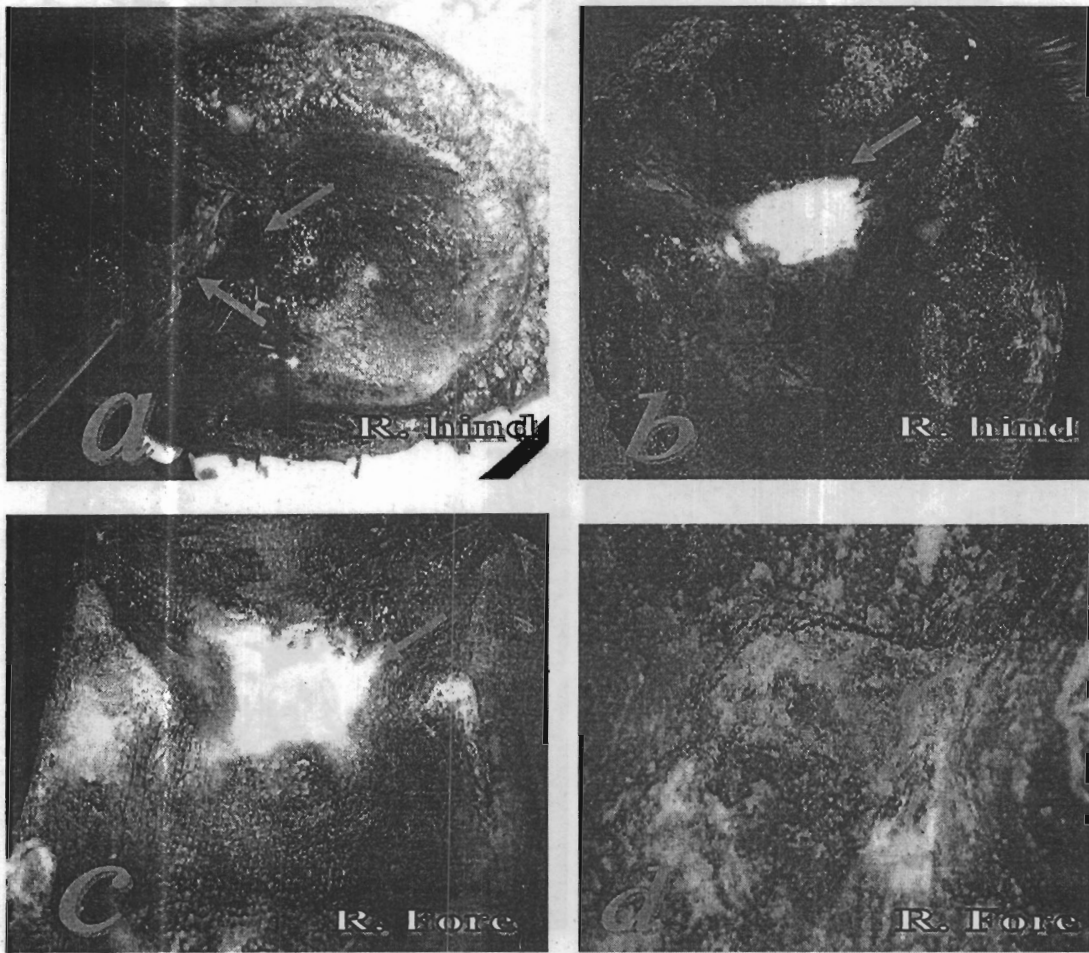


Fig 1: Central area of the frog; (a) one square cm full thickness wound of the frog including the deeper soft tissues and accompanied with hemorrhage (arrows). (b) Hemorrhage is arrested after topical application of chitosan powder (arrow). (c) and (d) Three days post operatively; notice that chitosan forms a thick compact layer over the frog defect (c) and the blood impregnates the chitosan seal (d) after removal of it is superficial layer (arrows).

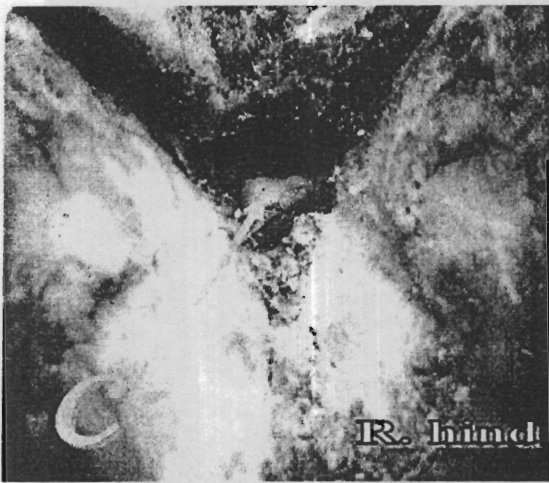
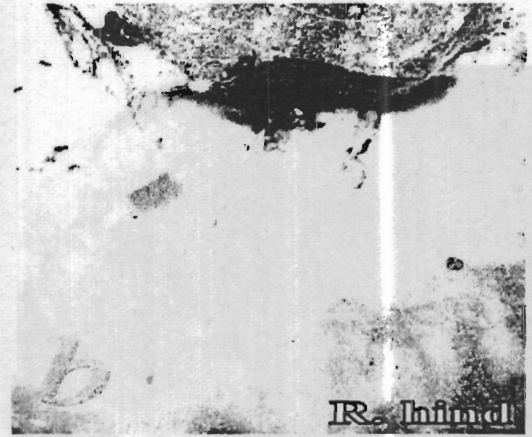
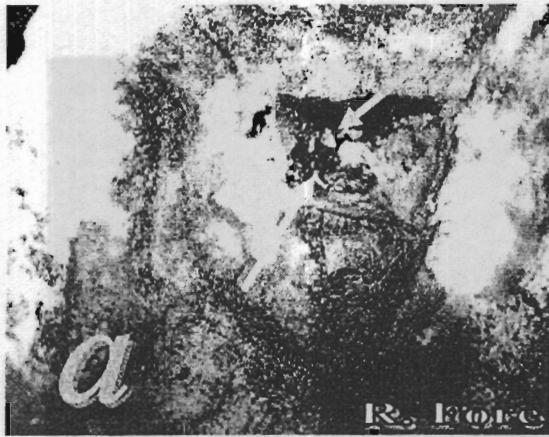

Fig 2: The healing process: (a) one week and (b) two weeks post-operatively: the frog defect is completely filled with granulation tissue (long arrows). Notice areas of cornification invade the granulating tissues that become thicker at the peripheral area of the frog defect (short arrows). (c) two months post-operatively the thickness of the newly formed horny material nearly fills the frog defect (arrow). (d) three weeks post-operatively the cornification forms a thin layer covering the whole defect (arrow). (d) The thickness of the newly formed horny material nearly fills the frog defect after two months post-operatively (arrow).

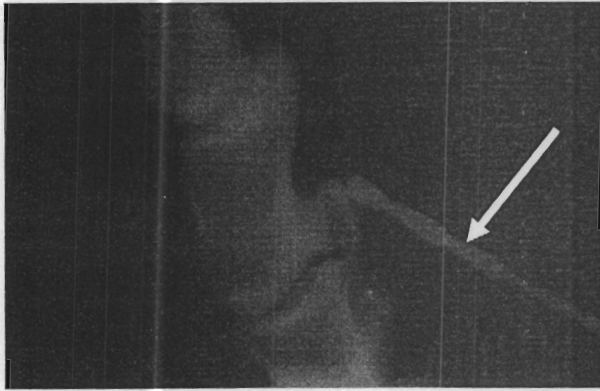


Fig 3: Lateromedial (LM) view of the right-hind foot soon after surgery, the drill pin penetrating the center of the frog and reaches to the level of the navicular bone (arrow).

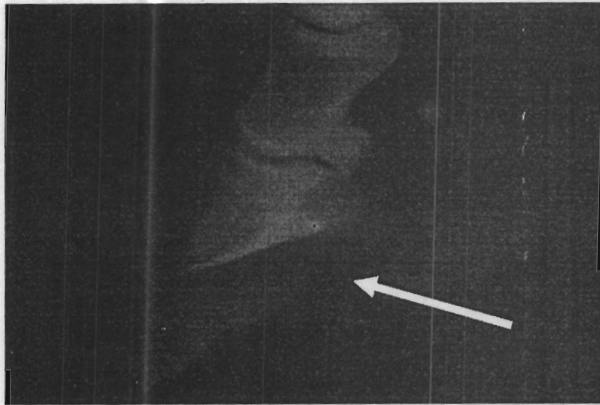


Fig 4: LM view of the right-fore foot 4 weeks post-operatively shows normal bone and soft tissue radiographic density with a noticeable defect of the horny tissues of the frog (arrow).



Fig 5: LM view of the right-fore foot 8 weeks post-operatively shows normal bone and soft tissue radiographic density with filling of the frog area with horny tissues (arrow).

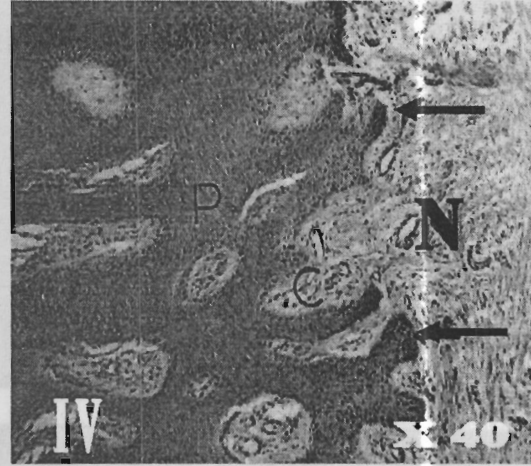
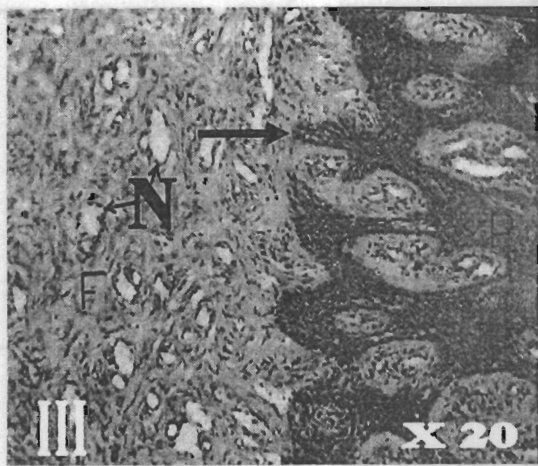
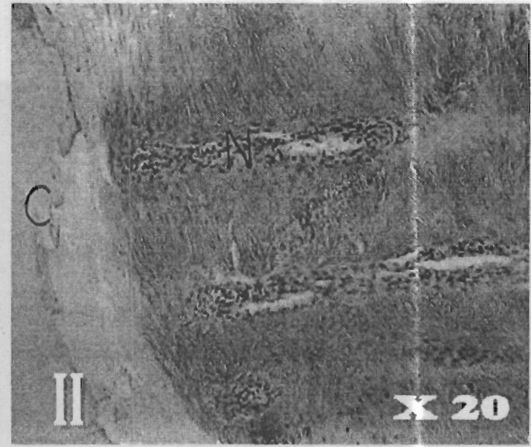
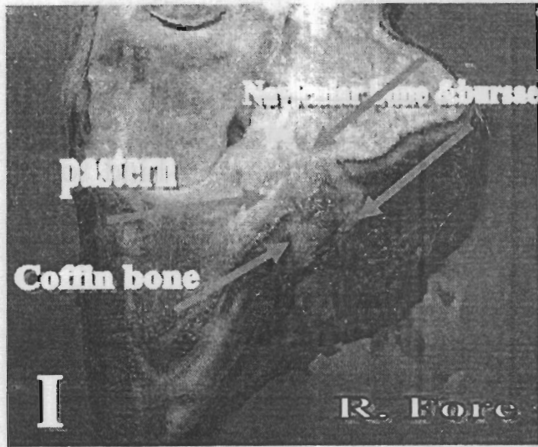


Fig. 6: Gross and histological pictures {H&E} 8 weeks after chitosan treatment. I- A longitudinal section of the hoof showing the area of regeneration extends from the level of the navicular bone to the center of the frog (arrows). II- Intact structurless fibroelastic {C} "digita cushion" area with newly formed capillaries {N} in the adjacent epidermal area "corium of the frog". III & IV - Acanthosis of the prickly cell layer {P} of the epidermis "horny Frog" with polyyps' formation {arrows} and connective tissue core formation {C} and newly formed capillaries {N} in the epidermis.

DISCUSSION

A variety of wound medications have been used and investigated in the treatment of hoof wounds. Many of these medications may allow normal wound healing but none actually stimulate or accelerate healing.

The central area of the frog was selected for the experiment in order to study the effect of chitosan on the healing process of the most serious soft tissue structures within the hoof. Wounds in the area of the central frog and sulci are especially critical because of the consequences associated with deeper infection of other vital structures (White and Moore, 1990; Honnas, et al., 1998; Mair, et al., 1998).

The frog is a predisposed location for foreign bodies penetration, which may reach underlying vital structures such as navicular bursa. Early recognition and effective treatment are of paramount importance for a satisfactory outcome (Richardson, et al., 1986; Honnas, 1999; Konig and Liebich, 2004).

Wound healing is a complex process involving various mechanisms, such as coagulation, inflammation, matrix synthesis and deposition, angiogenesis, fibroplasias, epithelization, contraction and remodeling (Clark and Denver,

1985; Uno, et al., 1999). Hemorrhage from the experimentally operated frogs was spontaneously arrested after topical application of chitosan. Moreover, it adhered firmly forming a waterproof barrier separating the wound from the environment. This may be attributed to the film forming, the gelatinous character and the haemostatic activity of chitosan (Howling, et al., 2001; Ishihara, et al., 2001 and 2002). The advantage of topical application of chitosan includes good flow properties, non-irritancy, some antibacterial effect and a potential for a suitable release rate from the dosage form (Bartone and Adickes, 1988).

The coagulation profile parameters revealed that chitosan greatly enhanced hemostasis through striking increase of platelets count which were reflected on the marked reduction of PT and APPT in all tested donkeys post-operatively in comparison with pre-operative standards. There are many reports of in-vivo experiments confirm the same result but in different animals species as Malette, *et al.*(1983); Klokkevold, *et al.* (1992) and Klokkevold, *et al.* (1999). Furthermore, in-vitro studies Okamoto, *et al.* (2003) proved that chitosan augments strongly platelet aggregation which was revealed clearly on blood coagulation time decrease.

The current study illustrates a non-significant difference between pre-operative and days post-operative up to 14 PO for the values of hemogram, glucose, fibrinogen and total proteins. These results are parallel to those reported by Minami, et al. (1997) in dog for the hemogram and total protein. This may be attributed to that chitosan enhances the release of cytokines (PDGF-AB and TGF- β 1) from platelets which play an important role on the wound healing process and inhibits the stress effects of the acute traumatic conditions (Okamoto, et al., 2003). Furthermore, chitosan have potent immunological activities through complement activation that will induce host defenses against various surgical and/or anesthetic stresses (Iida, et al., 1987; Minami, et al., 1997; Suzuki, et al., 2003). Consequently, the hematological changes associated with the acutely traumatized animal become negligible. On the other hand, Mela, et al. (1975) and Brasmer (1984) observed a significant change in packed cell volume (PCV) and glucose level in the acutely traumatized animal. The PCV is an interesting and important piece of baseline data as we begin to examine the traumatized animal. As trans-capillary refill produces hemodilution, the PCV will fall markedly, but hemodilution is slow (Brasmer, 1984). Glucose has an important prognostic value in the acutely traumatized animal (Mela, et al., 1975). The elevation of blood glucose after trauma is so consistent and is considered a common part of

the trauma response. This seeming paradox is the result of a number of factors, all of which tend to elevate blood glucose. The catecholamine response to trauma or stress increases hepatic glycogenolysis. Even while hepatic glycogenolysis is occurring, epinephrine, augmented by glucocorticoids, stimulates hepatic gluconeogenesis from three-carbon fragments. The three-carbon fragments are shuttled from muscle to the liver for conversion to new glucose. Glucagon levels are characteristically high following trauma, and this provides an additional signal to the liver for increased glucose production (Guyton and Hall, 2006).

Despite recent advances in surgical techniques and intensive care management, infectious complications and sepsis remain significant problem after surgery. Therefore, inflammatory markers (C-reactive protein, fibrinogen, serum amyloid A, haptoglobin,.....) were looked for that could help achieve an early and more reliable diagnosis of postoperative infections (Hulten, et al., 2002; Jacobsen, et al., 2005; Oberhofer, et al., 2006). Plasma fibrinogen is an unspecific positive marker of inflammation and used widely in veterinary medicine as an inflammatory marker: in horses, a level above the normal range suggests some degree of systemic inflammatory response (Hulten, et al., 2002). It is also lowered in disseminated

intravascular coagulation (Tamzali, et al., 2001).

The previous conclusions are in contrast to the present study of the fibrinogen concentrations. No substantial differences were recorded between pre-operative and days post-operative up to 14 PO for the values of fibrinogen concentrations as an inflammatory marker. This may be ascribed to chitosan effectiveness in controlling post-operative inflammation in all donkeys of the current study.

Healing of hoof wounds is quite a complicated process involving regeneration of connective tissue and migration of all portion of the corium to cover a healthy bed of granulation. This process will be slow and may take three to five months (White and Moore, 1990). Foot soaking with saturated solution of magnesium sulfate is not appropriate until granulation tissue has covered the regions susceptible to re-infection (Steckel and Fessler, 1983). To obtain a proper healing process a dry dressing is recommended specially for deep hoof wounds (Richardson and Pascoe, 1986). In the present work after topical application of chitosan powder as a dry dressing, the wounded area of the frog was completely filled with a healthy granulation tissue within one week. A thin layer of cornified tissues nearly covered the wound after three weeks

and the whole wound healed within two months from the experiment.

The histological results of the obtained specimens eight weeks post-operatively

revealed signs of regeneration as the presence of an intact structureless- fibroelastic mass at the digital cushion area and polyp's formation in the prickle cell layer of the epidermis and connective tissue core formations in the dermis. White and Moore (1990) emphasized that the digital cushion is relatively avascular- fibroelastic network containing masses of fat and islands of cartilage. Moreover, they insisted that the sensitive layers of the hoof "stratum geminativum and corium" must heal by granulation and epithelization rather than cornification. Chitosan is biodegradable polymers accelerates wound healing, permits regeneration of tissue elements and have a positive effect on wound healing (Conti, et al., 2000).

Although we did not use any anti-inflammatory drugs or antibiotics with the chitosan treatment; the grade of lameness in all operated animals were greatly improved one week post-operatively. Moreover, the radiographic examination did not reveal any signs of bone infection along the whole time of the study. Chitosan is biologically

activating the alternative pathway for complement activation 5 (C5a). The C5a is produced by this activation promotes PMN migration to the wound without any inflammatory signs, such as erythema, temperature elevation, or the formation of abscess (Minami, *et al.*, 1989).

The transaminases (AST and ALT) are widely distributed in the body, especially AST, and moderately elevated after extensive trauma and muscle diseases (Marshall, 2000). This fact is clearly recorded at 3 days PO of the present study. But due to efficacy of chitosan in wound healing, both AST and ALT levels go back to the pre-operative levels after 7 days

of operation and chitosan treatment. The returning of the transaminases levels to their pre-operative level seven days post-operatively might attribute to the efficacy of chitosan in acceleration of wound healing. Hence, Chitosan is not only pro-inflammatory agent, but also have an anti-inflammatory effect (Minami *et al.*, 1989).

CONCLUSION

Chitosan could be considered as an excellent dry dressing material for treatment of open hoof wounds as it stops bleeding, prevents wetting, alleviates the intensity of pain, reduces the risk of contamination and enhances both the regeneration and cornification of the hoof matrix.

REFERENCES

- Alemaroglu, C.; Degim, Z.; Celebi, N.; Zor, F.; Ozturk, S. and Erdogan, D. (2006): An investigation on burn wound healing in rats with chitosan gel formulation containing epidermal growth factor. *Burns*, 32: 319-327.
- Banchroft, J. D.; Stevens, A. and Turner, D. R. (1996): *Theory and Practice of Histological Techniques*. 4thEd., Churchill Livingstone, New York, London, San Francisco, Tokyo.
- Bartone, F. F. and Adickes, E. (1988): Chitosan: effects on wound healing in urogenital tissues: preliminary report. *J Urol.*, 140: 1134-1137.
- Brasmer, T. H. (1984): *The acutely traumatized small animal patient*. Saunders W.B. London, Tokyo, Toronto.
- Clark, R. A. F. and Denver, M. D. (1985): Cutaneous tissue repair. Basic biological considerations. *I.J. Am. Acad. Dermatol.*, 13: 701-725.
- Coles E. H. (1986): *Veterinary Clinical Pathology*, 4th ed. Saunders Company, Philadelphia, London, Toronto.
- Conti, B.; Giunchedi, P.; Genta, I. and Conte, U. (2000): The preparation and in vivo evaluation of the wound-healing properties of chitosan microspheres. *STP Pharma Sci.*, 10: 101-104.
- Guyton, A. C. and Hall, J. E. (2006): *Textbook of medical physiology*. 11th Ed Saunders Company, USA.
- Honnas, C. M. (1999): *The Foot*; In *Equine Surgery*. Auer, J. A. and Stick, J. A.; 2nd Ed W.B. Saunders Company, USA.
- Honnas, C. M.; Meagher, D. M. and Linford, R. L. (1998): Surgical management of difficult foot problems in the horse. *Am Assoc Equine Pract.*, 34: 249-253.
- Howling, G. I.; Dettmar, P. W.; Goddard, P. A.; Hampson, F. C.; Dornish, M. and Wood, E. J. (2001): The effect of chitin and chitosan on the proliferation of the human skin fibroblast and keratinocytes in vitro. *Biomaterials*, 22: 2959-2966.
- Hulten, C.; Gronlund, U.; Hirvonen, J.; Tulamo, R. M.; Suominen, M. M.; Marhaug, G. and Forsberg, M. (2002): Dynamics in serum of the inflammatory markers serum amyloid A (SAA), haptoglobin, fibrinogen and alpha2-globulins during induced noninfectious arthritis in the horse. *Equine Vet J.*, 34 (7):699-704.
- Iida, J.; Une, T.; Ishihara, C.; Nishimura, K.; Tokura, S.; Mizukoshi, N. and Azuma, I.(1987): Stimulation of non-specific host resistance against Sendai virus and Escherichiae coli infections by chitin derivatives in mice. *Vaccine*, 5: 270-274.
- Illum, L. (1998): Chitosan and its use as a pharmaceutical excipient. *Pharma Res.*, 15 (9): 1326-1331.
- Ishihara, M.; Nakanishi, K.; Ono, K.; Sato, M.; Kikuchi, M.; Saito, Y., and Yura, H. (2002): Photocrosslinkable chitosan as a dressing for wound occlusion and accelerator in healing process. *Biomaterials*, 23: 833-840.
- Ishihara, M.; Ono, K.; Sato, M.; Nakanishi, K.; Saito, Y.; Yura, H. and Kikuchi, M. (2001): Acceleration of wound contraction and healing with a photocrosslinkable chitosan hydrogel. *Wound Repair Regen.*, 9(6): 513-521.
- Jacobsen, S.; Jensen, J. C.; Frei, S.; Jensen, A. L.; Thoenfer, M. B. (2005): Use of serum amyloid A and other acute phase reactants to monitor the inflammatory response after castration in horses: A field study. *Equine Vet J.*, 37(6):552-556.
- Klokkevold, P. R.; Fukuyama, H.; Sung, E. C. and Bertolami, C. N. (1999): The effects of chitosan (poly-N-acetyl glucosamine) on lingual hemostasis in heparinized rabbits. *Journal of Oral Maxillofacial surgery*, 57: 49-52.

- Klokkevold, P. R.; Subar, P.; Fukuyama, H.; and Bertolami, C. N. (1992): Effects of chitosan on lingual hemostasis in rabbits with platelets dysfunction induced by epoprostenol. *Journal of Oral Maxillofacial surgery*, 50: 41-45.
- Konig, H. E. and Liebich, H. G. (2004): *Veterinary anatomy of domestic mammals*. Schattouer GmbH, Stuttgart, Germany.
- Mair, T.; Love, S.; Schumacher, J. and Watson, E. (1998): *Equine medicine, surgery and reproduction*. WB Saunders Company Ltd, London.
- Malette, W.G.; Quigley, H. J.; Gaines, R. D.; Johnson, N. D. and Rainer, W. G. (1983): Chitosan: A new hemostatic. *Annual Thoracic Surgery*, 36: 55-58.
- Marshall, W. J. (2000): *Clinical Chemistry*, 4th Edition, Mosby, Edinburgh, Toronto.
- Mela, L.; Crowe, W.; Harbig, K.; Wrobel-Kuhl, K. and Kovach, A. (1975): Inhibition of brain mitochondrial function and changes in tissue H⁺ and K⁺ concentration in hemorrhagic shock. *Surg. Forum*, 26: 51-53.
- Milks, H. J. (2002): *Veterinary pharmacology material medica and therapeutics*. 1st Ed. Greenworld publishers, India.
- Minami, S.; Masuda, M.; Suzuki, Y.; Okamoto, Y.; Matsuhashi, A.; Kato, K. and Shigemasa, Y. (1997): Subcutaneous injected chitosan induces systemic activation in dogs. *Carbohydrate Polymers*, 33: 285-294.
- Minami, S.; Suzuki, H.; Okamoto, Y.; Fujinaga, T. and Shigemasa, Y. (1998): Chitin and chitosan activate complement via alternative pathway. *Carbohydrate Polymers*, 36: 151-155.
- Nishimura, K.; Nishimura, S.; Nishi, N.; Saiki, I.; Tokura, S. and Azuma, I. (1984): Immunological activity of chitin and its derivatives. *Vaccine*, 2: 93-99.
- Nishimura, K.; Nishimura, S.; Seo, H.; Nishi, N.; Tokura, S. and Azuma, I. (1987): Effect of multiporous microspheres derived from chitin and partially deacetylated chitin on the activation of mouse peritoneal macrophages. *Vaccine*, 5: 136-140.
- Oberhofer, D.; Rumenjak, V.; Lazic, J. and Vucic, N. (2006): Inflammatory indicators in patients after surgery of the large intestine. *Acta Med Croatica*, 60(5):429-433.
- Okamoto, Y.; Minami, S.; Matsuhashi, A.; Sashiwa, H.; Saimoto, H.; Shigemasa, Y.; Tanigawa, T.; Tanaka, Y.; and Tokura, S. (1992): Application of chitin and chitosan in small animals. In: *Advances in Chitin and Chitosan* (Brine, C. J.; Sandford, P. A.; and Zikakis, J. P. eds) Elsevier Applied Sci., NY, USA: 70-78.
- Okamoto, Y.; Miyatake, K.; Morimoto, M.; Saimoto, H.; Shigemasa, Y. and Minami, S. (2002): Mechanism of wound healing acceleration by chitin and chitosan. *Res. Adv. in Macromolecules*, 3: 1-21.
- Okamoto, Y.; Shibazaki, K.; Minami, S.; Matsuhashi, A.; Tanioka, S. and Shigemasa, Y. (1995): Evaluation of Chitin and Chitosan on Open Wound Healing in Dogs. *J. Vet. Med. Sci.*, 57 (5): 851-854.
- Okamoto, Y.; Yano, R.; Miyatake, K.; Tomohiro, I.; Shigemasa, Y. and Minami, S. (2003): Effects of chitin and chitosan on blood coagulation. *Carbohydrate Polymers*, 53: 337-342.
- Richardson, G. L. and Pascoe, J.R. (1986): Puncture wounds of the foot in horses: Diagnosis and treatment. *Compend Cont Educ Pract Vet.*, 8: s379-s388
- SPSS[®] for Windows[™] (1996): Version 7.5, Copyright SPSS Inc.
- Steckel, R. R. and Fessler, J. F. (1983): Surgical management of seven hoofs wounds in the horse: A retrospective study of 30 cases. *Compend Cont Educ Pract Vet.*, 5: s435- s443.
- Suzuki, Y.; Miyatake, K.; Okamoto, Y.; Muraki, E. and Minami, S. (2003): Influence of the chain length of

- chitosan on complement activation. *Carbohydrate Polymers*, 54: 465-269.
- Tamzali, Y.; Guelfi, J. F. and Braun J. P. (2001): Plasma fibrinogen measurement in the horse: comparison of Millar's technique with a chronometric technique and the QBC-Vet Autoreader. *Res Vet Sci.*, 71(3): 213-7
- Uneo, H.; Mori, T. and Fujinaga, T. (2001): Topical formulation and wound healing applications of chitosan. *Adv Drug Deliv Rev.*, 52: 105-115.
- Uneo, H.; Yamada, H.; Tanaka, I.; Kaba, N.; Matsuura, M.; Okumura, M.; Kadosawa, T. and Fujinaga, T. (1999): Accelerating effects of chitosan for healing at early phase of experimental open wounds in dogs. *Biomaterials*, 20: 1407-1414.
- White N.A. and Moore J.N. (1990): *Current practice of equine surgery*. J.P. Lippincott Company, Philadelphia.

"تأثير الكيتوسان علي التأم جرح النسر التجريبي في الحمر والتغيرات المصاحبة للمنظورات الدموية والنسجية"

*أمل جلال أبو العلا - **سعيد ابراهيم فتح الله- *** س. منامي- **حسن عبد الرحمن عبدالرحمن
*قسم الجراحة- كلية الطب البيطري- جامعة المنوفية- فرع السادات- مصر
**قسم الفسيولوجيا- كلية الطب البيطري- جامعة المنوفية- فرع السادات- مصر
***قسم الجراحة- كلية الزراعة- جامعة توتوري- اليابان

- استخدمت ست إناث ناضجة من الحمر لتوضيح تأثير الكيتوسان على النواحي العيادية ، والتغيرات بالأشعة السينية علاوة علي المتغيرات النسجية و الدموية المصاحبة لعملية التأم جرح النسر التجريبي. وقد أوضحت الدراسة بعد إجراء العملية والعلاج الموضعي بمسحوق الكيتوسان الجاف النتائج الآتية:
- التأم الجروح دون أي دلالات عيادية أو تغيرات في صورة الأشعة السينية تدل علي حدوث العدوى.
 - تحسن درجة العرج في الحمر تحت الدراسة بشكل مرضي وكذلك امتلاء جرح النسر بنسيج أملس متجدد خلال أسبوع من العلاج بمسحوق الكيتوسان الجاف .
 - تكوين نسيج قرني رقيق يغطي الجرح وذلك خلال ثلاثة أسابيع من العلاج وقد تم الالتئام و تغطية جرح النسر بالنسيج القرني بالكامل خلال شهرين.
 - إيقاف النزيف المصاحب للجراحة بشكل قاطع نتيجة العلاج الموضعي بمسحوق الكيتوسان الجاف.
 - الزيادة المضطربة للصفائح الدموية والتي انعكست بشكل معنوي علي انخفاض وقت البروثرومبين(PT) وكذلك وقت البروثرومبين الجزئي النشط (APPT)
 - عدم وجود تأثير معنوي لتغير صورة الدم (حجم الكريات المرصوصة - تركيز الهيموجلوبين- عدد الكريات الحمراء- ودالات الدم)، جلوكوز، بروتينات الدم و الفيرينوجين في الدم.
 - الارتفاع المعنوي لتركيزات إنزيمات الترانس أميناز (AST&ALT) بعد ثلاثة من إجراء الجراحة ثم عودتها إلي سابق تركيزاتها قبل العملية عند اليوم السابع.
 - عند الفحص النسيجي للب الجرح بعد الالتئام وجد تكون: أوعية دموية جديدة وتكون طبقة خلايا الشوكة (prickle cell layer) لمنطقة فوق الأدمة (epidermis) و نسيج ضام بمنطقة الأدمة (dermis).
- وقد استخلصت الدراسة إن استخدام مسحوق الكيتوسان كغيار جاف له تأثير متميز لوقف النزيف، ملطف للألم و محفز ممتاز لالتأم الجروح العميقة للحافر.