

INVESTIGATION OF AN OUTBREAK OF SCRAPIE IN PALESTINE

SALAMEH BARHOOM

Clinical studies , Faculty of Veterinary Medicine. An-Najah National University ,
Nablus –Palestie P.O Box 7, e-mail address: bsalameh@najah.edu

Received: 15. 8. 2007

Accepted: 22. 8. 2007

SUMMARY

This study documents an outbreak of scrapie in adult sheep (East – Friesian Breed) in Palestine with high morbidity rate 21.5% . The clinical findings of the disease were abnormal behavior, ataxia, tremor, incoordination of locomotion, pruritus, loss of wool, nibbling, recumbency and hyperaesthesia to noise, movement or touch. The clinical diagnosis is supported by histopathological lesions and immuno-detection of prion proteins in central nervous system by immunohistochemistry using a reference specific staining monoclonal antibody RIDA Mab L42.

INTRODUCTION

Scrapie is a fatal degenerative disease of sheep and goats affecting the central nervous system of an incubation period 2-5 years. The onset of clinical disease is insidious, affected sheep show sub-

tle changes, excitable, tremor of head and neck which may be elicited by sudden noise or movement, shortly thereafter animal develop intense pruritus with wool loss and skin rubbed raw. After 1-3 months of progressive deterioration which characterized by emaciation, weakness, ataxia, staring eyes, recumbence death occur (Fraser, 2000). A disease affecting man and some animals known as transmissible spongiform encephalopathy (TSE) and is the prototype of the prion disease, the heterogenons group of PrP-sc associated disorders notably bovine spongiform encephalopathy (BSE), related humans disorders variant creutzfeldt-jakob disease of Captive and free ranging mule deer, white tailed deer and Elk (Richard, 2005). Animal prion diseases all seem to be laterally transmitted by contact with infected animals or by consumption of infected feed (Richard, 2005). The disease is caused by a novel transmissible agent largely composed of prion protein (PrP) Prsc, an abnormal folded isoform of the normal cellular PrP, PrPc. The PrP is very resistant to

many environmental insults, chemicals and physical condition that would destroy any virus or microorganism and it does not evoke any detectable immune response or inflammatory reaction in sheep and goats (Prusiner; a, 1982 and b, 1984). The diagnosis of the disease currently based on a clinical history, histopathological changes in the brain and demonstration the presence of PrP – containing Plaque by immunohistochemistry (OIE 2004). This study deals for the first time with an outbreak of scrapie in sheep (East –Fresian Breed) recently encountered in Palestine where clinical, pathological and immunohisto_chemistry studies were conducted.

MATERIAL AND METHODS

An outbreak of scrapie occurring in a private Farm with 95 adult sheep age about 2-5 years (East – Fresian Breed) was investigated, the disease appeared in Azzon area –East of Qalqelia Governorate, North Palestine.

Complete clinical examination was performed on the affected animals in April 2005 and Five recumbent animals were euthanized and subjected to thorough post-mortem examination. Specimens from the pons, medulla, Midbrain, thalamus, cerebellum, anterior spinal cord, hippocampus and ce-

rebrum were collected and fixed in 10% neutral buffered formalin for routine scrapie histopathology, Hematoxylin – Eosine stain (Luna, 1942).

Immunohistochemistry assay: slides with samples collected from suspected cases and uninfected control sheep were stained by a standard protocol developed for PrP-sc detection in central nervous system tissues according (Miller et al, 1994). Briefly slides were dewaxed, rehydrated and treated in 98% formic acid for 20 min prior to hydrated autoclaving for 30 min at 122c°. After blocking with normal goat serum (dilution, 1:66) sections staining monoclonal antibody (RIDA MAbL42) the sections were rinsed and treated with biotinylated goat anti-rabbit immunoglobulin G diluted 1:200, followed by treatment with vector Elite ABC and the color was developed with diaminobenzidine.

RESULTS

This study was conducted on a flock of 95 adult sheep (East – Friesian Breed), all animals were treated with Ivermectin and vaccinated annually against the following enzootic infectious diseases Sheeppox, Pest Des Petit Ruminants, Foot and Mouth Disease. The table (1) illustrate the distribution of animals according to clinical signs and their ages.

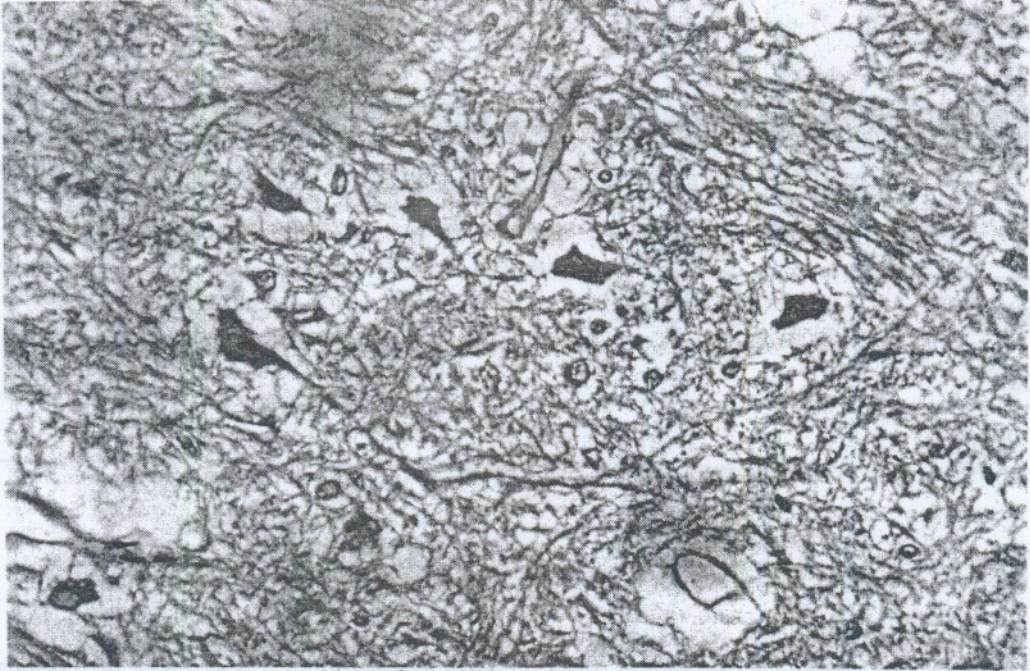


Fig.1: Vacuolation of several neurons with neuronal degeneration in the medulla oblongata of sheep. Hematoxyline and Eosine. X40.



Fig. 2: Positive immunohistochemistry of medulla oblongata of sheep showed abnormal accumulation of PrP. X40

Table 1: Distribution of animals on the bases of clinical signs and age.

	Number &% of clinically affected animals	Number &% of clinically healthy animals
Number of animals	25 (21.05%)	70 (73.7%)
Age in years	3-5	1-2

Clinical findings : The clinical signs of the disease appear at age 3-5 years old, morbidity rate 21.05%, affected animals starts by abnormal behaviour tendency where it separate itself from the flock then return normally if left undisturbed at rest, howere when stimulated by excessive movement like handling or abnormal noise, animals tremble or fall down, ataxia, tremor of the head and neck, incoordination of locomotion, pruritus, loss wool, emaciation despite retention of appetite and recumbency. The recumbent animals are hyperexcitable, tends to carry its head high and has fixed stare, nibble at the affected area of the skin, wool loss and denudation of skin. The course of the disease from onset until recumbency lasts 3-6 months .

Gross Pathology ; There were no characteristic gross lesions.

Histopathology; Vacuolation of neurons in medulla, Pons and midbrain, surrounding cytoplasm showed signs of degeneration and Interstitial spongy degeneration often found and amyloid plaques (sometimes) as in Fig: "(1)

Immunohistochemistry: Positive staining of medulla oblingata, pons and midbrain tissues were identified as strong Particulate and cytoplasmic staining in neurons of tissues as seen in Fig (2) while negative antibody were seen in control tissue.

DISCUSSION

Scrapie recognized as a distinct disease of sheep in many countries, its distributed widely in Europe, North America and occur sporadically in countries in Africa and Asia (Frederic et al, 2003), According to OIE International Animal Health code, scrapie can be found under list B and within the European Unoin countries, the disease has been a notifiable since January 1993 (OIE, 2004). Most breeds of sheep are affected although in some there is a clear genetic basis for resistance or low prevalence of clinical disease, scrapie has also been described in Moufflon (*Ovis musimon*) a primitive type of sheep such animal incubating the disease and that animal never develop clinical signs may still be a source of infection to others (Wood et al, 1992). Sheep are considered the natural hosts for scrapie agent, a considerable body of evidence indicate that most sheep with scrapie were infected early in life and the agent has persisted within them in quiescent state during intervening period (Fraser, 2000) Most Cases of clinical scrapie occur in sheep 2-5 years of age (Hoinville, 1996) Rarely Cases present in sheep under one year of age because in some instances the commercial lifespan of sheep may be too short to allow the clinical disease to develop (Frederic, 2003) and these findings were similar to that found in comparing with the present study. The encountered clinical findings in sheep were characterized by insidious onset,

abnormal behavior, affected animal may lead or trail the rest of flock, tremor, nibbling, ataxia, incoordination of the gait, pruritus, lose weights and recumbency, all these findings, were in accordance with those previously reported(Kimberline, 1981; Parry, 1983; Fraser, 2000; OIE, 2004). A particular interest of this outbreak is its appearance among adult sheep with high morbidity rate 21.05% in comparing with sporadically occurrence in Europe (OIE, 2004). The Pathological findings reported in this outbreak were prominent in the medulla, Pons, Mid-brain which characterized by interstitial spongy degeneration and all of these findings were in agreed with those previously reported (Jubb et al, 1985; Wood et al., 1997; Jeffry et al., 2001). The presence of prion protein in body cells with a high concentration on the surface of nerve cells in the brain due to proteinase K resistance which deposite on to the brain killing other nerve cells which leads to holes in spongiform diseases (Pousiner, 1998). Immunohistochemistry appears to be useful in detecting scrapie in affected animals and remains promising as it is widely available and inexpensive (Belt et al., 1999). The final diagnosis was based on the characteristic clinical signs, histopathological findings and identification of the prion by immunohistochemistry.

REFERENCES

Belt, P.B .G.M, Muileman I.H., Schreuder B.E.C., Gielken

- A.L.J., and Smith M.A. (1995): Identification of Five allelic Variants of the sheep PrP gene and their association with natural scrapie. *Journal of General Virology*, 76, 509-517.
- Fraser H. (2000): Scrapie in sheep and goats and related diseases. In: Diseases of sheep. Third edition. Martin W.B., and Aitken I.D. Black-well scientific Ltd. Oxford. U.K. 207-218.
- Frederic A Murphy, E Paul J Gibbs, Marinac Hozinek, Michael J Studdert. (2003): *Veterinary virology*. 3rd ed Academic press Newyork , P575-576.
- Hoinville L.J. (1996): A review of the epidemiology of Scrapie in sheep. *Rev. sci tech off. Int.Epiz.* , 15, 827-852.
- Jeffry M., Martins., Gonzalezt., Ryder S.J., Bellwothy S.J., and Jackman R. (2001): Differential diagnosis of infections with the Bovine Spongiform Encephalopathy (BSE) and Scrapie agents in sheep. *J. comp. Pathol.*, 125, 271-284.
- Jubb K.V.F, Kennedy P.C, and Palmer N. (1985): *Pathology of Domestic Animals* -3rd ed. Vol-I. Academic Prees. Newyork PP 305-307.
- Kimberline R.H. (1981): Scrapie Disease *Br. Vet J.* 137, 105-112.
- Luna LG. (1942): *Manual of histologic staining methods of the Armed Force Institute of Pathology*. 3rd .ed.. Newyork; M.C.Grow-Hill Book company.
- Miller J.M., Jenny A.I., Taylor W.D., Race R.E., Ernst D.R., Katz J.B., and Rubenstein R. (1994): Detection of prion protein in Formalin-Fixed brain by hydrated autoclaving immunohistochemistry for diagnosis of Scrapie in sheep. *J.vet.Diagn. Investing.*, 16:366-368.
- Office International Des Epizootics (2004): *Manual of Diagnostic tests and Vaccine for Terrestrial animals- Scrapie*. 5th edition,
- Parry H.B. (1983): *Scrapie Disease in sheep. Historical Clinical Epidemiological, pathological and practical Aspects of the natural disease*. Oppenheimer DR, ed. Academic press London . UK., pp192.
- Pousiner S.B. Prions. *Proc Natl Acad sci USA*. 1998., 95: 13363-83
- Prusiner S.B. (1982,a): Novel Proteinaceous infectious Particle Cause Scrapie. *Science*: 216:136-44.
- Prusiner S.B. Prion (1984b): Novel infectious Pathogen. *Advance virus. Res. a*, 29; 1-56,
- Richard T Johnson. (2005): Review. Prion diseases. *Lancet Neurol*. 4: b35-42.
- Wood J.L.N, MCGill I.S., Done S.H., and Bradley R. (1997): Neuro Pathology of Scrapie: a Study of the distribution patterns of brain lesions in 222 cases of natural scrapie in sheep, 1982-1991: *vet. Rec.*, 140, 167-174.
- Wood J L.N., Lund L.J., and Done S.H., (1992): The natural occurrence of scrapie in Moufflon. *Vet. Rec.*, 130, 25-27.

استكشاف مرض الحكة بفلسطين

سلامه برهوم

جامعة النجاح الوطنية
كلية الطب البيطري فلسطين

هذا التقرير يصف تفشي مرض الحكة في الأغنام البالغة سلالة الفريزين الشرقي (-East Friesian) في فلسطين حيث كان مصحوباً بنسبة إصابة عالية 21.5%. اشتملت العلامات السريرية على تصرفات غير طبيعية، ترقح، رجفة، عدم اتزان في الحركة، حكة، تساقط الصوف، تلمض، رقاد وفرط الحس لأي ضوضاء، حركة أو ملامسة. تم تأكيد التشخيص السريري بالتغيرات المجهرية الحاصلة على نسيج الحيوانات المصابة والكشف المناعي لتجمعات البروتينات اليروتينية في الجهاز العصبي المركزي باختبار Immunohistochemistry بالاستعانة بأجسام مضادة أحادية النسخة RIDA Mab L42.