

## **SERUM HEPATITIS (THEILER'S DISEASES) IN ANTITETANIC SERA PRODUCING HORSES 33 CLINICAL CASES**

**M. M. EL-HANAFY**

Faculty of Vet. Med., Dept. of Internal Medicine and Infectious Diseases,  
Cairo Uni.

**Received:** 5. 8. 2007

**Accepted:** 26. 8. 2007

### **SUMMARY**

The medical records of 33 horses aged between 3.5 and 9 years suffering from serum hepatitis were reviewed. Serum hepatitis in horses was clinically manifested by mental depression related signs in most of the affected horses including dullness, depression, lethargy, compulsive walk, and hyporeflexia. Other cases showed mental irritation related signs including hyperexcitability, muscle tremors and convulsions. The majority of horses were completely anorexic, enduring acute abdominal pain. The clinical examination revealed congested mucus membranes, tachypnea, tachycardia, abdominal distention and photosensitization. The blood picture revealed anemia, leukocytosis, and neutrophilia with regenerative shift left shift. Serum biochemistry revealed hypoproteinemia, hypoalbuminemia, hypoglycemia and increased activity of serum aspartate aminotransferase, Gama glutamyle transferase, alkaline phosphatase, increased total bilirubin and in-

creased prothrombin time.

All horses were treated with non-steroidal anti-inflammatory; 24 of which received as well corticosteroids. Special care were also trialed, including lactated ringers, dextrose 5% solutions, and neomycin. To control the nervous signs Xylazine was indicated. Most of the horses were treated for more than 5 days.

Fifteen out of the 33 examined horses rapidly died few hours from the onset of the clinical signs, while nine were euthanatized shortly before death because of their deteriorated condition.

The postmortem examination of the fifteen horses' revealed ruptured liver capsule, severe internal hemorrhages and friable liver parenchyma, the other nine cases showed hepatomegaly without rupture of the liver capsule. The histopathological examination of the liver tissues showed massive subcapsular hemorrhages with granulation tissue

proliferation replacing the hepatic parenchyma. Necrobiotic changes in hepatocytes, dilation of liver sinusoids and leukocytic infiltration by neutrophils, lymphocytes, macrophages and little number of mast cells were demonstrated.

---

## INTRODUCTION

Serum hepatitis is the major clinical problem of hepatic failure in horses (Messer and Johnson, 1994a). The exact etiological agent, mechanism and transmission of equine serum hepatitis are unknown, for which it was named Idiopathic acute hepatic disease in horses (Messer and Johnson, 1994b).

The diseases is frequently reported 30 to 70 days following the administration of biologic products (Divers, 1983), particularly those containing equine serum (Hjerpe, 1964 and Smith et al., 1991) especially tetanus antitoxin (TAT) (Smith et al., 1991). In some other cases, it has been observed that the affected horses may not have received TAT but may have been in contact with other horses that received TAT, therefore contact transmission could be suggested (Thomsett, 1969 and Tennant, 1978). Other clinical cases were reported without previous certain causes (Oduye et al., 1974).

Occurrence of the disease in groups of adult horses during the late summer or early fall (August to November) suggests an infectious (viral) or vec-

tor-spread etiology (Thomsett, 1969 and Tennant, 1978), although supporting evidence is lacking. The seasonal occurrence could reflect the fact that many foaling mares received TAT in the spring of the year along with their newborn foals. Lactating mares that received TAT at foaling seemed to be more susceptible (Messer and Johnson, 1994a).

A Type III (immune-complex mediated) hypersensitivity mechanism has also been proposed (Merck, 2000). The Majority of horses used for the production of commercial TAT died of acute hepatic failure probably from serum hepatitis as demonstrated from the present study.

The clinical signs of serum hepatitis usually developed with a wide variation in their severity and clinical course; usually beginning by decreased appetite to anorexia, acute abdominal pain, and hepatic encephalopathy. The mental depression related signs are variable, ranging from lethargy to maniacal behavior, central blindness, and ataxia (Robinson, 1997). Fever, acute respiratory distress has been recorded in some horses.

This paper describes the history, clinical findings, laboratory values and histopathological findings and outcomes in 33 horses with serum sickness.

## MATERIAL AND METHODS

### Animals

The horses belonged to the laboratory farm of the Egyptian organization for biological products and vaccines VACSERA. These horses were immu-

nized with tetanus toxoid for the production of TAT. The horse data and history were obtained from the medical records of the farms over a period of 2 years. A detailed physical examination was carried out for each case separately; the post-mortem examinations were carried out for the horses which rapidly succumbed from the acute illness.

The serum was removed by Pasteur pipette and clarified by centrifugation at 3000 r.p.m, for 15 min, to remove any residual red cells. The sera obtained were used to determine: total protein, albumin, glucose, aspartate aminotransferase (AST), gamma glutamyl transferase ( $\gamma$ GT), alkaline phosphatase (PAL), and total bilirubin.

**Table 1 Data and history of 33 horses with serum hepatitis**

		Number of horses
Age	5 years or younger	12
	6 to 10 years	17
	More than 10 years	4
Sex	Males	33
Medication	Dextrose 1ml/kg/hr	33
	Lactated ringer's solution 0.5ml/kg b. wt.	33
	Nonsteroidal anti-inflammatory	33
	Corticosteroid therapy	24
	Neomycin 5.0 mg/kg b. wt. p.o. t.i.d	33
	Xylazine 1 mg/kg B. wt. I/V b.i.d	
Dietary management	Barley (3 kg / horse ) divided on 2 times and free choice of hay	

### Samples

Blood samples were collected by jugular vein-puncture into heparinized vacutainers, immediately gently mixed and put on ice. These samples were used to determine the total leukocytic count, differential leukocytic count and blood platelets count according to the methods described by Schalm et al., (1975).

Part of the blood samples were taken at the same time on plain vacutainers and were left to coagulate at room temperature till the clot was retract-

Other whole blood samples were collected into citrated tubes for the determination of prothrombin-time, (Schalm et al., 1975).

Specimens from the liver were taken from necropsied horses for histopathological examination.

### RESULTS

As reported in table 2, serum hepatitis in horses was clinically manifested by mental depression related signs in most of the affected horses (76 %)

**Table 2 clinical findings in 33 horses with acute serum hepatitis (Theiler's diseases)**

Clinical findings	Horses	
	No.	%
<b>CNS related signs</b>		
Signs of mental depression (dullness, depression or lethargy)	25	76
Signs of mental irritation (hyperexcitability, mania behavior)	8	24
Anorexia	28	85
Signs of acute abdominal pain	24	73
<b>Mucous membranes</b>		
Icteric	5	15
Congested	21	64
Severely congested with petechial hemorrhages	7	21
<b>Rectal temperature</b>		
Slightly elevated (>38.2 °C)	11	33
Normal (37 – 38.2 °C)	17	51
Hypothermia less than (<37°C)	5	15
<b>Respiration</b>		
Normal respiration (8-14 breath/min. – thoracoabdominal type)	17	33
Tachypnea (respiratory rate > 14 breath/minute)	14	42
Sobbing respiration	2	6
Tachycardia (heart rate > 40 beat / minute)	23	70
Diarrhea	0	0
Reluctancy to movement	5	15
Recumbency	2	6
Abdominal distention	5	15
Photosensitization	3	9
Rapid death	15	45

**Table 3 laboratory values in 33 horses with acute serum hepatitis (Theiler's diseases)**

<b>Serum biochemistry</b>		
Hypoproteinemia (<6.6 g %)	9	27
Hypoalbuminemia (<2.9 g %)	11	33
Decreased blood glucose level (<60mg %)	23	70
Increase serum AST activity (>400 IU/L)	33	100
Increase serum $\gamma$ glutamyle transferase (>25 IU/L)	18	54
Increased serum alkaline phosphatase activity (>233 IU/L)	16	48
Increased total bilirubin (>6 mg %)	5	15
<b>Hematology</b>		
Anemia (hemoglobin > 11 g %)	33	100
Leukocytosis (>14000/ul)	33	100
Neutrophilia with left shift (>8580/ul)	33	100
Thrombocytopenia (<1.0 x 10 <sup>5</sup> /ul)	33	100
Increase prothrombin time (>13 sec)	33	100

including dullness, depression, lethargy, compulsive walk, and hyporeflexia. Other cases (24%) showed mental irritation related signs including hyperexcitability, muscle tremors and convulsions. The majority of the horses (85%) were completely anorexic. Subacute abdominal pain was recorded in 73% of the cases. The clinical examination revealed icteric mucus membranes (15%), while 64% showed congested mucus membranes, tachypnea (42%), tachycardia (70%), abdominal distention (15%) and photosensitization (9%).

As reported in table 3, the serum examination revealed hypoproteinemia (27%) hypoalbuminemia (33%) hypoglycemia (70%), increased activity of serum aspartate aminotransferase (100%), Gamma glutamyl transferase (54%), alkaline phosphatase (48%), increased total bilirubin (15%) and increased prothrombin time (100%).

The blood picture revealed anemia, leukocytosis, and neutrophilia with regenerative shift left shift (100%)

All diseased horses were kept under clinical observation with nursing therapy, but the responses

to therapy were unsatisfactory although the abdominal pain and mental changes were diminished.

Fifteen horses rapidly died few hours from the onset of the clinical signs. Nine other horses were euthanatized shortly before death because of their hopeless condition. All cases showed hepatomegally in post mortem examination, 13 cases out of 24 showed ruptured liver capsule and severe internal hemorrhages, 17 cases showed friable liver tissues. The microscopic examination of the liver tissues showed massive subcapsular hemorrhages with granulation tissue proliferation replacing the hepatic parenchyma (Photo 1). Necrobiotic changes in hepatocytes, dilation of liver sinusoids and leukocytic infiltration by neutrophils, lymphocytes, macrophages and little number of mast cells were also demonstrated (Photo 3). Massive proliferation of the portal fibrous tissues and hyperplasia of the bile duct were observed (Photo 2). Few cases reacted positively with Congo red stain which appeared as a homogenous eosinophilic mass deposited on the wall of the hepatic sinusoids (Photo 4), which confirms hepatic amyloidosis.

## Histopathological findings




Photo (1) Liver showing subcapsular hemorrhages and large area of granulation tissues. (H&E X100)




Photo (2) Liver showing necrobiotic changes of hepatocytes and mononuclear cells proliferation. (H&E X100).

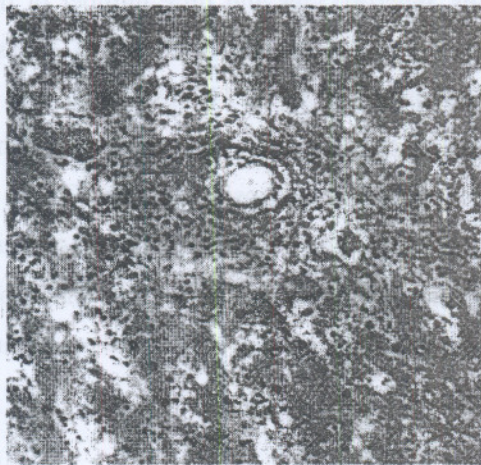


Photo (3) Liver showing massive fibrous connective tissue proliferation and hyperplasia of bile ducts. (H&E X100).




Photo (4) Liver showing deposition of hepatic eosinophilic amyloid substances on the wall of hepatic sinusoids. (Congo red X200).

## DISCUSSION

Serum hepatitis (Theiler's diseases) is the most common cause of hepatic failure in horses (Mary Ann et al., 1997), the condition is usually reported 30-70 days as a potential complication following the administration of biological products of equine origin (Divers, 1983). In the present study, serum hepatitis was recorded following the repeated administration of tetanus toxoid. The condition usually develops as a result of immune-complex hypersensitivity (hypersensitivity reaction type III).

Following the repeated administration of tetanus toxoid to horses with high level of circulating antibodies, immune complexes are formed in the blood stream (Stites et al., 1997). These complexes are normally removed by the cells of the mononuclear phagocytic system. However, if complexes are produced in excessive amounts, they may be deposited in the wall of blood vessels specially where there is a physiological outflow of fluid for example in liver sinusoids and renal glomerulie (Tizard, 1996). The deposited immune complexes irritate the nearby tissues and provoke complement cascade. When the complement-activating immune complexes are present in tissues, they generate chemotactic peptides that attract neutrophils and other inflammatory cells. Neutrophils release free radicals and proteolytic enzymes into the liver vascular tissues leading to vascular damage and loss of vascular tone. The later is fol-

lowed shortly thereafter by vascular dilatation and increased vascular permeability. Consequently, the blood flow to the injured liver tissues increases where the fluid moves from the blood to the liver tissues causing, edema, hemorrhage and hepatomegally. The swelling of the liver tissues causes stretching of the liver capsule and acute abdominal crisis as recorded in 24 cases of the diseased horses or may even lead to the rupture of the liver capsule and sudden death as demonstrated in fifteen cases.

Through this mechanism liver tissues get destructed, and the degree of damage governs the severity of the clinical illness. Lesions generated in such a way are classified as immune-complexes mediated hypersensitivity (Tizard, 1996).

Not all horses used in the production of tetanus antisera suffered from serum hepatitis which could be correlated with the development of hepatic amyloidosis in such horses. Hepatic amyloidosis presumably develops as a reaction to the repeated injection of foreign protein (Radostits et al., 2000). In our study it has been observed that the liver tissues showing deposition of amyloid on the wall of sinusoids, suffered a less severe inflammation and less leukocytic infiltration. The latter could be interpreted by the fact that the amyloid material is a glycoprotein impervious material which does not allow the infiltration of immune complex and consequently prevent the vascular neutrophil immigration and chemotaxis.

The development of the amyloid material thus probably minimizes the progress of acute inflammation which could explain why not all horses used in the production of immune sera did not die from serum hepatitis in short term during their production cycle, but survived for many years.

One of the primary effects of acute liver damage is a precipitate fall in blood sugar. If hepatic damage occurs more slowly the hypoglycemia is less marked (Kaneko et al., 1997), but in our study hypoglycemia was recorded in 70% of the cases which indicates that the process of liver damage developed rapidly. The persistent hypoglycemia evolves structural changes in the brain - hypoglycemia encephalopathy- (Radostits et al., 2000) and these may be the basis of the observed nervous signs.

The severe toxemia appears to be responsible for congestion of the mucus membranes in most diseased cases (Radostits et al., 2000). In this condition both antigenic and metabolic toxemias operate, the antigenic toxemia is due to injection of tetanus toxoid and the metabolic toxemia may be due to liver damage and insufficiency of hepatic detoxification of the portal blood.

Jaundice and photosensitization do not always occur and may be conspicuously absent in acute liver damage

The results of serum biochemistry also denote

that the occurrence of liver damage is acute rather than chronic taking into consideration the high activity of serum aspartate aminotransferase, Gamma glutamyl transferase and alkaline phosphatase. In conclusion, the condition of serum hepatitis does not only follow the administration of tetanus antitoxin but it also follows the repeated administration of tetanus toxoid, and regardless to the cause, the mechanism which operates in such alternate is the same, which is the formation and deposition of immune complexes.

During our study no clinical signs were observed in contact horses in the same stable, from which we can conclude that the possibility of contact transmission is very weak but could not be completely excluded.

## REFERENCES

- Divers, T. J. (1983) Liver diseases and liver failure in horses, in proceeding. *Am Assoc Equine Pract*; 29:213-233
- Hjerpe, C. A. (1964) Serum hepatitis in the horse. *J Am Vet Med Assoc.* 144:734-740.
- Kaneko, J. J., Harvey, J. W. and Michael, L. B. (1997). *Clinical Biochemistry of Domestic Animals*, 5th ed. New York, NY, USA, Academic Press.
- Mary, A. G., MacAllister, C. G., Ely, R. W. and Edwards W. C. (1995) Hepatic disease associated with administration of tetanus antitoxin in eight horses. *J Am Vet Med Assoc.* Vol 206 No. 11 June 1 1737-40
- Merck, (2000) *The Merck Veterinary Manual*. 8th ed. Pub-



- lished by merck & Co., Inc Whitehouse station, N.J.,USA
- Messer, N. T and Johnson, P. J. (1994a) Idiopathic acute hepatic disease in horses: 12 cases. *J Am Vet Med Assoc.* June 15;204(12):1934-7
- Messer, N. T and Johnson, P. J. (1994b) Serum hepatitis in tow brood mares. *J Am Vet Med Assoc.* Vol 204 No. 11, June 1.
- Oduye, O.O., Hill, D.H. and Apokodje, J. U. (1974) Parenchymatous hepatitis in horses in Nigeria. *J Nig Vet Med Assoc* 3;86-91
- Radostitis, O. M., Blood, D. C. and Gay, C. C. (2000) *Veterinary Medicine A text book of a disease of cattle, sheep, pigs, goat and horse*, 9th ed. The English language book Society, Bailliere Tindall Ltd., 1 London.
- Robinson, N. E, (1997) *Current Therapy in Equine Medicine.* philadelphia:WB Saunders Co,
- Schalm, O. W., Jam, N. C. and Correll, E. J. (1975). *Veterinary Hematology* 3 ed ed. Lea and Febiger Philadilphia
- Smith, H. L., Chambers, G. A., and Wedel, R. (1991) Acute hepatic failure (Theiler s disease) in a horse. *Can Vet J*,32:362-364.
- Stites, D. P., Terr, A. I. and Parslow, T. G. (1997) *Medical immunology* 9th ed Middle east ed. Appelton & Lange Norwalk, Connecticut/San Mateo California
- Tennant, B. (1978) Acute hepatitis in horses; problems of differentiating toxic and infectious causes in the adult, in *Proc.. Am Assoc Equine Pract* 1978;24:465-471.
- Thomsett, L. R. (1969) Acute hepatic failure in the horse. *Equine Vet* 3:15-19
- Tizard, I. (1996): *Veterinary Immunologyg an Introduction.* 5<sup>th</sup> ed. W. B. Saunder company.

التهاب الكبدى المناعى(مرض تيلر) فى الخيول المستخدمة فى إنتاج مصل التيتانوس  
٣٣. حالة مرضية

محمد محبى الدين محمد الحنفى

قسم الأمراض الباطنة و المعدية كلية الطب البيطرى جامعة القاهرة

اوضحت السجلات الطبية بعدد ٣٣ حصان تتراوح اعمارهم ما بين ٣,٥ الى ٩ سنوات و تعانى من الأتهاب الكبدى ان الأعراض الأكلينيكية للمرض فى معظم الخيول المصابة كانت ضعف ذهنى و خمول و اضطرابات فى الحركة انخفاض رد الفعل. الى جانب حالات اخرى تعانى من ارتعشات و تشنجات عضلية. اغلبيه الخيول كانت تعانى من فقدان الشهية الكامل و ألم باطنى حاد و تبين من الفحص الأكلينيكى احتقان لو اصفرار فى الأغشية المخاطية و زيادة معدلات التنفس و النبض و انتفاخ البطن و الحساسية للضوء تبين من التحليل الكيمىائى للدم انخفاض فى مستوى البروتين و الزلال و الجلوكوز و زيادة فى مستوى الخماثر (اسيرتيت امينو ترانسفيريز - جلوتاميل ترانسفيريز-الفوسفاتيز القلوى) الى جانب مستو الصفراء و وقت البروثرومين و اوضحت صورة الدم انخفاض مستوى الهيموجلوبين و زيادة كرات الدم البيضاء الصغيرة و اليافعة تم محاولة علاج جميع الحالات باستخدام مضادات الأتهاب الغير ستيرويدية الى جانب مضادات الأتهاب الأستيرويدية فى ٢٤ حالة الى مع العلاج بالمحاليل (دكستروز ٥٪ و رنجرز لاكلتيت) مع النيومايسن. وللتحكم فى الأعراض العصبية تم حقن الزيلازين لقد استمر العلاج لأكثر من خمسة ايام و لكن نفقت خمسة عشر حالة مصابة فى خلال ساعات من ظهور الأعراض الأكلينيكية فى حين ان تسعة خيول اخرى تم التخلص منهم بواسطة القتل الرحيم لسوء حالتهم و من التشريح المرضى للحالات النافقة تبين انفجار فى حافظة الكبد و تضخم الكبد مع انزفة داخلية شديدة مع سهولة تفتيت نسيج الكبد و تبين من الفحص المجهرى لنسيج الكبد انزفة تحت حافظة الكبد و تتركز فى خلايا الكبد مع تجمع خلايا التهابية