

## EFFECT OF ENVIROMENTAL TEMPERATURE ON *ICHTHYOPHONUS HOFERI* ISOLATED FROM FRESHWATER FISHES

BADRAN, A. F. H.<sup>1</sup>, MONA M. HUSIEN<sup>2</sup> AND SOAD S. A. SALAMA<sup>2</sup>

1. Faculty of Veterinary Medicine, Suez Canal University
2. Animal Health Research Institute, ARC, Ministry of Agriculture, Dokki, Giza

(Manuscript received 9 October 2007)

### Abstract

A total of 300 fishes examined related to 3 freshwater fish species, out of which 180 samples proved to harbour *Ichthyophonus hoferi* (60%) from River Nile, Ismailia Nile branch and El.Waffa fish farm at Giza. The incidence of isolation was higher in winter season (68.75%) than in summer (45.7%). The clinical investigation revealed dark grey coloration or even blackness of the skin with deformity in the skull, and the eyes appeared cloudy. The most predilection site of *I. hoferi* was liver followed by spleen, heart, kidney, intestine, ovary and eyes. Post-mortem examination of infected fishes revealed the presence of white to grey nodules of variable sizes in liver, kidney, heart, spleen and intestine. Isolation of the fungus was carried out on Sabouraud's Dextrose agar with 1% calf serum and in Minimum Essential Medium + 10% fetal calf serum at pH 3, 5, 7 and 9 within 10-15 days. At temperature 4°C the organism can still survive. The viability of the cultures was gradually diminished from 4°C to 0°C.

### INTRODUCTION

From the infectious diseases of wild and cultured Tilapia species among different fish farms in Egypt is Ichthyophonosis (Shaheen & Easa 1996). Ichthyophonosis is chronic, systemic, infectious and granulomatous fungal disease of most organs and tissues of many marine fishes and freshwater fishes causing high mortalities (McVicar, 1982). More recently, ichthyophonosis has been reported as an emerging disease in Chinook salmon in several Alaskan rivers (Kocan, Hershberger & Winton, 2004) and in sockeye salmon in British Columbia (Tierney & Farrell, 2004). The causative organism was named *Ichthyophonus hoferi*, (*I. hoferi*) by Plehn & Mulsow (1911). In Egypt, Ichthyophonosis was recorded for the first time from the wild Nile catfish (*Clarias lazera*) at Alexandria Governorate (Faisal *et al.*, 1985), as well as from both Nile catfish and tilapia (Manal *et al.*, 1996) and also in aquarium fish (Nahla *et al.*, 1997). Recently, it was reported from freshwater fish (*O. niloticus*) (Manal, 2002), as well as from sex reversal all-male tilapia (Ziedan 1999) and from females Nile catfish and tilapia (Nahla & Nashwa, 2003). The problems of this disease originated from the high losses of fish brood stocks and during fish processing industry, the fillets became very

soft, slimy and with strong off odours (Spanggaard *et al.*, 1994). Even after chilling, storage or smoking, the infected fillets may transfer the infection to the uninvaded fillets in storage at 8°C (McVicar, 1982). The organism will still survive at deep freezing and the only effective method of destroying the organism was deep freezing of fish at a temperature of -20°C (Athanasopoulou, 1992).

This research was planned to study prevalence and isolation of *I. hoferi* from freshwater fishes with referring to clinical signs and post-mortem examination. Also, investigation of the effect of some environmental factors on the survival of *I. hoferi* among freshwater fish was undertaken .

## MATERIALS AND METHODS

A total of 300 apparently healthy or diseased (wild and cultured) freshwater fishes was collected from different localities (Table 1) and transported with the minimum of delay to the laboratory for isolation of *I. hoferi*. From positive cultures, identification of the isolates was based on morphological characters according to McVicar (1982).

### **Prevalence of Ichthyophonosis according to seasonal variation with determined the distribution of the organism among the different organs of infected fishes**

All fishes were subjected to clinically and post-mortem examination according to the methods described by McVicar (1982). Samples were taken from the internal organs (liver, kidney, spleen, heart, ovary, testes and eyes) and embedded on Sabouraud's Dextrose agar with 1% calf serum and in Minimum Essential Medium + 10% fetal calf serum (MEM-10) at pH 3, 5, 7 and 9. The cultures were incubated at room temp. for 15 days. Also, squash preparation of the affected organs was prepared according to the method described by Faisal *et al.* (1985).

*I. hoferi* identification was carried out through studying the morphological characters of the fungus, hyphal growth of fungus suspended in the cultural broth media, MEM-10 and staining by Lacto phenol Cotton Blue stain (L.P.C.B) according to McVicar (1982). According to Spanggaard *et al.* (1995) a small portion of the hyphae were examined microscopically using low and high power objectives after staining.

### **Effect of some environmental factors on *Ichthyophonus hoferi* isolates**

#### **A -Effect of Temperature on survival of the fungus**

Ten isolates of *I. hoferi* from freshwater fishes were inoculated into MEM-10 (pH 5) and incubated at room temperature (20±2°C). After 7 days, 5 cultures were

incubated at 4°C and the others were incubated at 0°C for 5 days. After that, all cultures were tested for the viability of *I. hoferi* by reculturing into the same medium.

#### **B- Effect of different pH**

All isolates of *I. hoferi* from freshwater fishes were inoculated into Essential Medium + 10% fetal calf serum (MEM-10) at pH 3, 5, 7 and 9 were incubated at room temp. for 15 days

### **RESULTS AND DISCUSSION**

Clinical examination of naturally diseased freshwater fishes revealed the presence of excessive mucus secretion covering the skin and dark grey coloration or even blackness of the skin. Hemorrhagic spots over the skin were occasionally seen. In some cases, depression or notch was seen in the skull bone near or between the eyes with bone deformity in the skull, and the eyes appeared cloudy. In addition to that, there were easily detached scales with fin rot. These results supported those reported by Faisal *et al.* (1985), Manal *et al.* (1996), Shaheen & Easa (1996), Nahla *et al.* (1997), Ziedan (1999) and Manal (2002) in the infected Nile catfish, tilapia, freshwater salmonids, tilapia, ornamental fishes, cultured tilapia and in wild and cultured tilapia.

Post-mortem examination of naturally diseased Nile Tilapia freshwater fishes revealed pale, enlarged liver with white spots in their parenchyma especially at the caudal loop (Fig. 1). The gall bladder appeared distended with bile, and ascitic fluid in the abdominal cavity in some cases was also found. The gall bladder appeared leathery, enlarged and hemorrhagic and the spleen was congested, enlarged and friable in some cases with white nodules in *Clarias gariepinus* (Fig. 2). The kidneys were enlarged, hemorrhagic with clear spots. The intestine showed congestion of the intestinal wall, corrugation and containing white to grey nodules of variable sizes. In addition, there were macroscopic white nodules in ovarian tissue with greyish coloured ova. Moreover, spiral curvature, scoliosis and lordiosis were shown in Nile Tilapia (Fig. 3). These results are in agreement with those obtained by Faisal *et al.* (1985), Shaheen and Easa (1996), Manal *et al.* (1996), Ziedan (1999) and Manal (2002). Nahla and Nashwa (2003) reported that the internal examination of apparent healthy *O. niloticus* showed microscopic and macroscopic white nodules in ovarian tissue, while, in *C. carpio* showed only microscopic lesions in ovarian tissue with white macroscopic nodules in liver, kidney and spleen. Also, Kocan *et al.* (2006) found that the mean heart weight of infected fish was 40% greater than of uninfected fish.

The results revealed that 180 fish out of 300 were positive for Ichthyophonosis with a percentage of 60% (Table 1). This result was higher than that recorded by Shaheen and Easa (1996), who found that, the infection reached 37.5% in cultured tilapia, while, Manal (2002) recorded that the infection reached 58.8% in *O. niloticus*. Nahla and Nashwa (2003) found that the infections in females of *O. niloticus* and *C. carpio* were 40% and 30%, respectively, and lower than those found by Nahla *et al.* (1997) who found that, the infection reached 86.7% in ornamental fishes. Ziedan (1999) found that infections in all-male tilapia produced hormonally or through hybridization were 84% and 82%, respectively.

As shown in Table 2, the seasonal prevalence of *I. hoferi* infection among freshwater fishes was recorded; the maximum prevalence during winter was (68.75%) followed by autumn (66.6%) and the minimum prevalence was recorded in summer (45.7%). These results were in agreement with those reported by Sitja-bobadilla and Alvarez Pellitero (1990) who reported similar seasonal pattern of Ichthyophonus infection among wild and cultured Sea bass. Also, Manal *et al.* (1996) found that, the prevalence and infection intensities were higher at 16°C than 22°C in both tilapias and catfish. Manal (2002) reported that the higher prevalence of infection in *O. niloticus* was during winter (68.1%), followed by autumn (63.33%), spring (51.25%) and summer (37.7%).

The present results revealed that the liver was the most infected organ with *I. hoferi* (94.4%), followed by spleen (88.8%), kidney (75%), intestine (66.6%), heart (55.5%), then, ovary (25%) and eyes (10.5%). These results were in agreement with those obtained by Faisal *et al.* (1985), who recorded a higher prevalence in liver followed by kidney, spleen and heart of the examined *Clarias lazera* at a rate of 42%, 36%, 14% and 4%, respectively. Moreover, the results agreed with those reported by Ziedan (1999) who found that the prevalence of infection in the organs of male *O. niloticus* was higher in liver (81%), followed by kidney (79%), spleen (54%), intestine (60%) and eye (47%). Manal (2002) recorded a higher prevalence in liver followed by kidney, spleen, intestine, ovary, heart and eyes at a rate of 100%, followed by 88.09%, 78.23%, 32.31%, 12.24%, 11.22% and 4.08%, respectively, in the organs of *O. niloticus*.

The results of microscopic examination of squash preparations taken from liver, kidney, spleen, muscles, ovary and intestine of naturally diseased freshwater fishes revealed the presence of resting spores with different developmental stages of end spores (uni-,bi- and multinucleated spores) and hyphae. The fungal elements may replace the tissues of the infected organs forming glaucomatous lesions which were characteristic to Ichthyophonosis. These results were similar to those obtained by

McVicar (1982), Shaheen and Easa (1996), Manal *et al.* (1996), Ziedan (1999) and Manal (2002). *I. hoferi* occurred in the tissues of infected fish as spherical, thick-walled and multinucleate cell. This cell has been named variously by many authors as resting spore (Neish and Hughes, 1980), or large spherical bodies, large multinucleate bodies and spherical hyphal bodies by MEM (McVicar, 1982).

The results of temperature treatment on the survival of *I. hoferi* revealed that, even at a temperature of 4°C, the organism can still survive. The viability of the cultures was gradually diminished from 4°C to 0°C (Table 3). This result is in agreement with McVicar (1982), who recorded that *I. hoferi* can still live at 0°C and being destroyed at -20°C.

Macroscopical examination of effect of different pH on *I. hoferi* growth, through inoculated bottle in MEM-10 media from freshwater diseased fishes revealed abundant characteristic hyphal growth into the substrate of the medium within 10-15 days at pH 5.0. The hyphal growth was abundant and fast at pH 3.0 and 5.0 more than that at pH 7.0 and pH 9.0. These results were similar to those reported by Faisal *et al.* (1985), Okamoto *et al.* (1987), Shaheen and Easa (1996), Ziedan (1999), Manal (2002) and Nahla and Nashwa (2003).

Macroscopical examination of the inoculated sabouraud's dextrose agar plate from freshwater diseased fishes revealed that, growing culture appeared as white hyphal growth with different levels both on the surface and into the substrate of the media. The hyphal growth increased to fill the plates within 10-15 days post-inoculation. These results were similar to those described by McVicar (1982), Ziedan (1999) and Manal (2002).

Microscopic examination of the wet preparation at pH 5.0 from *I. hoferi* culture isolated from freshwater fishes showed continuous germination, and there was a relation between the times elapsed after culturing and the growth performance of the *I. hoferi*. The hyphae started to grow rapidly, extensive hyphal growth with many branches were noticed after one day (Fig. 4a). The characteristic evacuated non-septated hyphal branches with budding ends and their cytoplasm migrating to the apex of the hypha appeared after few days post inoculation (Fig. 4b). The hyphal tips started to be rounded up forming spherical hyphal terminal bodies after one week. Finally, almost all hyphal tips had rounded up forming spherical hyphal terminal bodies after 10 days. Thick-walled spherical multinucleated bodies completely formed and started to separate from the hypha till complete separation after 14 days or more (Fig. 5). The-thick walled spherical multinucleated bodies were ruptured and released their content of endospores (Fig. 6 a,b). All developments of hyphae at pH 5.0 were the same at pH 3.0. These results were similar to those reported by Faisal *et al.* (1985),

Okamoto *et al.* (1987), Shaheen and Easa (1996), Ziedan (1999), Manal (2002) and Nahla and Nashwa (2003).

Microscopic examination of the wet preparation at pH 7.0 from *I. hoferi* culture showed scanty growth of hyphae of the fungus with different sizes with keel formation and budding ends (Fig. 7a). Spherical multinucleated terminal bodies were completely formed and separated from the hyphae. Thereafter, the multinucleated bodies of varying sizes with many nuclei were ruptured and released the endospores (Fig. 7b). These results came in agreement with those described by Millero and Sohn (1992). Spanggaard *et al.* (1994) and Manal (2002) found that germination and growth of fungus require low pH, and that can only be induced in the stomach. *Ichthyophonus* can be considered a dimorphic fungus having a mold form at pH 3 and 5, and spheric form at pH 7 as multinucleated spherical thick-walled cysts. These results give us information about the fungus life cycle, as the infection mainly occurs via ingestion of spores either from infected dead fish or infected copepods which germinate to mold form in the fish stomach of low pH. This may explain the method of infection and penetration of the organism to find its way to the blood to reach the specific organs at neutral pH, where it developed to give all stages of its life cycle. Finally, it formed multinucleated bodies or resting spores. These findings are similar to those reported by Spanggaard *et al.* (1994), Spanggaard *et al.* (1995) and Manal (2002). The authors added that another possibility is that the fungus in the fillet with low pH and by action of hydrolytic enzymes, creates its own environment where germination can occur.

Microscopic examination at pH 5.0 culture isolated from freshwater fishes revealed presence of diverse shapes of the spherical multinucleated hyphal terminal bodies (Fig. 8a). This shape was observed only by Okamoto *et al.* (1985) in TGC-1 when the bodies were transferred from TGC-1 to MEM-10 (pH 7.0) (Fig. 8b). As observed in this study that any difference found, such as type of hyphal growth, morphological changes and diversity in the life history, may reflect the available nutrients and physical conditions such as pH surrounding *I. hoferi* (Okamoto *et al.* 1985).

Table 1. Prevalence of Ichthyophonosis among the examined freshwater fishes.

Location	Fish	No. of exam.	No. of infect	% of infect
Nile River	Carangidae ( <i>Caranx Spp.</i> )	60	24	40%
Nile River	Nile catfish ( <i>Clarias gariepinus</i> )	120	84	70%
Ismailia Nile branch	Wild freshwater Tilapia ( <i>O. niloticus</i> )	60	24	40%
El-Waffa farm	Cultured Freshwater Tilapia ( <i>O. niloticus</i> )	60	48	80%
	Total	300	180	60%

Table 2. Seasonal prevalence of Ichthyophonosis among the examined freshwater fishes.

Season	No. of examined	No. of infected	infection% of
Winter	80	55	68.75
Spring	60	33	55
Summer	70	32	45.7
Autumn	90	60	66.6
Total	300	180	60

Table 3. Effect of temperature treatment on the viability of *I. hoferi*.

Fish	No. of positive cultures/No. of cultures at different fish samples	
	4°C	0°C
Freshwater fish ( <i>O. niloticus</i> )	5 / 4	5 / 2

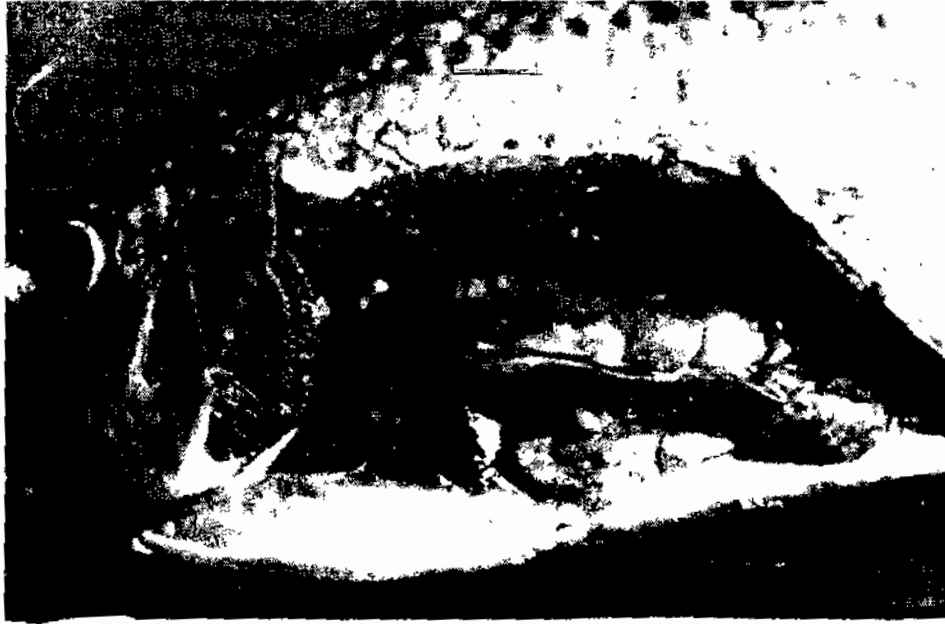

Fig 1. Nile tilapia, *O. niloticus* heavily infected with Ichthyophonosis showing enlarged liver with greyish white nodules of variable sizes in the liver

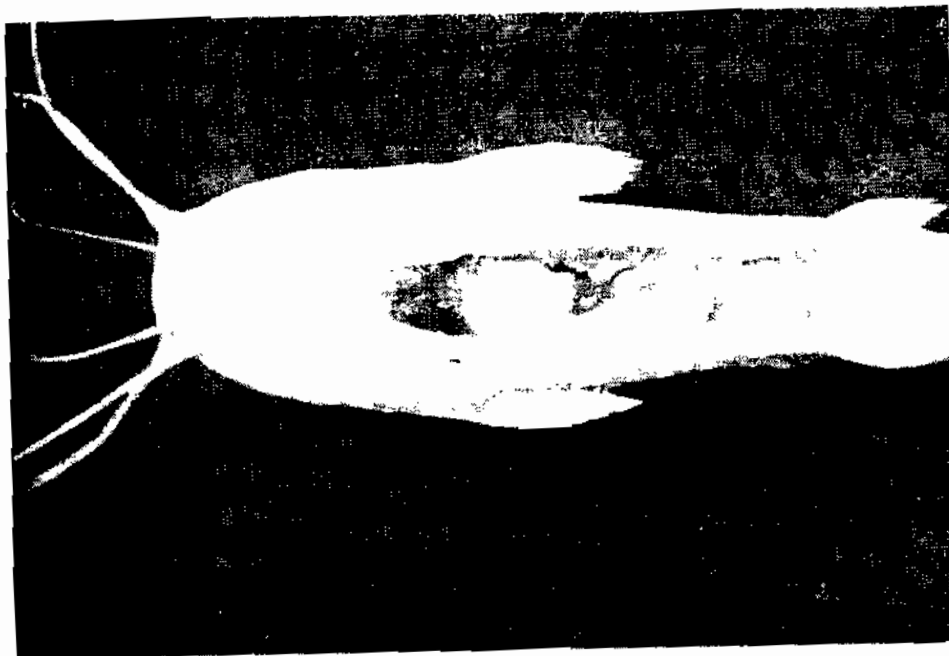


Fig 2. Nile Catfish, *Clarias gariepinus* infected with *I. hoferi* showing congested spleen with white nodules of variable sizes

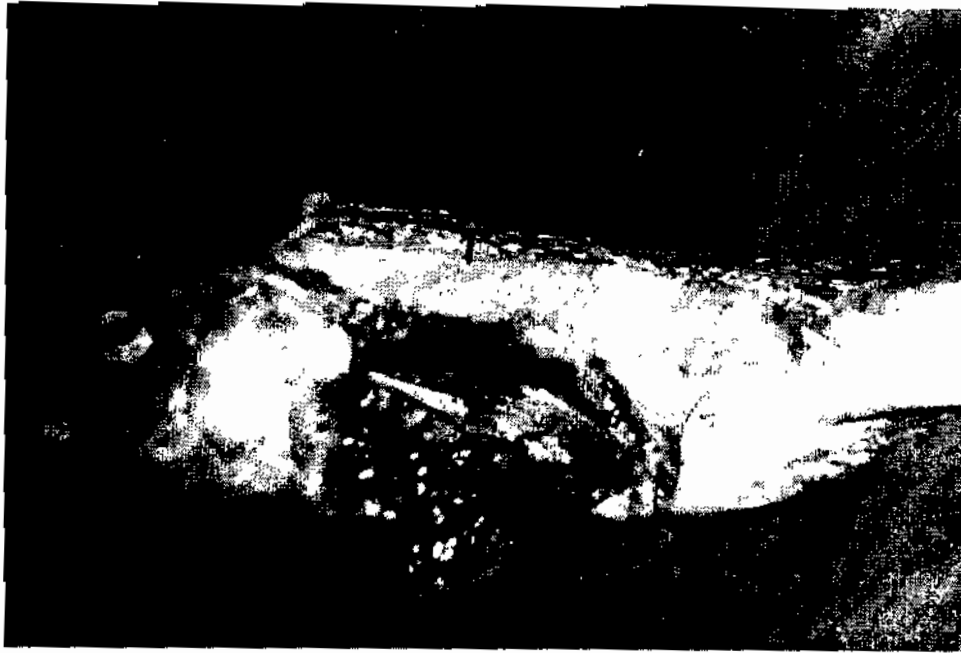

Fig. 3. Nile Tilapia, *O. niloticus* infected with *I. hoferi* showing spiral curvature (scoliosis and lordiosis)

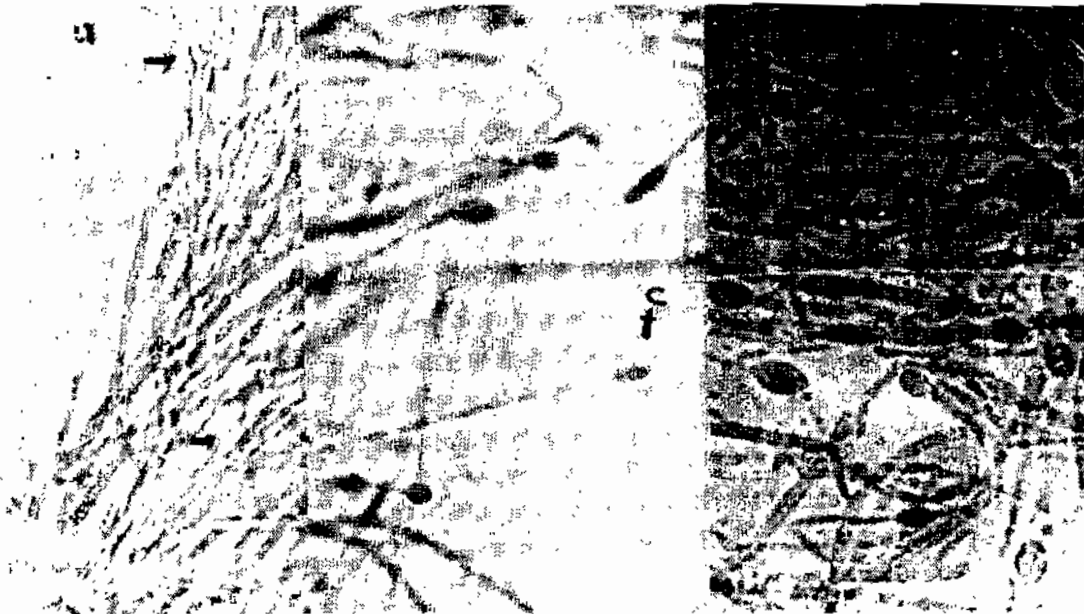


Fig. 4. culture of *I. hoferi* on MEM- 10 at pH5 showing starting of hyphal growth and many branches of non- septate hyphae (a) (x125), cytoplasm migrating to the apex of the hypha (b) , development process of spherical multinucleate hyphae terminal bodies(c). L.C.p.B. stain(x200)

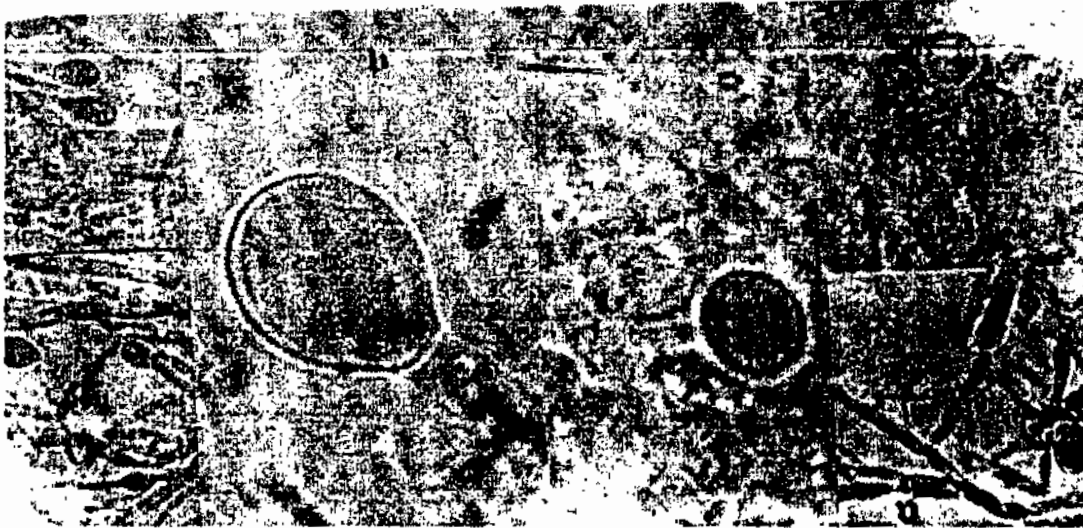


Fig. 5. Growth of *I. hoferi* at pH 5 hyphal tips forming thick walled terminal bodies (a) x800, separated thick-walled spherical terminal bodies after 14 days (b) x500, L.C.P.B. stain

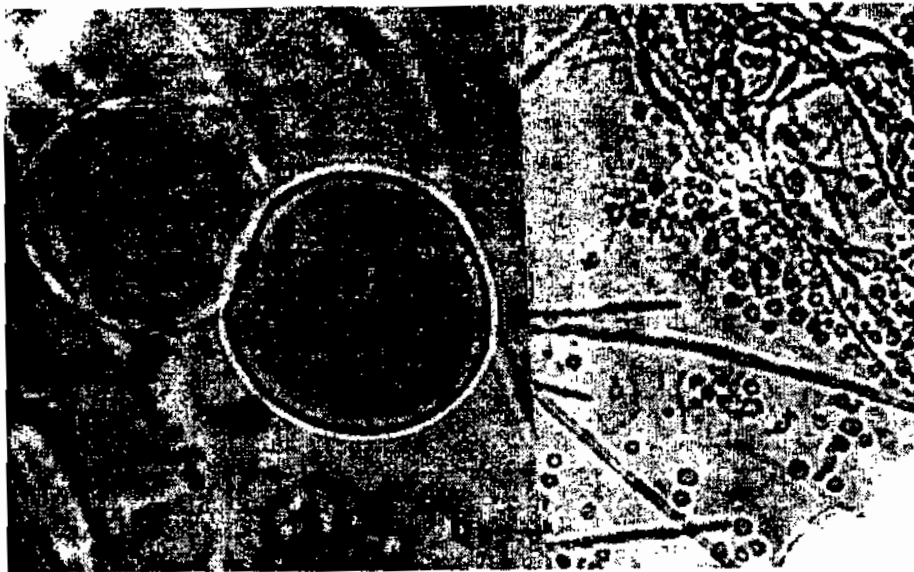


Fig .6. separated thick-walled spherical terminal bodies in cultured of *I. hoferi* at pH 5(a)x 1000, rupture of multinucleate bodies and release of endospores(b)




Fig. 7. culture of *I. hoferi* on MEM-10 at pH 7 showing scanty hyphal growth with budding ends (a) x125, complete separation of thick-walled terminal bodies (b)x 200.




Fig. 8. culture of *I. hoferi* on MEM-10 at pH 5 showing diverse shapes of the spherical multinucleate hyphal terminal bodies (a) (x400) L.C.P.B., diverse shapes of the spherical multinucleate hyphal terminal bodies after germination (Okamoto *et al.*, 1985) (b) .x270.

## REFERENCES

1. Athanassopoulou, F. 1992. Ichthyophoniasis in sea bream, *Sparus aurata* (L.), and rainbow Trout, *Oncorhynchus mykiss* (Walbaum), from Greece. J. Fish Dis., 15:15, 437-441.
2. Faisal, M., H. Torkey and H. H. Reichenbach-Klinike. 1985. A note on swinging disease among the labyrinth catfish (*Clarias lazera* C&V.). J. Egypt Vet. Med. Assn. 45(1) : 53-60.
3. Kocan R., P. Hershberger and J. Winton. 2004. Ichthyophoniasis an emerging disease of Chinook salmon, *Oncorhynchus tshawytscha* in the Yukon River. J. Aquatic Anim. Hlth., 16, 58-72.
4. Kocan R., S. Lapetra, J. Gregg, J. Winton and P. Hershberger. 2006. Ichthyophonus-induced cardiac damage: a mechanism for reduced swimming stamina in salmonids. J. Fish Dis., 29, 521-527.
5. Manal, E. M. Hefny. 2002. Ichthyophoniasis in freshwater fish (*Oreochromis niloticus*). Thesis, M. V. Sc., Zagazig University (Benha Branch).
6. Manal, A. A. Essa, Nahla R. H. El-Khatib and M. El. S. Easa. 1996. Some epizootiological aspects of Ichthyophonosis in freshwater fish from Egypt. 7 Sci. Con.-Fac. Vet. Med., Assuit, Egypt.
7. McVicar. A. H. 1982. Ichthyophonus infections of fish. Microbial Diseases of Fish. Ed. By R. J. Roberts. Academic Press, New York, PP. 243-269.
8. Millero, F. J. and M. L. Sohn. 1992. Chemical Oceanography. PP. 301 Florida: CRC press.
9. Nahla, R. H. El-Khatib and Nashwa S. Elias. 2003. Comparative fecundity estimation of cultured female fishes with myxosporean and fungal infections. Egypt J. Aquat. Biol. & Fish., 7 (4) : 141-156.
10. Nahla, R. H. El-Khatib, Mona M. Husien and Nariman A. Rahim. 1997. Studies on Ichthyophonosis in aquarium fish. Vet. Med. J. Giza, 45(2): 235-250.
11. Neish, G. A. and G. C. Hughes. 1980. Ichthyophonus : Diseases of Fishes. Book 6: Fungal diseases of Fishes. S. J. Snieszko & H. R. Axelod, Eds. New Jersey, T.F.H. Publications. PP. 61-100.
12. Okamoto, N., K. Nakase, H. Suzuki, Y. Nakai, K. Fujii and T. Sano. 1985. Life history and morphology of *Ichthyophonus hoferi* in-vitro. Fish Path., 20 (213): 273-285.
13. Okamoto, N., H. Suzuki, K. Nakase and T. Sano. 1987. Experimental oral infection of rainbow trout with spherical bodies of *Ichthyophonus hoferi*. Bull. Jap. Sci. Fish Nissuishi, 53 (3) : 407-409.

14. Plehn and K. Mulsow. 1911. Der erreger der Taumelkrankheit der Salmoniden. Zentralblatt für Bakteriologie, Parasitenkunde. Infektiöse Krankheiten und Hygiene 59, 63-68.
15. Shaheen, A. A. and M. el-S. Easa. 1996. Preliminary investigation on infection with *Ichthyophonus hoferi* in tilapia species. J. Comp. Path & Clin. Path., 9, (1): 215-222.
16. Sitja-Bobadilla, A. and P. Alvarez-Pellitero. 1990. First report of Ichthyophonus disease in wild and cultured sea bass *dicentrarchus labrax* from the Spanish Mediterranean area. Dis. Aquat. Org., 8 (2): 145-150.
17. Spanggaard B., N. Gram Okamoto and H. H. Huss. 1994. Growth of the fish pathogenic fungus, *Ichthyophonus hoferi* measured by conductivity and microscopy. J. fish. Dis., 17 (2) : 145-153.
18. Spanggaard, B., H. H. Huss and J. Bresciani. 1995. Morphology of *Ichthyophonus hoferi* assessed by light and scanning electron microscopy. J. Fish Dis., 18: 567-577.
19. Tierney K. B. and A. P. Farrell. 2004. The relationships between fish health, metabolic rate, swimming performance and recovery in return-run sockeye salmon, *Oncorhynchus nerka* (Walbaum). J. Fish Dis. 27 : 663-671.
20. Ziedan, A. H. H. 1999. Comparative study between hormonal effect and hybridization on the susceptibility of tilapia to infection with *Ichthyophonus hoferi* fungus. Thesis, M. V. Sc. Fac. Vet. Med., Cairo University.

## تأثير الحرارة البيئية على فطر الإكثيوفونوس هوفرى المعزول من أسماك المياه العذبة

أحمد فكرى بدران<sup>١</sup> ، منى مصطفى حسين<sup>٢</sup> ، سعاد صبرى سلامة<sup>٢</sup>

١. كلية الطب البيطري-جامعة قناة السويس

٢. معهد بحوث صحة الحيوان- مركز البحوث الزراعية-وزارة الزراعة-الدقى-جيزة

تبين من فحص عدد ٣٠٠ سمكة من أسماك المياه العذبة ان عدد ١٨٠ سمكة كانت موجبة لعزل فطر الاكثيوفونوس هوفرى بنسبة ٦٠% من نهر النيل وترعة الاسماعيلية ومزرعة الوفا. وكانت اعلى نسبة اصابة فى فصل الشتاء (٦٨,٧%) وأقل نسبة اصابة فى الصيف (٤٥,٧%). وقد وجد من الفحص الظاهرى ان الاعراض المرضية هى وجود اللون الاسود فى جلد الاسماك مع جحوظ وعتامة فى العينين وتشوهات فى العظام والرأس. وأوضحت الصفة التشريحية للأسماك المصابة وجود حويصلات بيضاء مختلفة الحجم فى الكبد والكلى والقلب والطحال والأمعاء مع وجود أنزفة والتهاب على سطح هذه الأعضاء وتموجات بالأمعاء. تم عزل فطر الإكثيوفونوس هوفرى المسبب لهذا المرض على بيئة السبارود ديكستروز +١% مصل صغار الأبقار و على بيئة الميم +١٠% (ميم-١٠) مصل جنين الأبقار من الاعضاء المصابة الغنية بالدم عند الأس الهيدروجينى (٣-٥-٧-٩) وكان نموه اسرع واكثر ومميز عند الأس الهيدروجينى ٣-٥ عن نموه عند الأس الهيدروجينى ٧-٩. كما وجد ان تحضين الفطر عند درجات مختلفة نقل القدرة على النمو تدريجيا من ٤ درجة مئوية حتى صفر درجة مئوية.