

CHRONIC AND ACUTE NATURAL SHEEP ORF INFECTION : COMPARATIVE CLINICO-PATHOLOGICAL OBSERVATIONS

F.M.T. HOUSAWI

College of Vet. Med. and Animal Resources
King Faisal Uni., P.O. Box 55011, Al-Hasa, 31982, Saudi Arabia

Received: 14. 2. 2008

Accepted: 4. 3. 2008

SUMMARY

This study involved clinico-pathological comparison of natural chronic and acute forms of orf virus infection which took place in a flock of sheep. Clinically, lesions in the acute orf took 5-6 weeks to heal, while healing in the chronic form took more than six months. Significant differences were observed on the histopathological lesions of both forms of the disease. Grossly, the scabs on the acute disease could be removed easily. However, in the chronic form they were strongly adherent to the skin and when forcibly removed they caused bleeding. Comparative discussion of both conditions was undertaken.

Key words: Natural Sheep orf Acute and Chronic Infection - Clinico-pathological Observations.

INTRODUCTION

Natural or experimental infection with Orf virus usually takes an acute form of the disease, which coalesces in 5-6 weeks after which the animal returns normal (Robinson and Balassu 1981). However, under certain conditions, orf infection can take a chronic pathway (Abuelzein and Housawi ., 1997), which could extend for six months or more.

In an orf outbreak in sheep, at Al-Ahsa oasis of eastern Saudi Arabia, both forms were seen. The clinico-pathological responses of both forms of the disease were compared and the results were discussed.

MATERIALS AND METHODS

In June, 1999 a flock of 160 mixed Refady sheep breed and Naimi breed which were kept in a

farm, at Al-Ahsa oasis of eastern Saudi Arabia, was hit by orf infection. The management and hygienic conditions in the farm were poor. The morbidity rate was 4.4%, while the case fatality rate was 4.6%. Both young and adult sheep were involved in this study.

In all affected sheep, the disease started as an acute form involving the skin around the lips, taking the usual stages of orf infection, i.e., erythema, papule, pustule and scab. The whole span of infection took 5-6 weeks. The orf lesions, in 4.2% of the affected sheep (1.4% of the adults, and 2.8% of the lambs) did not heal but spread to other parts of the body. Lesions were seen on mouth, udder, and tail which continued for more than six months.

Skin biopsy samples were separately collected from the scab lesions of the affected sheep with acute and chronic forms. A portion from each sample was placed in a sterile container, in an ice container for virus isolation. The other samples were placed in 10% formal saline. Paraffin sections 4-6 mn thick were prepared, stained with haematoxylin and eosin (H&E) and examined under the light microscope.

Suspected orf scabs were ground and made into a 10% suspension in sterile phosphate buffered saline (PS) pH 7.4; the suspensions were then clarified and treated with antibiotics (Romero et al., 1973). The 10% suspensions were used for virus

isolation by inoculating cell cultures of Vero and the viruses were titrated in cell cultures as described by (Plowright et al., 1959).

To identify the cell culture isolated viruses, the SNT of (Trueblood et al., 1963) was used employing a microtitre system.

The scab materials used in the AGID were made in a 50% suspension in PBS pH 7.4. The test was as described by (Sawhney et al., 1973). A rabbit anti orf hyperimmune serum (4) was included in the test.

RESULTS

A cytopathic effect (CPE) was observed on the inoculated Vero cell culture monolayers by day four post inoculation. The CPE was characterized by cell rounding, which progressed to cover more than 90% of the cell monolayers within 7 days. At that stage, the cell culture was harvested and stored at -860C until used. Two further passages were performed and the virus titre was log 104.0 for the virus from the acutely affected sheep and log 102.5 from the chronically affected.

The scab materials from the acute orf cases gave complete line of identity against the rabbit anti orf virus hyperimmune serum; while the skin samples from the chronically affected sheep didn't give any line against the hyperimmune serum.

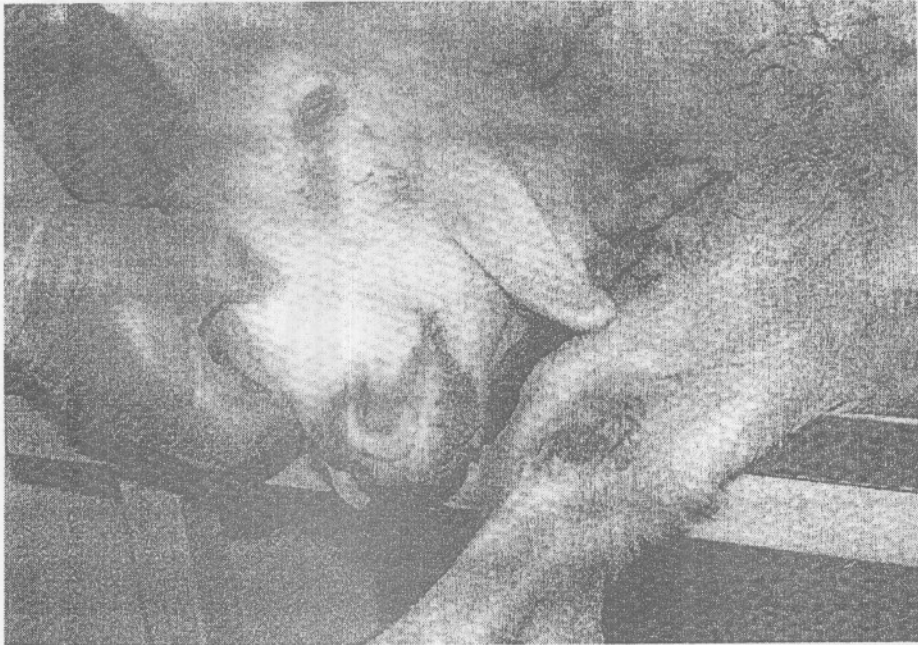

Fig. (1): Chronic Orf lesions around mouth, nostril and knee of affected sheep.

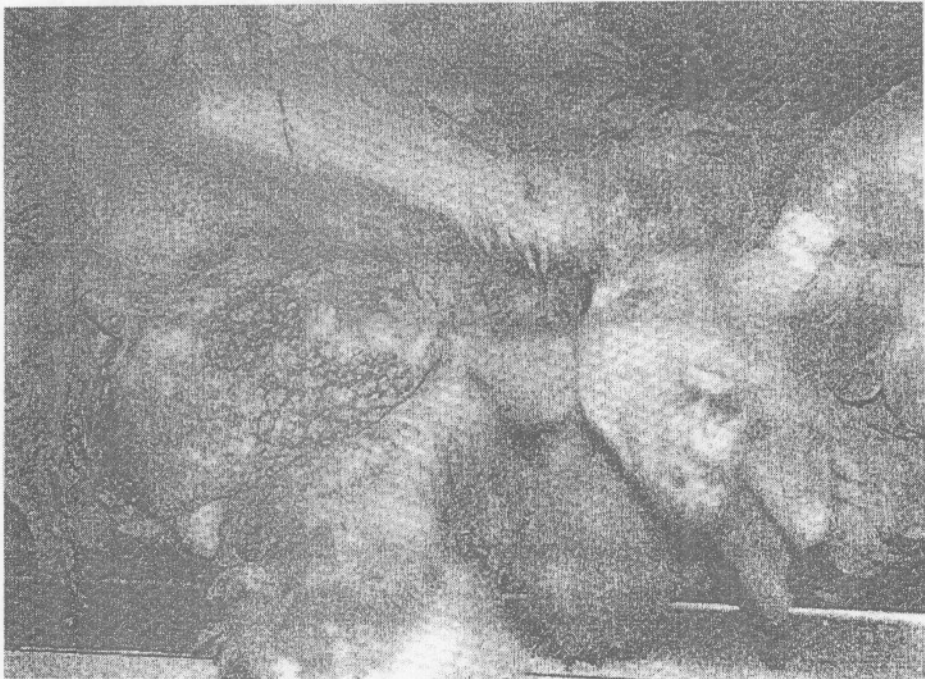

Fig. (2): Chronic scab lesions on the udder and coronary band of affected ewe.

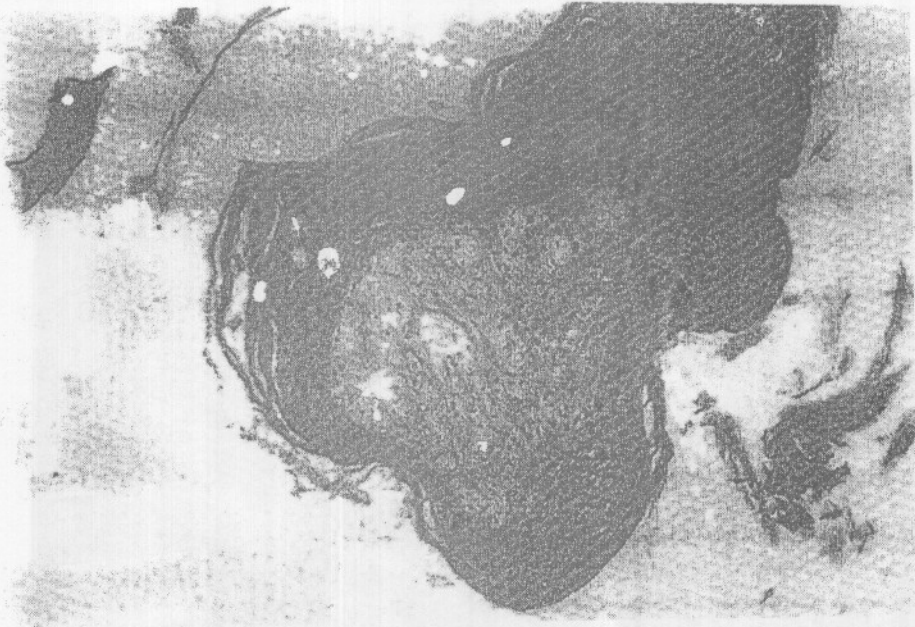

Fig. (3): Keratinized tissue surrounding degenerating epithelial cells
 (H&E = 100x)




Fig. (4): Keratinized tissue with entrapped degenerating neutrophils
 (H&E = 100x)




Fig. (5): Thick keratin layer (H&E=100).




Fig. (6): Keratinized tissue surrounding degenerating epidermal cells (H&E=100).

Both viruses isolated from the acute orf cases and the chronic cases were neutralized by the anti orf hyperimmune serum.

Control non-immune sheep serum gave negative results against the viruses in both the SNT and the AGID tests.

The histopathological examination of the lesions from the acute orf cases showed pseudo-epitheliomatous hyperplasia; epidermal cell vacuulations and necrosis with infiltration of neutrophils; acanthosis, hyperkeratosis with appearance of bacterial colonies; perivascular mononuclear cell infiltration in dermis and deeper tissue. (Fig. 7,10). Eosinophilic round bodies, resembling inclusion bodies, were occasionally seen in the cytoplasm of epidermal cells.

The picture of the histopathological examination of the chronic orf lesions, showed very thick keratinized tissue with islands of necrotic epithelial cells and connective tissue and of disintegrated neutrophils and pieces of hair (Fig. 5.6), which could denote a thick scab tissue. Interrupted areas of keratinized tissue, entrapping epithelial cells and hair follicles, were seen (Fig. 3.4). Chronic scab lesions on the udder and coronary band of affected Ewe were seen in (Fig. 2), while Chronic Orf lesions around mouth, nostril and knee of affected Awassi sheep were observed (Fig. 1).

DISCUSSION

Results in the present study, confirmed that orf virus was isolated and identified from both the acute and chronic cases using the SNT. However, the AGID, with its inherent low sensitivity, could detect orf virus antigen in lesions from the acute cases only. On the other hand, the titre of the virus isolated from the acute cases was double that from the chronic ones. This situation showed that the chronic lesions contained low titre virus. The explanation for this could be that, in the case of the acute infection, the orf virus was present in high titres in the scabs, while in the chronic cases, the lesions were not actually orf scabs but were rather due to complications by the granulomatous situation brought about by the hypersensitivity reaction during the long term involvement of the skin tissues.

The gross pathological picture showed great differences between the two conditions. The lesions in the acute form were confined to the area around the mouth, as usually seen in classical orf clinical cases, and the scabs dropped after six weeks leaving healed skin. In the chronic form, the lesions spread to other parts of the body and persisted for over six months. The lesions were strongly adherent to the skin and were not easy to remove like in case of the acute orf form. However, when forcibly removed, lead to bleeding.

There was also difference in the histopathological

picture between the two disease forms. The picture of the acute form, was typical of the classical orf lesions as reported by various authors Housawi et al., 1993. and Gameel et al.,1995. While the picture of the chronic form lesions denoted a chronic nature of the lesions, characterized by a very thick layer of keratinized tissue with islands of necrotic epithelial cells and connective tissue. Chronic orf usually occurs in small percentage of the affected herd. The reasons for the development of this clinical form were not clear. However, authors suggested that this orf form could be to individual susceptibility factors. In the present outbreak the chronically affected animals were weak and malfed. This could have attributed to the development of this chronic orf form.

ACKNOWLEDGEMENTS

The author would like to thank Prof. Ahmed Gameel for kind effort and advice regarding the histopathological figures and Prof. EL-tayb Abu ELzein for valuable discussion.

REFERENCES

Abuelzein E. M. E., Housawi F. M. T., (1997): Severe long lasting contagious ecthyma infection in goat's kid. *J. Vet. Med B.*, 44:461 ñ 464.

Concha-bermejillo A., Guo J., Zhang Z., Waldron D., (2003): Severe persistent orf in young goats. *J. Vet. Diagn. Invest.* 15 : 423-431.

Gameel a. A., abuelzein e. M. E., housawi f. M. T., agiba., ibrahim a. O., (1995): Clinicopathological observations on naturally occurring contagious ecthyma in lambs in Saudi Arabia. *Revue Elev. Med. Vet. Pays Trop.* 48 (3) : 233-235.

Housawi F.m.t., Abuelzein E.m.e., Gameel A. A., Alafaleq A. I., (1993): A close comparative study on the response of sheep and goats to experimental orf infection. *J.Vet.Med. B.*, 40 : 272-282.

Plowright W., Whitcomb M. A., Ferris., R.d., (1959): Studies with a strain contagious pustular dermatitis virus in tissue culture. *Arch. Ges. Virusforsch.*, 9 : 214-231.

Robinson A.j.,and Balassu T.c., (1981) : Contagious pustular dermatitis (orf). *Vet. Bull.*, 51 : 771-782.

Romero-mercado C.h., Mcpherson E.a., Laing A.h., Lawson J.b., Scott G.r., (1973): Virus particles and antigens in experimental orf scabs. *Arch. ges. Virusforsch.*, 40 : 152-158.

Sawhney A.n., Dubey S.c., Malik B.s., (1973): Diagnosis of contagious pustular dermatitis in sheep and goats by agar-gel precipitation test. *Indian Vet. J.*, 50 : 605-607.

Trueblood M.s., Chow T.l., Griner L.a., (1963): An immunologic study of ulcerative dermatitis and contagious ecthyma . *Am. J. Vet. Res.*, 24 : 42-46.

الشكل الحاد والمزمن لعدوى الأورف الطبيعية في الأغنام: ملاحظات إكلينيكية وباثولوجية مقارنة

ف. م. ت. هوساوي

كلية الطب البيطري والوارد الحيوانية

جامعة الملك فيصل ي ب: ٥٥.١١ الحساء ٣١٩٨٢١١ - المملكة العربية السعودية

اشتملت الدراسة على مقارنة إكلينيكية وباثولوجية لحالات لمرض الأورف الذي أخذ شكلا حادا ومزمن في قطيع من الأغنام. وقد تم تأكيد المرض بعزل المسبب علي خلايا الزرع النسيجي وعمل اختبار التعادل المصلي للفيروس المعزول. استغرق المرض حوالي ٥-٦ أسابيع لتتمام الشفاء في الشكل الحاد. على الوجه الأخر استغرق المرض أكثر من ٦ شهور لتتمام الشفاء في الشكل المزمن. أوضحت الدراسات الباثولوجية فروق معنوية بين الأشكال الحادة و المزمنة للمرض. بالفحص العيني يمكن إزالة القشرة بسهولة في الشكل الحاد بينما تكون هذه القشرة ملتصقة بالجلد و لا يمكن إزالتها و عند إزالتها بقوة فأنها تترك سطح نزفي شديد. تشمل الدراسة مناقشة دقيقة للشكلين الإكلينيكيين للمرض في قطيع من الأغنام.