

## **SCROTAL URETHROSTOMY FOR STRANGULATED PARAPHIMOSIS IN A DOG**

**M. M.SHOKRY\* and L. M. BEN ALI\*\***

\*Surgery, Anaesthesiology & Radiology Dept. ,Faculty of Vet.Medicine Cairo Uni., Giza, Egypt

\*\*Surgery Dept., Faculty of Vet.Medicine, AlFateh Uni.,Tribol

**Received:** 21. 6. 2008

**Accepted:** 23. 6. 2008

### **SUMMARY**

A 7-year-old male Griffon was presented for penile necrosis subsequent to strangulated paraphimosis. Scrotal urethrostomy combined with subtotal penile amputation, preputial ablation and castration was performed as a salvage treatment. The surgical procedure was described and discussed.

---

### **INTRODUCTION**

Acquired or congenital phimosis and paraphimosis are among preputial and penile deformities which cause urinary dysfunctions, failure of successful breeding or both (Smith ,1990 and Boothe, 1993). Paraphimosis occurs when the penis cannot be retracted back into the preputial cavity. It is more common and potentially more serious than phimosis (Ndiritu,1979). Surgical re-

pair or reconstruction through emergency urethrotomy and urethrostomy to relieve a urethral obstruction and resume the patency of urine flow (Dean et al, 1990). The purpose of this report was to describe the signalment, clinical findings and surgical procedure for urinary diversion of a male dog subjected to accidental penile injury.

### **CASE DESCRIPTION**

A 7-year-old male Griffon was presented to the veterinary surgery clinic of Al-Fateh University for assessment of penile trauma since 3 weeks. The owner admitted that he attempted to forcibly separate the locking of his dog from the partner during mating. He noticed lately difficult and bloody urination. On clinical examination, the dog looked misery, thin , feverish (40°C) and reluctant to move. Close inspection of the penis revealed swollen bulbus glandis and blackish color necrotic exposed os penis (Fig. 1). CBS and some

vital serum biochemical values showed mild changes.

A diagnosis of penile necrosis subsequent to strangulation paraphimosis was made.

Scrotal urethrostomy combined with subtotal penile amputation, preputial ablation and castration was indicated as a salvage treatment. The owner accepted the salvage treatment.

The dog was premedicated with atropine sulfate (0.04 mg/kg bw, SC), acepromazine (0.05 mg/kg bw, IM). Anaesthesia was induced with thiopental sodium (10.00 mg/kg bw, IV) and maintained with halothane after intubation. The dog was placed in dorsal recumbency and ventral abdomen and prepuce were aseptically prepared for surgery. Preoperative systemic antibiotic therapy of cefotriaxone (20.0 mg/kg bw, IM) was given and continued every 12 hours for 5 days post-operatively. Lactated Ringer's solution was infused at a rate of 5 ml/kg bw/h during the surgery.

## **SURGICAL PROCEDURE**

Ventral midline elliptical skin incision was made around the prepuce and partially the scrotum. The spermatic cord of each testicle was released from the scrotum and ligated (Fig. 2). A tourniquet was placed around the penis proximal to the bulbus glandis. The penis was then amputated just distal

to the tourniquet and proximal to the os penis. The tourniquet was carefully released to manage any bleeding from the penile stump. The tunica albuginea of the penile stump was sutured over the cavernous tissue by 2 mattress stitches using polyglactin 910 (Vicryl, Ethicon) 4-0. Scrotal urethrostomy was then induced after making a 3 cm ventral midline incision into the scrotal urethra of the penile stump after retraction of the retractor penis muscle. The dead space surrounding the penile stump was closed by suturing the penile tunica albuginea with the adjacent subcutaneous tissue with simple interrupted suture of Vicryl 4-0. The induced urethral opening was kept open by suturing the urethral mucosa with the skin by simple interrupted suture of Vicryl 4-0. The cut edges of the urethra were sutured to the skin with single interrupted suture of Vicryl 4-0. The remaining skin openings were closed to retain the distal end of the amputated penis under the skin using silk 4-0. A sterile urinary catheter was inserted and secured in the urethra with a suture loop to the skin of the abdomen.

Post-operative care comprised the application of special collar to prevent self trauma and continued antibiotic administration for 5 days as prescribed. The urine output was monitored for 24 hours P.O. to assess the patency of the urethra and the state of urine. Fluid therapy was continued after surgery until the dog's appetite regained normality. The urinary catheter was removed after 24 hours and the dog urinate through the urethrostomy.

my orifice without difficulty. Trivial amount of blood was noticed after removal of the catheter. The urethrostomy orifice was flushed with sterile normal saline for one week P.O. The dog's appetite was regained 24 hours P.O. Skin stitches were removed after 7 days and follow up was continued for 6 months without any complications ( Fig.3).

## DISCUSSION

In the present report, scrotal urethrostomy was the procedure of choice since subtotal penile amputation, preputial ablation and castration were mandatory. In this respect, scrotal urethrostomy has several advantages over prescrotal, prepubic , or perineal urethrostomy. The membranous urethra in the region of the scrotum is larger and more distensible than the prescrotal or perineal urethra. This reduces the risk of stricture formation and allows easier calculus passage after urethrostomy. Also, the urethra in the scrotal area is more superficial and surrounded by less cavernous tissue than it is in the perineal region. Furthermore, surgical exposure is easier and the risk of hemorrhage or urine extravasation into periurethral tissues is reduced. Scrotal urethrostomy

diverts urine directly downward and away from perineal skin which is kept dry. This reduces the possibility of occurrence of intractable dermatitis from urine scalding (Leighton,1976; Srneak, 2000; Boothe,1993; Fossum,2003). Performing scrotal urethrostomy, surgical repair was uneventful and the dog was doing quite well during 6 months follow up.

## CONCLUSION

Forcible or constrained attempts to untie the locking of dog partners during mating may end dramatically so that penile necrosis from strangulated necrosis may ensue. The peculiar anatomy of the dog's penis which has the bulbus glandis entirely surrounding the proximal end of the glans in which embedded the os penis. On erection, the bulbus glandis (the most distensible part of the penis) extremely increases in size , owing to its role in forming the "tie" or "lock" characteristic of canine copulation (Johnston and Archibald, 1974).

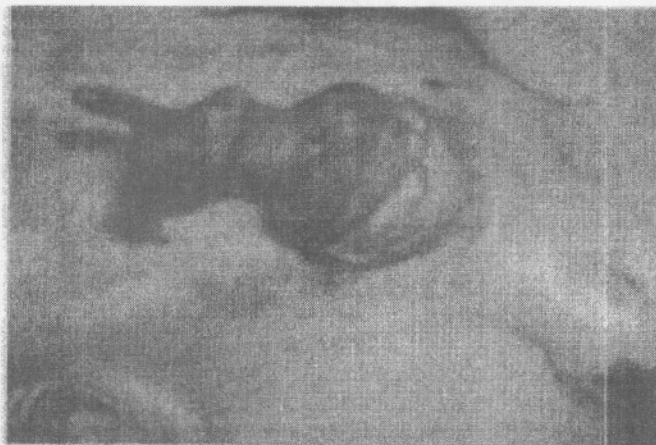

Figure 1- Photograph of the paraphimosed penis with necrosis of the os penis. Note the swollen bulbos glandis

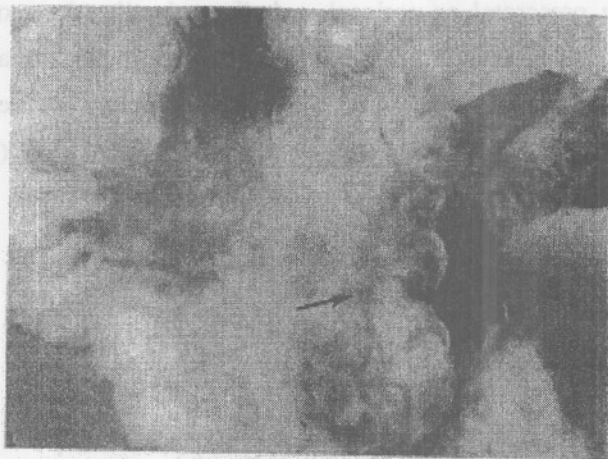


Figure 2- Photograph of the scrotal urethrostomy orifice one-month P.O. (black arrow)

## REFERENCES

- Boothe H.W. (1993) : Penis, prepuce and scrotum. In: Slat-  
ter D.H, Textbook of small animal surgery. Philadel-  
phia , WB Saunders, p. 1336-1348.
- Dean P.W., Hedlund C.S., Lewis D.D., et al (1990): Canine  
urethrotomy and urethrostomy. *Comp Contin Ed Pract  
Vet* . 12 ,1541-1554.
- Fossum T.W. (2002): Surgery of the bladder and urethra.  
In: Fossum T.W., *Small Animal Surgery*. 2nd  
ed.,St.Louis , Mosby, p. 585-607
- Johnston J.E.and Archibald J. (1974 ):Penis and prepuce.  
In: Archibald J, *Canine surgery*,2nd ed. Santa Barbara ,  
*Am Vet Pub* , p. 707-717.
- Leighton R.L. (1976): Ablation of the penis and scrotum  
with a urethrostomy in a dog. *J Am Anim Hosp Assoc*;  
12 ,661-663.
- Ndiritu G.C. (1979): Lesions of the canine penis and pre-  
puce. *Mod Vet Pract*; 60 , 712-715.
- Smeak D.D. (2000):Urethrotomy and Urethrostomy in the  
Dog. *Clin Tech in Small Anim Pract*, 15, 25-34.
- Smith M.M.and Gourley I.M. (1990):Preputial reconstruc-  
tion in a dog. *J Am Vet Med Ass* ,196 , 1493-1496.

# أحداث فتحة جراحية دائمة في الاحليل في منطقة الصفن كعلاج لحالة اختناق القضيب الغمدى في كلب

\*محمد مصطفى شكري      \*\*لطفى موسى بن على

\* كلية الطب البيطري - قسم الجراحة والتخدير والأشعة - جامعة القاهرة -  
الجيزة - مصر

\*\* كلية الطب البيطري - قسم الجراحة - جامعة الفتح - طرابلس - ليبيا

في هذا التقرير تم العلاج لحالة غرغرينا القضيب الغمدى لذكر جريفون عمر  
٧ سنوات ناشئ عن انفصال القضيب القسرى أثناء الجماع. وتمثل العلاج  
الجراحي في البتر الجزئي للقضيب مع الإزالة الكلية للغمد بالإضافة إلى  
الخصى مع أحداث فتحة دائمة بالاحليل في منطقة الصفن للتبول من  
خلالها.