

SOME MICROBIAL AND PARASITIC INVESTIGATIONS IN OREOCHROMIS SPECIES IN ELZWAIDA EFFLUENT AT KALUBIA GOVERNORATE

ABD EL-TAWAB, F. GHARIB*, MONA, M. HUSIEN** and SOAD, S. A. SALAMA**

* Giza Provincial Lab., Animal Health Research Inst.

** Fish Diseases Dept, Animal Health Research Inst., Dokki Giza

Received: 2. 11. 2008

Accepted: 27. 11. 2008

SUMMARY

Naturally infected *Oreochromis* species as well as water samples were collected from Elzwaida effluent at Kalubia governorate and examined. The study revealed presences of mixed infection by parasites, bacteria and fungi. 80 % of examined fish were suffered from Trichodiniasis. The involved pathogenic bacterial spp. from examined fish were identified as *Aeromonas hydrophila*, *Flavobacteria* spp. and *Vibrio* species. Also *Ichthyophonus hoferi* was identified in 40% of examined fish.

The clinical signs among examined fish varied according to the severity of infection which was summarized as detached scales, black coloration, superficial ulcers, fin & tail rot and or hemorrhagic signs on body surface. Post-mortem findings varied according to type and severity of infection summarized as hemorrhagic signs in

internal organs with congested blood vessels of intestine and mesentery.

INTRODUCTION

Fish is an essential source of animal protein. A great effort was performed to increase the production of fish to face the continuous increase of human population. Tilapia is the main popular fish species produced in Egypt.

Parasitic infestations, especially ectoparasites from the phylum protozoa are the most dangerous group affecting skin and gills that induces slimness of the skin, irritation, destruction of gills, anorexia and impaired breathing (Snieszko, and Axelord, 1980, Lom, 1995 and Osman, 2001). *Trichodina* spp. being directly transmitted they can easily spread and proliferate when resistance

of the host is decreased (Lom, 1995). External parasite may cause ulceration at the site of attachment to the fish, which may serve as a sight of secondary bacterial or fungal infection as reported by (Woo and Bruno, 1999). *Trichodina* spp. frequently form a problem (Lom and Dykova, 1992) but never occur in public among healthy fish unless the host is weakened by any stress. *Trichodiniasis* causes severe economic loses in various parts of the world (Van As and Bassan, 1987).

Bacterial diseases, particularly those caused by gram negative organisms are the major causes of mortality in both wild and cultured fish (Roberts, 1987). A wide variety of bacteria, normally living in harmony with their fish host (e.g. *Aeromonas hydrophila*) in water or inhabitant of the gastrointestinal tract are harmless to the host. Under certain circumstances (as the effect of crowding, pollution and parasitic infestation, exerting much stress on the fish), thus upsetting the balance between bacteria and its host. These commensal bacteria become secondary opportunistic pathogens and invade fish. *Aeromonas* species are known to be more common associated with disease in freshwater fish (Inglis et al., 1993 and Ruth 2002). *Flavobacterium* spp. were isolated in different occasions from diseased and apparently healthy fish (Toranzo et al. 1985). In Egypt, *Flavobacterium* spp. were isolated from *Oreochromis niloticus* (Husien, 1999) and from Sea bass, *Dicentrarchus Labrax* (Ali, 2007). *Vibriosis* was re-

ported in freshwater fish, its infections can spread rapidly when fish are confined in heavily stocked, commercial systems and morbidity may reach 100% in affected facilities (Peggy and Ruth, 2002).

Ichthyophonosis is a systemic fungal disease caused by the fungus, *Ichthyophonus hoferi*, grows in both fresh and saltwater among wild and cultured fish (Hefiney, 2002 and Badran et al. 2008). The disease is spread by fungal cysts which are released in the feces and by cannibalism of infected fish (Gavryuseva, 2007). *Ichthyophonosis* was reported in freshwater fish in Egypt (Hefiney, 2002 and Salama, 2004).

Aim of work: To study some microbial and parasitic investigations in *Oreochromis* species in Elz-waida effluent at Kalubia governorate.

MATERIALS AND METHOD

Fifty diseased and apparently healthy *Oreochromis* species were collected from Elz-waida effluents water in Kalubia governorate and were transported alive in large plastic bags to the Fish Diseases Department, Animal Health Research Institute Dokki Giza. Fish were subjected to:

- 1- Full clinical and post mortem examination (Schaper-clause, 1992).
- 2- Parasitological examination (Paperna, 1996).
To recognize *Trichodina* spp., smears were

taken from ulcers of infected fish, dried by air, then impregnated with 2% aqueous solution of silver nitrate for 8 minutes followed by rinsing in distilled water, then the slides were placed in white clean dish covered with distilled water and exposed to uv 98 diffused day light for about 2 hours, then slides were dried and examined microscopically. Terminology and method of measured of the components of the adhesive disc followed the uniform specific characteristic system proposed by (Arthur and Lam, 1984). Description of denticles was performed according to (VanAs and Bassan, 1992).

- 3- Bacteriological examination: Swabs taken under aseptic condition from skin lesion and internal organs namely, liver, kidney and spleen were inoculated on tryptic soy broth (Oxoid) at 25°C for 24 hrs then streaked into MacConkey and T.S.A. agar (Oxoid). Selective colonies were re-streaked onto aeromonas base media (Oxoid) and on TCBS media and Ordal's media. Pure colonies were streaked onto soft agar to be used for further studies. Bacterial isolates were identified by colonial morphology, growth characters on specific media and microscopically appearance as well as phenotypic characteristics (Balows et al., 1992; Cowan and Steel, 1993 and Buller, 2004).
- 4- Mycological examination: Squash preparation from internal organs was carried out according to method described by Faisal et al. (1985) to

identify *I. hoferi* in tissues. Samples taken from the internal organs namely, liver, kidney and spleen embedded in Minimum Essential Medium with 10% fetal calf serum (MEM10) at pH 5.0 were incubated at room temperature for 15 days for isolation of the fungus as described by McVicar (1982). The isolated fungus was stained by lactophenol cotton blue according to Spanggaard et al. (1994).

Experimental Design:

1-Experimentally infected fish:

1-1: A total number of 45 apparently healthy *Oreochromis niloticus* fish were collected alive from a private farm were stocked in glass aquaria for three weeks to be acclimatized prior to the experimental infection. Five fish were randomly selected for bacteriological and parasitological examinations to insure that they free from natural infection. 24 fish out of 40 were divided into 4 groups 6 of each (Groups 1, 2, 3 & 4).

1-2: Eight *O. niloticus* fish naturally heavily infested with *Trichodina* spp. (were kindly obtained from Fish Dis. Dept. An. Heal. Res. Inst. Dokki, Giza)

2-Preparation for *Trichodina* spp. infestation: The remained sixteen parasite free *O. niloticus* fish were held with eight *O. niloticus* fish naturally heavily infested with *Trichodina* spp. (were kindly obtained from Fish Dis. Dept. An. Heal. Res. Inst. Dokki, Giza) in 40 liters capacity aerated aquarium at 16-18c for 14 days

during which the clinical manifestation of external parasites in all fish were recorded (Total no.= 24 infested fish). The estimated infestation was determined according to Tojo et al. (1984). Fish divided into 4 groups 6 of each (Groups 5, 6, 7 and 8).

3-Method of bacterial infection: 100 ml of 24 hr old broth culture for each bacteria (*A. hydrophila*, *Flavobacteria* spp. and *Vibrio* spp.) was added separately to an aerated 20-liter aquarium the number of bacteria in immersion medium corresponded to about 2×10^7 colony forming unit (CFU) ml⁻¹ experimentally fish were allow to remain in contact with the culture for 90 min. (Hietale et al., 1995).

Fish was experimentally infected as shown in table (2). Group 1 and 5 experimentally infected with *A. hydrophila*, group 2 and 6 experimentally infected with *Flavobacteria* spp. and group 3 and 7 experimentally infected with *Vibrio* spp. while group 4 and 8 immersed in saline as a control. The experimentally fish groups were continuously investigated throughout one week (experimental period). Clinical signs were observed and mortality rate was recorded. Samples from internal organs of moribund fish were taken aseptically and bacteriologically examined.

RESULTS AND DISCUSSION

Clinical examination of naturally infected Ore-

ochromis species revealed the presence of excessive mucus secretion covering the skin and dark grey coloration or even blackness of the skin. Hemorrhagic spots over the skin were occasionally seen and the eyes appeared cloudy. In addition to that there were easily detached scales with skin ulceration and fin and tail rot. Fig. (1 and 2). While the autopsy of most clinically infected fish revealed the presence of patches of necrosis (yellow coloration) of liver Fig. (3), in some cases it appeared enlarged with presence of hemorrhagic signs. Bloody exudates in abdominal cavity, congestion of kidney and spleen in addition to macroscopic white nodules in liver, kidney and spleen in some fish.

The microscopical examination of fresh skin scrapings or gill clippings revealed presence of *Trichodina* spp. in percentage of 80 %, which are peritrichal ciliated protozoans saucer-shaped, with rows of cilia at either end and a macro and micro nucleus. When viewed dorsoventrally, the parasite appears as an ornate disk with a characteristic ring of interlocking denticles forming a circle in the middle of the organism. The examined fish infested with two species of *Trichodina* which were *Trichodina magna* (VanAS and Bassan, 1989) and *Trichodina centrestigeata* (Bassan et al. 1983). *Trichodina magna* (VanAS and Bassan, 1989) in which body diameter was (50-66 µm), adhesive disc (45-59 µm), denticular ring 26-37 µm, number of denticles 23-28 µm, radialpins / denticle 8-10 µm. It's the largest Tri-

chondinid with disc shaped or saucer-like body surrounded by finely striated border membrane and center of the adhesive disc is limely granulated and dark. Massive denticles and provided with strongly falcated blades and wedge-like rays. The blade is broad with a round apex. The central part of the denticle is broad at the base and tapers to a rounded point in close association with the preceding denticle rays are long and slightly curved anteriorly (Fig.4). *Trichodina centrestigeata* (Bassan et al. 1983) in which body diameter was 43-47um, adhesive disc 35-40 um, deticular ring 16-37um, number of denticles 26-29um, radialpins / denticle 6-8um. It's medium size Trichondinid with very high body, surrounded by finely striated border membrane. The junction of the blade with the central is narrow. In the same species, the tips of the blade are tangent to the border of the adhesive disc. Rays are straight or sometimes slightly curved posteriorly, thick at the base and tapering gradually to sharp rounded central part conical shape (Fig. 5). Isolation of *T. magna* (VanAS and Bassan, 1989) agree with VanAS and Bassan, (1989), VanAS and Bassan, (1992) & Ali (1992). While isolation *T. centrestigeata*, (Bassan et al.1983) agree with Nativided et al,(1986) who detected it from *Oreochromis niloticus* in Philippines and VanAS and Bassan, (1992) it in Eastern Caprivi. The naturally infected Fish suffering from scales sloughing as well as skin, fins and gills hemorrhages, could be attributed to continuous irritation of trichodina adhesive discs as recorded by Schaper-clause, (1992) and Noga

(1996). This protozoon is relatively common on many fish and its transmission direct contact with infected fish and or contaminated water (Moeller, 2001).

Grossly, naturally infested fish with *Trichodina* spp. were observed to have white or hemorrhagic lesions on the skin, fins and gills, detached scales, anorexia and signs of asphyxia, manifested by rapid breathing and aggregation of fish near the water surface. Most of these clinical signs coincided with observed by Post (1987) and Noga (1996).

The occurrence of stressors such as parasitism enable bacteria to produce infection (Inglis,et al. 1993). This agree with our results that bacteriological examination of internal organs (liver, kidney and spleen) of infected fish revealed isolation of some types of pathogenic gram negative, short bacilli, oxidase positive bacteria. The involved pathogenic bacterial spp. were identified as *Aeromonas hydrophila* as mainly isolates from 70% of examined fish while *Flavobacteria* spp. were identified in 60%. Also *Vibrio* spp. were isolated from necrosis patches of liver in five fish. Bacterial isolates were identified by colonial morphology, microscopic appearance and phenotypic characteristics of the recovered bacteria and were summarized in (Table, 1). Bacterial isolates were closely related to those described by American Society for Microbiology, Balows, et al.,(1992), Cowan and Steal,(1993) and Buller (2004). Isola-

tion of *A. hydrophila* and /or *Flavobacteria* spp. from internal organs of examined *Oreochromis* species which suffered from hemorrhagic signs, fin and tail rot, superficial ulcer and internally from bloody exudates agree with that reported by Husien, (1999), Woo & Bruno, (1999), Ahmed & Shoreit, (2001), El-Ashram (2002), Ali, (2007) and El Genidy & Yousseff (2007). The isolation of *A. hydrophila* from *Oreochromis* species which suffered from parasitic infestation agree with Ruth, (2002) who reported that *Aeromonas* spp. is a stress-mediated disease, it is not unusual to find that infected fish are heavily parasitized or concurrently infected with another systemic disease agent and also agree with Cahill (1990). Presences of variety of signs in fish infected with *A. hydrophila* agree with that reported by Stoskopf, (1993) who recorded that *Aeromonas* infection may occurs as an acute, sub acute, chronic or latent disease of fish. In this study the percentage of isolation of *A. hydrophila* (70%) and *Flavobacteria* spp. (60%) is higher than that reported by Ahmed and Shoreit, (2001), El-Ashram, (2002), Ali, (2007) and El Genidy and Yousseff (2007). This may be due to presence of external parasite which causes ulceration at the site of attachment to the fish, this ulceration may serve as a sight of secondary bacterial or fungal infection as reported by Woo and Bruno, (1999). While isolation of *Vibrio* spp. from liver with yellow discoloration agree with Ahmed and shoreit, (1994) who isolated *V. cholera* from tilapia fish in Assiut Governorate, Egypt and El-newery, (2008) who

isolated *Vibrio* spp. from *Oreochromis niloticus* in Beni-Suef Governorate, Egypt.

Bacteriological examination of water sample and soil revealed isolation of *E. coli*, *Serratia liquefaciens*, *Flavobacteria* spp. and *A. hydrophila*. *S. liquefaciens* was gram -ve, (oxidase, indole, urea, methey red and H₂S production were -ve) and glucose fermentation was +ve. It also gave red colony on nutrient agar. While *E. coli* was gram five, motile, oxidase five bacteria gave pink colony on MacConcy agar according to Balows et al.,(1992), Cowan & Steal,(1993) and Buller (2004).The result agree with Inglis,et al. (1993) who reported that there are a wide variety of pathogenic bacteria which can infect water pond.

Results of pathogenicity of isolated bacteria in *Oreochromis niloticus* revealed different mortalities with similar clinical signs Fig. (6&7) as hemorrhagic signs, fin and tail rot superficial ulcer with reddens in mouth region in case of *Flavobacteria* spp. infection as reported by Husien (1999), congestion of internal organs especially liver, spleen and kidneys, distention of gall bladder and slight accumulation of serous fluid in the abdominal cavity were in concomitant with those observed by Aoki, (1999) and Ahmed and Shoreit (2001).

As recorded in table (2) the mortality rate was varied according to the virulence of bacterial isolate and presence of external stress factors (*Trichodina* spp.). Increase mortality rate in group no.

5, 6 and 7 (mixed infection with bacteria and parasites) than group no. 1, 2 and 3 (free from parasites) indicate that external parasite act as stress factor on fish which lead to increase the effect of bacterial on fish. This agree with that reported by Roberts, (2001) and Igutchi et al, (2004) who regarding the significant role played by different stressors for the exaggeration of disease condition. While fish in group no. 4&8 still alive (control groups).The mortality rate of experimentally infected *Oreochromis niloticus* with isolated bacteria and *Trichodina* spp. was summarized in table (2).

Squash preparation of internal organs liver, kidney and spleen of examined fish revealed the presence of resting spores of *Ichthyophonus hoferi* with different developmental stages of the en-

dospores (uni-bi and multinucleate spores) scattered between the tissues. *I. hoferi* was isolated from 40% of examined fish. This agree with that reported by Salama, (2004) while Hefiney, (2002) recorded 30% infection among wild *O. niloticus* fish. The present study revealed that liver is the most infected organ with *I. hoferi* 60% followed by kidney 40% and spleen 36%. This result agree with Faisal et al. (1985) who recorded *I. hoferi* infection in percentage of 42%, 36% and 14% among liver, kidney and spleen respectively. *I. hoferi* was isolated especially from emaciated fish which internally suffered from granules in many visceral organs, as reported by Moeller, (2007). Fig. (8) showed cyst of *I. hoferi* in wet preparation of spleen while Fig. (9) showed growth character of *I. hoferi* in MEM at ph 5.

Table (1) Biochemical characters of isolated bacteria

Test	Bacteria/sp.	Aeromonas hydrophila	Flavobacteria spp.	Vibrio spp.
Gram stain		-ve	-ve	-ve
Motility		+ve	-ve	+ve
Oxidase		+ve	+ve	+ve
Catalas		+ve	+ve	+ve
H₂s on TSI		-ve	-ve	-ve
Hydrolysis of urea		-ve	-ve	-ve
Hydrolysis of starch		-ve	+ve	+ve
MR		+ve	+ve	+ve
VP		+ve	+ve	+ve
Gelatin hydrolysis		+ve	+ve	+ve
Indole		+ve	+ve	-ve
Growth at 7 % sod. chlorid		-ve	-ve	+ve
Glucose fermentation		+ve	+ve	+ve
Mannitol fermentation		-ve	-ve	+ve
Sorbitol fermentation		-ve	-ve	-----
Pigmentation on Tcbs		-----	-----	yellow
Pigmentation on TSA		-----	yellow	-----
Pigmentation on Aeromonas		yellow	-----	-----

Table (2) Pathogenicity of isolated bacteria in *Oreochromis niloticus*

fish group	Type of infection	No. of dead fish after:			% of mortality
		24hrs	96hrs	7days	
1	A. hydrophila	----	2/6	3/6	50
2	Flavobacteria spp.	-----	2/6	2/6	33.3
3	Vibrio spp.	3/6	5/6	6/6	100
4	free from bacteria	-----	-----	-----	0
5	A. hydrophila & Trichodina spp.	2/6	4/6	6/6	100
6	Flavobacteria spp. & Trichodina spp.	1/6	3/6	5/6	83.3
7	Vibrio spp. & Trichodina spp.	6/6	----	----	100
8	Trichodina spp.	-----	-----	-----	0

No. of fish in each group was 6

Mode of infection: Immersion in 24 hr old broth culture count in 2×10^7 cell CFU

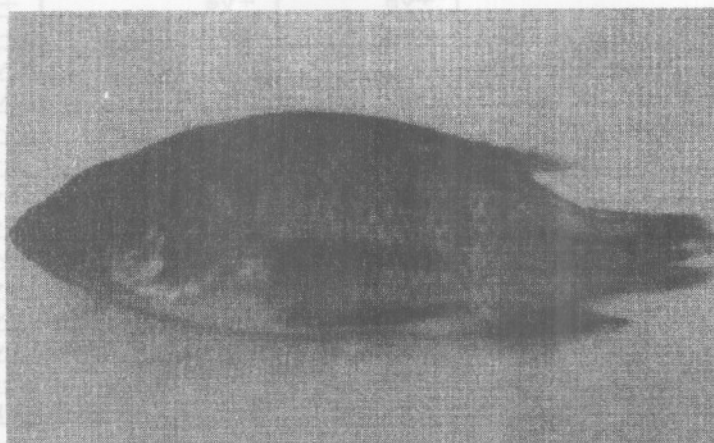


Fig. (1): *Oreochromis* sp. showing darkness, ulceration and tail rot (mixed infection with *Trichodimia* spp. and *A. hydrophila*).

Fig. (2): Oreochromis sp. showing darkness. ulceration loss of scales emasition (mixed infected with *Trichodinia* spp and *Flavobacteria* spp. and *I. hoferia*)



Fig. (3): Oreochromis sp. showing Slight hemorrghic signs patches of necrosis in liver (mixed infection with *A. hydrophila* and *V. cholera*).

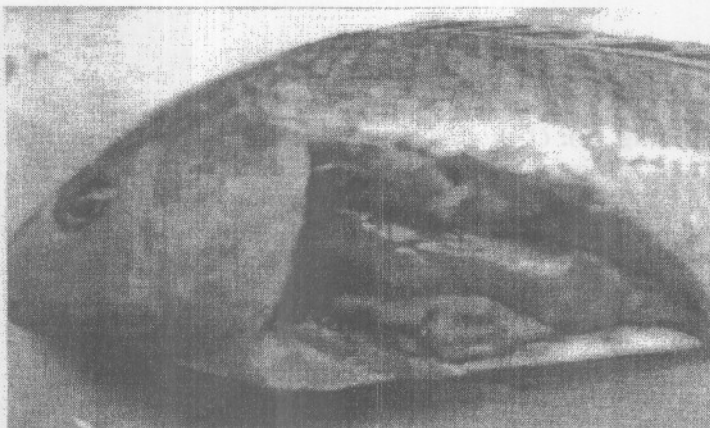


Fig. (4): *Trichodimia magna* (X 100).




Fig. (5): *T. centrestigeata* (X100).

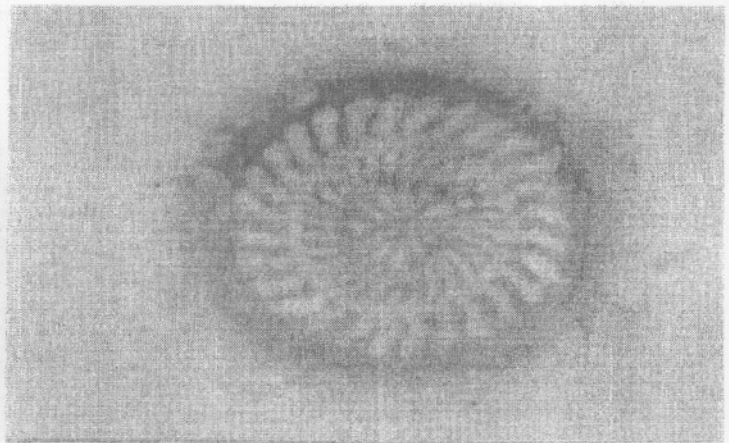


Fig. (6): *O. niloticus* experimentally infected with *A. hydrophila* and *Trichodinia* spp. showing loses of scales. hemorrghic signs and tail erosion.

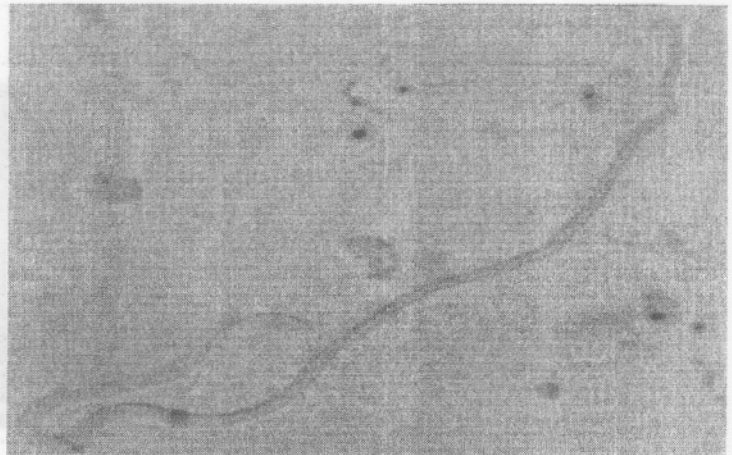


Fig. (7): *O. niloticus* experimentally infected with *Flavobacteria* spp. and *Trichodimia* spp. showing loses of scales hemorrghic signs.




Fig. (8): *Ichthyophonus hoferi* cyst in squash preparation of spleen.

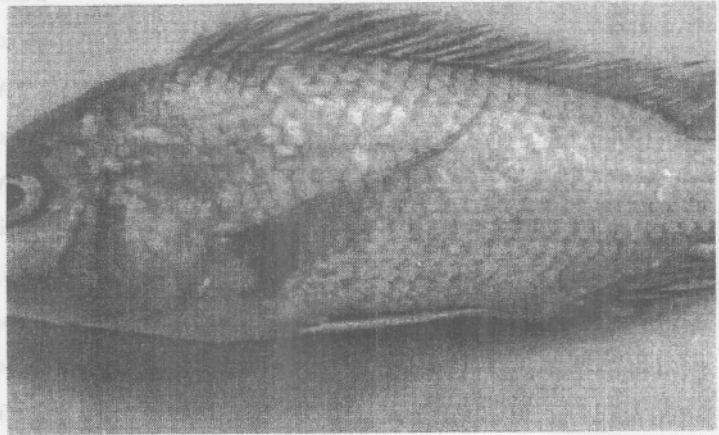


Fig. (9): Showing development process of spherical multinuclated hyphae, terminal bodies L. C. B. stain.

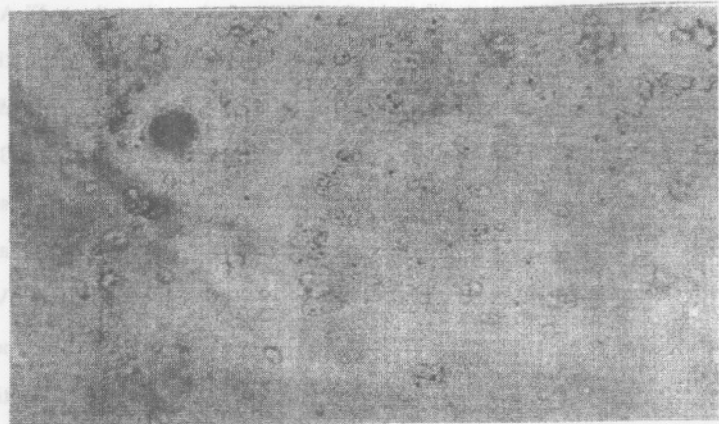
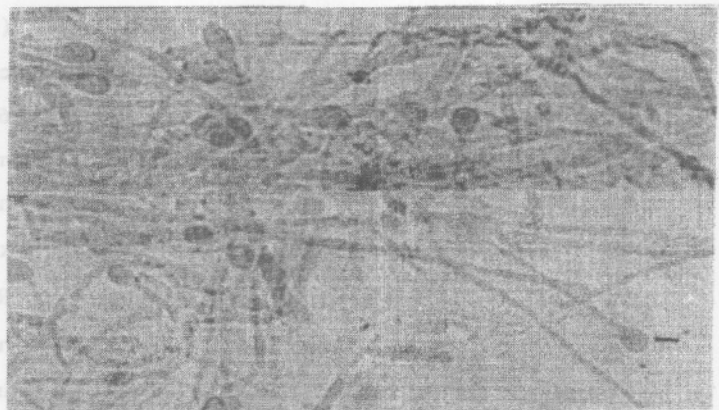


Fig. (10): Showing development process of spherical multinuclated hyphae, terminal bodies L. C. B. stain X 200.



- ha Branch).
- Hietala, J., Valtonen, E. t. and Aaltonen, T. (1995): Experimental infection of brown trout, *Salmo trutta* L., using a Finnish *Yersinia ruckeri* isolate. *Aquaculture*, 136,11-20.
- Husien, Mona. M. (1999): Natural and experimental infection of *Flavobacterium* species in freshwater fish. *Beni-Suef Vet. Med. J. Vol.9, No 3- A: 311-329.*
- Iguchi, K., Ogawa, K., Nagae, M. and Ito, F. (2004): The influence of rearing density on stress response and disease susceptibility of ayu, *plecoglossus altivelis*. *J.of Fish Diseases* 22, 515-523.
- Inglis, V., Robert, R. J. and Bromage, N. R (1993): Bacterial diseases of fish. Blackwell Scientific Publication, London, Edenburg, Boston, Ch.10: 169- 174.
- Lom, G. (1995): Trichodinidae and other ciliates (phylum ciliophora). Cited by "Woo, P.T.K. (1995) *Fish Diseases Disorders Protozoa, metazoan, infections CAP International*".
- Lom, J. and Dykova, I. (1992): Protozoan parasites of fishes. Elsevier Science Publishers, Amsterdam. pp.242.
- McVicar A.H. (1982): Ichthyophonus infections of fish. *Microbial Diseases of Fish*. Ed. By R. J. Roberts. Academic Press, New York, PP. 243-269.
- Moeller, R. B. Jr. (2001): Diseases of fish. California Animal Health and Food Safety Laboratory System California†rbmoeller@ucdavis.edu.
- Moeller R, B. Jr. (2007): Fungal Diseases of Fish. California Animal Health and Food Safety. Laboratory System. www. Cichild forum com./privacy phd.
- Nativded, J. M., Banded-Reantse, M. G. and Arthur, J.R. (1986) : Parasities of Nile Tilapia (*Oreochromis niloticus*) in the Philippines. In: Maclean, J.I.,Dizon,L. Bond, Hosillas, L.V.(Eds).The first Asian Fisheries Society, Mobila,Philippines, pp 225-259.
- Noga, E. J. (1996): Fish diseases diagnosis and treatment. Mosby ElectronicPublishing. USA 163.
- Osman, A. F. M. (2001): Studies on parasitic gill affections in some cultured fresh water fishes. M.V.Sc. Thesis Seuz Canal. Uni.
- Paperna, I. (1996): Parasites, infections and diseases of fishes in Africa FAO, CIFA Techincal Paper. 563.
- Peggy, A. R., and Ruth, F.F. (2002): *Vibrio* Infections of Fish. This document is FA31, one of a series of the Fisheries and Aquatic Sciences Department, Florida Cooperative Extension Service, Institute of Food and Agricultural Sciences, University of Florida. Reviewed July, 2002. Visit the EDIS Web Site at <http://edis.ifas.ufl.edu>.
- Post, G. (1987): Textbook of Fish Health. T.F.H. publications, Inc. Neptune City New Jersey, USA. P. 159- 214
- Roberts, R. J. (1987): *Fish Pathology*.1st ed.Baillera,Tindall ,LondonPP. 329.
- Roberts, R. J. (2001): *Fish Pathology*. 3rd Edition, W.B. Saunders, An imprint of Harcourt Publishers Limite .
- Ruth, F. F. (2002): *Aeromonas* Infections. IFAS Extension Veterinarian, Cooperative Extension Service, Institute of Food and Agricultural Sciences. Series of the Fisheries and Aquatic Sciences Department, Florida Cooperative Extension Service, University of Florida, Gainesville, 32611. HYPERLINK "<http://edis.ifas.ufl.edu>" <http://edis.ifas.ufl.edu> .
- Salama, Soad, S. A. (2004): Studies on Ichthyophonus disease among marine and freshwater fishes with trial to control. Ph. D. Vet. Suez canal Uni.
- Schaper-clause, W. (1992): *Fish Diseases*. Vol. 2 A.A.

- Blakema, Rotterdam, Berlin.
- Snieszko, S. F. and Axelrod, H. R. (1980): Diseases of fishes. Book 3: The prevention and treatment of fish diseases. T.F.H. Publications, Inc. Neptune City, New Jersey, USA.
- Spanggaard, B., Gram, L., Okamoto, N. and Huss, H. H. (1994): Growth of the fish pathogenic fungus, *Ichthyophonus hoferi* measured by condicimetry and microscopy. *J. Fish. Dis.* 17, 2: 145-153.
- Stoskopf, M. K. (1993): *Fish Medicine*. W.B.Saunders Company, Harcourt, Brace, Jovvavich, Inc. London
- Tojo, J. I., Santamarina, M. T., Leiro, J.,Uberia, F. M. and Sanmartin, M. L. (1984) : Pharmacological treatments against *Ichthyoboda* (Henneguy,1883) in Rainbow trout,*Oncorhynchus mykiss* (Walbaun).17: 135 -143.
- Toranzo, A. E, Combarro, P., and Conde, Y .and Baja, J. L. (1985): Bacteria isolated from Rainbow trout reared in freshwater in Galicia (north Spain): Taxonomic analysis and drug resistance patters. In. *Fish and Shellfish Pathology*. (A.ER. Ellis, ed.) pp 141-152. Academic press, London.
- Van As, J.G. and Bassan, L.(1987): Host specificity of Trichodinid ectoparasites of freshwater fish. *Parasitology Today*. 3 (3): 88-90.
- Van As, J. G. and Bassan, L. (1989): A further contribution to the taxonomy of the taxonomy of the Trichodinidea (Ciliophora: peritrichida and a review of the taxonomic status of some fish ectoparasitic Trichodinids. *Sys. Parasitol.* 14: 157-179.
- Van As, J. G. and Bassan, L. (1992): Trichodinid ectoparasites Ciliophora: (Peritrichida) of fresh of the Zambesi river system with a reappraisal of host specificity. *Sys. Parasitol.* 22:81-109.
- Woo, P. T. K. and Bruno, D.W. (1999): *Fish Disease and Disorders*. Vol.3:Viral Bacterial and Fungal .CAB International.U.K.USA.pp.427-453.

تعيين بعض الميكروبات والطفيليات فى أسماك البلطى بمصرف الزويدة بمحافظة القليوبية

د. عبدالنواب فهمى غريب* د.منى مصطفى حسين** د. سعاد صبرى عبدالحليم**
*معمل الجيزة الفرعى معهد بحوث صحة الحيوان الدقى
**قسم أمراض الأسماك معهد بحوث صحة الحيوان الدقى

تم فى هذه الدراسة تجميع عينات من أسماك البلطى من مصرف الزويدة بمحافظة القليوبية ونقلها الى معهد بحوث صحة الحيوان بالدقى وكانت هذه الأسماك تعاني من أعراض التسمم الدموى مع تقرحات على سطح الجسم وتعفن فى الدبل والزعانف وأثبت الفحص إصابتها بالترايكودينا بنسبة ٨٠% مع وجود بكتيريا ممرضة للأسماك حيث تم عزل ميكروب الإيرومونس هيدروفيليا بنسبة ٧٠% وميكروب الفلافوبكتيريا بنسبة ٦٠%. كما تم أيضا عزل فطر الإكسوفونس هوفرى من الأسماك المصابة بنسبة 40%. وأدت العدوى الصناعية بالبكتيريا المعزولة إلى نسبة نفوق ١٠٠% فى حالة العدوى الصناعية بميكروب الإيرومونس والترايكودينا معا .