

VITAMIN E AND ASCORBIC ACID EFFICACY ON RENAL ISCHEMIA- REPERFUSION INJURY IN EXPERIMENTAL DOGS

MOSBAH E. * and Nasr EL-DEEN N. A. M. **

* Dept. of Vet. Surgery, Anaesthesiology & Radiology, Faculty of Vet Medicine, Mansoura Univ.,

** Department of Clinical Pathology, Faculty of Vet. Medicine, Zagazig Univ..

Received: 23.11. 2008

Accepted: 30. 11. 2008

SUMMARY

It was reported that ischemia-reperfusion injury (IRI) is a major cause of acute renal damage in both the native and transplanted kidneys. Sixteen clinically healthy male dogs were exposed to 45 minutes renal ischemia followed by reperfusion and unilateral nephrectomy. Those dogs were subdivided equally into 4 groups. Gp.(1) was the positive control, gp.(2) was treated with vitamin E (20mg / kg Bwt/ day), gp.(3) was treated with ascorbic acid (30mg / mg / kg Bwt/ day) and gp. (4)was treated with both drugs. The experimental dogs were sacrificed, 7day after surgery. Specimens were taken from the left kidney in all groups.

The serum creatinine, urea nitrogen and potassium levels were significantly increased while the serum sodium and creatinine clearance were reduced in all groups, compared with the basal value. The urine of the positive control group con-

tained protein and blood, besides hyaline and cellular casts. Gps. (2&3) showed a weak improvement in the renal function while gp. (4) relieved some of the damage induced by the renal ischemia- reperfusion. Microscopically gp.(1) showed diffuse coagulative necrosis of the renal epithelium. Also casts were present inside the lumina of the renal tubules.Gp.(2) showed moderate necrotic or degenerative changes of some tubular epithelium accompanied with contraction of some glomerular tufts and leukocytic infiltration. Gp. (3) showed periglomerular leukocytic aggregations mainly lymphocytes with lobulation of some glomerular tufts and various degenerative or coagulative necrosis. Gp.(4) showed that the majority of renal tubules suffered from hydropic degeneration,cloudy swelling and some of them revealed necrotic changes with absence of nuclei.

It could be concluded that the combined vitamin E and ascorbic acid treatment partially ameliorated the renal IRI.

INTRODUCTION

Renal warm ischemia reperfusion injury in clinical practice is a consequence of both systemic hypoperfusion (e.g. shock and acute myocardial infarction) with subsequent circulatory resuscitations and local renal hypoperfusion following renal transplantation (Weight et al., 2001), unilateral nephrectomy, renal vascular surgery, enucleation of renal cell carcinoma (Saito and Miyagawa, 2000) and aortic cross clamping (Weight et al.,1998).

Renal ischemia is a major cause of acute renal failure (ARF). It initiates a complex of interrelated sequences, resulting in injury and eventual necrosis of the renal cells (Lieberthal and Levine, 1996 and Thadhani et al., 1996). The prognosis is bad due to the fact that reperfusion, although essential for the survival of the ischemic renal tissue, causes additional damage contributing to renal dysfunction and injury Lieberthal and Levine, 1996 ,Thadhani et al., 1996 and Weight et al.,1996).

Reperfusion of the ischemic organ (especially during transplantation) causes the release of superoxide, which exacerbates the primary injury,induced by ischemia (Bonventre, 1993). In order to reduce these metabolites, many studies have examined a variety of free radical oxygen scavengers. These include the effects of external supplementation of antioxidants (Gianello et

al.,1996 , Mathews and Gregory ,1997, Lee et al.,2006 and Bayrak et al.,2008).

It was reported that vitamin E (alphatocopherol) and vitamin C (ascorbic acid)are powerful antioxidants that react rapidly with a variety of oxidants .They represent the first line of antioxidant defense (Unal et al., 2002) which may improve the renal transplant function ,especially in grafts donated from marginal donors (Loong et al.,2004) . They attenuated the warm unilateral renal I/R injury in the pigs (Kim et al., 2007). Ascorbic acid has been used to improve the renal hemodynamics as well as decrease the oxidative stress, inflammation and fibrosis in the ischemic kidney of pigs (Chade et al., 2003).

Our experimental study aimed to examine the efficacy of vitamin E and/or ascorbic acid to ameliorate the renal IRI in dogs with the aim to improve the outcome of renal transplantation by attenuating the renal IRI.

MATERIAL AND METHODS

Sixteen male,mixed breed dogs (10-13 kg B.wt) were acclimatized and maintained on a standard diet for 1 week before the surgical procedure.The experimental dogs were premedicated with intramuscular injection of atropine sulphate (0.04 mg / kg B.wt) followed by intramuscular injection of xylazine Hcl (1 mg / kg B.wt), ketamine Hcl (10 mg /kg B.wt) and the anaesthesia was maintained

by intravenous injection of thiopental sodium (2.5%).

The abdominal skin was aseptically prepared. A midline abdominal incision was done. The left kidney was exposed and it was carefully dissected from the perirenal tissue and fat. Both the renal artery and vein were clamped with an atraumatic clamp (Fig.1). Heparin (150 IU /kg body weight) was given intravenously three minutes before ischemia. After 45 minutes of warm ischemia(Fig.2), the vessels were unclamped and the blood reflow to the left kidney was verified visually and then nephrectomy to the right kidney was performed. The technique was performed on sixteen dogs, equally divided into 4 groups (gps.1-4). Group (I) was the positive control. Gp.(2) was intramuscularly injected with vitamin E (20mg/ mg / kg Bwt/ day E-viton, Kahira Pharm. and Chem. Ind. Co.-Cairo-Egypt) ,one day before ischemia and for 6 successive days post operation. Gp.(3) was injected intravenous with ascorbic acid, one day before ischemia and for 6 successive days post operation (30 mg / kg Bwt/ day, Cevaryl, Memphis Co. for Pharm. and Chem. Ind.-Cairo-Egypt. Gp.(4) was treated with combination of Vit E and ascorbic acid , one day before ischemia and for 6 successive days post operation, at the same doses.

Two blood samples were collected from the cephalic vein before the operation (basal value) and after 2, 3,4, 5 and 7 day from the operation. The

first blood sample (0.5ml) was collected from each dog on disodium salt of EDTA and used for the estimation of erythrocytic count and pcv (Feldman et al.,2000) and hemoglobin (Zijlstra ,1960). The second blood sample (5 ml) was collected in a centrifuge tube to separate the serum for the determination of the serum creatinine (Henry , 1974), blood urea nitrogen (Patton and Crouch , 1977), potassium (Sunderman and Sunderman ,1958)) and sodium (Trinder ,1951). Daily urine samples were collected from each cage and urine analysis was done microscopically and chemically by using a reagent strip (Yoder et al.,1965). The urine volume was measured then a sample was taken for the estimation of urine creatinine.

The creatinine clearance was measured by the following equation (Kneko et al.,1997) .

$$\text{Ccr} = \frac{\text{Urine creatinine (mg/dl)} \times \text{Urine volume (ml/24h)}}{\text{Serum creatinine (mg/dl)} \times 1440(\text{min})} = \text{ml/min}$$

The experimental dogs were sacrificed 7 days post operation(p.o.). Specimens, from the left kidney of each group, were fixed in 10% neutral buffered formalin. Five micron thick paraffin sections were prepared , stained with hematoxylin and eosin(H&E) (Banks ,1981) and examined microscopically.

All the obtained data were analyzed using two way anova of SPSS statistical analysis system package (SAS, 2000). The study used the factori-

al design, General Linear Model (GLM).

RESULTS

All groups showed non significant decrease in the erythrocytes , pcv and hemoglobin (Tables 1-3). Gps.(1-4) exhibited a significant increase in the serum concentrations of creatinine and urea nitrogen ,when compared with the basal value, suggesting a significant degree of glomerular damage mediated by renal IRI. There was a significant reduction in the creatinine clearance value which is used as an indicator for the glomerular filtration rate and thus glomerular function. Treatment by vitamin E(gp.2) or ascorbic acid (gp.3) produced a significant decrease in the serum creatinine ,while the creatinine clearance was increased throughout the experimental period when compared with the untreated group. The blood urea nitrogen showed similar result except gp.(3)which showed a significant decrease on the 3rd day post operation. Gp.(4) showed a significant reduction in the serum levels of creatinine and urea nitrogen ,during the experimental period, together with an increase in the creatinine clearance when compared with the positive control(gp.1). Moreover a significant improvement was noticed when compared with each drug alone (Tables 4-6). Hyperkalemia was found in gps.(1-4) when compared with the basal value. This hyperkalemia was evident on the 2nd day post operation (gp.1) and on the 3rd day post operation in gps.(2-4). A significant decrease in the serum po-

tassium was found in gps.(2-4)throughout the experimental period when copared with gp.(1). (Table 7). Hyponatremia was present in gps.(1-4) during the experimental period when compared with the basal value. This hyponatremia was improved in gps.(2-4)when compared with the untreated group (Table 8).

Nearly all dogs showed traces of proteinuria before the operation. The urinalysis revealed erythrocytes in all groups on the 2nd day (p.o.) .The microscopic examination of the urine revealed hyaline casts on the 3rd day (p.o.) and epithelial casts on the 5th day till the end of the experiment in gp.(1). Hyaline casts were present on the 4th day till the end of the experiment in the urine of the other groups . Also proteinuria was found in all groups during the experimental period. The details of urinalysis are illustrated in table(9).

The left kidney was dark- purple during the ischemia (Fig. 2) and returned to its normal color after reperfusion. The experimental dogs began to walk, eat and drink one day po. All the animals survived for 7 days po and were sacrificed. At the time of sacrifice, the left kidney was slightly small particularly in gp.(1). Macroscopically, there were no lesions in the visceral organs. Gp. (1) showed diffuse coagulative necrosis of the renal epithelium(Fig.3)which was intensely infiltrated with leukocytes mainly mononuclears. Renal casts (hyaline and cellular) were detected within the lumina of some collecting tubules

(Fig.4). Gp.(2) showed moderate necrotic and degenerative changes of some renal epithelium. Fig.(5) showed contracted glomerular tufts and leukocytic infiltration in the renal parenchyma. Some regenerative attempts were encountered in the tubular epithelium. A few renal casts were seen. Gp.(3) showed periglomerular leukocytic aggregations, mainly lymphocytes ,besides lobulation of some glomerular tufts and various degenerative and coagulative necrosis (Fig. 6).

Some glomeruli had thickened glomerular basement membrane with interstitial round cell aggregations. The collecting tubules showed hydropic degeneration. The majority of the renal tubules(gp.4) suffered from hydropic degeneration,cloudy swelling with frequent necrotic changes where the nuclei were absent (Fig. 7). Some cellular casts could be seen within the lumina of some renal tubules. A few scattered extravasated erythrocytes could be seen among the necrotic renal tubules.

Table (1): Erythrocytes ($\times 10^6/\mu\text{l}$) of dogs in gps.(1-4)during 7 day PO,(mean+SE).

Time/day Groups	Basal	2	3	4	5	7
1	6.45 ^a ±0.19	6.25 ^a ±0.28	5.86 ^a ±0.23	5.64 ^a ±0.22	5.43 ^a ±0.21	4.80 ^a ±0.26
2	6.41 ^a ±0.25	6.20 ^a 0.34	5.90 ^a ±0.35	5.80 ^a ±0.29	5.63 ^a ±0.33	5.15 ^a ±0.21
3	6.40 ^a ±0.24	6.30 ^a ±0.30	5.93 ^a ±0.26	5.85 ^a ±0.30	5.68 ^a ±0.28	5.25 ^a ±0.16
4	6.43 ^a ±0.20	6.30 ^a ±0.26	6.23 ^a ±0.22	5.88 ^a ±0.36	6.00 ^a ±0.08	5.90 ^a ±0.06

Table (2): PCV % of dogs in gps.(1-4)during 7 day PO,(mean+SE).

Time/day Groups	Basal	2	3	4	5	7
1	36.50 ^a ±0.96	36.00 ^a ±0.91	35.75 ^a ±0.95	35.50 ^a ±1.44	35.00 ^a ±1.08	33.75 ^a ±1.44
2	36.25 ^a ±0.75	35.75 ^a ±1.11	35.75 ^a ±0.91	35.50 ^a ±0.87	35.25 ^a ±.75	34.50 ^a ±1.32
3	36.00 ^a ±1.15	36.00 ^a ±1.08	35.75 ^a ±0.63	35.50 ^a ±0.1.04	35.50 ^a ±1.19	34.75 ^a ±0.95
4	36.25 ^a ±0.95	36.25 ^a ±1.38	36.00 ^a ±0.75	35.75 ^a ±0.48	35.75 ^a ±1.11	35.25 ^a ±0.75

Table (3): Hemoglobin gm % of dogs in gps.(1-4)during 7 day PO,(mean+SE).

Time/day Groups	Basal	2	3	4	5	7
1	12.20 ^a ±0.14	12.07 ^a ±0.14	11.90 ^a ±0.21	11.78 ^a ±0.37	11.70 ^a ±0.45	11.50 ^a ±0.29
2	12.03 ^a ±0.09	11.98 ^a ±0.18	11.85 ^a ±0.21	11.80 ^a ±0.31	11.80 ^a ±0.15	11.65 ^a ±0.38
3	12.15 ^a ±0.18	12.00 ^a ±0.21	11.88 ^a ±0.13	11.83 ^a ±0.37	11.80 ^a ±0.19	11.70 ^a ±0.26
4	12.10 ^a ±0.20	12.00 ^a ±0.25	11.95 ^a ±0.08	11.88 ^a ±0.28	11.89 ^a ±0.33	11.90 ^a ±0.32

Table (4):Serum creatinine (mg/dl) of dogs in gps.(1-4)during 7 day PO,(mean+SE).

Time/day Groups	Basal	2	3	4	5	7
1	0.70 ^h ±0.05	3.80 ^{bc} ±0.26	4.98 ^a ±0.26	4.20 ^b ±0.18	3.58 ^c 0.10	3.65 ^c 0.12
2	0.71 ^h ±0.06	2.93 ^d 0.23	3.55 ^c ±0.21	2.95 ^d ±0.06	2.33 ^f ±0.13	2.43 ^{ef} ±0.12
3	0.72 ^h ±0.05	2.83 ^{de} ±0.11	3.43 ^c ±0.18	2.83 ^{de} ±0.13	2.30 ^f ±0.19	2.30 ^f ±0.19
4	0.69 ^h ±0.04	2.50 ^{ef} ±0.16	2.93 ^d ±0.15	1.80 ^g ±0.11	1.45 ^g ±0.13	1.43 ^g ±0.10

*LSD=0.429

*Mean carrying different superscripts are significant at P<0.05

Table (5): Creatinine clearance (ml/min) of dogs in gps.(1-4)during 7 day PO,(mean+SE).

Time/day Groups	Basal	2	3	4	5	7
1	38.34 ^a ±2.35	1.66 ^{gh} ±0.13	0.46 ⁱ ±0.05	1.03 ^{hi} ±0.11	3.73 ^{ig} ±0.07	3.63 ^{ig} ±0.09
2	37.45 ^a ±1.69	4.07 ^f ±0.11	3.41 ^{igh} ±0.15	4.92 ^{ef} ±0.11	7.26 ^{cde} ±0.28	7.28 ^{cdc} ±0.14
3	38.53 ^a ±1.99	4.43 ^f ±0.09	3.57 ^{ig} ±0.16	5.10 ^{ef} 0.15	8.18 ^c ±0.47	8.23 ^c ±0.48
4	37.88 ^a ±1.99	5.32 ^{def} ±0.17	3.83 ^{ig} ±0.16	7.65 ^{cd} ±0.22	13.90 ^b ±0.23	13.64 ^b ±0.27

*LSD=2.38

*Mean carrying different superscripts are significant at P<0.05

Table (6): BUN (mg/dl) of dogs in gps.(1-4)during 7 day PO,(mean+SE).

Time/day Groups	Basal	2	3	4	5	7
1	19.69 ^m ±0.70	60.79 ^{cde} ±0.91	69.50 ^a ±1.32	59.89 ^{def} ±0.88	48.11 ⁱ ±0.75	47.50 ⁱ ±0.96
2	19.78 ^m ±0.73	58.92 ^{ef} ±1.18	64.13 ^b ±0.76	50.90 ^h ±0.79	38.56 ^k ±0.88	37.75 ^k ±0.75
3	20.40 ^m ±0.83	58.20 ^{fg} ±1.18	63.03 ^{bc} ±0.82	49.75 ^{hi} ±0.85	38.00 ^k ±0.81	36.75 ^k ±0.85
4	19.99 ^m ±0.82	56.35 ^g ±0.71	62.00 ^{bcd} ±0.91	44.58 ^j ±0.87	30.75 ⁱ ±0.75	29.25 ⁱ ±0.48

*LSD=2.45Mean

*Mean carrying different superscripts are significant at P<0.05

Table (7): Serum potassium (meq/L) of dogs in gps.(1-4)during 7 day PO,(mean+SE).

Time/day Groups	Basal	2	3	4	5	7
1	4.03 ^g ±0.10	4.75 ^d ±0.15	5.37 ^a ±0.12	5.31 ^a ±0.14	5.23 ^{ab} ±0.14	5.17 ^{abc} ±0.13
2	4.00 ^g ±0.14	4.25 ^{efg} ±0.09	4.86 ^{bcd} ±0.18	4.79 ^{cd} ±0.16	4.70 ^d ±0.18	4.66 ^d ±0.19
3	4.05 ^g ±0.10	4.20 ^{fg} ±0.04	4.83 ^{cd} ±0.14	4.75 ^d ±0.13	4.70 ^d ±0.81	4.61 ^{de} ±0.12
4	4.05 ^g ±0.13	4.23 ^{efg} ±0.17	4.70 ^d ±0.18	4.65 ^d ±0.14	4.59 ^{de} ±0.12	4.48 ^{def} ±0.12

*LSD=0.389

*Mean carrying different superscripts are significant at P<0.05

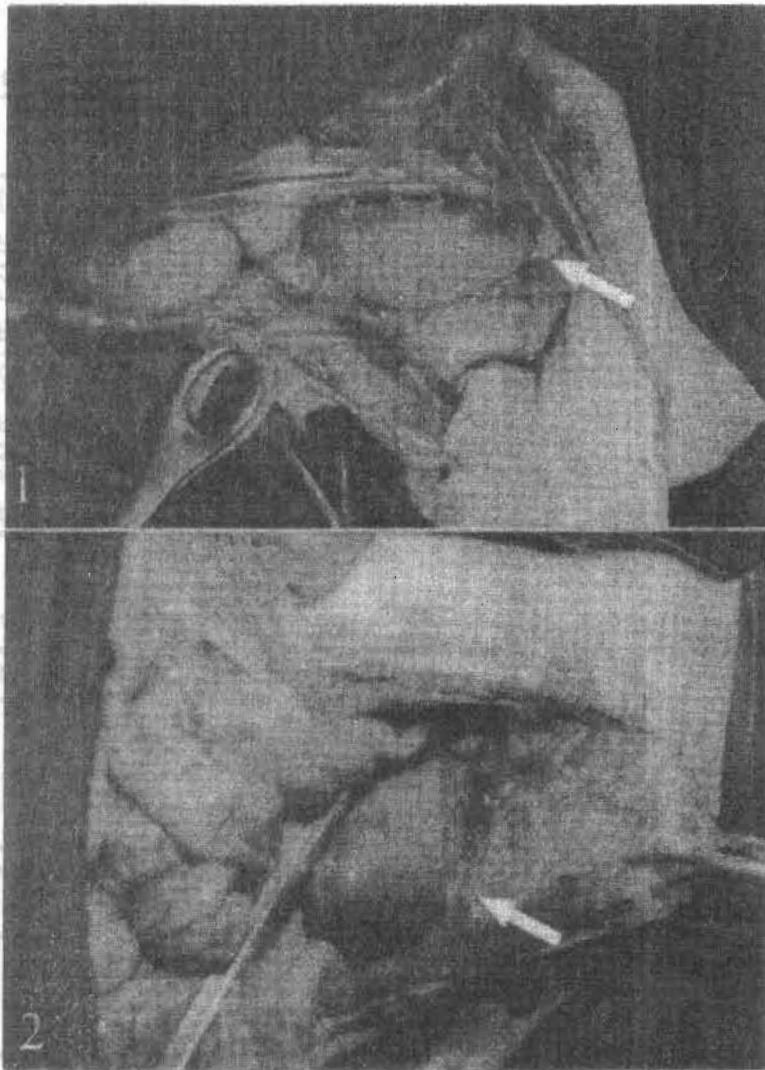
Table (8): Serum sodium (meq/L) of dogs in gps.(1-4) during 7 day PO,(mean-+SE).

Groups	Time/day	Basal	2	3	4	5	7
1		140.59 ^a	134.53 ^c	125.36 ^{gh}	116.98 ^j	115.25 ^j	110.93 ^k
		±1.20	±0.67	±0.71	±0.60	0.72	±0.68
2		140.88 ^a	136.95 ^b	129.13 ^{ef}	126.73 ^g	125.83 ^g	122.75 ⁱ
		±1.01	±0.81	±0.31	±0.89	±0.96	±0.48
3		140.60 ^a	137.30 ^b	129.88 ^{de}	127.56 ^{ig}	125.95 ^g	123.55 ^{hi}
		±0.95	±0.47	±0.97	0.77	±0.64	±1.78
4		141.00 ^a	138.00 ^b	131.68 ^d	130.75 ^{de}	129.00 ^{ef}	126.66 ^g
		±0.71	±1.16	±0.26	±0.48	±0.91	±0.64

*LSD=2.20 *Mean carrying different superscripts are significant at P<0.05

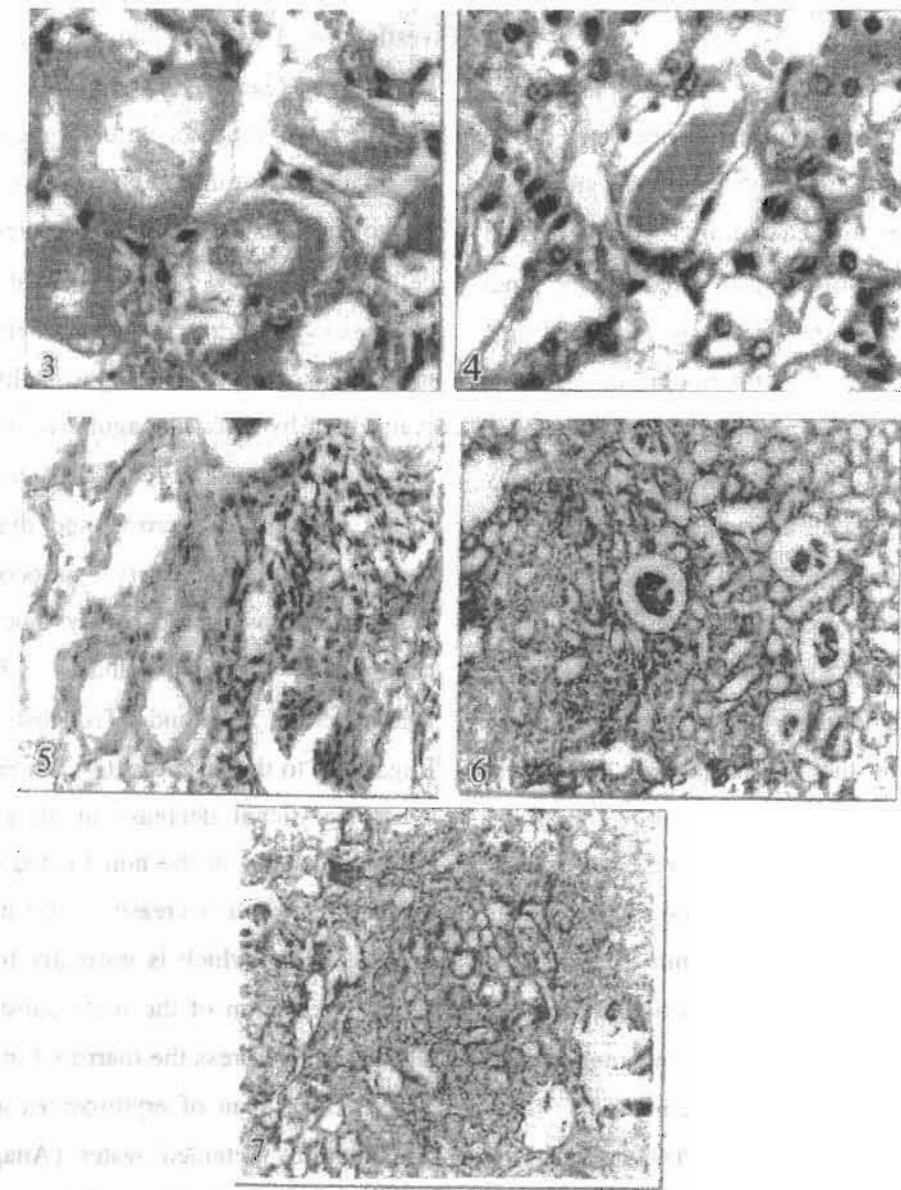
Table (9): Chemical and microscopic examination of dogs in gps.(1-4) during 7 day PO.

Groups	Parameters		RBCs					Hyaline casts					Epithelial casts					Protein							
	BASAL	2nd	3rd	4th	5th	7th	BASAL	2nd	3rd	4th	5th	7th	BASAL	2nd	3rd	4th	5th	7th	BASAL	2nd	3rd	4th	5th	7th	
1	-	++	-	-	-	-	-	-	+	+	+	+	-	-	-	-	-	+	+	trace	++	++	++	++	++
2	-	++	-	-	-	-	-	-	-	+	+	+	-	-	-	-	-	-	-	trace	+	+	+	+	+
3	-	++	-	-	-	-	-	-	-	+	+	+	-	-	-	-	-	-	-	trace	+	+	+	+	+
4	-	++	-	-	-	-	-	-	-	+	+	+	-	-	-	-	-	-	-	trace	+	+	+	+	+



Figs. (1&2):

1. Clamping the left vessels of the kidney with a traumatic forceps at the beginning of ischemia.
2. Left kidney after 45 minutes from the beginning of ischemia.



Figs. (3-6):

- 3. Gp.(1), kidney showing diffuse coagulative necrosis of the renal epithelium (H&E.,X1200).
- 4.Gp.(1), kidney showing casts inside the lumina of the renal tubules (H & E., X1200).
- 5.Gp.(2), kidney showing moderate necrotic or degenerative changes accompanied with leukocytic infiltration of the renal parenchyma (H & E.,X 120).
- 6.Gp.(3),kidney showing periglomerular lymphocytic aggregations and lobulated glomerular tufts (H & E.,X 120).
- 7.Gp.(4), kidney showing that the majority of renal tubules suffered from severe hydropic degeneration and some of them revealed necrotic changes (H & E.,X 120).

DISCUSSION

The oxidative stress is an imbalance between the oxidants and antioxidants (Sies, 1997), and probably contributes to the development, progression and complications of both acute and chronic renal failure which is characterized by increased production or decreased elimination of oxidants (Andreoli, 1991). The employment of the antioxidants (Vits. E&C), in our study, was reasonably effective in the amelioration of the renal IRI damage, thus, it may improve the outcome of the renal transplantation from dead donors. The addition of ascorbic acid protected the renal tissue against the reperfusion injury and so it may help the recovery of the renal function after renal transplantation (Lee and Kim, 2006). The ascorbic acid reduces the level of the reactive oxidant species, both intracellular and extracellular (Iheanacho et al., 1993). Vitamin E is a chain-breaking antioxidant with the particular function of scavenging peroxide radicals in order to prevent lipid peroxidation in the membrane systems (MacDonald-Wicks and Garg, 2003 and Suminen et al., 2003). Vitamin E supplement proved to be protective against the effects of the oxidative stress (Sakarya et al., 1999) and is essential for protecting the aging kidneys against the ischemic acute renal failure (Shimizu et al., 2004). The present work showed that the renal ischemia reperfusion injury caused degenerative changes in the renal tissue as was clarified by both the clinicopathological and histopathological means of in-

vestigation. This renal damage was elucidated by the increased serum creatinine, urea nitrogen and hyperkalemia together with decreased creatinine clearance and serum sodium. Also, the presence of proteinuria and hematuria, besides hyaline and cellular casts in the urine indicated degenerative changes in the kidney. Such biochemical changes are the outcome of the nephropathy which was manifested by diffuse coagulative necrosis of the renal epithelium. The renal IRI injury was manifested by tubular necrosis and dysfunction, as well as glomerular injury, vasoconstriction of the glomerular tufts and dysfunction (Weight et al., 1998, Chander and Chopra 2005, Rhoden et al., 2005 and Troncoso et al., 2005). Regarding to the erythrocytes, our results proved a non-significant decrease in all groups which was pronounced in the non treated groups. This may be due to a decrease in the production of erythropoietin (which is normally formed in the kidney), retention of the toxic substances in the blood which depress the marrow function and reduce the life span of erythrocytes and dilute of the blood by retained water (Anagnostou and Kurtzman, 1986 Walter and Isreal, 1987, and Kneko et al., 1997).

We found that the combined treatment with both vitamin E and ascorbic acid caused a significant improvement in the various measured parameters (serum creatinine, creatinine clearance, blood urea nitrogen, serum potassium and sodium), when compared with the positive control. The re-

nal function was significantly still less than the basal rate. This indicates that the combined treatment although was beneficial, but not sufficient to relief all the damage induced by the renal IRI. Nearly similar findings were previously obtained (Unal et al., 2002) as they concluded that the administration of vitamin E plus ascorbic acid caused a mild improvement of the renal IRI damage.

It could be concluded that the combined treatment with ascorbic acid and vitamin E partially alleviated the renal IRI. Further molecular studies, are needed to elucidate the pathogenesis of the renal IRI damage to maintain the viability of the transplanted organs.

ACKNOWLEDGMENT

Thanks to Prof. Dr. A. A. Ali Prof. of Histopathology, Faculty.of Vet. Medicine, Zagazig Uni.

REFERENCES

- Anagnostou A. and KurtzmanN. (1986): Hematological consequences of renal failure, in *The Kidney*, edited by Brenner BM, Rector FC Jr, Philadelphia, WB Saunders Co., pp. 1642-1643
- Andreoli SP (1991): Reactive oxygen molecules, oxidant injury and renal disease. *Pediatric Nephrol* ; 5(6):733-42.
- Banks WJ(1981): *Methods of histology* .In *Applied Veterinary Histology*. 2nd ed.Williams and Wilkins. Baltimor/ London.
- Bayrak,o.;Uz.E.;Bayrak,R.;Turgut,F.;Atamaca,A.F.;Sahin, S.;Yildir im, M.E. and Akcay, A.(2008): Curcumin protects against ischemia/ reperfusion injury in rat kidneys. *World Journal of Urology*, 26(3):p.285-291.
- Bonventre J V (1993): Mechanisms of ischemic acute renal failure *Kidney Int*; 43 (5):1160-1178.
- Chade AR, Rodriguez - Porcel M, Herrmann J, Krier JD, Zhu X, Lerman A and Lerman LO (2003): Beneficial effects of antioxidant vitamins on the stenotic kidney. *Hypertension*; 42 (4): 605-12.
- Chander V and Chopra K (2005): Renal protective effect of molsidomine and L-arginine in ischemia-reperfusion induced injury in rats. *J Surg Res* ; 128 (1):132-9.
- Feldman BF, Zinki JG and Jain VC (2000): *Schalm's Veterinary Hematology*,5th Ed, Lippincott Williams and Wilkins., Canada.
- Gianello P, Saliez A, Bufkens X, Pettinger R, Misseleyn D, Hori S and Malfroy B (1996): EUK-134, a synthetic superoxide dismutase and catalase mimetic, protects rat kidneys from ischemia-reperfusion-induced damage. *Transplantation*; 62 (11): 1664-6.
- Henry TZ (1974): *Determination of serum creatinine. Clinical Chemistry Principles and techniques*; sec. Ed., Harper and Row publisher. New York.
- Iheanacho EN , Stocker R. and Hunt NH (1993): Redox metabolism of vitamin C in blood of normal and malaria- infected mice. *Biochim Biophys Acta* ; 1182(1):15-21.
- Kim, M.J.; Lee, S.J.; Park, C.S.; Son, H.Y.; Jun, M.H.; Jeong, S.M. and Kim, M.C.(2007):Attenuation of renal ischemia-reperfusion injury by antioxidant vitamins in pigs. *Journal of Vet. Clinics*, 24 (2): p.94-98.

- Kneko JE, Harvey WJ and Bruss LM (1997): Clinical Biochemistry of Domestic Animal. Fifth ed., Academic Press Sandiego, California, USA.
- Lee JI, Son HY and Kim M C (2006): Attenuation of ischemia-reperfusion injury by ascorbic acid in the canine renal transplantation. *J Vet Sci.*; 7(4):375-9.
- Lieberthal W and Levine JS (1996): Mechanisms of apoptosis and its potential role in renal tubular epithelial cell injury. *Am J Physiol* ; 1(32): 477-88.
- Loong, C.C.; Chng, Y.H.; Wu, T.H.; King, K.L.; Yang, W.C.; Wu, C.W. and Lui, W.Y. (2004): Antioxidant supplementation may improve renal transplant function: A preliminary report. *Transplantation Proceedings*, 36: 2438-2439.
- MacDonald-Wicks LK. and Garg ML (2003): Vitamin E supplementation in the mitigation of carbon tetrachloride induced oxidative stress in rats. *J Nutr Biochem*; 14(4):211-8.
- Mathews KG and Gregory C R (1997): Renal transplants in cats: 66 cases (1987-1996). *J Am Vet Med Assoc.*; 211(11):1432-6.
- Patton CJ and Crouch SR (1977): Estimation of blood urea nitrogen. *Anal.Chem.* 49: 464-489.
- Rhoden EL, Rhoden CR, Lucas ML, Pereira-Lima L, Zettler C. and Bello-Klein A (2005): The role of nitric oxide pathway in the renal ischemia-reperfusion injury in rats. *Transpl Immunol.*; 10(4): 277-284.
- Saito, M. and Miyagawa, I. (2000): Renal time monitoring of nitric oxide in ischemia reperfusion injury rat kidney. *Urol. Res.* 28:141-146.
- Sakarya M, Eris F, Derbent AB, Koca U, Tuzuns S, Onat T, Veral A. and Moral AR (1999): The antioxidant effects of vitamin C and vitamin E. on antioxidant stress. *Clin. Intensive Care*; 10, 245-250.
- SAS (2002): SAS/STAT and user guide . SAS Institute INC, Car , NC , 27513, USA.
- Shimizu MH, Araujo M, Borges SM, de Tolosa EM and Seguro A C (2004): Influence of age and vitamin E on post-ischemic acute renal failure. *Exp Gerontol*; 39 (5): 825-30.
- Sies H . (1997): Oxidative stress: oxidants and antioxidants. *Exp Physiol* , 82 (2):291-5.
- Sumien N , Forster MJ . and Sohal R S (2003): Supplementation with vitamin E fails to attenuate oxidative damage in aged mice. *Exp Gerontol* 38(6):699-704.
- Sunderman FW Jr and Sunderman FW (1958): *Am. J. Clin. Pathol.* 29:95.
- Thadhani R, Pascual and Bonventre JV (1996): Acute renal failure. *N Engl J Med.*; 334(22):1448-60.
- Trinder P (1951): *Analyst*, 76:596.
- Troncoso P , Ortiz AM , Dominguez J and Kahan B D (2005): Use of FTY 720 and ICAM-1 antisense oligonucleotides for attenuating chronic renal damage secondary to ischemia-reperfusion injury. *Transplant Proc. Trans Proc* ; 37(10):4284-8.
- Unal D, Yeni E, Erel O, Bitiren M and Vural H (2002): Antioxidative effects of exogenous nitric oxide versus antioxidant vitamins on renal ischemia reperfusion injury. *Urol Res*; 30(3):190-4.
- Walter J.B. and Isreal M.S. (1987): *General pathology*. 6th Ed. Churchill Livingstone Edinburgh London Melbourne and New York.
- Weight SC , Bell PR and Nicholson ML (1996): Renal ischaemia- reperfusion injury. *Br. J. Surg.* ; 83(2):162-170.

- Weight, S.C.; Furness, P.N. and Nicholson, M.L.(1998):
New model of renal warm ischemia -reperfusion injury
for comparative functional , morphological and patho-
physiological studies. Br. J. Surg. ,85:1669-1673.
- Weight, S.C.; Waller, J.R. Bradley, V. Whiting, P.H. and
Nicholson, M.L. (2001): Interaction of eicosanoids
and nitric oxide in renal reperfusion injury. Transplan-
tation . 72: 614-619.
- Yoder J, Adams E C and Free A H (1965):Simultaneous
screening for urinary occult blood, protein, glucose and
PH. Am J Med Tech; 31: 285.
- Zijlstra, N.C (1960): Estimation of hemoglobin. Clin.
Chem. Acta., 5:719.

كفاءة فيتامين هـ وحمض الأسكوربيك في مجابهة الضرر الناجم عن اندفاع الدم للكلى بعد الاسكيمية فى كلاب التجارب

عصام مصباح* ، نصر عبدالوهاب محمد نصر الدين

* قسم الجراحة والتخدير والأشعة – كلية الطب البيطرى – جامعة المنصورة
قسم الباثولوجيا الأكلينيكية – كلية الطب البيطرى – جامعة الزقازيق

أظهرت الدراسات ان إصابة الكلى بالاسكيمية (فقر الدم موضعى) هو سبب رئيسي من أسباب الضرر الكلوي الحاد في كل من الكلى الطبيعية او التى يتم زراعتها. وفى هذه التجربة تم احداث اسكيمية كلوية لمدة ٤٥ دقيقة مع استئصال الكلى اليمنى لعدد ستة عشر من ذكور الكلاب الاصحاء . قسمت تلك الكلاب بالتساوي إلى ٤ مجموعات. المجموعة الاولى تركت بدون علاج والمجموعة الثانية تم اعطاؤها فيتامين هـ (٢٠مجم/كجم من الوزن/يوم) والثالثة تم اعطاؤها حمض الاسكوربيك (٣٠مجم/كجم من الوزن/يوم) والرابعة عولجت بفيتامين هـ مع حمض الاسكوربيك لمدة أسبوع واحد ابتداء من قبل العملية بيوم . وتم أخذ عينات من الكلى اليسرى في جميع المجموعات.

وقد اظهرت النتائج عن وجود زيادة معنوية فى الكرياتينين واليوريا والبوتاسيوم مع نقص فى الصوديوم ومعدل التخلص من الكرياتينين في كل المجموعات بالمقارنة بالقيمة الابتدائية لكل مجموعة. وقد وجد ان البول يحتوى على بروتين ودم الى جانب اسكرانيات بروتينية وخلوية فى المجموعة الغير معالجة. أظهرت المجموعتان (٢ & ٣) تحسن ضعيف في حين أنه حدث تحسن لبعض التلف الناجم عن الاسكيمية فى المجموعة الرابعة. ميكروسكوبيا أظهرت المجموعة الاولى وجود تتركز منتشر فى الخلايا الكلوية مع وجود بعض الاسكرانيات داخل جدار الانابيب الكلوية. وقد وجد فى المجموعة الثانية تغيرات تنكسية ونخرية متوسطة لبعض الخلايا الطلانية المبطنة لبعض الانابيب الكلوية مصاحبا بانكماش فى بعض الكوبيبات الكلوية وانتشار للخلايا البيضاء. وأظهرت المجموعة الثالثة تجمعات لخلايا الدم البيضاء حول الكوبيبات الكلوية تتكون معظمها من الخلايا الليمفاوية مع تفصص لبعض الكوبيبات الكلوية والعديد من التغيرات التنكسية أو النخر المخثر. و اظهرت المجموعة الرابعة ان معظم الانابيب الكلوية تعانى من تنكس خزبى وتورم غيمى وبعض الانابيب الكلوية أظهرت تغيرات نخرية مع غياب بعض الانوية .

ومن هنا يمكن أن نستخلص أن الجمع بين فيتامين هـ (هـ) وحمض الاسكوربيك احدث تحسن جزئيا لحالة فقر الدم الموضعى للكلى.