

Animal Health Research Institute,  
Shalatin Regional lab.

**SARCOCYSTIS INFECTION IN SHEEP AND GOATS  
SLAUGHTERED IN SHALATIN ABATTOIR, RED SEA  
GOVERNORATE, EGYPT**  
(With 7 Tables and 2 Plates)

By

**O.M. MAHRAN**

(Received at 2/3/2009)

الإصابة بالساركوسست في الأغنام والماعز المذبوحة بمجزر شلاتين  
محافظة البحر الأحمر \_ مصر

عثمان محمد مهران

تم جمع عينات نسيجية شملت كلا من المرئ، الحجاب الحاجز، اللسان، القلب والعضلات بين الضنوع من ٥٥٥ من الأغنام و٣٧١ من الماعز ذبحت بالمجزر بمنطقة الدراسة وفحصت لاستبيان الإصابة بأنواع الساركوسست وذلك باستخدام الفحص المرئي والمجهري. من هذا العدد، ٢٢٩ (٤١,٢٦%) في الأغنام و١٣٧ (٣٦,٩٢%) في الماعز كانت إيجابية لحويصلات الساركوسست. ووجدت كلا من الحويصلات المرئية والمجهريه. كانت نسبة انتشار الحويصلات المرئية (٧,٥٤% ، ٩,٩%) في الأغنام والماعز علي التوالي وتراوحت شدة الإصابة بها من ١- ٣٥ حويصلة للذبيحة. وأسفر الفحص الظاهري علي التعرف علي نوع واحد من الحويصلات المرئية اعتمادا علي الاختلاف في حجم وجدار الحويصلة وتميزت بأنها حويصلة بيضاوية كبيرة ذات جدار سميك ويعرف هذا النوع بالساركوسست جاجنتيا. أما الحويصلات المجهريه فقد وجدت في (٨١,٨ و ٨٠,٣٣%) في الأغنام والماعز علي التوالي، تراوحت شدة الإصابة بهذه الحويصلات من ٣ إلي ١٣ إلي ٢٥ للعضلة. وتم التعرف علي نوعين من الحويصلات المرئية اعتمادا علي الاختلاف في شكل جدار الحويصلة وكانت حويصلات الساركوسست في الأغنام ذات جدار ناعم رقيق ووجت بنسبة ٨١,٠٨% ويتراوح طولها من ٨ ، ٣٤ إلي ٥٨٠ ميكرون وعرض الجدار ١,٦ الي ٢,٤ ميكرون ويعرف هذا النوع بالساركوسست تينلا. أما الحويصلات في الماعز فكانت ذات جدار سميك ووجدت في ٨٠,٣٣% وكان طولها يتراوح من ٩٢ إلي ٦٨٠ ميكرون وعرض الجدار حوالي ٣,٢ إلي ٣,٧ ميكرون ويعرف هذا النوع بالساركوسست كابرلي كانز. كان معدل الإصابة بالساركوسست أكثر شيوعا في المرئ مقارنة بالأعضاء الأخرى في كلا النوعين، وكانت الإصابة اعلي في الأعمار الأكثر من سنة (٤٧,٩٦ ، ٦٤,٩٦%) عنها في الأعمار اقل من سنة (٣٠,٥٦ & ٢٥,٢٠%). وكان معدل الإصابة اعلي في الإناث (٥٤,٨٦ & ٤٦,٨٤%) عن الذكور (٣٧,٧٨ & ٣٢,٦٩%). وأن معدل الإصابة اعلي في فصل الشتاء مقارنة بفصول السنة الاخرى. هذه أول دراسة تسلط الضوء علي أنواع

الساركوسست في هذه المنطقة النائية. وان الإصابة بالساركوسست شائعة في الخراف والماعز بمنطقة شلاتين. وبما أن الخراف والماعز يلعبان دوراً مهماً في اقتصاد هذه المنطقة الصحراوية، فإن تأثير العدوى بالساركوسست في هذا النوع من الحيوانات يحتاج إلى المزيد من الاهتمام. وأيضاً وأوضحت هذه الدراسة أن هناك عوامل مثل العمر والجنس ونوع الحيوان وكذلك الأعضاء ساهمت بوضوح في معدل الإصابة.

## SUMMARY

Tissue samples comprising the oesophagus, diaphragm, tongue, heart and intercostal muscles were collected from 555 sheep and 371 goats slaughtered at the abattoirs in the study area. and examined for infections with *Sarcocystis* spp. using macroscopic and microscopic methods of detection. Out of this number, 229 (41.26%) were positive for *Sarcocystis* cysts in sheep and 137(36.92%) in Goats. Macroscopic and microscopic sarcocysts were seen. Macroscopic cysts were found in (9.9% & 7.54%) of the sheep and goats respectively, ranging in intensity from 1 to 35 cysts per carcass. Morphometric studies detected one type of macroscopic cysts which differed in their size and cyst wall morphology. Large ovoid cysts have thick primary cyst walls were identified as *S. gigantea* (syn. *S. ovifelis*). In comparison, microscopic cysts were detected in (81.8% to %80.33%) in sheep and goats respectively. Calculations of the intensities of infection ranged from 3 to 13 to 25 cysts per unit volume of muscle. Sarcocysts in sheep have smooth thin walls, measured 34.8 to 580  $\mu$  lengthwise and the cyst-wall 1.6- 2.4  $\mu$  They were identified to be *Sarcocystis tenella* (*S. ovis*). The cysts in goats measured 92 to 680  $\mu$  and the cyst – wall 2.3 - 3.7 $\mu$ . They were identified as *Sarcocystis capracanis*. In both animal species, the sarcocysts were more frequent in the oesophagus compared to the other organs. Animals more than a year old were infested more frequently (46.96 & 47.96%) than those younger than a year old (30.56 & 25.20%). The females had a higher rate of infestation (54.86 & 46.84%) than males (37.78 & 32.69%). Infection reached peak in winter season compared to other seasons. This is the first study to throw light upon *Sarcocystis* species of sheep and goats in this area. *Sarcocystis* infection was shown to be common in sheep and goats in Shalatin area. Since the sheep and goats play an important role in the economy of this desert area. The impact of *Sarcocystis* infection in these animal species needs further attention. Also, this study shows that factors such as age, gender, animal type and involved organ contribute to the frequency infestations.

**Key words:** *Sarcocystis* sheep, goats at Shalatin

## INTRODUCTION

*Sarcocystis* infections of animals are commonplace and of worldwide distribution. Some species can be severely pathogenic to farm animals, causing anorexia, weight-loss, abortion and even death. But perhaps because sarcocysts are so common they have frequently been regarded as innocuous. Many cases of abortion in farm animals go undiagnosed, and it is only now that Sarcocystosis is being implicated as potentially of economic importance to the farm industry (Dubey *et al.*, 1988). In many cases however, the major effect is likely to be subclinical, seen in farm animals only as a reduction in live weight gain (Herbert and Smith, 1987). Sarcocystosis is a zoonotic disease in domestic animals caused by *Sarcocystis* spp., a cyst-forming coccidian parasite with obligatory two-host life cycle involving carnivorous as definitive hosts and herbivorous or omnivorous as intermediate hosts. Each intermediate and definitive host may harbor more than one *Sarcocystis* species (Dubey *et al.*, 1989). Some species of *Sarcocystis* can cause a reduced weight gain, poor feeding efficiency, anorexia, fever, anemia, muscle weakness, reduced milk yield, abortion, and death of intermediate hosts such as cattle, sheep and goats. Anemia, anorexia, ataxia, and abortions are the chief clinical signs of acute ovine sarcocystosis (Dubey, 1976). Certain species can infect humans and can cause digestive disturbances such as nausea vomiting, and diarrhea (Rommel, 1989). Recent studies, however, have shown that muscular Sarcocystosis is a bigger problem than previously thought. (Dubey *et al.*, 1989). *Sarcocystis* is found mainly in striated muscles where it causes myositis, degenerative changes, atrophy and death in their hosts (Levine, 1986). (Harness *et al.*, 1999) mentioned that infection of the intermediate host causes a loss of appetite, fever, weight loss, anemia, and death in severe infections. It also causes gait abnormalities, weakening of the limbs, muscle wasting, and head tilt. The animal may also move in circles. The number of clinical signs that appear is proportional to the number of *Sarcocystis* organisms parasitizing the host (Dubey *et al.*, 1988). Humans might become accidental intermediate hosts for a number of species of *Sarcocystis* (*S. bovi-hominis* and *S. suil-hominis*) and the infection is acquired in human by eating insufficiently cooked meat. This work presents the results of the first study on the prevalence of *Sarcocystis* infection in this remote area in sheep and goats, identify the species and

describe the morphological characters, besides the influence of age, gender and seasons on the infection rate of *Sarcocystis* was also studied.

## **MATERIALS and METHODS**

### **Animals**

During December 2007 to November 2008 a total of 926 animals comprised of 555 sheep and 371 goats belonging to both gender and different ages slaughtered at Shalatin abattoir were investigated for the presence of *Sarcocystis* in muscular tissues. Age and gender of the Investigated animals were assessed by visual inspection of teeth, horns, and sexual organs.

### **Samples:**

The oesophagus, diaphragm, tongue, heart and intercostal muscles were chosen for inspection and collection of samples, immediately after the animals were slaughtered, the freshy tissues were labeled separately, put in ice box, brought to the laboratory and were kept at 4°C until further examination.

**Macroscopical examination:** each sample was examined by naked eye for detection of macroscopic cysts. Oesophagus was thoroughly washed in running tap water to expel the ingesta present in the lumen. The superficial, fat and connective tissue were removed. Each oesophagus was thoroughly searched for the presence of (Macro cysts) in the musculature. Special effort was made to detect the small-sized sarcocysts that might have been embedded deeply in the tissue by ballooning out the oesophagus by filling it with water and then examining against a strong light (Saleque *et al.*, 1992).

**Microscopical examination:** the samples found negative on gross examination were examined microscopically by 1- crush technique: About 2 g of tissue was cut into small pieces, approximately 3–5mm thick, and crushed firmly between two glass slides and examined under the microscope (40 x) (Mohanty *et al.*, 1995). For detection of liberated trophozoites: homogenization of muscle samples was done with physiological saline (Ali, 1985). The intensity of infection in muscles from different parts of individual animals was recorded as number of microcysts present in 2g of muscles examined. The intensity of infection was considered as light (+), moderate (++) and heavy (+++) depending upon the presence of 1-10 cysts, 11-20 cysts and 20 or more cysts per 2g of muscles respectively (Dayashank and Bhatia, 1993).

**Histomorphological examination:** muscular samples sized approximately 15 mm x 10mm with or without macroscopically visible sarcocysts were cut from each of the muscular tissues mentioned. The samples were fixed in neutral buffered 10% formalin, processed by standard histological techniques, sectioned at 5 mm, stained by haematoxylin and eosin, and examined by light microscopy for the presence of sarcocysts, (Bancroft and Stevens, 1993). The differentiation between the microscopic species was based on the morphological criteria described by (Levine, 1985) and (Dubey *et al.*, 1989)

## RESULTS

Combination of ocular and histological examination revealed that 229 (41.26%) of 555 sheep and 137 (36.92%) of 371 goats had sarcocysts of at least one species described in sheep and goats (Tables 1 & 2). The prevalence of macroscopic and microscopic sarcocysts in slaughtered sheep and goats, is shown in table (2). Macroscopic cysts were found in (9.9% to 7.54%) of sheep and goats respectively. Morphometric studies detected one type of macroscopic cysts which differed in their size and cyst wall morphology. Cysts appeared as large ovoid cysts with thick primary cyst walls, milky-white colored embedded in the muscular tissues and their length ranged from 4 to 6 mm, ranging in intensity from 1 to 35 cysts per carcass. They were identified as *S. gigantea* (*syn. S. ovifelis*) plates 1 (1&2). Microscopic cysts were detected in 81.8% to 80.33% in sheep and goats respectively. Calculations of the intensities of infection ranged from 3 to 13 to, 25 cysts per unit volume of muscle. Two types of microscopic cysts were also identified on the basis of their cyst wall morphology. Cysts having smooth thin walls were detected in 81.8% of the sheep measured 34.8 to 580  $\mu$  lengthwise and the cyst-wall 1.6- 2.4  $\mu$ , appeared to conform to the original descriptions of *S. tenella* (*S. ovicanis*) plate 2 (3&4), whereas cysts, with radially-striated thick walls were found in 80.33% of the goats measured 92 to 680  $\mu$  and the cyst – wall 2.3 - 2.7  $\mu$  appeared to conform to the original descriptions *S. capracanis* plate 2 (5). Concerning the prevalence of *Sarcocystis* spp. in different muscular tissues and Intensity of infection amongst positive cases in sheep and goats, oesophagus showed the highest rate (71.17 & 67.38) and heart the lowest (38.7% & 41.23%) in sheep and goats respectively. (tables 3&4). In both males and females animals the prevalence of *Sarcocystis* infection increased with age (Tables 5&6). Overall, the prevalence of

infection was lowest in animals below a year old (30.56 & 25.20) and highest in animals more than a year old (46.96 & 47.96%) in sheep and goats respectively. The female animals had a higher rate of infestation than males (37.78%-54.86%) and (32.69%-46.84%) in sheep and goats respectively (Tables 5&6). The seasonal prevalence of sarcocysts in sheep and goats examined in the present study has been shown in (table 7). It's evident from the tables that the infection was prevalent throughout the year under study with the highest rate in winter season and lowest in summer seasons.

**Morphological studies:**

**Macroscopic cyst:** Cysts were found in (9.9% to 7.54%) of the sheep and goats respectively, ranging in intensity from 1 to 35 cysts per carcass. cysts found as ovoid cysts resemble, grains of rice with thick primary cyst walls as grayish to whitish streaks, in color 4-6 mm in length, running lengthwise with the muscle fibers. They were identified as *S. gigantea* (syn. *S. ovifelis*). A mature cyst, 350  $\mu$  in length, up to 0.5 mm long and a secondary cyst wall was present plate(1).

**Microscopic cysts:**

**In sheep:** Cysts were detected in (81. 8%) of sheep as cylindrical or fusiform, with tapering ends,. They consist of a delimiting membrane from which trabeculae pass inwards, and are filled with spores. The spores are more mature towards the center of the cysts. The sarcocysts measured 34.8 to 580  $\mu$  lengthwise and with smooth thin cyst walls measuring 1.6- 2.4  $\mu$ . The cystozoites in mature *sarcocystis*, were banana shaped and measured 13.0-15.0  $\mu$ m by 3.6-6.0  $\mu$ m in size. Such cysts were described as *S. tenella* (*S. ovicanis*) plate 2 (3&4).

**In goats:** Cysts were detected in (80.33%). Sarcocysts showed thick wall with radial striations and finger like projections, mostly elongate, slender or spindle shaped with one or both ends tapering. The cysts in goats measured 92 to 680  $\mu$  and the cyst-wall was thick measuring 2.3-2.7  $\mu$ . Oval metrocytes were seen measuring 7.3-11.2  $\mu$ m $\times$ 4.3-7.0  $\mu$ m. Bradyzoites were banana shaped and measured 8-12.3  $\mu$ m septa were seen dividing the sarcocyst cavity into a number of compartments such cyst was described as *S. capracanis* plate 2 (5).

**Table 1:** Prevalence of *Sarcocystis* infection in sheep and goats examined 4.

	No. examined	No. Infected animals	No. of positive%		
			Macroscopic cysts	Microscopic cysts	Mixed infection
Sheep	555	229 (41.26%)	55 (9.9%)	450 (81.8%)	55 (9.9%)
Goats	371	137 (36.9%)	28 (7.54 %)	298 (80.33%)	28 (7.54 %)

**Table 2:** Prevalence of macroscopic cysts in sheep and goats according to organs examined

No. of Animal examined	No. Positive (%)	Esophagus	Diaphragm.	Heart	Tongue	Intercostals muscles
Sheep (555)	55 (9.91)	45 (81.81)	7(12.72%)	3 (5.45%)	-	-
Goats (371)	28 (7.54)	17 (60.71%)	7 (25%)	4 (14.29%)	-	-

**Table 3:** Prevalence of *Sarcocystis* spp. in different muscular tissues of sheep ( $n = 555$ ) and Intensity of infection amongst positive cases

Organs	No. of samples of organs / tissues examined.	No. of organs / tissues positive	(% of <i>S. tenella</i> found amongst positive case	(Intensity of infection) average no. cysts per 10 microscope fields in positive cases		
				+(%)	++(%)	+++ (%)
Esophagus	555	395	71.17	325(82.28%)	40(10.13%)	30(7.59%)
Diaphragm	555	305	54.95	260(85.25%)	27(8.85%)	18(5.9%)
Heart	555	205	36.94	178(86.83%)	15(7.32%)	12(5.85%)
Tongue	555	270	48.65	240 (88.89%)	21(7.79%)	9(3.33%)
Intercostals muscles	555	226	40.72	201(88.94%)	18 (7.96%)	7(3.093%)
Total	2775	1401	50.49	1204(85.94%)	121(8.64%)	76(5.42%)

**Table 4:** Prevalence of *Sarcocystis* spp. in different muscular tissues of goats ( $n = 371$ ) and Intensity of infection amongst cases positive.

Organs / tissues Examined	No. Of samples organs / tissues examined.	No. Of organs / tissues positive	% Of <i>S. capracanis</i> found amongst positive case	(Intensity of infection) average no. cysts per 10 microscope fields in positive cases		
				+(%)	++(%)	+++ (%)
Esophagus	371	250	67.38	210(84%)	28(11.2%)	12(4.8%)
Diaphragm	371	197	53.09	166(84.26%)	22(11.16%)	9(4.57%)
Heart	371	153	41.23	135(88.23%)	12 (7.84%)	6(3.92%)
Tongue	371	185	49.87	162 (87.57%)	16 (8.65%)	7(3.78%)
Intercostals Muscles	371	170	45.82	146(85.88%)	16(9.41)	8(4.7%)
Total	1855	955	51.48	819(83.76%)	94(9.84%)	42(4.4%)

**Table 5:** Distribution of sheep infected with *S. tenella* according to age and gender at Shalatin area.

Gender	Animal examined	Below one year	Above one year	Total
Male	No. Exam.	145	297	442
	No. Positive	40	127	167
	Percentage	27.58	42.76	37.78
Female	No. Exam.	48	65	113
	No. Positive	19	43	62
	Percentage	39.58	66.15	54.86
Total	No. Exam	193	362	555
	No. Positive	59	170	229
	Percentage	30.56	46.96	41.26

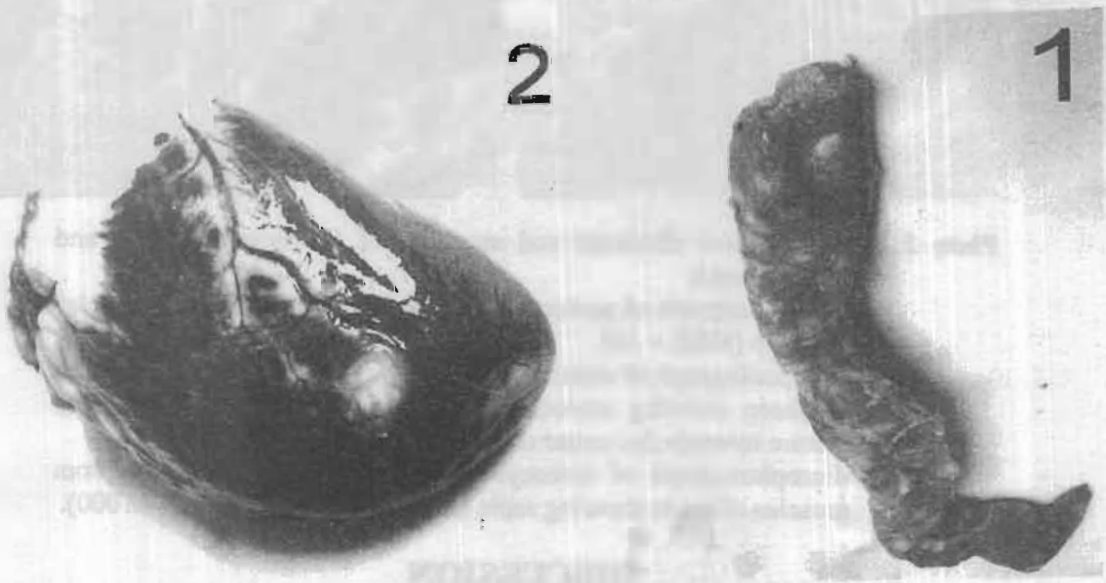
**Table 6:** Distribution of goats infected with *S. capracanis* according to age and gender at Shalatin area.

Gender	Animal examined	Below one year	Above one year	Total
Male	No. Exam.	75	185	260
	No. Positive	14	71	85
	Percentage	18.66	38.37	32.69
Female	No. Exam.	48	63	111
	No. Positive	17	35	52
	Percentage	35.41	55.55	46.84
Total	No. Exam.	123	242	371
	No. Positive	31	106	137
	Percentage	25.20	42.74	36.92



**Table 7:** Seasonal variation of *Sarcocystis* infections in sheep and goats

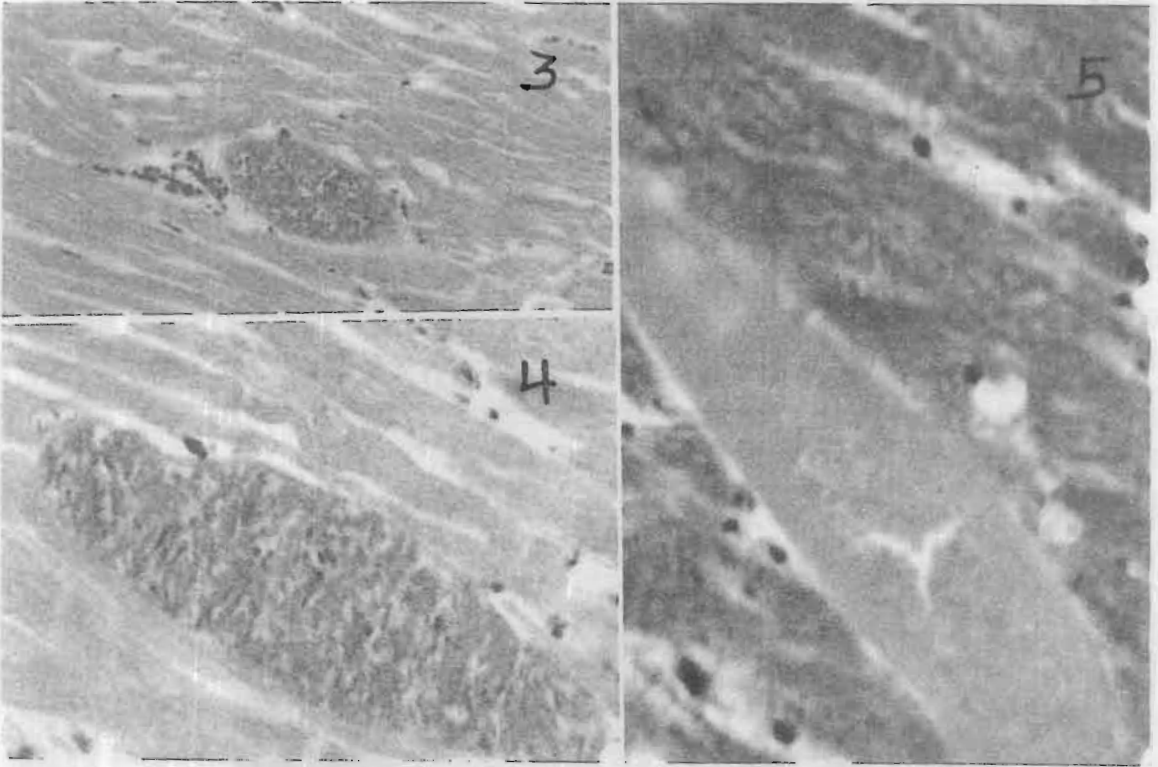Seasons	No. Of exam. Animals		No. Of infected cases		Percentage of infection	
	Sheep	Goats	Sheep	Goats	Sheep	Goats
Winter	165	121	95	58	57.57	47.93
Spring	146	94	60	37	41.09	39.36
Summer	116	81	38	17	32.75	20.98
Autumn	128	75	36	25	28.12	33.3
Total	555	371	229	137	41.26	36.92



**Plate 1:** Morphological characters of visible sarcocysts

1- Grossly visible sarcocysts the oesophagus muscle of sheep.

2- Grossly visible sarcocysts in heart muscle of goats



**Plate 2:** Morphological character and structure of *Sarcocystis tenella* and *S. capracanis*

- 3- Microphotograph of sarcocysts of *Sarcocystis tenella* from muscles of sheep (H&E  $\times$  10).
- 4- Microphotograph of sarcocysts of *Sarcocystis tenella* from muscles of sheep showing smooth cyst thin walls and spores are more mature towards the center of the cysts. (H&E  $\times$  40).
- 5- Microphotograph of sarcocysts of *Sarcocystis capracanis* from muscles of goats showing septa and thick cyst wall (H&E  $\times$  1000).

## DISCUSSION

The current study revealed that (41.26%) and (36.92%) out of 555 sheep and 371 goats carcasses screened carried *Sarcocystis* infection respectively, this is compatible with the report of (Saha and Ghosh, 1992) and (Abo- Shehada, 1996) in Jordan. Our results was lower than that recorded by Dubey *et al.* (1989) in United States, Latif *et al.* (1999) in

Iraq and Nedjari (2003) in Algeria who reported that the rate of infection was (91.6%), (100%), (97-97.4%) and (64%) in sheep and goats respectively. The difference in prevalence rate of sarcocysts might be due to different factors like discontinuation of life cycle, management condition, living of stray dogs and cats with livestock and habits of definitive and intermediate hosts (Masoud *et al.*, 2007). In the present study macro-sarcocysts and micro- sarcocysts were encountered in sheep and goats, agreeing with Abo-Shehada (1996) in Jordan, Latif *et al.* (1999) and Barham *et al.* (2005) in Iraq, Al- Hoot *et al.* (2005) in Saudi Arabia and Daryani *et al.* (2006) in Iran. disagreeing with the finding of Pethkar and Shah (1983), Hussein and Warraq (1985), Kudi *et al.* (1991) and Mohanty *et al.* (1995), who reported micros-sarcocysts only. The high prevalence rate of microscopic sarcocysts (81.08% & 80.32%) in sheep and goats indicates the importance of the infection for the intermediate host. Fayer and Dubey (1986) reported that the rate of infection with micro-sarcocysts reached 100% in sheep in the United States and Ginawi and Shommein (1977) in Sudan reported (91.6%) in goats. The low frequency of macroscopic sarcocysts (9.9 & 7.54%) in the present study, compared with the prevalence of microscopic sarcocysts (81.08% & 80.32%) may be due to the fact that such cysts are of feline origin and the contact between farm animals and cats is rare as the farmers do not keep cats Latif *et al.* (1999) in Iraq and Al-Hoot *et al.* (2005) in Saudi Arabia reported low incidence of macroscopic cysts compared with microscopic cysts was between (0-33.6%) in Iraq and (8 to 18%) and (73 to 85%) in Saudia Arabia. Two types of micro-sarcocysts were differentiated on the basis of their morphology *Sarcocystis tenella* in sheep and *S. capracanis* in goats. *S. tenella* is thought to be the most pathogenic of the *Sarcocystis* species in sheep. It can cause anorexia, fever, decreased weight gain, anemia and death in experimentally infected lambs, and has been associated with abortions in ewes. Neurologic signs including encephalomyelitis, muscle weakness, hind limb paresis and ataxia have been seen in naturally infected sheep. After recovery from the acute illness, some sheep may lose their wool. Acute deaths can also occur without other symptoms (Fayer and Dubey, 1986). Macroscopic sarcocysts of *S. gigantea* were also found in sheep and goats. This is compatible with the report of Dubey *et al.* (1989), Abo-Shehada (1996) in Jordan, Latif *et al.* (1999) and Barham *et al.* (2005) in Iraq and Al- Hoot *et al.* (2005) in Saudi Arabia. The morphology of *Sarcocystis* species in the present study, was comparable to the description given by Munday and Obendorf (1984), Odonoghue

and Ford (1986), Dayashank and Bhatia (1993) and Dubey *et al.* (1988). Concerning the prevalence of *Sarcocystis* spp. in different muscular tissues and intensity of infection amongst positive cases in sheep and goats tables (3 & 4) revealed that maximum sarcocysts were found in the muscles of oesophagus in sheep and goats. Saha and Ghosh (1992), Huong and Uggla (1999), Latif *et al.* (1999) and Jumde *et al.* (2000) made similar observation. Oesophagus musculature appeared as more favorable site of *Sarcocystis* infection Fayer and Dubey (1986). The severity of clinical signs that appear is proportional to the number of *Sarcocystis* cysts parasitizing the host (Dubey *et al.*, 1989). Our study revealed a heavy intensity of *Sarcocystis* species in the muscles of oesophagus followed by those in diaphragm, tongue, intercostal muscles and heart. Fewer reports on this aspect were recorded by Shastri (1990) who counted (67) cysts in 20g of a muscle piece of diaphragm and Dayashank and Bhatia (1993) recorded highest number of cysts in 2g of a muscles pieces of oesophagus and diaphragm. In the present study, there was a seasonal variation in percentage of positive cases reaching the peak in winter and lowest in Summer. The high incidence in winter may be due to the high humidity and easy dissemination of sporocysts shed by definitive host. Humidity is favorable for the spread and survival of sporocysts and there are more chances of contamination of food and water (Masoud *et al.*, 2007). The low prevalence of positive cases in Summer seasons may be attributed mainly to the high temperature and reduced humidity preventing the dissemination of sporocysts by drying the faeces (Mohanty *et al.*, 1995). These results agree with the results of Pethkar and Shah, (1983) and Singip *et al.* (1992) who recorded that the highest rate of positive cases was found in Winter and lowest in Summer, disagreeing with the finding of Talari *et al.* (2003) who reported that seasons of the year have no influence on the percentage of infection. The season –wise incidence of sarcocystis varied from place to place as it mainly depended upon the geoclimatic condition of the region and close proximity between definitive host and intermediate host (Singip *et al.*, 1992). The incidence of infection was found to increase with age. The overall prevalence of *Sarcocystis* was the lowest in animals below a year old and highest in above a year old, thereby indicating a positive correlation between the prevalence rate and age of animals, which may be explained by the fact that the adults pick up over a long period and more exposure to infective grazing field (Mohanty *et al.*, 1995) whereas the younger animals remain mostly confined to the shed and thus do not get more chances to pick up infection, also younger

animals usually are not sent for grazing they may remain with their mother and are sometimes stall-feed up to 2 months of age. Biswas *et al.* (1990), Mohanty *et al.* (1995) and Abo-Shehada (1996), observed that higher incidence of infection was recorded in older animals and lower prevalence in younger animals. Observation on the variation due to gender on prevalence of sarcocysts infection in sheep and goats indicated that the incidence was comparatively higher in females than in males, which correlates with the observation of Rommel (1985) and Mohanty *et al.* (1995).

## REFERENCES

- Abo-Shehada M.N., (1996):* Age variations in the prevalence of sarcocystosis in sheep and goats from northern and central Jordan. *Prev. Vet. Med.* 27: 135-140.
- Al-Hoot, A.S.; Al-Qureishy, S.A.; Al-Rashid, K. and Bashtar, A.R. (2005):* Microscopic study on *Sarcocystis moulei* from sheep and goats in Saudi Arabia. *Journal of the Egyptian Soci. of Parasitol.* 35: (1) 295-312
- Ali, G.A.T. (1985):* Studies on *Sarcocystis* of animals in Assiut Governorate. M.V.sc. Thesis, Fac. of Vet. Med., Assiut Univ.
- Bancroft, J.D. and Stevens, A. (1993):* Theory and practice of Histological Techniques, 3rd Ed. Long Man Group Limited.
- Barham, M.; Sttzer, H.; Karnnis, P.; Latif, B.M. and Neiss, W.F. (2005):* Seasonal variation in *Sarcocystis* species infections in goats in Northern Iraq. *Parasitol.*, 130: 151-156.
- Biswas, S.; Chakrabarti, A. and Roy, S. (1990):* *Sarcocystis* infection in buffalo meat (Carabeef) in West Bengal. *J. Vet. Anim. Sci.*, 21, 29-31.
- Daryani, A.; Alaei, R.; Dehghan, M.H.; Arab, R.; Sharif, M. and Ziaei, H. (2006):* Survey of *Sarcocystis* Infection in Slaughtered sheep and Buffaloes in Ardabil, Iran. *Journal of Animal and Veterinary Advances* 5 (1): 60-62.
- Dayashank, A.R. and Bhatia, B.B. (1993):* *Sarcocystis* infection in goats in Uttar Pradesh. *Indian J. of animal Sci*, 63 (3) 248- 287.
- Dubey, J.B. (1976):* A review of *Sarcocystis* of domestic animals and other coccidians of cats and dogs *J. Am. Vet. Med. Assoc.* 15169 (10): 1061-78.

- Dubey, J.P.; Lindsay, D.S.; Speer, C.A.; Fayer, R. and Livingston, C. W. (1988): Sarcocystis rieticanis and other Sarcocystis species in sheep in the United States. J. Parasitol. 74(6): 1033-1038.*
- Dubey, J.P.; Speer, C.A. and Fayer, R. (Eds.). (1989): Sarcocystosis of Animals and Man. CRC Press, Inc., Florida, Trop. Anim. Health Prod. (215). 62-78.*
- Fayer, R. and Dubey, J.P. (1986): Bovine sarcocystosis. Com. Contin. Educ. Pract. Vet., 8:130-14*
- Ginawi, M.A. and Shommein, A.M. (1977): Prevalence of sarcocystosis in sheep, goats and camels in the Sudan. J. Vet. Sci. Anim. Husb. 18: 92-97.*
- Harness, M.K.; Brown, J.D.; Dubey, J.P.; Neafie, R.C. and Granstrom, D.E. (1999): An outbreak of acute eosinophilic myositis attributed to human Sarcocystis parasitism. Am. J. Trop. Med. Hyg., 61 (4): 548-553.*
- Herbert, L.V. and Smith, T.S. (1987): Sarcocystosis review. Parasitology Today, 3: 16-21.*
- Huong, L.T.T. and Uggla, A. (1999): Sarcocystis dubeyi n. sp. Protozoa: Sarcocystidae) in the water buffalo (Bubalus bubalis). J Parasitol. 8:102-104.*
- Hussein, H.S. and Warraq, M. (1985): Prevalence of Sarcocystis in food animals in the Sudan. Trop. Anim. Health prod., 17(2): 100-112.*
- Jumde, P.D.; Bhojne, G.R.; Maske, D.K. and Kotte, S.W. (2000): Prevalence of sarcocysts in goats at Nagpur. Indian J., 77: 662-668.*
- Kudi, A.C.; Aganga, A.O.; Ogbogu, V.C. and Umoh, J.U. (1991): Prevalence of sarcocystis in sheep and goats in north Nigeria. Rev. Elev. Med. Vet... Pays trop. 44: 59-60.*
- Latif, B.M.A.; Al-Delemi, J.K.; Mohammed, B.S.; Al-Bayati, S.M. and Al-Amiry, A.M. (1999): Prevalence of Sarcocystis spp. in meat-producing animals in Iraq. Vet. Parasitol., 84 (1-2): 85-90*
- Levine, N.D. (1985): Veterinary Protozoology (1st ed.). Iowa State, University press, Ames.*
- Levine, N.D. (1986): The taxonomy of Sarcocystis (Protozoa, Apicomplexa) species. J. Parasitol. 72: 372-382.*
- Masoud, G.; Hossein, H.; Lily, N.; Gholam, H.K. and Mohammad, R.A. (2007): Evaluation of an Elisa for the diagnosis of Sarcocystosis in water buffaloes. Bull Vet Inst Pulawy 51: 229-231.*

- Mohanty, B.N.; Misra, S.C.; Panda, D.N. and Panda, M.R. (1995):* prevalence of Sarcocystis infection in ruminants in Orissa. *Indian Vet.* 72: 1026- 1030.
- Munday, B.L. and Obendorf, D.L. (1984):* Morphology of Sarcocystis gigantea in experimentally-infected sheep. *Vet. Parasitol.* 16: 192-193.
- Nedjari, M. (2003):* The occurrence of animal sarcocystiosis in Algeria. *Berl Munch* 16(3-4): 139-141.
- Odonoghue, P.J. and Ford, G.E. (1986):* The prevalence and intensity of Sarcocystis spp infections in sheep. *Aust. Vet. J.*, 63 (9): 273-278.
- Pethkar, D.K. and Shah, H.L. (1983):* Prevalence of sarcocysts in goats in Madhya Pradesh. *Indian Vet. J.*, 59: 110-11.
- Rommel M. (1985):* Sarcocystosis of domestic animals and humans; In *Practice*, 158–160.
- Rommel, M. (1989):* Recent advances in the knowledge of the biology of the cyst-forming Coccidia. *Angew. Parasitol.*, 30 (3): 173-183.
- Saha, A.K. and Ghosh, D. (1992):* Prevalence of Sarcocystis in black Bengal in goats in Tripura. *Indian Vet. J.*, 69: 82-83.
- Saleque, A.; Bhatia, B.B. and Dayashanker, A.R. (1992):* Prevalence of two species of Sarcocystis in sheep in Uttar Pradesh. *Indian Vet. J.*, 69: 841-842.
- Shastri, U.V. (1990):* Sarcocystis infection in goats in Maharashtra. *Indian Vet. J.*, 67: 70-71.
- Singip, L.A.I.; Mraisinghanf, P.M.; Pathak, K.M.L.; Dkumar, G.S.; Manohar, A.K.; Bhans, J.K.; Arora, and Swarankar, C.P. (1992):* Epidemiology of Sarcocystis capracanis in goats at Bikaner, Rajasthan, India. *Indian J. animal Sci.* 62 (11):1044-1045.
- Talari, S.A.; Momtazmanesh, N.; Rad, E.M. and Talari, M.R (2003):* Prevalence of Sarcosystis spp. at slaughter house of Kashan-Iran. *Uttar Pradesh J. Zool.*, 23 ( 3 ): 197-200