

Some pharmacodynamic interactions between salinomycin and vitamin E or selenium in chickens

S.E. El-Sadek¹, M. A. Tohamy¹, Abeer A. El-Badry², Noha A. M.

Fouad², A. A. M. El-Gendy^{1*}

¹Department of Pharmacology, Faculty of Veterinary Medicine, Beni-Suef University, Beni-Suef 62511, Egypt and ²Animal Health Research Institute, Qena, Egypt.

The present study was conducted to determine the effect of salinomycin at a concentration 60 and 120 ppm alone and with vitamin E or selenium on haematological and biochemical parameters and histopathological changes of the treated chicken. Salinomycin (120 ppm) induced decrease in body weight, feed consumption and feed conversion efficiency. In addition, when salinomycin (120 ppm) given with vitamin E, the body performance improved significantly, but when sodium selenite used, body performance significantly decreased. Salinomycin at concentration 120 ppm induced decrease in blood parameters (RBCs count, TLC count, Hb content and PCV %). Concurrent use of vitamin E with salinomycin leads to improvement of these parameters. Salinomycin at 120 ppm induced significant increase in enzymes activities (ALT and AST). The uses of vitamin E with salinomycin (120 ppm) caused significant decrease in these activities. In contrast to selenium, which reduce the activity of AST enzyme only. Salinomycin at 120 ppm decreased the total protein concentration and increased the level of creatinine and uric acid. Concurrent administrations of vitamin E or selenium with salinomycin have no effect on these parameters. At 120 ppm salinomycin, selenium increased the creatinine concentration in blood serum. The drug at 60 or 120 ppm induced various pathological changes in certain tissues (liver, heart, kidney and skeletal muscle) ranged from degeneration to necrosis of these tissues. Concurrent administration of salinomycin with vitamin E or selenium revealed that vitamin E decreased the pathological changes of studied tissues.

Coccidiosis is among the most important diseases of poultry worldwide caused by a protozoan parasite, *Eimeria*. The parasite invades the cells of the intestine producing enteritis, diarrhoea and mortality. The bird develops a disability to absorb sugars, amino acids, vitamins, fats and minerals through the disruption of the integrity of the intestinal mucosae (Greif, 2000; Persia *et al.*, 2006; Zhao *et al.*, 2006 and Mansoori *et al.*, 2008). In order to prevent, control and/or treat poultry coccidiosis, several coccidiostats and coccidiocidal drugs have been developed and used commercially. The ionophore antibiotics such as lasolocid, maduramicin, monensin, narasin and salinomycin are widely used in poultry for the prevention and treatment of coccidiosis caused by *Eimeria* species (Lindsay and Blagburn, 2001). Salinomycin, a polyether antibiotic drug belonging to the group of ionophores, is produced by fermentation by the

Streptomyces albus strain (Blazsek and Kubis, 2005). Salinomycin is extensively used as a coccidiostat in poultry and other livestock and is also commonly fed to ruminant animals to improve feeding efficiency of animals (Sparidans *et al.*, 2007). Ionophores toxicity could be probably due to oxidative damage (Khan *et al.*, 1995 and Kamashi *et al.*, 2004). Such damage can be prevented by the supplementation of antioxidants in feed (Main, 2000).

Vitamin E plays important roles in various biochemical and physiological processes, including antioxidation (Brigelius-Flohé *et al.*, 2002; Fang *et al.*, 2002). In nutritional and physiological research, vitamin E supplementation has been proven to improve growth performance (Kocabas and Gatlin, 1999), enhance immunity (Gatlin, 2002; Sealey and Gatlin, 2002; Puangkaew *et al.*, 2004; Trushenski and Kohler, 2007) and restore impaired immunity (Montero *et al.*, 1998; Sahoo and Mukherjee, 2002), as well as influence neuroendocrine function (Khan and Thomas, 2004).

* Corresponding author. Tel.: +20 0822322066;
 fax: +20 822327982.
 E-mail address elgendy@bsu.edu.eg
 (Abdel-Nasser El Gendy).

Selenium is an important part of the glutathione (GSH) peroxidase family of selenoenzymes (Gladyshev and Hatfield, 1999) that are involved in the antioxidant protection of cells against oxidative stress (Tapiero *et al.*, 2003; Elango *et al.*, 2006 and Ortac *et al.*, 2006). Selenium exerts its protective effect against oxidative damage by decreasing the amount of free radicals and increasing the synthesis of glutathione peroxidase, which catalyses the breakdown of toxic hydrogen peroxide and lipid hydroperoxides (Schrauzer, 2005).

The present study aimed to demonstrate the effects of administration of salinomycin (at a concentrations 60 and 120 ppm) alone and in combination with vitamin E or selenium on performance of broilers. Also, haematological and biochemical parameters as well as histopathological changes were studied.

Materials and Methods

Drugs. Salinomycin (Coxistac[®]) was obtained from Animal Health Division Pfizer Company, Cairo, Egypt. Vitamin E obtained as a pure powder from F. Hoffmann-La Roche, Basle, Switzerland. Selenium (sodium selenite) obtained as a pure powder from Animal Health Research Institute, Giza, Egypt.

Experimental protocol. Two hundred and ten, one-day old Ross broiler chicks were used in this study. The birds were obtained from the Hatchery of Cairo Poultry Company. The birds were fed on a ration prepared in Faculty of Agriculture (South Valley University) according to National Research Council (NRC 2004). The chicks were reared in a well cleaned shed under standard hygienic conditions. Feeds and water were provided *ad libitum* to birds. Each pen was equipped with ventilation fans which used to control recommended temperature and 24 hours of light. The birds were vaccinated at the 7th day of age with the Hitchner B₁ strain against *Newcastle* disease in drinking water then vaccinated at the 18th day of age by LaSota vaccine (against *Newcastle* disease) in drinking water. Moreover, birds were vaccinated against *infectious bursal* disease at days 14, 21 and 35. The broiler chicks were divided into 7 groups (each group 30 chick) as follow: The first group was fed only on basal diet as negative control. While the 2nd and 3rd groups were fed on the basal ration mixed with salinomycin only at concentrations 60 and 120 ppm (Kamashi *et al.*, 2004), respectively. The 4th and 5th groups were fed on the basal diet containing salinomycin 60

and 120 ppm with vitamin E 300 mg kg⁻¹ (Jayasree *et al.*, 2003), respectively. At the same time, the 6th and 7th groups were fed on the basal ration mixed with salinomycin at the same two concentrations with selenium 0.1 ppm (Yarsan, 1998), respectively.

Birds of each group were weighed every week individually using a sensitive balance and the mean body weight was calculated and recorded. A known weighed amount of feed was given to birds of each group daily in the morning, then the remaining amount was weighed and subtracted from the original amount of offered feed. The average amount of feed consumed per bird was calculated and recorded after respective time of weighing of bird. Mean weight gain of each group was calculated weekly by subtracted the previous body weight and the next one then recorded. Feed conversion ratio (FCR) was calculated according to Brady (1968) using following formula:

$$\text{FCR} = \frac{\text{Feed consumption in a given period}}{\text{Body weight gain at the same period}}$$

Two blood samples were collected from the wing vein of five birds in each group weekly after the first week. The first blood portion added to an anticoagulant EDTA (1 mg ml⁻¹) and used in haematological studies, while the second portion was taken without anticoagulant, left to clot then centrifuged at 3000 rpm for 15 minutes to obtain serum that kept at -20 °C until assayed for biochemical analysis.

Total erythrocyte and leukocyte counts, Hb content, PCV %, erythrocyte indices, differential leukocyte count, Total protein, albumin and globulin concentrations, ALT and AST activities, creatinine and uric acid concentrations were determined according to methods described by Natt and Herrick (1952), Varley (1980), Schalm *et al.*, (1975), Wintrobe (1932), Schalm (1961), Gornall *et al.*, (1949), Doumas *et al.*, (1971), Reitman and Frankel (1957), Doolan *et al.*, (1962), Richterich and Colombo (1978), respectively.

At the end of the experimental period, five birds from each group were slaughtered and tissue samples from liver, kidney, heart and skeletal muscle were taken in buffer formalin 10 % solution then sectioned and stained with Haematoxylin and Eosin (H&E) (Claydan, 1971) for histopathological examination.

Results were expressed as mean and standard error (S.E) and statistically analyzed using student "t" test and analysis of variance

"F" test (one way ANOVA). Standard errors were calculated from the mean data according to Snedecor and Cochran (1976).

Results

The effects of salinomycin and vitamin E or selenium on the different body performances are presented in table (1). Salinomycin (120 ppm) induced a decrease in the body weight, feed consumption and feed conversion efficiency. In addition, when salinomycin (120 ppm) was given with vitamin E, the body performance improved significantly, but when sodium selenite was used, the body performance significantly decreased.

The effect of salinomycin and vitamin E or selenium on blood picture is recorded in table (2). Salinomycin at concentration 120 ppm induced a decrease in blood picture (RBCs count, TLC count, Hb content and PCV %). Concurrent use of vitamin E with salinomycin caused an improvement of these parameters.

As indicated from the effect of the drug on the different biochemical parameters recorded in table (3), salinomycin at 120 ppm induced a significant increase in enzymes activities (ALT and AST). The use of vitamin E with salinomycin (120 ppm) caused a significant decrease in these activities. In contrast to selenium, which reduced the activity of AST enzyme only. Salinomycin at 120 ppm decreased the total protein concentration and increased the level of creatinine and uric acid. Concurrent administrations of vitamin E or selenium with salinomycin have no effect on these parameters. At 120 ppm salinomycin, selenium increased the creatinine concentration in blood serum.

The histopathological studies revealed that salinomycin at 60 or 120 ppm in chicken's ration induced various pathological changes in certain tissues (liver, heart, kidney and skeletal muscle) ranged from degeneration to necrosis of these tissues. The histopathological changes resulted in chicken's liver from administration of salinomycin 60 ppm were shown in figures (1) and (2), while figures (3) and (4) show the changes in liver after concurrent administration of salinomycin at 60 ppm with vitamin E or selenium. Concurrent administration of salinomycin with vitamin E or selenium revealed that vitamin E decreased the pathological changes of studied tissues.

Table (1): Effect of salinomycin and vitamin E or selenium on body performance (Mean \pm S.E) (N=5)

Item	Body weight (gm)		Feed consumption (gm)		Weight gain (gm)		Feed conversion ratio (FCR)	
	1 st week	6 th week	1 st week	6 th week	1 st week	6 th week	1 st week	6 th week
Control	131.56 \pm 4.16	1519.2 \pm 37.3	105	1010.4	71.48 \pm 2.91	375.37 \pm 21.84	1.47	2.69
Salinomycin 60	121.44 \pm 3.63	1464.8 \pm 31.2	104	980	61.10 \pm 2.91 ^b	362.56 \pm 16.52	1.70	2.63
Salinomycin 120	120.60 \pm 3.47	1117.9 \pm 36.5 ^{CA}	103	787	60.64 \pm 2.07 ^{CA}	301.34 \pm 13.52 ^a	1.70	2.61
Salinomycin 60 + vitamin E	132.41 \pm 4.44	1499.2 \pm 42.2	113.83	915.71	70.65 \pm 4.10 ^b	383.18 \pm 33.20	1.61	2.39
Salinomycin 120 + vitamin E	128.14 \pm 5.58	1326.4 \pm 35.5 ^{AC}	111.17	833.13	64.48 \pm 4.11	352.92 \pm 38.85	1.72	2.36
Salinomycin 60 + Selenium	116.54 \pm 1.74 ^A	1190.2 \pm 38.6 ^{AB}	100	783	56.45 \pm 2.16 ^A	332.04 \pm 27.01	1.77	2.36
Salinomycin 120 + Selenium	114.90 \pm 2.27 ^A	1099.6 \pm 20.4 ^A	103	745	54.54 \pm 0.50 ^A	286.41 \pm 8.06 ^A	1.89	2.60

The different small letter in the same column in each time mean significant difference at ($P < 0.05$), while the capital letter mean significant difference at ($P < 0.01$).

Table (2): Effect of salinomycin and vitamin E or selenium on blood picture at the 6th week (Mean \pm S.E) (N=5).

Item	RBCs ($10^6/\text{mm}^3$)	Hb (gm/dl)	PCV (%)	MCV (mm^3)	MCH (10^{-12})	MCHC (%)	TLC (10^3)	Lymphocytes (%)
Control	2.67 \pm 0.03	8.81 \pm 0.12	27.57 \pm 0.33	103.14 \pm 1.33	32.93 \pm 0.12	31.94 \pm 0.25	13.26 \pm 0.52	64.21 \pm 1.9
Sal-60	2.61 \pm 0.01	8.52 \pm 0.10 ^b	27.49 \pm 0.20	105.96 \pm 3.86	32.79 \pm 0.88	31.01 \pm 0.59	11.55 \pm 0.61 ^b	45.55 \pm 2.9 ^{bA}
Sal-120	2.42 \pm 0.03 ^a	8.21 \pm 0.09 ^A	25.69 \pm 0.38 ^{CA}	105.75 \pm 1.83	33.93 \pm 0.31	31.96 \pm 0.12	8.60 \pm 0.58 ^A	39.02 \pm 0.7 ^{CA}
Sal-60 + vit. E	2.56 \pm 0.06	8.63 \pm 0.14	27.54 \pm 0.38	107.73 \pm 2.55	33.70 \pm 0.22	31.32 \pm 0.17	13.63 \pm 0.57	62.23 \pm 3.9 ^B
Sal-120 + vit. E	2.59 \pm 0.05	8.28 \pm 0.16 ^a	26.58 \pm 0.36	103.56 \pm 2.05	32.05 \pm 0.43	31.15 \pm 0.26	9.61 \pm 0.50 ^A	61.07 \pm 5.7 ^C
Sal-60 + Se	2.54 \pm 0.09	8.10 \pm 0.12 ^{Ab}	26.41 \pm 0.69	101.01 \pm 2.42	32.01 \pm 0.72	30.70 \pm 0.38	8.10 \pm 0.48 ^{AB}	35.34 \pm 3.3 ^{Ab}
Sal-120 + Se	2.45 \pm 0.11 ^a	7.82 \pm 0.15 ^{AC}	24.71 \pm 0.56 ^A	99.36 \pm 2.98	32.09 \pm 1.35	31.66 \pm 0.16	7.50 \pm 0.76 ^A	32.33 \pm 3.0 ^A

The different small letter in the same column in each time mean significant difference at (P < 0.05), while the capital letter mean significant difference at (P < 0.01).

*RBCs = Red blood cell count *Hb = Hemoglobin concentration *PCV = Packed cell volume *MCV = Mean corpuscular volume

*MCH = Mean corpuscular hemoglobin *MCHC = Mean corpuscular hemoglobin concentration *TLC = Total leukocytes count

Table (3): Effect of salinomycin and vitamin E or selenium on content of biochemical parameters at the 6th week (Mean + S.E) (N=5).

Item	Total protein (gm/dl)	Albumin (gm/dl)	Globulin (gm/dl)	ALT (U/L)	AST (U/L)	Creatinine (mg/dl)	Uric acid (mg/dl)
Control	2.94 \pm 2.31	0.85 \pm 0.07	2.10 \pm 0.07	6.28 \pm 0.15	66.89 \pm 1.20	0.61 \pm 0.04	6.81 \pm 0.16
Sal-60	2.72 \pm 2.27	0.85 \pm 0.06	1.86 \pm 0.09	7.16 \pm 0.67	69.71 \pm 2.40	0.65 \pm 0.06	6.99 \pm 0.14
Sal-120	2.23 \pm 2.01 ^{ca}	0.80 \pm 0.05	1.43 \pm 0.07 ^a	7.77 \pm 0.30 ^{ac}	74.13 \pm 1.67 ^{ca}	0.87 \pm 0.08 ^{CA}	7.62 \pm 0.30
Sal-60 + vit.E	2.63 \pm 2.23	0.96 \pm 0.09	1.67 \pm 0.13	6.18 \pm 0.49	66.93 \pm 2.35	0.65 \pm 0.05	6.76 \pm 0.35
Sal-120 + vit.E	2.41 \pm 2.17	0.88 \pm 0.05	1.53 \pm 0.25 ^a	7.19 \pm 0.28	66.31 \pm 2.36 ^c	0.70 \pm 0.03	7.28 \pm 0.40
Sal-60 + Se	2.56 \pm 2.06	0.84 \pm 0.04	1.72 \pm 0.23	6.59 \pm 0.52	67.47 \pm 2.47	0.71 \pm 0.07	7.37 \pm 0.37
Sal-120 + Se	2.00 \pm 2.08 ^A	0.81 \pm 0.05	1.19 \pm 0.25 ^A	7.58 \pm 0.20 ^a	66.82 \pm 1.87 ^c	1.11 \pm 0.08 ^{AC}	7.73 \pm 0.28

The different small letter in the same column in each time mean significant difference at (P < 0.05), while the capital letter mean significant difference at (P < 0.01).

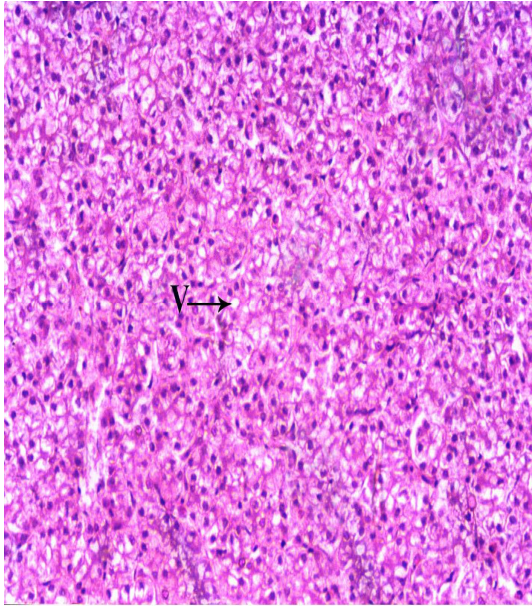


Fig. (1): Liver of birds treated with Salinomycin (60 ppm) alone revealing diffuse vacuolar degeneration of hepatocytes with individual cell necrosis (H&E x 125).

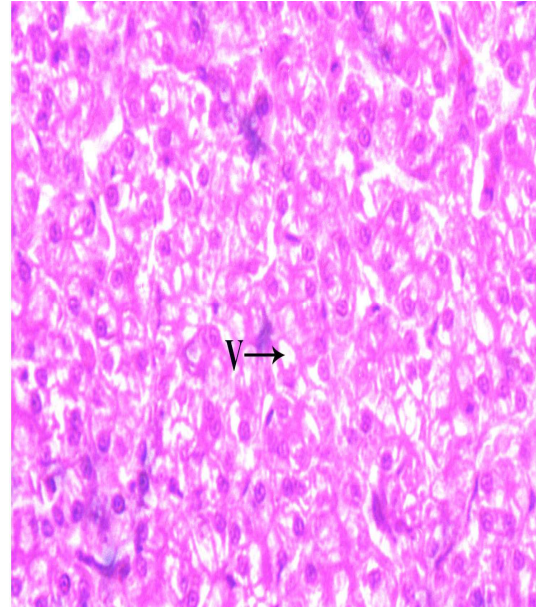


Fig. (2): Liver of birds treated with Salinomycin (60 ppm) alone revealing diffuse vacuolar degeneration of hepatocytes with individual cell necrosis (H&E x 250).

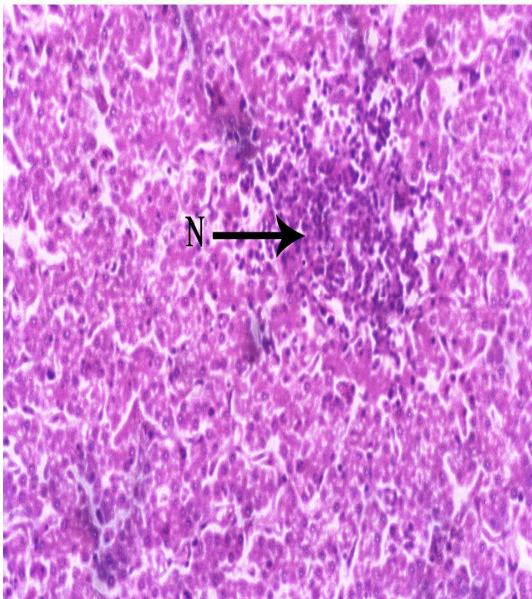


Fig.(3): Liver of birds receiving Salinomycin (60 ppm) with selenium showing few focal areas of necrosis with inflammatory cell aggregation and congestion of some blood vessels(H&E x 125).

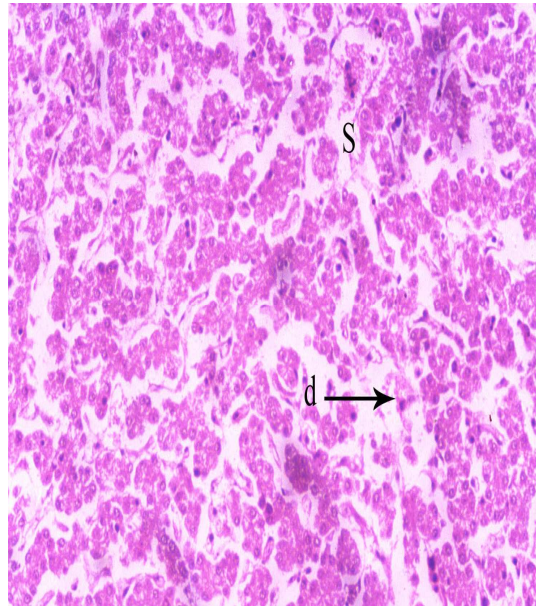


Fig.(4): Liver of birds receiving Salinomycin (60 ppm) with vit. E showing dilatation of sinusoidal capillaries and destruction of some hepatic cells (H&E x 125).

Discussion

At concentration of 120 ppm salinomycin, the body weight and body weight gain were significantly decreased when compared with those of the control chickens. These findings were in accord with those of Rizvi *et al.*, (1999). Co-administration of salinomycin (120 ppm) with vitamin E revealed significant increase in body weight compared to salinomycin 120-medicated group. The improvement in the body weight of birds fed vitamin E could be attributed to some of its biological function such as its role on enzymatic oxidation-reduction, nucleic acid metabolism and in promoting the activity of easily oxidized substances as carotenoides and vitamin A (Osman, 1999). Moreover, such improvement may be due to the role of vitamin E as an immune stimulant (Franchini *et al.*, 1991) which in turn raises the bird resistance. Another study reported an improved growth rate in chicks supplied with vitamin E due to high bone formation rates (Xu *et al.*, 1995). This possibility was confirmed by Watkins and Chen (1997), who stated that vitamin E supplementation, significantly increased bone calcium and phosphorus and thereby improve growth rate.

Combination of salinomycin (120 ppm) with vitamin E revealed a significant increase in body weight gain compared with the group given salinomycin only at concentration 120 ppm. This improvement in body gain was confirmed by the findings of Swain *et al.*, (2000), Villar-Patino *et al.*, (2002) and Raza *et al.*, (1997). High doses of dietary vitamin E increased nutrient digestibility in Japanese's quails (Sahin and Kucuk, 2001).

At concentration of 120 ppm salinomycin, selenium decreased the body weight gain of chicken compared to those given salinomycin alone. Similar result obtained by Khan *et al.*, (1993). There are significant decreases in total erythrocytic count (TEC), Hb concentration and PCV % in chicken given salinomycin at concentration of 120 ppm and this result was agreed with Saly *et al.*, (2002). Supplementation of vitamin E significantly increased the TEC, Hb content and PCV % and this was confirmed by Abdel-Raheem and Abdel-Ghaffar (2004).

The protective effect of vitamin E against the alterations induced by salinomycin on blood picture (TEC, Hb and PCV) in this study could be attributed to the role of vitamin E as fat soluble antioxidant which protects the biological membranes from oxidative damage and decrease osmotic fragility of erythrocytes. (Abas, 2002).

Chicken administered salinomycin at 120 ppm show significant decrease in WBCs count. This effect could be attributed to the immunosuppressive properties of some anticoccidials ionophores as it inhibit both cellular and humoral immune response (Karlson and Malcolm, 1978).

Concerning differential leucocytic count (DLC), salinomycin at 60 or 120 ppm evoked a significant decrease in the number of lymphocyte with increase in heterophil number and decrease in monocyte count (only at 120 ppm) compared to non-medicated chicken. The same result recorded by Shalaby *et al.*, (1993) who reported that marked immunosuppressive effect caused by using salinomycin characterized by lowered titres of antibodies to Newcastle disease virus vaccine (NDV), decrease in the relative weight of lymphoid organs, reduction in heterophil percentage and lower mitogenic response of peripheral blood lymphocytes.

A significant decrease was recorded in the total protein and globulin but no changes in the level of albumin in serum of chicks given 120 ppm of salinomycin. Arun *et al.*, (2003) recorded a significant decrease in total protein, albumin and globulin in chickens given the drug at 120 ppm. Kamashi *et al.*, (2004) declared salinomycin at level of 120 ppm caused a significant decrease in total protein level in blood but not affect albumin or globulin level. On the other hand Mazurkiewicz *et al.*, (1989) reported that administration of salinomycin sodium in turkeys at toxic level evoked increase in total proteins in blood. This increase may be due to the higher sensitivity of turkey to salinomycin than broiler chicks.

Chicks fed salinomycin at a level of 120 ppm evoked a significant increase in ALT and AST activities, compared to non-medicated group. This was agreed with Arun *et al.*, (2003) and Kamashi *et al.*, (2004). Co-administration of vitamin E with salinomycin (120 ppm) induce significant decrease in the activities of ALT and AST., while selenium revealed significant decrease only in AST activity when compared to salinomycin 120-medicated group.

Administration of salinomycin for 6 weeks at concentration 60 or 120 ppm, showed variable concentration-dependent histopathological changes in the liver, kidney, heart and skeletal muscle ranged from degeneration to necrosis (of some hepatic and renal cells), focal areas of degeneration to hyalinization (of heart muscle)

and few focal areas of loss of striation to loss of most of the muscle fiber (of skeletal muscle).

This concentration dependant results were agreed with those reported by Shehata *et al.*, (1990), Gill *et al.*, (1991) and Ahmed *et al.*, (2000). Co-administration of selenium (0.1 ppm) with salinomycin at 60 or 120 ppm not prevents the hazard effect of salinomycin on liver, kidney, heart and skeletal muscle tissues, but administration of vitamin E with salinomycin revealed partial protection against salinomycin hazardous effects especially those in the liver and skeletal muscle. Administration of vitamin E to chicken is more efficient than selenium in the prevention of hazardous effects of monensin on heart and skeletal muscle tissues (Yarsan, 1998).

It is concluded that when salinomycin is given to chicken at concentration of 120 ppm in ration induces undesirable effects on all estimated parameters (physical, haematological, biochemical and histopathological) and on studied tissues. Concurrent use of salinomycin with vitamin E or selenium reveals that, vitamin E is more efficient than selenium in the prevention of the hazardous effects of salinomycin. Therefore, co-administration of vitamin E with salinomycin is recommended in the poultry feed to protect against the hazardous effects of salinomycin.

References

- Abas, S.F. (2002):** Effect of vitamin E and selenium injection on lamb viability, growth performance and some blood serum constituents in saidi lambs. *Assiut Vet. Med. J.*, 47(94): 129-138.
- Abdel-Raheem, H. A. and Abdel-Ghaffar, S. K. H. (2004):** Effect of ascorbic acid, vitamin E and melatonin on performance and immune response of broiler. *Assiut Vet. Med. J.*, 501(101): 215-233.
- Ahmed, S. E.; El-baomy, A. M.; Zienab, M. N. and Abd-Allah, M. A. M. (2000):** Studies on teratogenic effect of some carboxylic ionophores with special reference to their residues in certain tissues. Ph. D. thesis (Pharmacology), Fac. Vet. Med. Beni Suef, Cairo University.
- Arun, K. H. S.; Manjunath, H. S.; Reddy, K. S. and Reddy, R. (2003):** Sub-acute oral toxicity of salinomycin in broiler chicks. *Online-J. Vet. Res.*, 7: 33-42.
- Blazsek, M. and Kubis, M. (2005):** HPLC determination of salinomycin and related compounds in fermentation media of *Streptomyces albus* and premixes. *J. Pharmaceut. Biomed. Anal.*, 39: 564-571.
- Brady, W. L. (1968):** Measurements of some poultry performance parameters. *Vet. Recor.*, 88: 245-260.
- Brigelius-Flohe, R.; Kelly, F. J.; Salonen, J. T.; Neuzil, J.; Zingg, J. and Azzi, A. (2002):** The European perspective on vitamin E: current knowledge and future research. *Am. J. Clin. Nutr.*, 76: 703-716.
- Claydan, E. C. (1971):** "Practical section cutting and staining" 5th Ed. Churchill Living-ston Edinburgh and London.
- Doolan, P. D.; Alen, E. L. and Theil, G. B. (1962):** A clinical appraisal of the plasma concentration and endogenous clearance of creatinine. *Am. J. Med.*, 8: 32-65.
- Doumas, B. T.; Waston, W. A. and Biggs, H. S. (1971):** Albumin standards and the measurements of serum albumin with bromocresol green. *Clin. Chem. Acta.*, 31: 87-96.
- Elango, N.; Samuel, S. and Chinnakkannu, P. (2006):** Enzymatic and non-enzymatic status in stage (III) human oral squamous cell carcinoma and treated with radical radio therapy: influence of selenium supplementation, *Clin. Chem. Acta.*, 373 (1-2): 92-98.
- El-Daly, E. S. (1998):** Protective effect of cysteine and vitamin E, *Crocus sativus* and *Nigella sativa* extracts on cisplatin-induced toxicity in rats. *J. Pharm. Belg.*, 53(2): 87-93.
- Fang, Y.; Yang, S. and Wu, G. (2002):** Free radicals, antioxidants, and nutrition. *Nutri.*, 18: 872-879.
- Franchini, A.; Canti, M.; Manfreda, G.; Bertuzzi, S.; Asdrubali, G. and Franciosi, C. (1991):** Vitamin E as adjuvant in emulsified vaccine for chickens. *Poultry Sci.*, 70: 1709-1715.
- Gatlin, D. M. (2002):** Nutrition and fish health. In: Halver, J.E., Hardy, R.W. (Eds.), *Fish Nutrition*. Academic Press, San Diego, CA, USA, pp., 671-702.
- Gill, B. S.; Singh, J. and Kwatra, M.S. (1991):** Experimental monensin toxicity in buffalo calves clinical, clinicopathological and histopathological studies. *J. Res. (Punjab. Agric. Univ)*, 28(3): 401-407.
- Gladyshev, V. N. and Hatfield, D. L. (1999):** Selenocysteine-containing proteins in mammals. *J. Biomed. Sci.*, 6: 151-160.
- Gornall, A. G.; Bardawill, C. J. and David, M. M. (1949):** Determination of serum protein by means of the biuret reagent. *J. Biol. Chem.*, 177:751.
- Greif, G. (2000):** Immunity to coccidiosis after treatment with toltrazuril. *Parasitol. Res.*, 86: 787-790.
- Jayasree, U.; Reddy, A. G.; Reddy, K. S.; Anjaneyulu, Y. and Kalakumar, B. (2003):** Evaluation of vitamin E against deltamethrin toxicity in broiler chicks. *Indian J. Physiol. Pharmacol.*, 47(4): 447-52.
- Kamashi, K.; Reddy, A. G.; Reddy, K. S. and Reddy, V.R. (2004):** Evaluation of zinc against salinomycin toxicity in broilers. *Indian J. Physiol. Pharmacol.*, 48(1): 89-95.
- Karlson, T. and Malcolm, W. (1978):** Development of immunity coccidiosis in chicken administrated anticoccidials in feed. *Avian-Dis.*, 22(3): 487-496.
- Khan, I.A. and Thomas, P. (2004):** Vitamin E co-treatment reduces Aroclor 1254-induced impairment of reproductive neuroendocrine function in Atlantic croaker. *Mar. Environ. Res.*, 58: 333-336.
- Khan, M. Z.; Szarek, J. and Markiewicz K. (1993):** Concurrent oral administration of monensin and selenium to broiler chickens: effects on concentration of different elements in the liver. *Acta., Vet. Hung.*, 41(3-4):365-79.
- Khan, M.Z.; Szarek, J.; Marchaluk, E.; Macig, A. and Bartlewski, P. M. (1995):** Effects of concurrent administration of monensin and selenium on erythrocyte glutathione peroxidase activity and liver selenium concentration in broiler chickens. *Biol. Trace Elem. Res.*, 49(2-3): 129-38.
- Kocabas, A. M. and Gatlin, D. M. (1999):** Dietary vitamin E requirement of hybrid striped bass (*Morone chrysops* × *M. saxatilis*). *Aquac. Nutr.*, 5: 3-7.
- Lindsay, D. S. and Blagburn, B. L. (2001):** Antiprotozoan

- drugs. *Veterinary Pharmacology and Therapeutics*, 8th Ed. Adams, H.R. pp., 992-1016. Iowa State Press, Ames.
- Main, S. k. (2000):** Oxidation related problems in poultry and livestock feeds. *Poultry Planner*, 1: 7-8.
- Mansoori, B.; Nodeh, H.; Modirsanei, M.; Rahbari, S. and Aparnak, P. (2008):** d-Xylose absorption test: A tool for the assessment of the effect of anticoccidials on the intestinal absorptive capacity of broilers during experimental coccidiosis. *Anim. Feed Sci. Technol.*, 120: 179-186.
- Mazurkiewicz, M.; Nicpon, J.; Gawel, A.; Jopek, Z. and Wieliczko, A. (1989):** Studies on the side effects of salinomycin sodium in turkeys. *Medycyna-Weterynaryjna*, 45(3): 154-157.
- Montero, D.; Tort, L.; Izquierdo, M. S.; Robaina, L. and Vergara, J. M. (1998):** Depletion of serum alternative complement pathway activity in gilthead seabream caused by α -tocopherol and n-3 HUFA dietary deficiencies. *Fish Physiol. Biochem.*, 18: 399-407.
- National Research Council (NRC) (2004):** National Academy of Science, Washington, D.C.
- Natt, M. P. and Herrick, C. A. (1952):** A new blood diluent for counting erythrocytes and leukocytes of the chicken. *Poult. sci.*, 31: 735-738.
- Ortac, E.; Ozkaya, O.; Saraymen, R.; Yildiz, N.; Bedir, A.; Buyan, N.; Bek, K.; Okuyucu, A. and Baysal, K. (2006):** Low hair selenium and plasma glutathione peroxidase in children with chronic renal failure, *Pediatr. Nephrol.*, 21(11): 1739-1745.
- Osman, A. M. (1999):** Influence of various levels of dietary vitamin E on the performance of pekin ducks and quality of its products. *Egypt. Poul. Sci.*, 19(1): 97-119.
- Persia, M. E.; Young, E. L.; Utterback, P. L. and Parsons, C. M. (2006):** Effects of dietary ingredients and *Eimeria acervulina* infection on chick. Performance, apparent metabolizable energy and amino acid digestibility. *Poult. Sci.*, 85: 48-55.
- Puangkaew, J.; Kiron, V.; Somamoto, T.; Okamoto, N.; Satoh, S.; Takeuchi, T. and Watanabe, T. (2004):** Non specific immune response of rainbow trout (*Oncorhynchus mykiss* Walbaum) in relation to different status of vitamin E and highly unsaturated fatty acids. *Fish Shellfish Immunol.*, 16: 25-39.
- Raza, F. K.; Khan, S. A.; Raza, A.; Saeed, M. A. and Basher, I. N. (1997):** Effect of vitamin E deficiency and excess on immune system of broiler chickens. *International journal of animal sciences*, 12(1): 39-41.
- Reitman, S. and Frankle, S. (1957):** Determination of serum glutamic oxalacetic and glutamic pyruvic transaminase. *Am. J. Clin. Pathol.*, 28, 56-58.
- Richterich, R. and Colombo, J. P. (1978):** *Klinische chemie*. 4th ed. basel: karger, S., 319-323.
- Rizvi, F.; Anjum, A. D. and Rizvi, F. (1999) :** Effect of salinomycin on broiler health. *Veterinarski-Arhiv.*, 69(1): 39-47.
- Sahin, K. and Kucuk, O. (2001):** Effect of vitamin E and selenium on performance, digestibility of nutrients and carcass characteristics of Japanese quails reared under heat stress (34°C). *J. Anim. Physiol. Nutr.*, 85(11-12): 342-348.
- Sahoo, P. K. and Mukherjee, S. C. (2002):** Influence of high dietary α -tocopherol intakes on specific immune response, nonspecific resistance factor and disease resistance of healthy and aflatoxin B₁-induced immunocompromised Indian major carp, *Labeo rohita* (Hamilton). *Aquac. Nutr.*, 8: 159-167.
- Saly, J.; Magic, D.; Neuschl, J.; Simko, S.; Tuckova, M.; Sevcikova, Z.; Kremen, J. and Sutiak, V. (2002):** Subchronic toxicity to chicks of sodium salinomycin. *Folia Veterinaria*, 46(2): 86-89.
- Schalm, O. W. (1961):** "Veterinary Haematology" 4th Ed., Lea and Febiger, Philadelphia, USA., p., 320-395.
- Schalm, O. W.; Jain, N. C. and Carroll, E. J. (1975):** *Veterinary Haematology*. 3rd Ed., Lea-Febiger, Philadelphia, USA, p., 42-54.
- Schrauzer, G. N. (2005):** Selenium in nutritional cancer prophylaxis: an update, in: A.S. Prasad (Ed.), *Vitamins, Nutrition and Cancer*, Basel, Karger, pp., 240-250.
- Sealey, W. M. and Gatlin, D. M. (2002):** Dietary vitamin C and vitamin E interact to influence growth and tissue composition of juvenile hybrid striped bass (*Morone chrysops* x *M. saxatilis*) but have limited effects on immune responses. *J. Nutr.*, 132: 748-755.
- Shalaby, M. A.; Elsnusi, A. A.; Yehie, M. M.; Naser, A. and Reda, I. M. (1993):** The effect of salinomycin on the immune response of chicks. *Dtsch-Tierarztl-Wochenschr*, 100(5): 182-185.
- Shehata, M. A.; El-Mahdy, M. M.; Sakr, E. E. and Abonorage, M. A. (1990):** Histopathological changes induced by some anticoccidial drugs in chicks. *Egypt. J. Com. Pathol. Clin. Pathol.*, (2): 399-408.
- Snedecor, G. W. and Cochran, W. G. (1976):** *Statistical methods*. 6th Ed. Ames, Iowa, USA, pp., 502-503.
- Sparidans, R. W.; Lagas, J. S.; Schinkel, A. H.; Schellens, J. H. M. and Beijnen, J. H. (2007):** Liquid chromatography-tandem mass spectrometric assays for salinomycin in mouse plasma, liver, brain and small intestinal contents and in optimum cell culture medium. *J. Chromat. B*, 855: 200-210.
- Swain, B. K.; Johri, T. S. and Majumdar, S. (2000):** Effect of supplementation of vitamin E, selenium and their combination on the performance and immune response of broiler. *Br. Poult. Sci.*, 41(3): 287-292.
- Tapiero, H.; Townsend, D. M. and Tew, K. D. (2003):** The antioxidant role of selenium and seleno-compounds, *Biomed. Pharmacother.*, 57: 134-144.
- Trushenski, J. T. and Kohler, C. C. (2007):** Influence of stress or dietary natural-source vitamin E on nonspecific immunocompetence, tissue tocopherol composition and post-slaughter fillet oxidative stability in sunshine bass. *N. Am. J. Aquac.*, 69: 330-339.
- Varley, H. (1980):** *Practical Clinical Biochemistry*. 5th Ed, William Heinemann Medical Books LTD, London.
- Villar-Patino, G.; Diaz-Cruz, A.; Avila-Gonzalez, E.; Guinberg, R.; Pablos, J. L. and Pina, E. (2002):** Effects of dietary supplementation with vitamin C or vitamin E on cardiac lipid peroxidation and growth performance in broilers at risk of developing ascites syndrome. *Am. J. Vet. Res.*, 63(5): 673-676.
- Watkins, B. A. and Chen, Y. (1997):** Conjugated linoleic acid alters fatty acid composition and collagen synthesis in primary cultures of epiphyseal chondrocytes. *Journal of Bone and Mineral Research*, 12: 279.
- Wintrobe, M. M. (1932):** "Clinical Hematology" 2nd Ed., Lea-Febiger, Philadelphia, USA, p., 52-53.
- Xu, H.; Watkins, B. A. and Seifert, M. F. (1995):** Vitamin E stimulates trabecular bone formation and alters epiphyseal cartilage morphology. *Calcif. Tissue Int.*, 57(4): 1701.
- Yarsan, E. (1998):** Effects on enzyme values and histopathologic findings with vitamin E and/or selenium on monensin toxicosis in broiler chickens. *Turk. J. Vet. Anim.*

Sci., 22: 53-64.

Zhao, J.; Guo, Y.; Xun Suo, X. and Yuan, J. (2006):

Effect of dietary zinc level on serum carotenoid levels, body and shank pigmentation of chickens after experimental infection with coccidia. Arch. Anim. Nutr., 60: 218-228.

بعض التداخلات الفارماكوديناميكية بين عقار سالينومييسين وفيتامين هـ او السلينيوم في الدواجن

أجريت هذه الدراسة لتوضيح تأثير عقار السالينومييسين منفردا عند تركيز 60 مجم/كجم أو 120 مجم/كجم وكذا مع فيتامين هـ أو السلينيوم في الدواجن على الخواص الطبيعية (معدل النمو ، معدل استهلاك العليقة و معدل التحول الغذائي) وصورة الدم وكذلك بعض مكونات المصل ونشاط إنزيمات المصل بالإضافة إلى دراسة التغيرات الباثولوجية على الأنسجة. استخدم في هذه التجربة عدد 210 كتكوت عمر يوم والتي قسمت إلى 7 مجموعات كل مجموعة تحتوي على 30 طائر ، على النحو التالي: المجموعة الأولى أعطيت عليه أساسية فقط (مجموعه ضابطه سالبه) والمجموعة الثانية والثالثة أعطيت عقار السالينومييسين عند تركيز 60 مجم/كجم و120 مجم/كجم علي التوالي (مجموعه ضابطه موجب) والمجموعة الرابعة والخامسة أعطيت عقار السالينومييسين عند تركيز 60 مجم/كجم و120 مجم/كجم متزامنا مع فيتامين هـ (هـ) عند تركيز 300 مجم/كجم علي التوالي و المجموعة السادسة والسابعة عقار السالينومييسين عند تركيز 60 مجم/كجم و120 مجم/كجم متزامنا مع السلينيوم عند تركيز 0.1 مجم/كجم علي التوالي. و قد أوضحت النتائج أن تأثير عقار السالينومييسين عند تركيز 120 مجم/كجم يحدث نقص واضح في كل من وزن الطائر و كمية العليقة المستهلكة و معدل التحول الغذائي. وهذا النقص قد تحسن تدريجيا بإضافة فيتامين هـ (هـ) للعليقة بينما إضافة السلينيوم لم تحدث أي تحسن. أثبتت الدراسة أيضا أن عقار السالينومييسين بتركيز 120 جم/كجم أدى إلى نقص واضح في صورة الدم و إضافة فيتامين هـ (هـ) أحدث تحسن ملحوظ في صورة الدم. و قد أدى تعاطي عقار السالينومييسين بتركيز 120 جم/كجم إلى زيادة واضحة في نشاط كل من إنزيم ALT و AST و عند استخدام فيتامين هـ (هـ) يقل نشاط هذه الإنزيمات على عكس السلينيوم الذي أدى إلى تقليل نشاط إنزيم AST فقط. و قد وجد أن عقار السالينومييسين (تركيز 120 جم/كجم) يحدث نقص في بروتين المصل وزيادة في كل من الكرياتينين وحمض البوليك في الدم ، بينما إعطاء فيتامين هـ و السالينومييسين لم يحدث أي تأثير واضح على هذه الخواص بينما إعطاء السلينيوم نتج عنه زيادة معنوية في مستوى الكرياتينين. و قد لوحظ أيضا أن تعاطي عقار السالينومييسين (تركيز 60 مجم/كجم أو 120 جم/كجم) أدى إلى تغيرات باثولوجية في الأنسجة تصل إلى موت الخلايا حسب الجرعة المعطاة. تبين أن عقار السالينومييسين عند تركيز 120 جم/كجم قد أحدث تأثيرات غير مرغوب فيها على كل المعايير المختبرة (الخواص الطبيعية و صورة الدم والتحليل لبعض مكونات المصل ونشاط الإنزيمات) والتغيرات الباثولوجية في أنسجة الدواجن و استعمال فيتامين هـ أو السلينيوم مع عقار السالينومييسين أوضح أن فيتامين هـ له كفاءة أفضل عن السلينيوم في الوقاية من التأثيرات الغير مرغوب فيها والتي أحدثها عقار السالينومييسين، مما سبق من النتائج ، توصى الدراسة بتزامن إضافة فيتامين هـ مع عقار السالينومييسين في عليقة الدواجن للحماية ضد التأثيرات الضارة المحتملة لعقار السالينومييسين .