

Monogeniasis in African Catfish "*Clarias gariepinus*" and Common Carp "*Cyprinus carpio*"

ABDEL LATIF, A.M*; AMANY, A. ABBASS and SHAHEEN, A.A

Department of Fish Diseases and Management, Fac. Vet. Med.,
Benha University

*Veterinary Teaching Hospital, Fac. Vet. Med.,
Benha University

Abstract

Over a one-year period, the gills of *Clarias gariepinus* and *Cyprinus carpio* were examined for the presence of monogenean parasites. Three monogeneans were found: *quadriacanthus sp*, *macrogyrodactylus sp* and *dactylogyrus sp*. The prevalence of monogeniasis was 56% and 57.5 % in *Clarias gariepinus* and *Cyprinus carpio* respectively. Grossly, the lesions developed were congested or pale colored gills which covered by hypersecretion of mucous. Histopathological examination showed cross-sections from one or more parasites in-between the gill filaments. PAS positive parasitic elements were detected. Moreover, fusion of secondary gill lamellae and mononuclear cellular infiltration were also noticed. Treatment trials showed that Metriphonate, Mirazid, Fresh minced garlic, Potassium Permanganate, Mebendazole and Copper sulphate were effective in treating monogeniasis

Introduction

Fish parasites play an important role in determining the healthy status of fish, they may act either as a primary source of disease or as secondary invaders to other infections (10 and 11). Parasitic diseases in warm water fishes are considered serious problems rather than bacterial diseases (6). They may lead to economical losses in body weight as well as public health significance in certain circumstances (29). Fish gills are multifunctional organs which are responsible for respiration, digestion, excretion of nitrogenous waste and osmoregulation. However, they are often the primary site of infection (21) *Quadriacanthus Kearni* and *Q. clariadis clariades*, monogeneans from the gills of *Clarias lazera* inhabiting Nile Delta water in Egypt in Dakahlia (13) and Sharkia provinces (12 and 20). In addition the disease was recorded in African catfish by several investigators (1, 9, 14,

Third Inter. Sci. Conf., 29 Jan.- 1 Feb./ 2009, Benha & Ras Sudr, Egypt
Fac. Vet. Med. (Moshtohor), Benha Univ

and 39). Moreover, *Dactylogyrus spp.*, were recorded in *Cyprinus carpio* in other previous studies (5, 1, 11, 29 and 22). The present work was conducted to study the problem associated with monogenean gill infestation and trails for treatment.

Materials and Methods

Fish samples

A total number of 200 African Catfish, *Clarias gariepinus*(*C. gariepinus*) and 320 Common Carp, *Cyprinus carpio* (*C. carpio*) were collected during the period from January 2005 to December 2006 from their natural sources (El- Riah El-Tawfiki, and private fish farms). The fishes were transported safely (21) to the Fish Diseases Laboratory, Faculty of Vet. Medicine, Banha. .

Examination of fishes

The fishes were subsequently subjected to thorough investigation of the gills. The fish were clinically examined and signs observed were recorded. Then, the fish were killed and subsequently the gills were dissected and lesions noticed were reported. The gills were examined microscopically and the live parasites were isolated, fixed and mounted in glycerine-gelatine (21).

Histopathological examination:

Specimens for histopathological studies were taken from gills of naturally infected fish. The specimens were fixed in 10% buffered formalin. Sections of 3-5 micron were prepared and stained with hematoxylin and eosin (25). Moreover, Periodic acid Schiff reaction (PAS) was used for detection of parasitic elements.

Treatment Trails:

Fish used

Sixty *C. gariepinus*, weighted 130 ± 10 g and naturally infested with monogena were collected El- Riah El-Tawfiki, its tributaries. In addition, one hundred and twenty *C. carpio*, weighted 15 ± 5 g, suffered from monogeniasis were obtained from private farm. They were transported safety (21) and were kept in well prepared glass aquaria, each measured 100 x 30 x 50 cm and were supplied with sufficient aeration by using electric air pump (Rena, Italy). The fish were divided into 6 groups each of 10 and 20 fish for *C. gariepinus* and *C. carpio* respectively and stocked separately in aquarium.

Compounds used for treatment:

1. Chemicals:

- 1- Potassium permanganate (EL-Nasr Pharmaceutical Chemicals Co.)
- 2- Copper sulphate (EL-Gomhorya Pharmaceutical Chemicals Co.)
- 3- Metriphonate powder (ADWIA) 10th of Ramadan City.
- 4- Metabendazol. (PHARCO Pharmaceutical Chemicals Co.)

2. Natural products

- 1- Mirazid. (PHARCO Pharmaceutical Chemicals Co.)
- 2- Fresh minced garlic.

Experimental design:

Number of groups, Number of fish per group, type of compound used, concentration of used drug and exposure time were presented in table 1. The fish were kept under observation for 7 days. Number of dead fish was recorded. Both dead and survivors were examined for evidence of disease and the presence of monogenean at the end of the experiment.

**Table (1): Natural and chemical compounds used for control of monogeniasis in *Clarias* Third Inter. Sci. Conf., 29 Jan.- 1 Feb./ 2009, Benha & Ras Sudr, Egypt
Fac. Vet. Med. (Moshtohor), Benha Univ**

gariepinus and *Cyprinus carpio*.

Group No.	Treatments	Concen mg/L	Exposure time	Fish No.	
				<i>C. gariepinus</i>	<i>C. carpio</i>
1*	Metriphonate [Negm-Eldin and Salah (20)]	0.33	72 hr	10	20
2*	Mirazid [Mai Ibrahim (18)]	10	1hr /3days	10	20
3*	Fresh minced garlic [Ebtisam and Younis (8)]	300	48 hr	10	20
4*	Potassium Permanganate [Osman (23)]	2.5	1 hour	10	20
5*	Cupper sulphate [Noga (21)]	3	24hr	10	Non
6*	Mebendazol [Noga (21)]	1	24 hr	Non	20
7*	Control (infested group)	-	-	10	20

Each fish species in separate aquarium.

Non: not used * two aquaria per each group

Results and Discussion

Monogeneasis was recorded among the examined *C. gariepinus* and *C. carpio* in a rate of 56% and 57.5% respectively. The infested fish showing no obvious signs, internally the gills showed fading color with hypersecretion of mucous on the gills (Fig.1). Some gill filaments showed pale patches alternated with reddish ones. Microscopically the gills harbored monogenea (Fig.4). Similar Observations were recorded in previous studies (19, 20, 9, 1 and 26).

Three monogenea sp. were detected in the present study, *Quadriacanthus* sp., *Macrogyrodactylus clarii* and *dactylogyrus* sp.

Quadriacanthus species found in the gills of infested *C. gariepinus* (Fig. 2 A, B). The parasite appeared flat, short worm and had many oval or spherical pigmented eye granules scattered in its anterior part. The opisthaptor was equipped with two pairs of central large anchors and numbers of small marginal hooklets (Fig.2: A; B). The common features of recorded monogenea were agreed with that described by previous authors (19, 20, 23 and 22)

Macrogyrodactylus clarii (Fig.3: A; B) was identified from the gills of infested *C. gariepinus*. The parasite was characterized by transparent bodies, without eyes pots, and with large medially located uterus containing embryos. They were relatively large elongated flattened flukes of average body length 2mm. The head was bilobed with a pair of head organs. The cirrus apparatus was oval shaped, contained 16 small spines arranged in one row. The haptor sclerites composed of one pair of large anchors and 16 marginal hooklets. The same descriptions were previously reported in several studies (27, 11 and 23).

Fig. (1): *C. gariepinus* gills showing congestion of gill filament and sliminess.

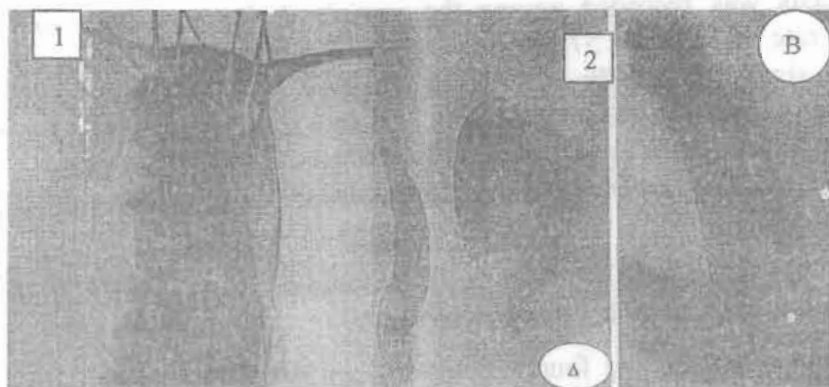


Fig. (1): *C. gariepinus* gills showing congestion of gill filament and sliminess.

Fig. (2) Photo of *Quadracanthus* sp. (A) x 4 and (B) x 10

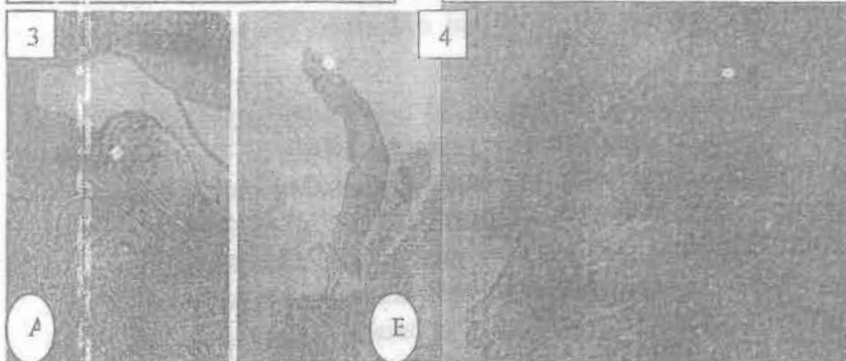


Fig.3: Photo of *Macrogyrodactylus* (A) X4, and posterior end(x10), (B)

Fig (4) Photo of *Dactylogyrus* sp. X20



Fig. (5): Gill of *C. carpio* infested with *Dactylogyrus* sp. x 4

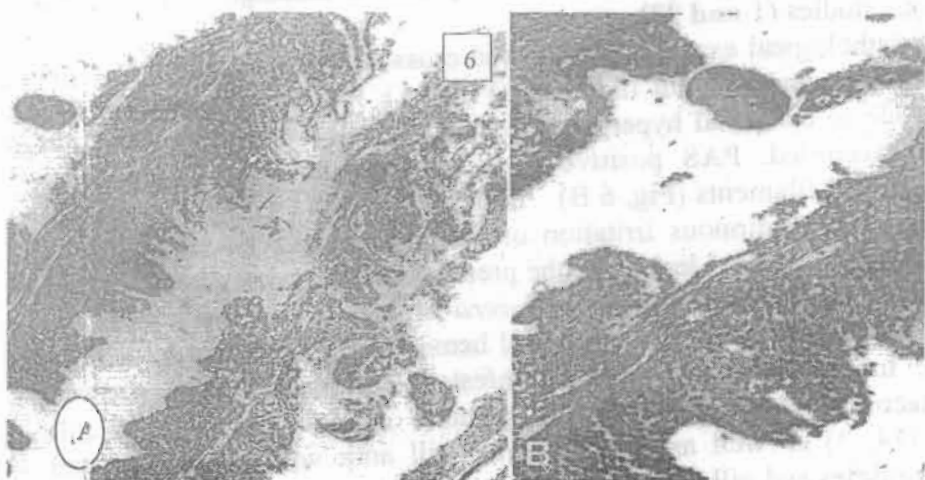


Fig. (6): (A) Gills of *C. gariiepinus* showing cross sections of monogenea in-between gill filament (H & E x 100).

(B) Positive PAS cross section of one monogenea in between gill filament (PAS x 200).

Dactylogyrus species recorded in the gills of *C. carpio* (Fig.4). The parasite was flat and elliptical and possesses at its anterior end four anterior eyespots. The fixation apparatus or haptor consists of two large hooks surrounded by up to 16 smaller hooklets. The same parasite was recorded in other works (17, 11).

The prevalence of Monogenic trematodes among the examined *C. gariepinus* was 56%. These results were agreed with that recorded by El Bouhy (12), but lower than that observed by Osman (23) who mentioned the prevalence was 77.2% in *C. gariepinus*, meanwhile it has been higher than that reported in other previous studies (4,7, 16, 2, 1, 3 and 9). Concerning the seasons, the highest prevalence of disease recorded during spring (82%) and the lowest in winter (36%). Similarly, other researchers (19) found the maximum monogenetic infestation during autumn and spring. On the other hand, monogeneasis was recorded in highest rate during summer in several studies (1, 9, and 23). Regarding to *C. carpio*, monogeneasis was recorded in a rate of 57.5% and the disease mainly found during summer (80%). Nearly similar findings were reported in previous studies (1 and 23)

Histopathological examination showed cross-sections from one or more parasites in-between the gill filaments (Fig.6 A). Fusion of secondary gill lamellae due to epithelial hyperplasia and mononuclear cellular infiltration were also recorded. PAS positive parasitic elements were observed in between the gill filaments (Fig, 6 B). These proliferative gills lesions could be attributed to continuous irritation of monogenea and the action of its hooks (27). The recorded lesions in the present investigation were similar to those observed previously in *Clarias lazera* (4 and 16) and tilapia (1, 24, and 22). Moreover, congestion and focal hemorrhages were also noticed in gill arch. In the same respect, gills infested with monogenea showed melanomacrophages and eosinophilic granular cells in the primary gill lamellae (14, 3) as well as, edema of the gill arch with necrosis in the adductor muscles and gill Lamellae were recorded in previous work (15).

Treatment trials for monogeniasis, revealed that Metrophonate, potassium permanganate, fresh minced garlic, mirazid and copper sulphate were highly effective against monogeniasis in *C. gariepinus* (table.2) and the

survival rate reached 100% except in group treated with metophonate and cupper sulfate, it was 90% compared with control group (70%). These results were in a harmony with that reported in previous studies (20, 21, 8, and 18). Moreover, as presented in table 3, metrophonate, potassium permanganate, fresh minced garlic, mirazid and Mebendazole were highly effective in treatment of *C. carpio*. These results were nearly agreed with the findings given by several investigators (20, 21, 8, and 18). In conclusions monogenea infestation induced health hazard and had deterruined effects on function of the affected gills which represented by fusion of the gill lamellae. Potassium permanganate is the cheapest and highly effective antiparasitic agent.

Table (2): Effect of natural and chemical compounds in treatment of monogeneiasis in *Cl. gariepinus*

Group No.	Compound	Concentration	Exposure time	No. of fish	% of survival	Fish Behaviour	Microscopic examination of gills at the end of exposure	Microscopic examination of gill 2 days post exposure
1	Me rophonate	0.33 mg/L	72 hr	10	90	Mostly normal	Dead monogenea	Gill free from monogenea
2	Pot. permanganate	2.5 mg/L	1 hr	10	100	Mostly normal	Dead monogenea	Gill free from monogenea
3	Fresh minced garlic	300 mg/L	48 hr	10	100	Mostly normal	Dead monogenea	Gill free from monogenea
4	Mirazid	10 mg/L	1 hr / 3 days	10	100	Mostly normal	Dead monogenea	Gill free from monogenea
5	CuSO ₄	3 mg/L	24 hr	10	90	Mostly normal	Dead monogenea	Gill free from monogenea
6	Control (infested)	-	-	10	70	Fish were lethargic and swim near the water surface	Alive gill fluke	Alive gill fluke

Table (3): Effect of natural and chemical compounds in treatment of monogeniasis in *C. carpio*.

Group No.	Compound	Concentration	Exposure time	No. of fish	% of survival	Fish Behaviour	Microscopic examination of gills at the end of exposure	Microscopic examination of gill 2 days post exposure
1	Metronidazole	0.33 mg/L	72 hr	20	100	Mostly normal	Dead monogenea	Gill free from monogenea
2	Potassium permanganate	2.5 mg/L	1 hr	20	100	Mostly normal	Dead monogenea	Gill free from monogenea
3	Fresh minced garlic	300 mg/L	48 hr	20	100	Mostly normal	Dead monogenea	Gill free from monogenea
4	Mirazid	10 mg/L	1hr / 3 days	20	100	Mostly normal	Dead monogenea	Gill free from monogenea
5	Mebendazole	1 mg/L	24 hr	20	100	Mostly normal	Dead monogenea	Gill free from monogenea
6	Control (infested)	-	-	20	80	All fish were lethargic & swim near the water surface	Alive gill fluke	Alive gill fluke

References

- 1-Abd El-Rahim, G.E.A. (1998): Studies on the main parasitic diseases affecting cultured fish and its influences by some ecological factors. Thesis Ph.D. (Fish Diseases and management), Fac. Vet. Med. Zag. Univ.
- 2-Abdel-Hady, O.K. (1998): Comparative studies on some infection of fishes in fresh and polluted water sources. Ph.D. Fac. Vet. Med. Cairo Univ.
- 3-Aly, S.M.; Hassan, M.G. and Abdel-Aal, A.A. (1998): Studies on parasitic infections among some freshwater fishes and their associated pathological lesions. Vet. Med. Zag. Congress, 26-28 August in Hurghada.
- 4-Alyain, S.S.; Nahla, El-Kh. and Mahmoud, N.M.A. (1995): The relationship between the monogenetic trematode infestation (*Quadricanthus spp.*) and the pathological alterations in gills among cat fish (*Clarias lazera*). Beni-Suef Vet. Med. Res. 2.
- 5-Appleby, C. and Sternd, E. (1996): The parasite Fauna of common carp from a pond in south-eastern Norway. Bulletin of the Scandinavian Society for parasitology. 6 (2): 131-133.
- 6-Axelord, H. and Snieszko, S. (1980): Diseases of Fishes T. F. H. Publications. Inc. Ltd. Book 3.
- 7-Derwa, H.I.M. (1995): Some studies on Gill Affections of some freshwater fishes. M.V.Sc. Thesis, Fac. of Vet. Med. Suez Canal University.
- 8-Ebtsam, A.A. and Younis (2003): Comparative study on the effect of formalin and garlic (*Allium stivum*) on ectoparasites infesting *Oreochromis niloticus* fish with reference to their effect on blood picture and serum constituents. Egypt J. Agric. Res., 81 (1).
- 9-El-Nobi, G. (1998): Studies on the main parasitic diseases affecting cultured fish and its influences by some ecological factors. Ph. D. Thesis, Vet. Med. Sc. Zag. Univ.
- 10-Eissa, I.A.M. and Hala, M.F. (1993): Studies on yellow grub disease in Nile Bolti. Beni-Suef, Vet. Med. Res., III (1): 96-107.
- 11-Eissa, I.A.M. (2002): Parasitic fish diseases in Egypt. Dar El- Nahdda El- Arabia Publishing, Cairo, Egypt.
- 12-El-Bouhy, Z.M. (1986): Studies on disease affecting the skin in some Nile fishes. Ph.D. Thesis, Fac. Vet. Med. Zag. Univ.
- 13-El-Naggar, M.N. and Hanaa, M. Serag (1985): The monogenean *Quadriacanthus kearni* N. Sp. and A report of *Q. clariadis clariades* paperna, 1979 on the gills of *Clarias lazera* in Nile Delta. J. of the Egyptian Society of Parasitology, 15 (2) 479-492.
- 14-Eman Mohamed, M.Y. (1996): Studies on the Ectoparasites of *Oreochromis niloticus* fresh water fish species, in Suez Canal Area. M.D. Thesis (Parasitology) Fac. Vet. Med. Suez Canal Univ.
- 15-Eman Youssef, M. (2001): The internal parasites of catfishes. Ph.D. Thesis (Parasitology). Fac. Vet. Med. Suez Canal Univ.
- 16-Ganfar, S.A.A. (1997): Pathologic studies on some parasitic diseases of fish in Sharkia governate. M.V.Sc., Thesis, Fac. Vet. Med. Zag. Univ.

17-Gratzek, J.B. (1993): "Parasites associated with freshwater tropical fish". In: Fish Medicine, (edited by Stoskopf, M. K.) Chapter 70, PP. 573-590. W. B. Saunders Company, Philadelphia.

18-Maj, D. Ibrahim; Iman, B. Shaeed and Olfat, A. Mahdy (2005): Trials for control of some parasitic infestation in cultured Nile Tilapia (*Oreochromis* sp.) using Mirazid® PHAR Co. Vet. Med. J. Giza, 53 (2) 659-675.

19-Nabila El-Khatib, N.R.H. (1993): Further studies on ectoparasitic infestation in freshwater fishes. Ph.D. Thesis, Fac. Vet. Med. Cairo Uni.

20-Negm, M.M. and Saleh, G. (1995): Identification and chemotherapeutic control of Monogenetic trematodes affecting *Clarias lazera* and *Tilapia nilotica* fishes. Alex. J. Vet. Science; 11(3) 243-262 (1st SCVMR).

21-Noga, E.J. (1996): Fish Disease Diagnosis and Treatment. Mosby. New York. pp. 367.

22-Noor El-Deen, A.I.A. (2007): Comparative studies on the prevailing parasitic diseases in morosex tilapia and natural male tilapia in Kafr El-Sheikh Governorate Fish Farms. Ph.D. Thesis Fac. Vet. Med. Kafr El-Sheikh Univ.

23-Osman, H.A. (2005): Studies on Monogeniasis among fish. Ph.D.V.Sc. Thesis, Fac. Vet. Med. Suez Canal Univ.

24-Rawia Adawy, S.M. (2000): Studies on the parasitic diseases of some freshwater fishes in Dakahlia Governorate. Ph.D. Thesis, Fac. Vet. Med. Cairo Univ.

25-Roherts, R.J. (1978): Fish pathology. Bailliere. Tindall. London. Pp.146-186.

26-Saleh, G.A. and El-Nobi, G.A. (2003): Prevalence of monogeniasis in tilapia fish among different systems of fish management, seasons fish life stages with special reference to the therapeutic effect of praziquantel at different temperatures. Zag. Vet. J. Vol. 31, No. 1, 37-48.

27-Schaperclaus, W. (1992): Fish Diseases, A.A. Balkema / Rotterdam, 5th Ed.

28-Simkova, A.; Morand, S.; Jobet, E.; Gelnar, M. and Verneau, O. (2004): Molecular phylogeny of congeneric monogenean parasites (*Dactylogyrus*): a case of intrahost speciation, Evolution. Int. J. Org. Evolution 58 (5): 1001-18.

29-Stoskopf, M.K. (1993): Fish Medicine. W.B. Saunders Company Philadelphia, PA PP 882.

30-Walaa Emeish (2006): Gill affections in catfish (*Clarias gariepinus*) in Qena- Egypt. M.D. Fac. Vet. Med. Assiut Univ.

الملخص العربي

أجريت هذه الدراسة علي مرض المونوجينيا التي تصيب خياشيم أسماك القراميط ،
(المبروك)

وقد بينت الدراسة ما يلي :

- كانت معدلات الإصابات في أسماك القرموط الأفريقي و أسماك المبروك بالمونوجينيا هي ٥٦ ،
٥٧,٥٠ % على التوالي

- كانت أهم الأعراض الإكلينيكية الظاهرية في الأسماك المصابة وجود احتقان وبهتان أبيض لون
الخياشيم مع زيادة في كمية المخاط علي الخياشيم .

- كانت الطفيليات التي تم عزلها تنتمي إلى الديدان المفلحة وحيدة العائل (المونوجينيا الورقية)
وتشمل الكوادريكانسس والماكروجيروكتليس والدكديلوجيرس.

- أظهر الفحص الهستوباثولوجي للخياشيم المصابة بالمونوجينيا وجود مقطع عرضي أو أكثر
بين خيوط الخياشيم مع التحام صفائح الخياشيم الثانوية نتيجة فرط التنسج للخلايا الظلانية
وتراكم الخلايا الالتهابية أحادية النواة .

- أظهرت السحالات العلاجية لأسماك القرموط الأفريقي و أسماك المبروك المصابة بالمونوجينيا
باستخدام أي من المتروفونات أو برمنجنات البوتاسيوم أو الثوم الطازج المثلوم أو اميرازيد
أو كبريتات النحاس أو مييندازول نتائج فعالة.