

THE ANATOMICAL STRUCTURES OF SHEEP CERVIX AND ITS INFLUENCE ON THE TRANSCERVICAL PASSAGE OF AN INSEMINATING CATHETER INTO THE UTERINE LUMEN

K.H.EL-Shahat , M. A. M. Alsafy

*Theriogenology Dept of. Faculty of Vet. Medicine, Cairo Uni.

**Anatomy and Embryology Dept of Faculty of Vet. Medicine, Alex. Uni.

Recived 20/08/ 2009 .

Accepted 2/09/2009 .

SUMMERY

A total of 103 Barbari sheep cervices were used to conduct this work. The cervices were allocated into two main series obtained from an abattoir during the breeding season. The first series was 43 of adult ewe cervices, while the second was a series of 60 cervices obtained from ewe lambs. The tract of both series was further subdivided into luteal and follicular phases based on ovarian structure. The morphology of the cervical external os was classified as slit, papilla, duckbill, flap or rose. An inseminating pipette was inserted into the cervical lumen and the depth of penetration was recorded. The cervix was opened longitudinally, its length and number of cervical rings and its arrangement were recorded. The

results revealed that there was a significant ($P < 0.01$) effect of age on the length of the cervix. Similarly, the length of cervix was significantly ($P < 0.001$) related to the number of cervical rings but not to the stage of the oestrous cycle. The maximum depth of cervical penetration of an inseminating catheter was affected by cervical grade and the stage of the oestrous cycle. The distribution of os types differed with age, with rose types were more common in adult ewes, and papilla os types were more common in ewe lambs. In conclusion, the success of transcervical artificial insemination (TCAI) in ewes is highly dependent on the anatomy of the cervical lumen and the stage of the oestrous cycle.

KEYWORDS: Cervix; Anatomy; Penetration; Artificial insemination; Sheep.

1. INTRODUCTION

Artificial insemination (AI) is used to enhance the production of improved offspring via introduction of superior genotypes, maximize the use of superior rams and to control contagious disease within flocks (Evans and Maxwell, 1987). The lambing rate obtained following cervical artificial insemination is low mainly due to the inability of frozen-thawed sperm to traverse the tortuous nature of cervical canal (Naqvi et al., 2005). The lumen of ovine cervix is highly convoluted and tortuous due to the presence of 4–7 cervical rings that point caudally providing a physical barrier to external contaminants (Dun, 1955; Fukui and Roberts, 1987). These cervical rings that present the major barrier to transcervical artificial insemination (TCAI) as they project into the

lumen and the second and third rings are frequently out of alignment with the first, resulting in the inseminating pipette being misdirected away from the central lumen (More, 1984). Furthermore, the inseminating pipette is rarely inserted more than 1 cm into the cervical canal (Evans and Maxwell, 1987). Therefore, the aim of the present study was: (1) to examine the gross anatomy of the cervix in slaughtered ewe lambs and adult ewes and (2) to determine if any relationship exist between the morphology of the external os, the structure of the internal cervical canal, stage of oestrous cycle, age, cervical length and depth of penetration of the cervix by an inseminating pipette.

2. MATERIALS AND METHODS

2.1. *Animals*

A total of 103 sheep cervices of Barbari ewe lambs (n = 60) and adult ewes (n = 43) were obtained from an abattoir in Libya during the breeding season (January to April, 2007). The genital tracts from both groups were further subdivided into luteal and follicular stages based on the morphology of the ovary. Ovaries with a corpus luteum were described as luteal and

those without a corpus luteum were termed follicular (Kershaw et al., 2005).

2.2. *Measurements*

The genital tracts were transported on ice to the laboratory where they were examined within 3 hours after slaughter. The tracts were prepared by excising the majority of ligamentous tissue and then separated cranially at the body of the uterus and caudally at the vestibule. The tissue of the

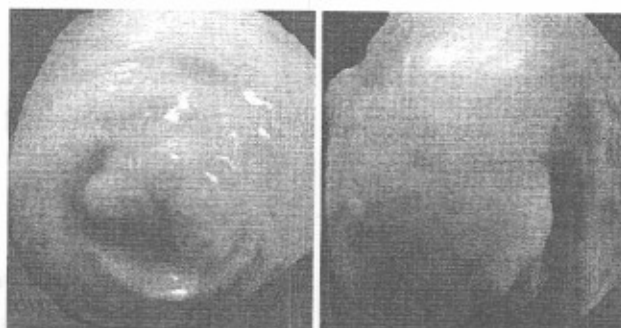anterior vagina was incised longitudinally to expose the cervical external os. According to Halbert et al. (1990); Kershaw et al. (2005) five types of external os were identified (Fig.1):

1. The Duckbill: two opposing folds of cervical tissue protruding into the vagina with a central horizontal slit like external os.
2. The Slit: no protrusions into the anterior vagina with a slit like opening at the os of the cervix giving entry to the cervical canal.
3. The Rose: a cluster of cervical folds protruding into the anterior vagina obscuring the external os.
4. The Papilla: a papilla protruding into the anterior vagina with the external os at its apex
5. The Flap: one-fold of cervical tissue protruding into the anterior vagina and completely or partially overlaying the external os creating the appearance of a flap.

A conventional straight catheter for ovine artificial insemination (IMV technologies, 10, rue Clemenceau-BP81 61302 L'AIGLE, Cedex) was passed into the cervix to its maximum depth

of penetration and the distance from the tip of the catheter to the entrance of external os was recorded to the nearest mm. The length of the cervix (to the nearest mm) from the external os to the internal os was then measured. The cervical rings were counted and the degree of completeness and interdigitation of these rings was recorded as one of three grades (Fig. 2) according to Kershaw et al. (2005):

1. Grade 1 cervixes had a series of complete aligned cervical rings lying across the opened lumen with no interdigitation of the cervical rings.
2. Grade 2 cervixes had a mixture of complete rings (as in grade 1) and incomplete cervical rings that lay partially across the opened lumen and interdigitated with one another, obscuring the central lumen.
3. Grade 3 cervixes had predominantly incomplete and interdigitation cervical rings that were not aligned.



(A)

(B)

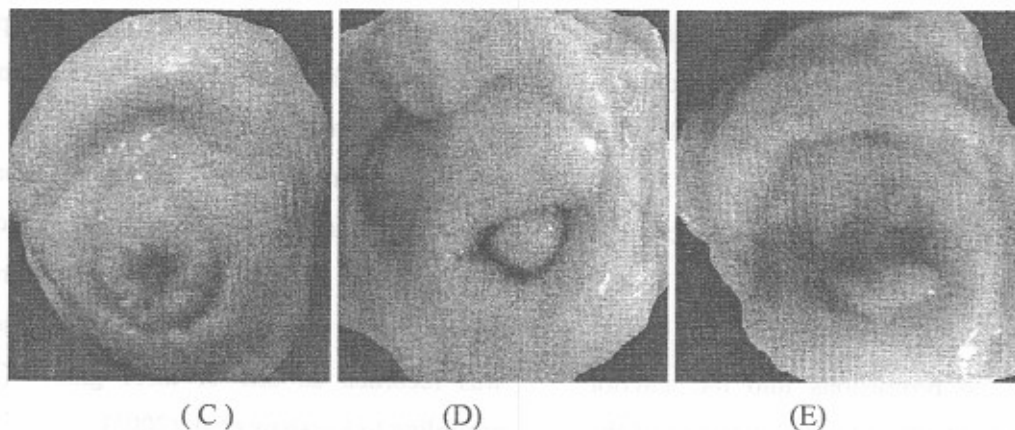


Fig (1): Classification of the external os of the ewe: (A) duckbill, (B) slit, (C) rose, (D) papilla, and (E) flap.

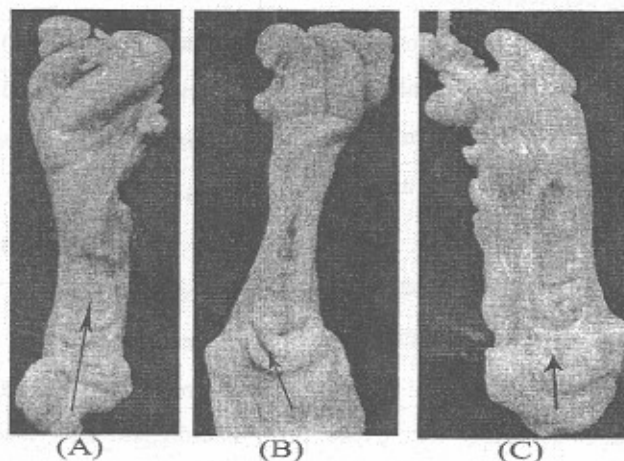


Fig (2): Classification of the cervical grade in the ewe: (A) grade 1, (B) grade 2, and (C) grade 3. Arrows illustrate direction and maximum depth of the penetration.

2.3. Statistical analysis

The data were statistically analyzed according to the general linear model and the difference between means was detected by ANOVA and Duncan's Multiple Range Test. Distributions of external cervical os were analyzed by the Chi-square test. The correlation analysis concerning the cervical grades, stage of oestrous cycle; age,

cervical length and depth of penetration of the cervix were verified according to SAS (1992).

3. RESULTS

3.1. Length of the cervix

The mean length of the ovine cervixes was not altered significantly between luteal and

follicular stage in ewe lambs and adult ewe (Table 1). The normal range for cervical length of ewe lambs was 25–50 and 27-50 mm for both follicular and luteal stage respectively. On the other hand, the range for cervical length of adult ewes between luteal and follicular stage was the same (30-60mm). For both parity (ewe lambs

and adult ewes) the length of the cervix was significantly ($P < 0.001$) related to the number of cervical rings. Similarly, the age of the ewes had a significant ($P < 0.01$) effect on the length of the cervix. However, the length of the cervix was not related to either the grade of the cervix or to the type of the external os.

Table (1): Effect of age and stage of cycle on the length of ovine cervix (Mean \pm S.E) .

Parity	Stage of cycle(n)	length of ovine cervix(mm)	
		Mean \pm S.E	Range
Ewe lambs	Follicular (44)	34.02 \pm 0.82 ^a	25-50
Ewe lambs	Luteal (16)	35.75 \pm 1.36 ^a	27-50
Adult ewes	Follicular (21)	46.09 \pm 2.06 ^b	30-60
Adult ewes	Luteal (22)	44.54 \pm 2.01 ^b	30-60

Values with the same superscripts within columns are not significantly differed. Numbers within parentheses represent the total number of animals in that group.

3.2. Depth of penetration

The depth of maximum cervical penetration was significantly ($P < 0.001$) related to the stage of oestrous cycle (Table 2). The minimum depth of cervical penetration was recorded in luteal stage of both ewe lambs and adult ewes compared to follicular stage one. The depth of cervical penetration was neither affected by the age of ewes nor the number of cervical rings and the type of external os. Penetration into the body of the uterus (expressed as the maximum depth of

penetration) was achieved in 7/43 (16.27%) cervixes in adult ewes and 5/60 (8.33%) of the cervixes from ewe lambs. The maximum depth of penetration was significantly related to cervical grade (ewe lambs: $P = 0.001$ and adult ewes: $P = 0.004$). Grade 1 cervixes were significantly ($P < 0.001$) more penetrable than either grade 2 and 3 for both adult ewes and ewe lambs (Table 3).

Table (2): Influence of age and stage of cycle on the depth of penetration of ovine cervix(Mean \pm S.E.).

Parity	Stage of cycle (n)	Maximum depth of penetration from the external os (mm)
Ewe lambs	Follicular(44)	13.59 \pm 0.988 ^a
Ewe lambs	Luteal(16)	10.50 \pm 1.58 ^b
Adult ewes	Follicular(21)	15.76 \pm 1.02 ^a
Adult ewes	Luteal(22)	10.13 \pm 1.41 ^b

^{a,b} Values with different superscripts within columns differ significantly (P < 0.001). Numbers within parentheses represent the total number of animals in that group.

Table (3): Influence of cervical grades on the number of cervical rings and depth of penetration of ovine cervix (Mean \pm S.E.).

cervical grade	Maximum depth of penetration from the external os (mm)		Number of cervical rings	
	Ewe lambs	Adult ewes	Ewe lambs	Adult ewes
1	22.10 \pm 1.98 ^a	24.20 \pm 1.75 ^a	5.60 \pm 0.384 ^a	5.40 \pm 0.35 ^a
2	10.70 \pm 1.14 ^b	15.57 \pm 1.21 ^b	4.60 \pm 0.222 ^b	4.57 \pm 0.24 ^b
3	7.07 \pm 1.74 ^b	7.88 \pm 1.85 ^c	4.50 \pm 0.337 ^b	4.33 \pm 0.20 ^b

^{a,b} Values with different superscripts within columns differ significantly (P < 0.001).

3.3. Cervical rings and grade

The mean number of cervical rings did not show significant differences between luteal and follicular stage in ewe lambs and adult ewes. The range of cervical rings per cervix was 4-8 for both luteal and follicular stage of ewe lambs. The same trends were observed for adult ewes (Table 4).

The mean number of cervical rings was not significantly related to the age of the ewes, or type and stage of the oestrous cycle (Table 4). On the other hand, the number of cervical rings was significantly related to the grade of the cervix (Table 3).

Table (4): Effect of age and stage of cycle on the number of cervical ovine rings (Mean \pm S.E.).

Parity	Stage of cycle(n)	Cervical rings	
		Mean \pm S.E.	Range
Ewe lambs	Follicular(44)	5.45 \pm 0.16 ^a	4-8
Ewe lambs	Luteal(16)	5.87 \pm 0.32 ^a	4-8
Adult ewes	Follicular(21)	5.95 \pm 0.23 ^a	4-8
Adult ewes	Luteal(22)	5.72 \pm 0.24 ^a	3-8

^{a,b} Values with the same superscripts within columns are not significantly differed. Numbers within parentheses represent the total number of animals in that group.

3.3. Type of external os

The results of the present work (Table 5) revealed that, the distribution of external os type was significantly affected by age ($\chi^2 = 11.114$; $P = 0.025$) but not by the stage of the oestrous cycle. In adult ewes the rose os (34.90%) was

observed more frequently than in ewe lambs (8.34%), while the reverse was true for the papilla os type (23.25% in adult ewes versus 33.34% in ewe lambs).

Table (5): Incidence of external os type between ewe lambs and adult ewes.

Parity	Types of external os					χ^2 value
	Number (%)					
	papilla	Duckbill	Flap	Slit	Rose	
Ewe lambs	20 (33.34)	17 (28.34)	10 (16.67)	8 (13.34)	5 (8.34)	11.114(S)
Adult ewes	10 (23.25)	8 (18.60)	5 (11.62)	5 (11.62)	15 (34.90)	

S: significant

4. DISCUSSION

The data obtained in the present work demonstrated that, the mean cervical length is similar to that reported previously (Getty 1975; Hemmoda et al. 2000; Naqvi et al., 2005). Breed, age, parity and physiological state influence the length of the ovine cervix. The mean length of the

cervical canal has been described as, 6.5, 5.5 and 6.7 cm (Fukui and Roberts 1978; More 1984; Halbert et al., 1990; Hemmoda et al., 2000) respectively and the length ranges from 5.7 to 10 cm (Abusineina 1969) illustrating the high variability between individuals. In ageing ewes, the cervix tended to become longer and wider,

with loose folds (Kaabi et al., 2006). The cervical length range of Barbari ewes was determined as 25-60mm. These results go in parallel with the findings of Kershaw et al. (2005). The main findings of the present study were that the depth of cervical penetration in ewes was influenced by the grade of the cervical lumen and the stage of the oestrous cycle. These results confirm with those reported by Kershaw et al. (2005). Cervices were graded herein according to the complexity of the convolutions of their canals with grade 1 being the least convoluted and grade 3 was the most. It has been reported that the second or third cervical ring from external os was observed to be eccentric in both ewe lambs and adult ewes (Naqvi et al., 2005), and furthermore the mean distance of the second ring from the external os is 10.50 ± 1.582 ; 15.74 ± 1.406 mm in luteal and follicular stage ewe lambs, respectively and 11.78 ± 0.56 ; 15.86 ± 3.35 mm in adult ewes of luteal and follicular stage, respectively (Kershaw et al., 2005). The mean depth of penetration in the present study was 10.50 ± 1.58 ; 13.59 ± 0.988 ; 10.13 ± 1.41 and 15.76 ± 1.02 mm in luteal and follicular stage of ewe lambs and adult ewes, respectively, which are approximately the same as the reported distance of the second cervical ring from the external os. This suggests that the alignment of the second or third cervical ring, in relation to the first ring is the principal determinant of depth of penetration and the major impediment to TCAI (Naqvi et al.,

2005). The grade of the cervical lumen was significantly related to the number of cervical rings in the present study. Similar finding was obtained by (Kershaw et al., 2005). As the rings became more interdigitated and incomplete they became progressively more difficult to count and therefore it may be that the number of rings in the higher grade cervixes was underestimated.

The stage of the oestrous cycle had almost effect on the penetrability of the cervix of the present finding. This agreed with the opinion of (Kershaw et al., 2005). The mean depth of penetration was 3.09; 5.63 mm greater in follicular stage ewe lambs and adult ewes, respectively, compared to luteal stage of both groups. Increasing the depth of semen deposition into the cervix by just 10 mm increases lambing rates by approximately 10% (Salmon and Maxwell 1995) and pregnancy rates (Halbert et al., 1990). The greater depth of cervical penetration in follicular stage ewes indicated that there is a degree of natural relaxation of the cervix at oestrus, possibly as a consequence of the action of ovarian follicular steroids, which enables deeper penetration of the cervix. The stage of the cycle did not affect the grade of the cervix, implying that rather than altering the morphology of the cervix the peri-ovulatory changes in estrogen and progesterone are reducing the resistance of the cervix to the AI pipette (Ayad et al., 2004). Furthermore, Kershaw et al. (2004) suggested that the deeper penetration

in non luteal tracts is the result of natural cervical relaxation at oestrus caused by increased concentrations of oestradiol, oxytocin receptor, prostaglandin E2 (PGE₂) and cyclo-oxygenase-2 (COX-2). In addition to increase PGE₂ concentrations in the oestrous cervix of the ewe compared to luteal cervixes and PGE₂ plays a key role in cervical relaxation and remodeling (Stys et al., 1981; Ledger et al., 1983).

The present study also recorded that the distribution of external os types differed with age. In particular the rose type os was more common in adult ewes than ewe lambs and the reverse was true for the papilla type os. The incidence of cervical prolapse is greater in parous ewes and therefore the more complex os types such as rose

may be more common in older multiparous ewes. Similarly, the papilla type os, which was most common in ewe lambs, is likely to be a tightly constricted os that is most commonly seen in nulliparous ewes. It has been suggested that the classification of the cervical os may change at parturition, increasing in size and complexity (Dun, 1955).

The external os type in this study did not change with stage of the cycle, implying that the ovarian steroids, which may be responsible for relaxation of the cervix during the follicular phase; do not affect the appearance of the external os. It would be reasonable to suggest that the external os is determined genetically and influenced by mechanical factors such as parturition (Kershaw et al., 2005).

5. CONCLUSION

The success of TCAI in ewes is highly dependent on the anatomy of the cervical lumen and the stage of the oestrous cycle.

REFERENCES

- Abusineina, M.E.(1969): Effect of pregnancy on the dimensions and weight of the cervix uteri of sheep. *Br. Vet. J.*, 125: 21–24.
- Ayad, V.J., Leung, S.T., Parkinson, T.J.and Wathes, D.C.(2004): Coincident increases in oxytocin receptor expression and EMG responsiveness to oxytocin in the ovine

- cervix at oestrus. *Anim. Reprod. Sci.*, 80: 237–250.
- Dun, R. (1955): The cervix of the ewe. Its importance in artificial insemination of sheep. *Aust. Vet. J.*, 101–103.
- Evans, G. and Maxwell, W. (1987): Salamon's artificial insemination of sheep and goats. Butterworths.
- Fukui, Y. and Roberts, E. (1978): Further studies on non-surgical intrauterine technique for artificial insemination in the ewe. *Theriogenology* 10: 381–393.
- Getty, R.(1975): Sisson and Grossman's the anatomy of the domestic animals. 5th ed. Philadelphia: WB Saunders Co. Vol (1).PP. 946.
- Halbert, G., Dobson, H., Walton, J. and Buckrell , B.(1990): The structure of the cervical canal of the ewe. *Theriogenology* 33: 977–992.
- Halbert, G., Dobson, H., Walton, J., Sharpe, P. and Buckrell, B.(1990): Field evaluation of a technique for transcervical intrauterine insemination of ewes. *Theriogenology* 33: 1231–1243.
- Hemmoda, A.K., Amin, M.E., Youssef, G.A.E., El-sharaby, A. and Shoaib, M. (2000): Comparative morphological studies on the cervix uteri of ruminants in Egypt. *S.C.V.M.J.*, 1: 251-265.
- Kershaw, C., Khalid, M., McGowan, M., Wheeler-Jones, C. and Scaramuzzi, R.(2004): The Pattern of COX-2 and EP4 mRNA expression in the ovine cervix during the oestrous cycle. *Reprod. Abstr. Ser.* 31: 16.
- Kershaw, C., Khalid, M., McGowan, M., Ingram, K., Leethongdee, S., Wax, G. and Scaramuzzi, R.(2005): The anatomy of sheep cervix and its influence on the transcervical passage of an inseminating pipette into the uterine lumen. *Theriogenology* 64: 1225–1235.
- Kaabi, M., Alvarez, M., Anel, E., Chamorro, C.A., Boixo, J.C., Depaz, P. and Anel, L.(2006): Influence of breed and age on morphometry and depth of inseminating catheter penetration in the ewe cervix. *Theriogenology* 66: 1876–1883.
- Ledger, W.L., Ellwood, D.A. and Taylor, M.J.(1983): Cervical softening in late pregnant sheep by infusion of prostaglandin E-2 into a cervical artery. *J. Reprod. Fertil.*, 69: 511–515.
- More, J.(1984): Anatomy and histology of the cervix uteri of the ewe: new insights. *Acta Anat.*, 120: 156–159.

- Naqvi, S., Pandey, G., Gautam, K., Joshi, A., Geethalakshmi, V. and Mittal, J.(2005):Evaluation of gross anatomical features of cervix in tropical sheep using cervical silicone moulds. Anim. Reprod. Sci., 85: 337-344.
- SAS (1992): SAS User's Guide: Statistics. (SAS Institute: Cary, NC,USA.)
- Salamon, S., and Maxwell, W.(1995): Frozen storage of ram semen. II. Causes of low fertility after cervical insemination and methods of improvement. Anim. Reprod. Sci., 38:1-36.
- Stys, S.J., Dresser, B.L., Otte, T.E.and Clark, K.E.(1981): Effect of prostaglandin E2 on cervical compliance in pregnant ewes. Am. J. Obstet. Gynecol.,140:415-419.

تأثير التراكيب التشريحية لعنق رحم الأغنام على مرور قسطرة التلقيح داخل التجويف الرحمي

د / خالد حافظ الشحات محمد عطية * و د / محمد الصافي محمد الصافي **

قسم التوليد والتناسل والتلقيح الإصطناعي - كلية الطب البيطري - جامعة القاهرة *

قسم التشريح - كلية الطب البيطري - جامعة الاسكندرية **

ملخص البحث

أجرى البحث على ١٠٣ عينة من أرحام نعاج البربرى تم تجميعها من السلخانة . ٤٣ عينة كانت من أرحام نعاج بالغة و ٦٠ من نعاج غير بالغة . قسمت العينات حسب نشاط المبايض ووجود أو عدم وجود الجسم الأصفر الى مرحلتين مرحلة تكوين الجريبات المبيضية ومرحلة تكوين الجسم الأصفر . تم تصنيف وتقسيم الفتحة الخارجية لعنق الرحم الى ٥ أشكال شقى وحلمى ووردى ومنقار البط . وأدخلت قسطرة التلقيح الإصطناعي الخاصة بالأغنام فى عنق الرحم وقيست أقصى مسافة لدخول القسطرة وتم قياس طول عنق الرحم وعدد الحلقات لعنق الرحم وترتيبها وتصنيفها الى ٣ أنواع وتم دراسة تأثير عمر النعاج ومرحلة الشياح على طول عنق الرحم وعدد الحلقات وترتيبها وأشكال الفتحة الخارجية لعنق الرحم وأقصى مسافة لدخول القسطرة التلقيح فى عنق الرحم . دلت النتائج على أن عمر النعاج له تأثير معنوى على طول عنق الرحم كما أن طول عنق الرحم مرتبط معنويا بعدد الحلقات الرحمية وليس بمرحلة الشياح . أيضا دخول ونفاذ قسطرة التلقيح داخل عنق الرحم تتأثر معنويا بمرحلة الشياح ونوع وترتيب الحلقات الرحمية . الموع الأول من ترتيب الحلقات الرحمية أكثر نفاذية لقسطرة التلقيح الإصطناعي عن الثانى . النوع الثالث كان أقل نفاذية . كما أن مرحلة تكوين الجريبات المبيضية من الشياح لعنق الرحم كانت أكثر نفاذية لقسطرة التلقيح الإصطناعي عن مرحلة تكوين الجسم الأصفر . توزيع وشكل الفتحة الخارجية لعنق الرحم تختلف حسب عمر النعاج . النوع الوردى للفتحة الخارجية لعنق الرحم أكثر شيوعا فى النعاج البالغة بينما النوع الحلمى كان أكثر شيوعا فى النعاج غير البالغة . مما سبق يتضح أن نجاح نفاذ ودخول قسطرة التلقيح الإصطناعي داخل عنق الرحم للنعاج يتوقف على التركيب التشريحي لها .