

## **MODULATING EFFECT OF PEPPERMINT AND EUCALYPTUS OILS IN INFECTIOUS BURSAL DISEASE IMMUNOCOMPROMISED CHICKENS**

**Awaad\*, M. H. H.; G. A. Abdel- Alim; Kh. S. Shaaban; Kawkab, A. Ahmed\*\*; A. A. Nada\*\*\* and A. S. Z. Metwalli, Faculty of Veterinary Medicine, Cairo Uni.**

\*Corresponding Author Address: Dept. of Poultry Disease, Faculty of Vet Medicine, Cairo Uni, Egypt.

\*\*Dept. of Pathology.

\*\*\* Animal Health Research institute, Dokki.

**Received:** 07/09/2009

**Accepted:** 11/10/2009

### **SUMMARY**

The immunomodulatory effect of peppermint and eucalyptus essential oils in broiler chickens immunocompromised by either infection or vaccination with infectious bursal disease virus (IBDV) was investigated.

No significant difference in HI titers was observed in volatile oils treated group over their untreated one at any interval. However, the protection percentage reached 35% in treated group and was 25% in untreated one as compared with 0% in unvaccinated control group when challenged with velogenic viscerotropic Newcastle disease virus (vvNDV).

Significant increase in Bursa / body weight ratios was observed between IBDV vaccinated treated group as compared with untreated one at 3 and 10 days post-vaccination (PV). In addition, significant increase was observed between IBDV infected treated birds versus infected untreated group at 3 days post-infection (PI). These findings indicate that treatment with volatile oil ameliorated the immunocompromised effects of IBDV vaccine or infection on immune system of treated birds.

The positive effect of volatile oils on cell mediated immunity of treated birds revealed significant increase in phagocytic %, lysozyme and nitric oxide activities at 14 and

28 days of age in IBDV vaccinated and treated birds as compared with IBDV vaccinated and untreated birds. Moreover; the phagocytic index was higher in IBDV infected and treated birds over non treated ones at 42 days of age.

Histomorphological examination of the major immune organs clarified lymphocytic necrosis and depletion, hyperplasia of reticuloendothelial cells, vacuolations of lymphoid follicles, interfollicular lymphocytic cells infiltration and interfollicular connective tissue proliferation of bursa of Fabricius (B.F). Lymphocytic depletion and hyperplasia of reticular cells of spleen. Lymphocytic necrosis, depletion, focal hemorrhage of thymus glands. Necrosis and depletion of caecal tonsils. The sum lesion scores were 0, 0, 2 and 1, 1, 5 in volatile oils treated and untreated chickens at 3, 7 and 10 days PV respectively. While the sum lesion scores reached 21, 23, 14 and 21, 23, 20 in volatile oils treated and untreated chickens at 3, 7 and 10 days PI respectively. On the other hand there was lymphoblast activation reached 1 score in BF in volatile oils treated group only at 3 and 7 days PV. No histopathological changes all over the experimental period could be detected in blank control group.

In conclusion our study reveals that eucalyptus and peppermint oils have a potent immunomodulatory effects and are able to evoke the immune response in IBDV vaccinated or infected chickens.

---

## INTRODUCTION

Infectious bursal disease (IBD) is an acute highly contagious disease of chickens caused by dsRNA virus which belongs to Bimaviridae family (Murphy et al., 1999); it was first recognized in USA, Gumboro area by Cosgrove, (1962). The emergence of highly pathogenic vvIBDV in Europe during 1988 (Chettle and Wyeth 1989) increased the financial impact of the disease on producers. These vvIBDV were reported to break through high levels of maternal antibodies in commercial flocks, causing up to 60-100% mortality rates in chickens and producing typical lesions (Cao et al., 1998). IBDV infection weakens response to vaccination and makes chickens more susceptible to a number of other infections (Anon, 2000).

Immunosuppression of IBDV is a result of direct lyses of B-cells or their precursors (Rosenberger, 1994). It is undoubtedly true that factors contributing to immune-suppression would lead to immunodeficiency which is a hazard-anticipating causative agent of serious economic impacts in poultry industry all over the world. Recognition and scientific identification of factors encountered in immune deficiency have lead to increase perusal investigation in the counterattacking modulators to accomplish immune-

stimulation that strengthen immune mechanisms and currently usable for stimulating non-specific immune responsiveness in both human and Veterinary Medical practice (Emmerich et al.; 1988, and Awaad et al.; 1999, 2000,a and b).

Peppermint and eucalyptus essential oils proved to have an immunostimulant effect on ND-HI antibody response (Awaad et al.; 2002 and Tayfun Carli et al.; 2006).

Accordingly; the aim of the present study is to determine the utility of peppermint and eucalyptus essential oils in broiler chickens immunocompromised by either IBDV infection or vaccination as compared with untreated control groups

## **MATERIAL AND METHODS**

### **Volatile oils:**

Eucalyptus and peppermint essential oils in emulsifiers produced commercially under the trade name "MENTOFIN<sup>®</sup>" by EWABO Co., Germany were used.

### **Viruses and vaccines:**

#### **I- Viruses:**

##### **a- Virulent Infectious bursal disease virus (IBDV) strain:**

A bursal homogenate containing highly pathogenic pathotype virulent Egyptian strain of IBDV that has been characterized earlier by RT-PCR -RFLP (Abdel-Alim et al.; 2003)

was used. Virus titration in chicken embryos was made by serial 10-fold dilutions of the bursal homogenate and inoculation onto the chorioallantoic membrane as described by Hitchner (1970). The titer is expressed as the 50% embryo infective dose (EID50) per ml and was calculated by the method of Reed and Muench (1983).

##### **b- Newcastle disease virus (NDV) challenge strain:**

A velogenic viscerotropic strain of Newcastle disease (VVND) characterized by Sheble and Reda (1976) was obtained from Newcastle Vaccine Research Dept., Veterinary Serum and Vaccine Research Institute, Abbasia, Cairo, Egypt. The velogenicity of the virus was checked in 10 chickens by intramuscular injection of  $10^{6.8}$  EID50 / ml / bird and resulted in 100% mortality rate.

#### **II-Vaccines:**

**a- ND and IB vaccines:** Hitchner B1 strain (ND) + H120 strain (IB) Vaccine (Pfizer) and La Sota strain vaccine were given via intra-ocular route.

**b- IBDV vaccine:** A freeze-dried live vaccine Noblis Gumboro 228E strain (Intervet International, B.V. BOXMEER-Holland) was given via intra-ocular route.

**c- Avian Influenza vaccine:** Inactivated H5N2 vaccine (Intervet International, B.V.

BOXMEER-Holland), was given via subcutaneous route.

#### **Experimental design:**

A total of 150, day-old chickens were used in this study. The chickens were divided into 5 groups (1-5) consisting of 30 each. All birds were kept in separate pens and fed on a commercial ration *ad libitum*.

Chickens of all groups were vaccinated with Avian Influenza vaccine by subcutaneous route at 7<sup>th</sup> and 28<sup>th</sup> day of age.

Birds in groups 1 and 2 were vaccinated with Hitchener B1+H120 vaccine at 7<sup>th</sup> day of age and with both La Sota vaccine and IBDV vaccine at 14<sup>th</sup> day of age via intra-ocular route.

Birds in group 3 and 4 were vaccinated with Hitchener B1+H120 vaccine at 7<sup>th</sup> day of age, with La Sota vaccine at 14<sup>th</sup> day of age via intra-ocular route and were inoculated with 10<sup>3.5</sup> EID<sub>50</sub> / ml of pathogenic strain of IBDV at 28<sup>th</sup> day of age via oro-nasal route. Birds in group 5 were kept as negative non vaccinated non-infected control.

Chickens of group 1 and 3 were orally treated with eucalyptus and peppermint essential oils in a dose of 0.25 ml / L drinking water for 12 hours / day at 9-11, 16-18 and 23-25 days of age as directed by the producer.

#### **Measurement of phagocytic activity:**

Measurement of phagocytic activity of peripheral blood monocytes using *Candida*

*albicans* was adopted as described by Anthony et al. (1985) and Chu and Dietert (1989). Separation of peripheral blood mononuclear cells using ficoll-hypaque density gradient was carried out as described by Boyum (1968). Mononuclear cell layer was collected, washed and re-suspended in RPMI-1640 supplemented with 10% foetal calf serum and viability was done after Hanks and Waalace (1985). Phagocytic percentage and index were estimated as follows:

Phagocytic % = No. of macrophage ingesting *Candida albicans* / Total No. of macrophages.

Phagocytic index = No. of macrophages ingesting more than 3 blastopores / Total number of macrophages with ingested blastopores.

#### **Measurement of nitric oxide production:**

This was determined according to Pertile et al. (1995). Briefly; 100 µl of serum sample was transferred into flat-bottom 96-well ELISA plates and 100 µl Greiss reagent were added to each well. The absorbance was read at 570 nm with ELISA plate reader, then the absorbance was converted to (µM) of nitrite by comparison with absorbance values of sodium nitrite standard curve fit.

#### **Lysozyme activity:**

This was determined according to Schlitz (1987) using agarose gel lyses assay. Briefly; lyso plates were prepared by dissolving 0.1%

agarose in 0.06 M of P.B.S. at pH 6.3, 500 mg of *Micrococcus lysodeikticus* in 5 ml saline were added to 1 liter of agarose. Plates were poured, and then 25  $\mu$ l of serum samples and standard lysozyme were put in each well. After 18 hours the cleared zones diameter were measured to both standard lysozyme and serum sample and the concentration was estimated.

#### **Statistical analysis:**

The obtained data were statistically analyzed using analysis of variance and comparing between groups was performed using least significant difference (LSD) at  $P \leq 0.05$  according to Petrie and Waston (1999) and computerized using SPSS (1999).

#### **Criteria for evaluation of the immunostimulating effect of eucalyptus and peppermint oils:**

##### **1- Evaluation of immunostimulating effect:**

1-To investigate the possible effect of eucalyptus and peppermint oils on cell-mediated immunity, serum samples were collected at 14 and 28 days of age from groups 1, 2 and 5 (0 and 14 days post IBDV vaccination) and at 42 days of age from groups 3, 4 and 5 (14 days post infection with IBDV) to carry out phagocytic activity of macrophages, nitric oxide production and lysozyme activity tests.

2-To investigate their possible effect on humoral immunity, blood samples were

collected from 10 birds at weekly intervals (1-4 weeks of age) from investigated groups and serum samples were subjected to HI test for determining antibody titers against ND employing 8 HA units (Swayne et al., 1989).

##### **2- Bioassay against Newcastle disease virus:**

At 28<sup>th</sup> day of age, 10 chickens out of groups 1, 2 and 5 were challenged with vvND by inoculating  $10^{6.8}$  EID<sub>50</sub> / ml / bird by intramuscular injection. These birds were kept under close observation for further 2 weeks for clinical signs, mortality and lesion scoring.

##### **3-Relative Bursa of Fabricius weight / body weight ratios:**

From all groups; 5 chickens / group were sacrificed at 3, 7 and 10 days post IBDV vaccination or infection. The bursa / body weight ratios were calculated by the formula; Organ weight in grams x 1000 / total body weight in grams and then expressed as the arithmetic mean for each group of birds and evaluated statistically as described by Sharma et al. (1989).

##### **4-Histopathological assay:**

Bursae of Fabricius, spleens, thymus glands and caecal tonsils were collected from the sacrificed 5 chickens per groups at 3, 7 and 10 days post IBDV vaccination and fixed in 10% neutral buffered formalin. Routinely prepared Paraffin-embedded sections were stained with Hematoxylin and Eosin (Bancroft et al.; 1996) and scored for histopathological lesions

Paraffin-embedded sections were stained with Hematoxylin and Eosin (Bancroft et al.; 1996) and scored for histopathological lesions according to the method described by Rosales et al.; (1989). Bursae were subjectively scored as 1= no lesions, 2= focal, mild cell necrosis or depletion, 3= multifocal, 1/3 to 1/2 of the

follicle show atrophy and 4= diffuse atrophy of all the follicles.

## RESULTS

Obtained results are shown in tables 1-5 and Figs. 1-18.

**Table1.** HI antibody titers (HI geometric means) against Newcastle disease virus (NDV) vaccines and protection % in birds immunocompromised with IBDV vaccination and treated with or without eucalyptus and peppermint oils.

Age of birds	Chicken groups*		
	Group1 (NDV vaccinated and treated)	Group2 (NDV vaccinated and untreated)	Group5 (Unvaccinated negative control)
7 days	6.6+ 0.5 <sup>a</sup>	6.6+ 0.5 <sup>a</sup>	6.6+0.5 <sup>a</sup>
14 days	4.8+ 0.6 <sup>b</sup>	4.6+ 0.4 <sup>b</sup>	3.6+ 0.2 <sup>a</sup>
21 days	4.0+ 0.4 <sup>b</sup>	3.8+0.3 <sup>b</sup>	2.4+0.5 <sup>a</sup>
28 days	5.0+0.7 <sup>b</sup>	5.0+0.6 <sup>b</sup>	1.5+0.2 <sup>a</sup>
Protection% against vvNDV	35%	25%	0%

Values in the same column with no common superscripts are significantly different ( $P \leq 0.05$ ).

\*Birds of groups 1 and 2 were vaccinated against Newcastle disease (ND) with Hitchener B1+H120 vaccine at 7<sup>th</sup> day of age and with La Sota vaccine (B1 type, La Sota strain) ND vaccine at 14<sup>th</sup> days of age by intraocular route. Birds of group 5 were inoculated with vvNDV challenge virus at a dose of  $10^{6.8}$  EID<sub>50</sub> /ml/bird by intramuscular injection at 28 days of age.

**Table2a:** Relative bursal body weight ratio of chickens vaccinated with IBDV vaccination and treated with or without eucalyptus and peppermint oils

Group NO.*	Eucalyptus and peppermint oils Treatment	Days post IBD vaccination		
		3ds	7ds	10 ds
1	+	4.1 <sup>b</sup>	4.4 <sup>b</sup>	5.0 <sup>a</sup>
2	-	5.2 <sup>a</sup>	4.2 <sup>b</sup>	3.8 <sup>b</sup>
5	Negative control	5.3 <sup>a</sup>	5.3 <sup>a</sup>	4.7 <sup>a</sup>

Values in the same column with no common superscripts are significantly different ( $P \leq 0.05$ ).

\*Chickens of group 1 and 2 were vaccinated against infectious bursal disease at 14<sup>th</sup> day of age via intra-ocular route. Birds in Group 5 were kept as negative non-vaccinated control.

**Table2b:** Relative bursal body weight ratio of chickens inoculated with a field pathogenic IBDV and treated with or without eucalyptus and peppermint oils

Group NO.*	Eucalyptus and peppermint oils Treatment	Days post IBD infection		
		3ds	7ds	10 ds
3	+	2.3 <sup>b</sup>	1.2 <sup>b</sup>	1.0 <sup>b</sup>
4	-	1.2 <sup>c</sup>	1.1 <sup>b</sup>	1.0 <sup>b</sup>
5	Negative control	5.3 <sup>a</sup>	5.3 <sup>a</sup>	4.7 <sup>a</sup>

Values in the same column with no common superscripts are significantly different ( $P \leq 0.05$ ).

\*Birds of group 3 and 4 were inoculated with  $10^{3.5}$  EID50/ml of pathogenic IBDV strain via naso-oral route at 28<sup>th</sup> days of age. Birds in Group 5 were kept as negative non-vaccinated control.

**Table3a.** Effect of eucalyptus and peppermint oils on cell mediated immunity in immunocompromised chickens with IBDV vaccination and treated with or without eucalyptus and peppermint oils.

Age of birds	Test	Chicken groups*		
		Group1 (treated)	Group 2 (Untreated)	Group 5
14 days	Phagocytic %	52.00±1.9 <sup>b</sup>	45.00±1.3 <sup>a</sup>	41.00±3.5 <sup>a</sup>
	Phagocytic index	0.21±0.08 <sup>b</sup>	0.17±0.01 <sup>b</sup>	0.01±0.06 <sup>a</sup>
	Lysozyme activity µg/L	17.00±8.0 <sup>b</sup>	27.00±5.0 <sup>a</sup>	22.00±5.0 <sup>a</sup>
	Nitric oxide µm/L	90.00±12.0 <sup>c</sup>	59.00±8.0 <sup>b</sup>	73.00±14 <sup>a</sup>
28 days	Phagocytic %	48.00±3.4 <sup>b</sup>	42.00±1.0 <sup>a</sup>	37.00±2.9 <sup>a</sup>
	Phagocytic index	0.17±0.02 <sup>b</sup>	0.11±0.01 <sup>a</sup>	0.11±0.01 <sup>a</sup>
	Lysozyme activity µg/L	32.00±3.0 <sup>b</sup>	31.00±2.0 <sup>b</sup>	22.00±1.5 <sup>a</sup>
	Nitric oxide µm/L	61.00±6.0 <sup>b</sup>	66.00±2.0 <sup>b</sup>	46.00±4.0 <sup>a</sup>

At one day of age: Phagocytic % 38±2.9, Phagocytic index 1.07±0.03, Lysozyme activity 55± 2.3 and Nitric oxide 113± 6.6

Values in the same column with no common superscripts are significantly different ( $P \leq 0.05$ )

\*Chickens of group 1and 2 were vaccinated against infectious bursal disease at 14th day of age via intra-ocular route. Birds in Group 5 were kept as negative non-vaccinated control

**Table3b.** Effect of eucalyptus and peppermint oils on cell mediated immunity in immunocompromised chickens with IBDV infection and treated with or without eucalyptus and peppermint oils.

Age of birds	Test	Chicken groups*		
		Group1 (treated)	Group 2 (Untreated)	Group 5
42 days	Phagocytic %	43.00±2.3 <sup>a</sup>	36.00±1.7 <sup>a</sup>	42.00±2.9 <sup>a</sup>
	Phagocytic index	0.13±0.08 <sup>a</sup>	0.08±0.001 <sup>b</sup>	0.10±0.0 <sup>a</sup>
	Lysozyme activity µg/L	46.00±1.3 <sup>c</sup>	53.00±3 <sup>b</sup>	39.00±5 <sup>a</sup>
	Nitric oxide µm/L	58.00±5 <sup>c</sup>	67.00±6 <sup>b</sup>	53.00±13 <sup>a</sup>

At one day of age: Phagocytic % 38±2.9, Phagocytic index 1.07±0.03, Lysozyme activity 55± 2.3 and Nitric oxide 113± 6.6

Values in the same column with no common superscripts are significantly different ( $P \leq 0.05$ )

\*Birds of group 3 and 4 were inoculated with  $10^{3.5}$  EID50/ml of pathogenic IBDV strain via naso-oral route at 28<sup>th</sup> days of age. Birds in Group 5 were kept as negative non-vaccinated control.

**Table4a.** Scoring of histomorphological changes of IBDV vaccinated birds and treated with or without Eucalyptus and peppermint oils

Histomorphological changes	Days Post IBDV Vaccination					
	Treated group			Non-treated group		
	3ds	7ds	10ds	3ds	7ds	10ds
B.F.Lymphocytic necrosis and depletion	0	0	0	0	0	1
B.F.Hyperplasia of RE cells	0	0	0	0	0	1
B.F.Vacuolation of lymphoid follicles	0	0	0	0	0	1
B.F.Interfollicular lymphocytic cells infiltration	0	0	0	0	0	0
B.F.Interfollicular C.T. infiltration	0	0	0	0	0	0
Spleen lymphocytic depletion	0	0	1	1	1	1
Spleen hyperplasia of reticular cells	0	0	0	0	0	0
Thymus lymphocytic necrosis and depletion	0	0	0	0	0	0
Thymus gland focal hemorrhage	0	0	1	0	0	1
Caecal tonsils necrosis and depletion	0	0	0	0	0	0
<b>Sum of lesion score</b>	<b>0</b>	<b>0</b>	<b>2</b>	<b>1</b>	<b>1</b>	<b>5</b>
B.F. Lymphoblast activation	1	1	0	0	0	0
<b>Sum of activation</b>	<b>1</b>	<b>1</b>	<b>0</b>	<b>0</b>	<b>0</b>	<b>0</b>

No histopathological changes all over the experimental period could be detected in blank control group.

**Table4b.** Scoring of histomorphological changes of IBDV infected birds and treated with or without Eucalyptus and peppermint oils

Histomorphological changes	Days Post IBDV Infection					
	Treated group			Non-treated group		
	3ds	7ds	10ds	3ds	7ds	10ds
B.F.Lymphocytic necrosis and depletion	3	3	2	3	3	3
B.F.Hyperplasia of RE cells	3	3	2	3	3	2
B.F.Vacuolation of lymphoid follicles	3	3	2	3	3	2
B.F.Interfollicular lymphocytic cells infiltration	3	3	2	3	3	2
B.F.Interfollicular C.T. infiltration	0	2	0	2	2	0
Spleen lymphocytic depletion	2	2	3	3	3	3
Spleen hyperplasia of reticular cells	2	3	3	3	3	3
Thymus lymphocytic necrosis and depletion	2	2	0	0	0	1
Thymus gland focal hemorrhage	1	0	0	0	0	1
Caecal tonsils necrosis and depletion	2	2	0	1	3	3
<b>Sum of lesion score</b>	<b>21</b>	<b>23</b>	<b>14</b>	<b>21</b>	<b>23</b>	<b>20</b>
B.F. Lymphoblast activation	0	0	0	0	0	0
<b>Sum of activation</b>	<b>0</b>	<b>0</b>	<b>0</b>	<b>0</b>	<b>0</b>	<b>0</b>

No histopathological changes all over the experimental period could be detected in blank control group.



## **Histopathological results:**

### **I. Bursa of Fabricius**

#### **Group (1): IBD Vaccinated and vol. oils treated:**

At the 1<sup>st</sup> and 2<sup>nd</sup> samples (PV), examined bursae showed no histopathological alterations except slight lymphoblasts activation (Fig. 1). Meanwhile, at the 3<sup>rd</sup> sample (PV) examined sections revealed apparent normal lymphoid follicles.

#### **Group (2): IBD Vaccinated - non treated:**

At 1<sup>st</sup> and 2<sup>nd</sup> samples (PV), no histopathological alterations were noticed in examined bursae (Fig. 2). Meanwhile, at the 3<sup>rd</sup> sample (PV), examined sections revealed lymphocytic necrosis and depletion in some lymphoid follicles (Fig. 3) associated with hyperplasia of reticuloepithelial cells.

#### **Group (3): IBD infected and vol. oils treated:**

At 1<sup>st</sup> and 2<sup>nd</sup> samples (PI), examined sections revealed lymphocytic necrosis and vacuolations of lymphoid follicles; marked intrafollicular and interfollicular heterophilic cells infiltrations (Fig. 4) associated with caseous necrosis (Fig. 5), interfollicular edema and hemorrhage. Meanwhile, at 3<sup>rd</sup> sample (PI) the more conspicuous alterations were atrophy of lymphoid follicles, interfollicular leucocytic cells infiltrations accompanied with intrafollicular connective tissue proliferation (Fig. 6).

#### **Group (4): IBD infected - non treated:**

At 1<sup>st</sup> sample (PI), examined sections showed lymphocytic necrosis, depletion, vacuolations of lymphoid follicles and interfollicular heterophilic cells infiltration (Fig. 7). Moreover, at the 2<sup>nd</sup> and 3<sup>rd</sup> samples (PI), the most conspicuous alterations were atrophy of lymphoid follicles associated with interfollicular connective tissue proliferation (Fig. 8).

#### **Group (5): Blank control:**

Examined sections revealed no histopathological changes at 3, 7, and 14 days post IBDV vaccination or infection.

### **II. Spleen:**

#### **Group (1):**

Microscopically, at the 1<sup>st</sup> and 2<sup>nd</sup> samples (PV), the spleen showed normal lymphoid follicles (Fig. 9). However, slight lymphocytic depletion was observed at the 3<sup>rd</sup> sample (PV).

#### **Group (2):**

At 1<sup>st</sup>, 2<sup>nd</sup>, and 3<sup>rd</sup> samples (PV), examined spleen showed no histopathological changes except slight lymphocytic depletion of some lymphoid follicles (Fig. 10).

#### **Group (3):**

Marked lymphocytic necrosis and depletion (Fig. 11) as well as hyperplasia of reticular cells were noticed in the examined sections at 1<sup>st</sup>, 2<sup>nd</sup>, and 3<sup>rd</sup> samples (PI).

#### **Group (4):**

At 1<sup>st</sup>, 2<sup>nd</sup> and 3<sup>rd</sup> samples (PI), examined spleen revealed lymphocytic

At 1<sup>st</sup>, 2<sup>nd</sup> and 3<sup>rd</sup> samples (PI), examined spleen revealed lymphocytic necrosis, depletion and hyperplasia of reticular cells (Fig. 12).

**Group (5):**

No histopathological changes were noticed.

**III. Thymus gland:**

**Group (1):**

At 1<sup>st</sup>, 2<sup>nd</sup>, and 3<sup>rd</sup> samples (PV), examined thymus revealed no histopathological changes (Fig. 13).

**Group (2):**

At 1<sup>st</sup> and 2<sup>nd</sup> samples (PV), no changes were noticed in examined thymus. However, slight lymphocytic necrosis and depletion were observed at 3<sup>rd</sup> sample (PV).

**Group (3):**

At 1<sup>st</sup> and 2<sup>nd</sup> samples (PI), it showed lymphocytic necrosis and depletion in both cortex and medulla (Fig. 14). Adversely, repopulation with lymphocytes was noticed at 3<sup>rd</sup> sample (PI).

**Group (4):**

At 1<sup>st</sup> sample (PI), it showed slight lymphocytic necrosis and depletion in both cortex and medulla (Fig. 15). No histopathological changes were observed at 2<sup>nd</sup> and 3<sup>rd</sup> samples (PI).

**Group (5):**

No histopathological changes were noticed.

**VI. Caecal tonsils:**

**Group (1):**

No histopathological alterations were observed in all collected samples.

**Group (2):**

No histopathological alterations were observed in all collected samples (Fig. 16).

**Group (3):**

At 1<sup>st</sup> and 2<sup>nd</sup> samples (PI), the caecal tonsils showed lymphocytic necrosis and depletion. Meanwhile, at 3<sup>rd</sup> sample (PI) examined sections revealed apparent normal caecal tonsils (Fig. 17).

**Group (4):**

Slight lymphocytic necrosis and depletion were the histopathological alterations noticed at the 1<sup>st</sup> sample (PI). However, at 2<sup>nd</sup> and 3<sup>rd</sup> samples (PI), the examined caecal tonsils revealed marked lymphocytic necrosis and depletion (Fig. 18).

**Group (5):**

No histopathological alterations were observed in all collected samples.

**DISCUSSION**

Peppermint oil is one of the most important therapeutically used oils and is also widely used in sweets, tooth paste and chewing gum.

Table (1) is showing the immune response against ND vaccination as well as results of NDV challenge of IBDV vaccinated

with unvaccinated blank control group. No significant difference in HI titers was observed in volatile oils treated group over their untreated one at any interval. However, the protection percentage reached 35% in treated group and was 25% in untreated one as compared with 0% in unvaccinated control group when challenged with vvNDV. Similar observation was reported by Barbour (2006) who concluded that Mentofin improved the homogeneity of immune response to respiratory vaccine viruses of NDV and infectious bronchitis virus (IBV).

The results of treatment of IBDV vaccinated or infected birds with volatile oils were summarized in Tables (2a & b). Significant differences in Bursa / body weight ratios were observed between IBDV vaccinated and treated groups as compared with untreated groups at 3 and 10 days post-vaccination (Table 2a). In addition, significant difference was observed between IBDV infected and treated birds when compared with infected untreated group at 3 days PI (Table 2b). These findings indicate that treatment with volatile oil ameliorate the immunocompromised effects of IBDV vaccine or infection on the immune system of treated birds.

The positive effect of volatile oils on cell mediated immunity of treated birds is illustrated in Tables (3a & b) that revealed significant increase in phagocytic%, lysozyme activity and nitric oxide production at 14 and

28 days of age in IBDV vaccinated and treated birds as compared with IBDV vaccinated and untreated birds (Table 3a). Moreover; the phagocytic index was higher in IBDV infected and treated birds over non treated ones at 42 days of age (Table 3b).

Phagocytes (macrophages) are known to play an important role in resistance to infection. They are part of the nonspecific first line of defense because of their ability to engulf and degrade invading microorganisms. Macrophages perform a variety of functions other than phagocytosis, act as secretory cells, produce nitric oxide (NO) that kill intracellular microorganisms, also secrete many different proteins such as lysosomal enzymes and cytokines that play a key role in regulating immunity (Tizar, 1996 and Stafford et al., 2002). These results agree with those obtained by Serafine (2008) who found that eucalyptus oil is able to induce morphological and functional activation of human monocyte-derived macrophages and the increased phagocytic ability is coupled to allow release of interleukin-4, I-L-6 and Tumor necrosing factor alpha, proinflammatory cytokines. Also; previous investigator recorded that essential oil (eucalyptus) is able to induce a dramatic recovery of granulocytes/monocytes activity after bone marrow suppression produced by 5-flouro-uracil administration in immuno-competent rats. Juergens et al. (1998) stated that in eucalyptus globules, the major monoterpenoid

marrow suppression produced by 5-fluorouracil administration in immuno-competent rats. Juergens et al. (1998) stated that in eucalyptus globules, the major monoterpenoid component is eucalyptol (1,8-cineole) that has been reported to inhibit the production of synthesis of tumor necrosing factor alpha (TNF-alpha), interleukin-1B (I-L1B), leukotrien B4, and thromboxan B2 in human blood monocytes. It is actually known that internalization by macrophages occurs by a restricted number of phagocytic receptors present in their surface (Aderem and Underhill, 1999).

Specifically, infectious agents are mainly phagocytosed by complement receptors after relatively nonspecific opsonization with complement, and by Fc receptor after specific opsonization with antibodies. We suggest that stimulatory effect of eucalyptus oil in phagocyte may be attributed to stimulating the complement receptor mediated phagocytosis. Besides stimulatory effect of eucalyptus oil, also peppermint oil has strong antioxidant action which protects cell membrane from free radical oxidants. Free radical and non free radical oxidants can produce damaging effects in animal tissues; these oxidants are produced during infection, stress, aerobic exercise and detoxification of many compounds (Nickels, 1996). On this context, Mekay and Blumberg (2006) recorded that peppermint oil has a strong antioxidant, significant antimicrobial,

antitumor action, antiviral, immunomodulating action and chemopreventive potential. Iscan et al. (2002) and Schuhmacher et al. (2003) reported that peppermint oil had also antimicrobial effect against wide range of bacteria and subsequently they improve the general healthy conditions of animal that may be reflected in immune response.

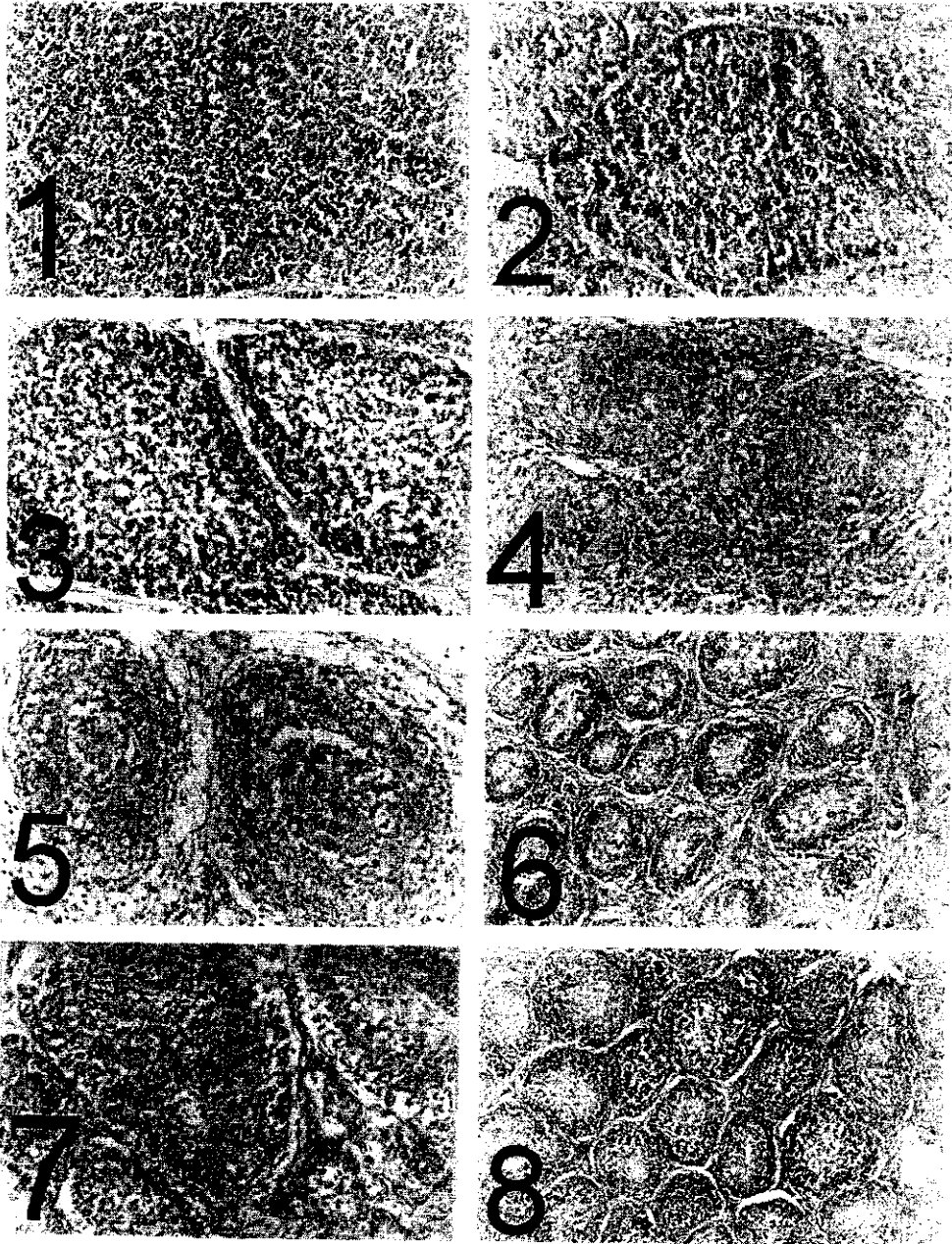
Concerning the phagocytic index in group I at 42 days (2 weeks post challenge with IBDV), the lowest level of phagocytic index was observed in this group compared to other groups. Our results agree with Lam (1998) who recorded IBDV- induced alteration in heterophil and macrophage functions, decrease in phagocytosis and the death of these phagocytic cells may play a role in subsequent immunosuppression in the affected chickens.

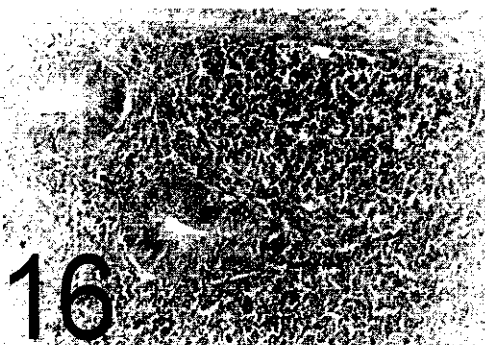

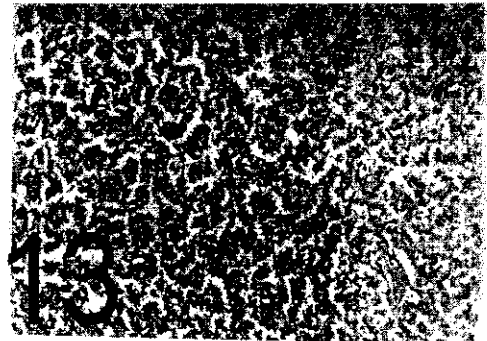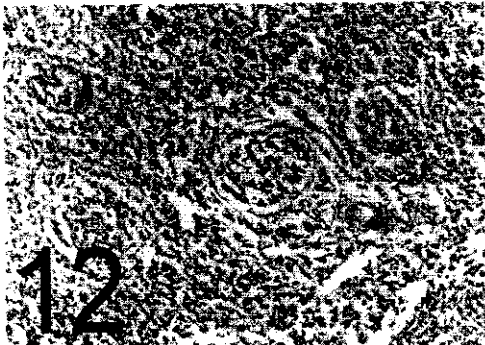
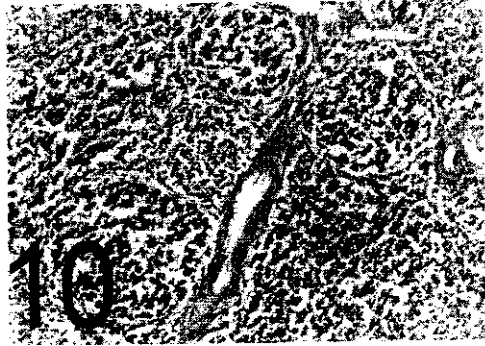
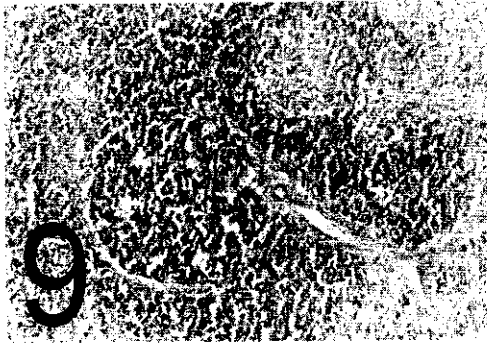Serafino (2008) found that eucalyptus oil is able to induce morphological and functional activation of human monocyte-derived macrophages. Aderem and Underhill (1999) reported that internalization by macrophages occurs by a restricted number of phagocytic receptors present in their surface. We suggest that the obtained stimulatory effect of eucalyptus oil in this study might be attributed to stimulating the complement receptor mediated phagocytosis. Nickels (1996) mentioned that peppermint oil maintains the structure integrity of immune cells due to its strong antioxidant action which protects cell

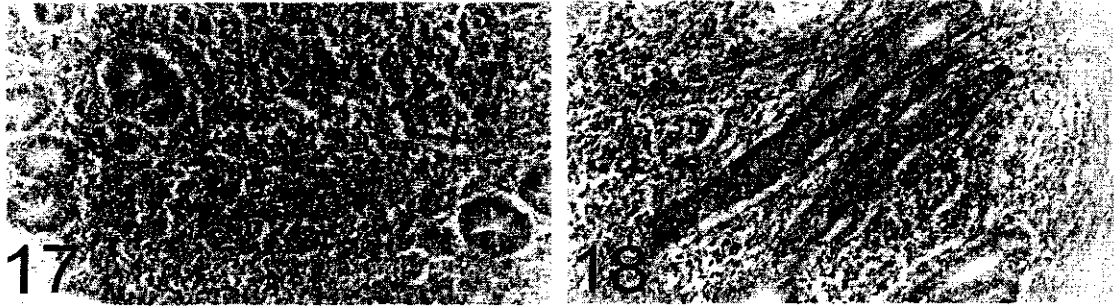
clarified lymphocytic necrosis and depletion, hyperplasia of reticuloendothelial cells, vacuolation of lymphoid follicles, interfollicular lymphocytic cells infiltration and interfollicular connective tissue infiltration of B.F. Lymphocytic depletion and hyperplasia of reticular cells of spleen. Lymphocytic necrosis, depletion, focal hemorrhage of thymus glands. Necrosis and depletion of caecal tonsils. The sum lesion scores were 0, 0, 2 and 1, 1, 5 in volatile oils treated and untreated chickens at 3, 7 and 10 days post IBDV vaccination respectively. While the sum lesion scores reached 21, 23, 14 and 21, 23, 20 in volatile oils treated and untreated chickens at 3, 7 and 10 days post

IBDV infection respectively. On the other hand there was lymphoblast activation reached 1 score in BF in volatile oils treated group only at 3 and 7 days post IBDV vaccination. While no histopathological changes all over the experimental period could be detected in blank control group.

Regarding aforementioned results; our data are indicating that eucalyptus and peppermint oils are able to implement both innate-cell mediated and humoral immune response in chickens. It could be concluded that administration of these volatile oils have a potent immunomodulatory effect and evoke the immune response in chickens.







### Legands of figures:

- Fig. 1:** Bursa of fabricius of chicken from group 1 (1st sample PV) showing slight lymphoblasts activation (H & E X 200).
- Fig. 2:** Bursa of fabricius of chicken from group 2 (1st sample PV) showing no histopathological changes (H & E X 200).
- Fig. 3:** Bursa of fabricius of chicken from group 2 (3rd sample PV) showing lymphocytic necrosis and depletion of lymphoid follicles (H & E X 200).
- Fig. 4:** Bursa of fabricius of chicken from group 3 (1st sample PI) showing lymphocytic necrosis, vacuolations of lymphoid follicles; marked intrafollicular and interfollicular heterophilic cells infiltrations (H & E X 200).
- Fig. 5:** Bursa of fabricius of chicken from group 3 (1st sample PI) showing caseous necrosis of the medulla of lymphoid follicles (H & E X 200).
- Fig. 6:** Bursa of fabricius of chicken from group 3 (3rd sample PI) showing atrophy of lymphoid follicles, interfollicular leucocytic cells infiltrations accompanied with intrfollicular connective tissue proliferation (H & E X 100).
- Fig. 7:** Bursa of fabricius of chicken from group 4 (1st sample PI) showing lymphocytic necrosis, depletion, vacuolations of lymphoid follicles and interfollicular heterophilic cells infiltration (H & E X 200).
- Fig. 8:** Bursa of fabricius of chicken from group 4 (2nd sample PI) showing atrophy of lymphoid follicles associated with interfollicular connective tissue proliferation (H & E X 100).
- Fig. 9:** Spleen of chicken from group 1 (2nd sample PV) showing normal lymphoid follicles (H & E X 200).
- Fig. 10:** Spleen of chicken from group 2 (2nd sample PV) showing slight lymphocytic depletion of some lymphoid follicles (H & E X 200).
- Fig. 11:** Spleen of chicken from group 3 (2nd sample PI) showing marked lymphocytic necrosis and depletion (H & E X 200).
- Fig. 12:** Spleen of chicken from group 4 (3rd sample PI) showing lymphocytic necrosis, depletion and hyperplasia of reticular cells (H & E X 200).
- Fig. 13:** Thymus gland of chicken from group 1 (3rd sample PV) showing no histopathological changes (H & E X 200).
- Fig. 14:** Thymus gland of chicken from group 3 (2nd sample PI) showing lymphocytic necrosis and depletion in both cortex and medulla (H & E X 200).
- Fig. 15:** Thymus gland of chicken from group 4 (1st sample PI) showing slight lymphocytic necrosis and depletion in both cortex and medulla (H & E X 200).
- Fig. 16:** Caecal tonsils of chicken from group 2 (2nd sample PV) showing no histopathological alterations (H & E X 200).
- Fig. 17:** Caecal tonsils of chicken from group 3 (3rd sample PI) showing apparent normal caecal tonsils (H & E X 200).
- Fig. 18:** Caecal tonsils of chicken from group 4 (3rd sample PI) showing marked lymphocytic necrosis and depletion (H & E X 200).

### REFERENCES

- Abdel-Alim, G.A., Awaad, M. H.H., and Y. M. Saif (2003). Characterization of Egyptian field strains of infectious bursal disease virus. *Avian Dis.*, 47: 1452- 1457.
- Aderem, A. and Underhill, D.M. (1999). Mechanisms of phagocytosis in



- macrophages. *Ann Rev Immunol.*, 17:593-623.
- Anon, (2000). Exotidis infectious bursal disease. Exotic disease surveillance information in NewZeland 1-2.
- Anthony, T. W. C.; Twin, K. M. L.; Erin, M. W. and Michael, E. M. (1985). Phagocytic and killing capacities of uterine derived leukocytes from mares resistant and susceptible to chronic endometritis. *Am. J. Vet. Res.*, 46 (9): 1938-1940.
- Awaad M. H. H., A. A. El-Gohary and H. A. Sultan (2002). Effect of volatile oils on concomitant infection of *Ornithobacterium rhinotracheal* "ORT" and velogenic viscerotropic Newcastle disease "VVND" in broiler chickens. *Vet.Med.J. Giza. Vol.50, No.2:289-298.*
- Awaad, M. H. H., F. E. Saad, M. A. Afify, O. A. Elshazly and H. F. El-Menyawi (1999). Immunomodulation of organic acids in chickens. *Esmailia Vet. J. 2, (1): 103-114.*
- Awaad, M. H. H., M. A. Kutkat and F. A. El Shobaki (2000, a). Immunopotential of infectious bursal disease (IBD) vaccination. *Vet Med J. Giza. 48: No.1, 27- 33.*
- Awaad, M. H. H., Sahar, A. Zouelfakar, Elshazly, O. A., Afify, M. A. and Iman, B. Shaheed (2000, b). Immunomodulatory properties of inactivated *Propiobacterium granulosum* (IM-104) 1: In non-immunosuppressed chickens. *J. Egypt. Vet. Med. Ass. 60, No. 7: 137- 148.*
- Bancroft, J.D.; Stevens, A. and Turner, D.R. (1996). *Theory and Practice of Histological Techniques.* 4th Ed. New York, Churchill, Livingstone.
- Barbour, EK. (2006). Evaluation of histopathology of the respiratory system in essential oil-treated broilers following a challenge with *Mycoplasma gallisepticum* and/or H9N2 influenza virus. *Intern J. Appl. Res Vet Med. Vol.4, No.4, 293-300.*
- Boyum, A. (1968). "Isolation of mononuclear cells and granulocytes from human blood". *Cand. J. Clin. Invest.*, 21:77-89.
- Cao, Y. C., Young, W. S., law, M., BI, Y. Z., Leung, F. C., and Lim, B.L (1998). Molecular characterization of seven Chinese isolates of infectious bursal disease virus: classical, very virulent, and variant strains. *Avian Dis.*, 42: 340- 351.
- Chettle, N. J., and P. J. Wyeth (1989). Failure of maternally derived infectious bursal disease antibodies to serotype 1 and 2 to protect against heterologous virus. *British. Vet. J.*, 145 (2): 165- 169. Mar-Apr.
- Chu, Yi and Dietert, R. R. (1989). Monocyte functions in chicken with hereditary dystrophy. *Poult. Sci.*, 68: 226-232.
- Cosgrove, A.S. (1962). An apparently new disease of chickens-avian nephrosis. *Avian Dis.* 6, 385-389.
- Emmerich, B, K. Pachmann, M. Hallek, D. Milatovic, M. L. Lohmann-Mathes, R. Busch, H. P. Emslander (1988). Immunomodulation with bacterial extracts: Effects on gamma interferon, macrophages, T-lymphocytes and S-IgA in bronchoalveolar lavage fluid patients with chronic bronchitis. 7th. Congress of the European Society of Pneumology (SEP), Budapest, Hungary.
- Hanks,D. H. and Wallace, O. H. (1985). "Determination of cell viability". *proc. Soc. Exp. Biol. Med.* 98:183-192.
- Hitchner, S. B. (1970). Infectivity of infectious bursal disease virus for embryonating eggs. *Poult. Sci.* 49:511-516.
- Iscan, G.; Kirimer, N.; Kurkeuglu, M.; Baser, K.H. and Demirci,F. (2002). Antimicrobial screening of *Mentha piperita* essential oils. *J. Agric. Food Chem.* July. 3; 50 (14): 3943-3946.
- Juergens, U.R.; Stober, M. and Vetter, H. (1968). Inhibition of cytokine production and arachidonic acid metabolism by eucalptol(1,8 cineole) in human blood

- monocytes in vitro. *Eur J. Med. Res.* 3:508-510.
- Lam, K. M. (1998). Alteration of chicken heterophil and macrophage functions by the infectious bursal disease virus. *Microb. Pathog.*, 25(3):147-155.
- Mekay, D.L. and Blumberg, J.B. (2006). A review of the bioactivity and potential health benefits of peppermint tea (*Mentha piperita* L). *Phytother Res.* 20(8) 619-633.
- Murphy, F.A., Gibbis, .E.P.J., Horzinek, M. C. and Studdert, M.J. (1999). Birnaviridae. In: *Veterinary Virology*, third edition. Academic Press, San Diego, California, USA. chapter 25, 405-409.
- Nickels, CH. F. (1996). Antioxidant improve cattle immunity following stress. *Animal feed Science and Technology*, 62(1): 59-68.
- Pertile, T. L., Sharma, J. M., Walsler, M. M. (1995). Reovirus infection in chickens primes splenic adherent macrophages to produce nitric oxide in response to T-cell produced factors. *Cell immunol.* 164:207-216.
- Petrie, A. and Weston, P. (1999). *Statistics for Veterinary and animal science.* 1st Ed., pp. 90-99, the Blackwell Science Ltd, United Kingdom.
- Reed, L. J., and H. A. Munech (1983). Simple method for estimation of fifty percent end-point. *Am. J. Hyg.* 27:493- 497.
- Rosales, A. G., Villegas, P., Lukert, P. D., Fietcher, D. J., Mohamed, M. A., and Brown, J. (1989). Isolation, identification and pathogenicity of two field strains of infectious bursal disease virus. *Avian Dis.*, 33: 35-41.
- Rosenberger, J. K. (1994). The role of IBD in immunosuppression. *World Poultry Misset Supplement (Gumboro)*, 7.
- Schlitz, L. A. (1987). "Methods in clinical chemistry". The C.V. MosbyLost Louis 742-746.
- Schuhmacher, A.; Rrichling, J. and Schnitzler, P.(2003). Virucidal effect of peppermint oil on the enveloped viruses herpes simplex virus type 1 and type 2 in vitro. *Phytomedicine* 10:504-510.
- Serafino, A.; Vallebona, P. S.; Andreola, F.; Zonfrillo, M; Rasi,J.; Garaci, E. and Pierimachi, P. (2008). Stimulatory Effect of eucalyptus essential oil on innate cell-mediated immune response. *BMC immunology* April 18; 9:17
- Sharma, J. M. Dohms, J. E. and Metz, A. L. (1989). Comparative pathogenesis of serotype 1 and variant serotype 1 of infectious bursal disease virus and their effect on specific pathogen free chickens. *Avian Dis.* 33: 112- 124.
- Sheble, A and Reda, I. M. (1976). Cited by Khaphagy, A. K. (1977), M. V. Sc. Thesis, Faculty of Veterinary Medicine, Cairo University.
- SPSS (1999). "Statistical package for social science, Spss for windows Release 11.00", Standard version copyright Spss Inc., 1989 2002, All rights Reserved, copyright © Spss Inc.
- Stafford, J. L.; Neumann, N. F. and Belosevic, M. (2002). Macrophage-mediated innate host defense against protozoan parasites. *Crit. Rev. Microbiol.* 28: 187-248.
- Swayne, D. E., Glisson; J. R., Jackword, M. W.; Person, J.E. and Reed, W. M. (1989). *A laboratory manual for isolation and identification of avian pathogens.* 4th.Ed.
- Tayfun Carli; K., Kaan Onat and Elcin Gunaydin (2006). The use of Mentofin in broilers with clinical Infectious Bursal Disease to reduce E.coli-dependent problems after vaccination against Newcastle Disease.
- Tizard, I. (1996). "An introduction to veterinary immunology" 5th. Ed., Saunders publishers, Philadelphia. pp 30-38.

## التأثير المناعي لزيوت النعناع واللايكوليبيتس علي الدجاج المصاب بمرض الجمبورو

محمد حسين حسن عواض، جمعه عبد العظيم عبد العليم، خالد سيد شعبان سيد، كوكب عبد العزيز أحمد، عبد الفتاح عبد الحميد ندا\* وأحمد صلاح زيدان متولي  
كلية الطب البيطري – جامعة القاهرة  
\*معهد بحوث صحة الحيوان – الدقي

تمت دراسة التأثير المنشط للمناعة لزيوت النعناع واللايكوليبيتس في بداري التسمين المثبطة مناعيا اما بعدوي فيروس الجمبورو أو بالتحصين ضده.

لم يكن هناك أي فروق معنوية في مستوى المناعة عند قياسها باختبار التلازن الدموي ضد مرض النيوكاسل بين المجموعات المعالجة والغير معالجة عند أي مرحلة فحص. بينما وصلت درجة الحماية عند اختبار تحدي المناعة الي 35% في المجموعة المعالجة بزيوت النعناع واللايكوليبيتس مقارنة ب25% في الغير معالجة و0% في مجموعة الضوابط الغير محصنة ضد مرض النيوكاسل.

كان هناك زيادة معنوية في وزن البرسا الي وزن الجسم في المجموعة المعالجة بزيوت النعناع واللايكوليبيتس مقارنة بالغير معالجة.

كان هناك زيادة معنوية في مستوى المناعة الخلوية في المجموعة المعالجة بزيوت النعناع واللايكوليبيتس مقارنة بالغير معالجة.

أثبت الفحص النسيجي الباثولوجي وجود آفة تشريحية في الانسجة المناعية الرئيسية بعد عدوي فيروس الجمبورو أو التحصين ضده بينما الطيور التي تم علاجها بزيوت النعناع واللايكوليبيتس كان هناك زيادة في نشاطها.

الخلاصة أثبتت الدراسة أن زيوت النعناع واللايكوليبيتس لها تأثير قوي في تحسين المناعة في الطيور المثبطة مناعيا بعدوي أو التحصين بفيروسات مرض الجمبورو.