

Department of Wildlife and Zoo Medicine,
Faculty of Veterinary Medicine, Suez Canal University, Ismailia, Egypt.

**PULMONARY AND SUBMANDIBULAR LYMPH
NODE ABSCESSSES IN A WHITE – TAILED DEER
(ODOCOILEUS VIRGINIANUS)**
(With One Table and One Figure)

By

RABAB AFIFI; J.M. SLEEMAN*; G.K. SAUNDERS
and T. KAUR****

* Department of Biomedical Sciences and Pathobiology,

Virginia, Maryland Regional College of Veterinary Medicine, USA.

**U.S. Geological Survey, National Wildlife Health Center, 6006 Schroeder
Road, Madison, Wisconsin 53711, USA.

(Received at 3/10/2009)

**خراجات رئوية والعقدة الليمفاوية تحت الفك السفلي في الايل ابيض الذيل
(Odocoileus Virginianus)**

رباب عفيفي ، جونسون سليمان ، جيفيري ساندر ، ترنجيات كار

أنثى الايل ابيض الذيل (ضعيفة ، مرضعة ، غير متزنة) قدمت للتشريح كجزء من برنامج لمراقبة مرض الهزال المزمن (CWD). الفحوصات المعملية لمرض الهزال المزمن ومرض داء الكلب جاءت سلبية. في حين كشفت تشريح الجثة عن وجود خراجات رئوية والعقدة الليمفاوية تحت الفك السفلي المرتبطة بميكروب الزكينيوكتيريم المقحية والبستريلا. العرض الاجمالي يشير الي أن العدوي قد تكون مرتبطة بالاجهاد المزمن لاييل.

SUMMARY

A thin, lactating and uncoordinated female white-tailed deer was submitted for necropsy as part of a surveillance program for chronic wasting disease (CWD). Laboratory tests for CWD and rabies were negative. Post-mortem examination revealed pulmonary and submandibular lymph node abscesses associated with *Arcanobacterium pyogenes* and *Pasteurella*. The overall presentation suggests that the infections may have been associated with chronic stress.

Key words: *Arcanobacterium pyogenes*, chronic stress, chronic wasting disease, deer, *Pasteurella*.

INTRODUCTION

Arcanobacterium pyogenes (formely *Actinomyces pyogenes* and *Corynebacterium pyogenes*) is nonmotile, facultatively anaerobic, gram-positive bacterium (Ames *et al.*, 2002) that can cause a wide variety of nonspecific suppurative lesions invading various visceral organs (Baumann *et al.*, 2001). *Arcanobacterium pyogenes* produces a range of disease condition in domestic ruminant and wild ruminant including pneumonia, mastitis, abscessation, endocarditis, pyometra, endometritis and umbilical infection (Davidson *et al.*, 1990). In Cervidae, *A. pyogenes* has been implicated in fetal pleuropneumonia in (white tailed deer), intracranial abscess in (white tailed deer), mastitis with subsequent disseminated disease in (white tailed deer), chronic fibrinopurulent bronchopneumonia with abscessation in (free ranging Elk), necrobacillosis in (deer and antelope), foot abscess in (free ranging fellow deer), metritis, endocarditis and abortion in (white tailed deer) as seen on Table 1.

Table 1: *Arcanobacterium pyogenes* isolated from cervidae associated with potential stressor and pasteurilla infection.

Animal species	Lesion(s)	Potential stressors
Mule deer	cerebral abscess ^a	parasitic infestation (Johnson <i>et al.</i> , 1983).
Reindeer	Subcutaneous abscess ^a	overcrowding (Zulty and Montali 1988).
White tailed deer	intracranial abscess ^a	subcutaneous infection adjacent to antler pedicle, pedicle fractures (Davidson <i>et al.</i> , 1990).
Elk	chronic fibropurulent bronchopneumonia ^{a,b}	predation/hunting (Rhyan <i>et al.</i> , 1997).
White tailed deer	Mastitis with subsequent Disseminated disease ^a	radio collar (Turnquist and Fales, 1998).
White tailed deer	fetal pleuropneumonia ^a	pregnancy, capture, transport (Palmer and Whipple, 1999).
White tailed deer	intracranial abscess ^{a,c}	seasonal (breeding and predation); trauma to antlers and skin (Baumann <i>et al.</i> , 2001).
White tailed deer	mandibular abscess ^a	overcrowding (Chirino-Trejo <i>et al.</i> , 2003).
Fallow deer	foot abscess ^a	Humidity; species competition;
White tailed deer	pneumonia, abscess ^{a,c}	predation; handling (Lavin <i>et al.</i> , 2004). handling, overhandling (Haigh <i>et al.</i> , 2005).

^a *Arcanobacterium pyogenes*

^b *Pasteurella multocida*

^c Other genera of bacteria including *Pasteurella* species

MATERIALS and METHODS

A female white-tailed deer (*Odocoileus virginianus*) was observed on August 1, 2007 in Russell County, Virginia by a field biologist working in conjunction with Virginia's Department of Game and Inland Fisheries (VDGIF). The deer was observed to be very thin and uncoordinated. As part of the VDGIF's targeted surveillance program for Chronic Wasting Disease (CWD), she was euthanized by gunshot and transferred to the Virginia Department of Agriculture and Consumer Services laboratory for post-mortem evaluation. The doe was approximately 7 years old, lactating and thin. Old superficial skin lacerations were found on her right ventral neck. Both submandibular lymph nodes were enlarged and contained abscesses filled with a thick caseous exudate (Figure 1A). Multifocal areas of consolidation and abscesses were present in both lungs; some of the abscesses were approximately 2 cm in diameter (Figure 1B). There was nasopharyngeal myiasis. The gastrointestinal tract, liver, kidneys, spleen, urinary bladder, uterus and brain were grossly normal.

Brain tissues were removed aseptically and transferred to VDGIF for analysis for CWD and rabies virus. Brain culture swabs were sent to the Virginia-Maryland Regional College of Veterinary Medicine (VMRCVM) for anaerobic bacteria on PRAS Brucella agar plates (Anaerobe Systems, Morgan Hill, California 95037 USA). Brain was cultured for *Listeria monocytogenes* in BHI Broth (Remel, Lenexa, Kansas 66215 USA) for 12 weeks at 4 °C with weekly sub-culturing of broth onto Columbia blood agar with 5% sheep blood (Remel, Lenexa, Kansas 66215 USA).

Submandibular lymph nodes, lung, and intestine were taken aseptically for culture. Samples from lymph nodes were cultured for aerobic bacteria on Tryptic Soy agar, MacConkey agar II, Columbia CNA agar. Lung tissue was cultured for aerobic bacteria on chocolate 2, blood, MacConkey Agar II, and Columbia CNA agar (Becton, Dickinson and Company, Fisher Scientific, Suwanee, Georgia 30024 USA), and for *Mycoplasma* on PPLO agar (University of California, Davis, California 95616 USA). Salmonella enrichment culture was performed on intestine using Tetrathionate Broth (Becton, Dickinson and Company, Fisher Scientific, Suwanee, Georgia 30024 USA) and Hektoen Enteric agar (Virginia Department of Agriculture and Consumer Services, Wytheville Animal Diagnostic Laboratory,

Wytheville, Virginia 24382 USA). Blood, Columbia CNA and chocolate agar plates were incubated in 5% CO₂ at 37 °C. Hektoen and MacConkey Agar plates were incubated at 37 °C with no CO₂. PPLO agar plates were kept in a humidity chamber and placed in 5% CO₂ at 37 °C for 7 days.

Lung, lymph node, brain, spleen, liver, intestine and heart samples were preserved in 10% neutral buffered formalin for histopathologic examination. Feces and nasopharyngeal samples were taken for parasite analysis. The zinc sulfate flotation method was used for fecal analysis and parasite identification was done by microscopic examination (Zajac *et al.*, 2002).

RESULTS

Arcanobacterium pyogenes was isolated from lung and submandibular lymph node, and identified using bioMérieux API Coryne strips (bioMérieux, Inc., Durham, North Carolina 27712, USA). *Pasteurella* spp. was isolated from the same lymph node, and identified using bioMérieux API 20 NE strip (bioMérieux, Inc., Durham, North Carolina 27712, USA). Laboratory tests for rabies, CWD, *Listeria*, *Mycoplasma*, *Mycobacterium* and *Salmonella* were all negative. Histopathologic examination was performed on lung, brain, spleen, lymph node, intestine, heart and liver. The intestine was severely autolyzed. The lung had multiple discrete nodules of coagulative necrosis containing neutrophils and macrophages (Figure 1C). A rim of neutrophilic inflammation surrounded the necrosis; peripheral to this was a layer of fibroplasia and fibrosis. A few nodules contained fibrin circumscribed by fibrosis. Alveoli adjacent to the nodules were distended with foamy, pale basophilic fluid or filled with fibrin. Between the nodules, lung tissue had neutrophils, macrophages and fibrin filling alveoli. The brain had a single focus of hemorrhage within the cerebral cortex adjacent to the lateral ventricle. No reaction to the hemorrhage was seen. Nasopharyngeal myiasis was identified as *Cephenemyia* spp. (nasal bot) and *Trichostrongylus* spp. was found in the feces.

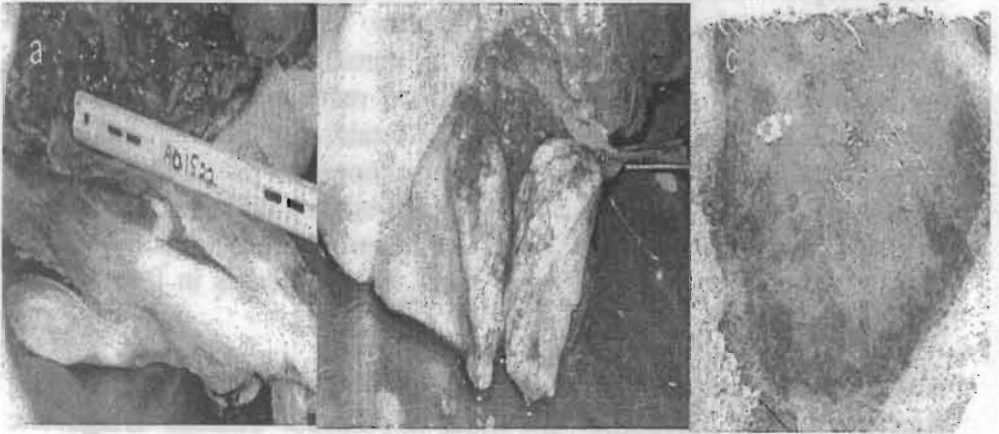


Fig. 1: Pulmonary and submandibular lymph node abscesses associated with *Arcanobacterium pyogenes* in a white-tailed deer (*Odocoileus virginianus*).

- A. *Arcanobacterium pyogenes* and *Pasteurella* were cultured from submandibular lymph node abscesses.
- B. Pulmonary abscess and multifocal areas of consolidation due to *A. pyogenes*.
- C. Section of lung with fibrinopurulent and necrotizing bronchopneumonia due to mixed *Pasteurella* and *A. pyogenes* infection; a discrete nodule of coagulative necrosis (arrows) containing neutrophils and macrophages (Bar = 25 μ m).

DISCUSSION

Pasteurella is a common commensal in the upper respiratory tract of domestic and wild animals (Jaworski *et al.*, 1998). It is the most common cause of pneumonia in ruminants. Isolation of *Pasteurella* from the submandibular lymph node suggests that it was in the doe's lung at one time. *A. pyogenes*, generally an opportunistic organism mainly presenting as a mixed infection in stressed animals, may have entered the doe's body through neck lacerations or compromised nasal and gastrointestinal mucosa. In conclusion, even though it was not isolated from the lung, *Pasteurella* was the primary cause of infection in the lung and from there it spread to the lymph node. *A. pyogenes* was considered to be a secondary infection in the lungs where pneumonia was already present. The final diagnosis was pulmonary and lymph node abscesses due to *A. pyogenes* and fibrinopurulent and necrotizing

bronchopneumonia due to a mixed *Pasteurella* and *A. pyogenes* infection. Based on the doe's history and presentation, some combination of stressors likely led to chronically high stress levels sufficient to suppress the doe's immune response, thereby allowing *Pasteurella* and *A. pyogenes* to become established in lung and lymph nodes, and cause the fulminant bronchopneumonia. Table 1 lists previously reported clinical cases of *A. pyogenes* infection reported in cervidae with exposure to potential stressors and in some cases, *Pasteurella* co-infection, including cases with abscesses in free ranging white-tailed deer.

Acknowledgment(s): The authors thank the Virginia Department of Agriculture and Consumer Services, Wytheville Animal Diagnostic Laboratory and J. Wills, Virginia Department of Game and Inland Fisheries for assistance with this case.

REFERENCES

- Ames, T.R.; Baker, J.C and Wikse, S.E. (2002):* The Bronchopneumonias. In Smith B.P (ED). Large animal Internal Medicine, 3RD ED, Mosby INC., St. Louis., Missouri. PP. 551-552.
- Baumann, C.D.; Davidson, W.R.; Roscoe, D.E. and Beheler-Amass, K. (2001):* Intracranial abscessation in white-tailed deer of North America. *J. Wildl. Dis.* 37: 661-670.
- Chirino-Trejo, M.; Woodbury, Woodbury, M.R. and Huang, F. (2003):* Antibiotic sensitivity and biochemical characterization of *Fusobacterium* spp. and *Arcanobacterium pyogenes* isolated from farmed white-tailed deer (*Odocoileus virginianus*) with necrobacillosis. *J. Zoo Wildl. Med.* 34: 262-268.
- Davidson, W.R.; Nettles, V.F.; Hayes, L.E.; Howerth, E.W. and Couvillion, C.E. (1990):* Epidemiologic features of an intracranial abscessation/suppurative meningoencephalitis complex in white-tailed deer. *J. Wildl. Dis.* 26: 460-467.
- Haigh, J.; Bere, Zowski, J. and Woodbury, M.R. (2005):* A cross-sectional study of the causes of morbidity and mortality in farmed white-tailed deer. *Can. Vet. J.* 46: 507-512.
- Jaworski, M.D.; Hunter, D.L. and Ward, A.C. (1998):* Biovariants of isolates of *Pasteurella* from domestic and wild ruminants. *J. Vet. Diagn. Invest.* 10: 49-55.

- Johnson, J.L.; Campbell, J.B.; Doster, A.R.; Nason, G. and Cagne, R.J. (1983):* Cerebral abscess and *Cephenemyia* phobifer in a mule deer in central Nebraska. *J. Wildl. Dis.* 19: 279-280.
- Lavin, S.; Ruiz-Bascaran, M.; Marco, I.; Abarca, M.L.; Crespo, M.J. and Franch. J. (2004):* Foot infections associated with *Arcanobacterium pyogenes* in free-living fallow deer (*Dama dama*). *J. Wildl. Dis.* 40: 607-611.
- Palmer, M.V. and Whipple, D.L. (1999):* *Arcanobacterium pyogenes* as a cause of fatal pleuropneumonia after capture and transport of white-tailed deer (*Odocoileus virginianus*). *J. Vet. Diagn. Invest.* 11: 468-471.
- Rhyan, J.C.; Aune, K.; Ewalt, D.R.; Marquardt, J.; Mertins, J.W.; Payeur, J.B.; Saari, D.A.; Schladweiler, P.; Sheehan, E.J. and Worley, D. (1997):* Survey of free-ranging elk from Wyoming and Montana for selected pathogens. *J. Wildl. Dis.* 33: 290-298.
- Turnquist, S.E. and Fales. W.H. (1998):* Disseminated *Actinomyces pyogenes* infection in a free-ranging white-tailed deer. *J. Vet. Diagn. Invest.* 10: 86-89.
- Zajac, A.M.; Johnson, J. and King. King, S.E. (2002):* Evaluation of the importance of centrifugation as a component of zinc sulfate fecal flotation examinations. *J. Am. Anim. Hosp. Assoc.* 38: 221-224.
- Zulty, J.C. and Montali, R.J. (1988):* *Actinomyces pyogenes* infection in exotic Bovidae and Cervidae: 17 cases (1978-1986). *J. Zoo Anim. Med.* 19: 30-32.