

College of Veterinary Medicine,
Sudan University of Science and Technology
P. O. Box 204, Hilat kuku, Khartoum North, Sudan
E-mail: rehabeen@yahoo.co.uk

**ULTRASONOGRAPHY AS A DIAGNOSTIC TOOL FOR
FETAL MORTALITY IN GOATS (*CAPRA HIRCUS*)
IN THE SUDAN
"TWO CASE REPORTS"
(With 2 Figures)**

By

RIHAB MOHAMED ABDELGHAFAR OSMAN

(Received at 23/8/2010)

SUMMARY

Two cases of fetal mortality were reported in caprine does. The first case was an apparently healthy Damascus doe presented for pregnancy diagnosis at 62 days post insemination. The other a Saanen doe, presented to the clinic because of anorexia, dyspnoea, inability to stand, severely enlarged abdomen, anestrus and prolonged gestation. Transabdominal ultrasonographic examination was done using two real-time ultrasound scanners: Fukuda, Denshi (Japan) equipped with 3.5 MHz curvilinear probe and Pie Medial, Easote, (Holland) equipped with dual frequency 5-7.5 MHz micro convex probe. The animals were well restrained on dorsal recumbancy. In the first doe (Damascus) ultrasound scanning revealed numerous highly echogenic cotyledons, with a few amount of fetal fluid; the fetus was barely visible measuring 3.5 cm. It was ill-defined with outline contours only. The fetus showed no heart beats and movements. The case was diagnosed as intrauterine fetal death. In the second doe (Saanen), there was a highly echogenic compact mass attached to the uterine wall with anechoic surrounding fluid. Abnormally shaped and sized placentomes were visible. The case was diagnosed as mummified fetus. In conclusion ultrasound was found to be an efficient and reliable aid in diagnosing obstetrical disorders in caprines.

Key words: *Ultrasound, Goat, Mummification, Intrauterine fetal death.*

INTRODUCTION

Early and accurate diagnosis of pregnancy is of considerable value in improving efficiency of production in dairy goat herds by limiting the number of non-productive days (Gonzalez, *et al.*, 2004; Romano and Christians 2008).

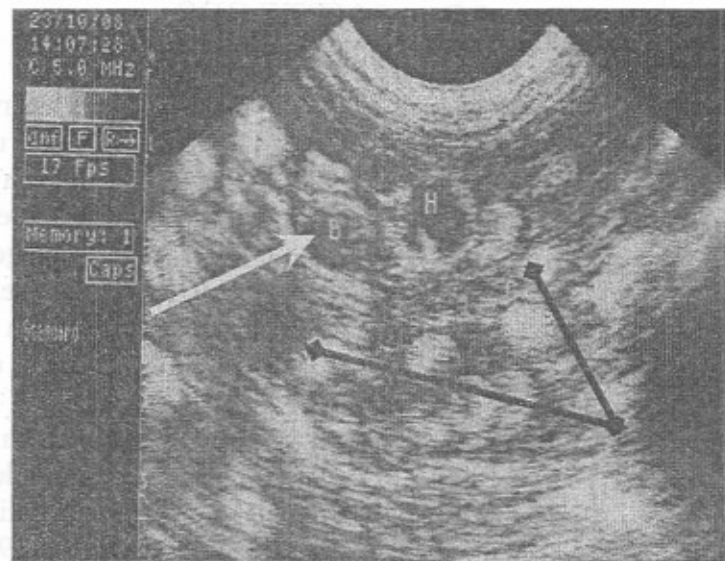
Reproductive assessment plays an important role in production increase, because most reproductive failures are due to death during pregnancy or due to pregnancy expectations in females with false pregnancy (Azevedo, *et al.*, 2007). Ultrasound nowadays is used for many species of animals; not only as a routine clinical examination for pregnancy diagnosis but also to assess physiological structures and pathological changes of the genital tract (Hesselink and Taverene 1994). The potential use of ultrasonography in research for early detection of viable embryos and monitoring embryo mortality is unlimited (Beal, *et al.*, 1992). In sheep, embryonic and fetal mortality contributes to a large economic loss (Dixon, *et al.*, 2007). The causes of fetal death are manifold, but can be divided broadly into infectious and non-infectious (Jonker, 2004). In farm animals, a pregnancy check during the fetal period is usually made only in those cases in which there are doubts with regard to whether the animal is still pregnant or when there are clear signs of threatened pregnancy loss (Jonker, 2004). Mummification of the fetus is a curious, but uncommon event. It is one of the possible outcomes of fetal death, but no specific cause has been identified for the mummification of the bovine fetus; and early embryonic death constitutes the largest percentage of pregnancy wastage (Acland, 2001; Drost, 2007). Ultrasonography has proved to be an extremely valuable tool in obstetrics and it provided practitioners with a non-invasive and non-disruptive means to directly image the reproductive tract and its contents (England 1995; Griffin 1995). It is also used in delineating different pathological conditions of the bovine genital tract which are less frequently described (Kumar and Purohit, 2009). In Sudan although there were few articles concerning use of ultrasound techniques for pregnancy diagnosis, determination of fetal numbers and prediction of gestational age in Saanen goats (Abdelghafar, *et al.*, 2007b; Abdelghafar *et al.*, 2007a), pregnancy diagnosis and fetal quantification in Damascus goats (Abdelghafar, *et al.*, 2009) and diagnosis of hydrometra and pyometra in goats (Ahmed, *et al.*, 2010); this article is the first in the country to describe fetal mummification and intrauterine fetal death in caprine does using real-time ultrasonography.

MATERIALS and METHODS

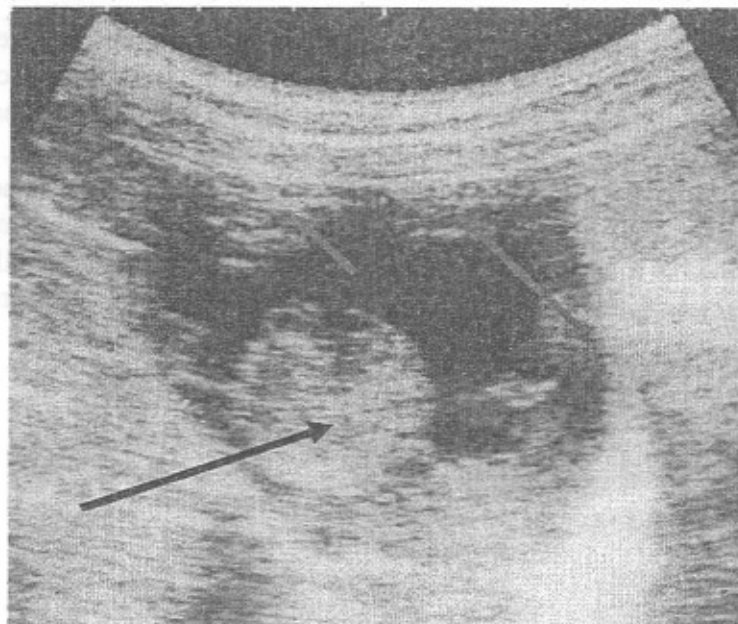
Two does (Saanen and Damascus), their ages were between 4-6 years and weighing 40-60 kgs were subjected to pregnancy diagnosis using real-time ultrasonography. Area between the udder and hind limbs, on both sides and 10 cm cranially to the udder were clipped and shaved carefully using manual clippers. Sufficient amount of ultrasound gel (Sonogel, ® Vertriebs GMBH 65520 Bad Camberg-Germany) was applied to the area of scanning. Animals were well restrained on dorsal recumbancy on a table with a pillow put underneath. Transabdominal ultrasound was done using two real-time scanners Fukuda, Denshi, (Japan) equipped with 3.5 MHz curvilinear probe and Pie Medical Easote, (Holland) equipped with dual frequency (5-7.5) MHz micro convex probe. Images were recorded in thermal papers, Sony type 1 (Normal), UPP-110S, 1-7-1, Konan, Minato-KU, Tokyo, Japan using special printer, Video graphic printer UP-895EC, Sony, Japan.

RESULTS

In the first case (Damascus doe) ultrasound examination revealed several highly echogenic placentomes close to each other with scanty amount of fetal fluid; the uterine lumen was not greatly distended. A barely visible, ill-defined fetus with only outer contours was demonstrated. The Crown- Rump Length of the fetus measures 3.5 cm (Fig. 1) with absence of heart beats and movements. In the second doe, ultrasound scanning revealed a highly echogenic compact mass attached to the uterine wall and surrounded by a few amount of anechoic fluid (Fig. 2). Few abnormally shaped and sized placentomes were visible.



**Fig. 1: Dead fetus (Yellow arrow)
Placentomes (Purple arrow)**



**Fig. 2: Mummified fetus (Black arrow),
Placentomes (Red Arrow)**

DISCUSSION

Embryonic and fetal mortality reduce lambing rates and thus contribute to economic loss in the sheep industry (Dixon *et al.*, 2007). Fetal mortality using ultrasound techniques was reported all over the world, to the best of our knowledge this is the first report of fetal mortality in the Sudan in caprine does using ultrasound technique. In the first case (Damascus doe) presented here, no fetal heart beats or movements were recorded. Hesselink and Taverne (1994) reported that the absence of fetal movements and heart beats are the first ultrasonographic signs of fetal death. The fetus was ill-defined and small in size as compared for its gestational age.

At 62 days of gestation the CRL should measure at least 11 cm (Abdelghafar, *et al.*, 2007a). Due to the few amount of fetal fluids the uterine lumen appeared small and the cotyledons became close to each other. The case was diagnosed as intrauterine fetal death. In the second case (Saanen doe) ultrasonography showed a highly echogenic compact mass resembling high density tissues, this is in accordance with Hesselink and Taverne (1994) who reported that mummified fetuses or remnants of fetal bones show echogenic properties consistent with high tissue density. In combination with clinical examination which revealed closed cervix, history of the prolonged gestation beyond nine months and failure of the doe to return to estrus, the case was diagnosed as mummified fetus. Jones *et al.* (1997) reported that fetal death and mummification will lead to persistence of the corpus luteum of pregnancy in which the animal appears to remain pregnant beyond the usual time of gestation. No signs of bacterial infection, but dyspnoea and inability to stand were due to the great distention of the abdomen which hampers respiration. The obtained findings in goats are in agreement with Kumar and Purohit (2009) who reported that ultrasound proved to be a useful supplement to confirm developmental abnormalities such as mummified and macerated fetus in bovine (as the animal failed to return to estrus and the gestational period extended beyond the normal limits).

In conclusion pathological changes of the uterus of the doe can be diagnosed efficiently by transabdominal real-time ultrasonography, which proved to be harmless, easily applicable and efficient tool.

ACKNOWLEDGMENT

Great thanks are due to the Sudan University of Science and Technology for providing all the facilities for the study. I am also indebted to Dr Sharaf Eldinn Makawi, Department of Obstetrics and Gynecology, University of Khartoum, and Prof. Abdelhamid Ahmed Alfadil, College of Veterinary Medicine, Sudan University of Science and Technology for their valuable recommendations and comments.

REFERENCES

- Abdelghafar, R.M.; Abdallah, S.A. and Ahmed, B.H. (2009):* Pregnancy diagnosis and fetal quantification in Damascus goats using transabdominal real-time ultrasonography. *Assiut, Vet. Med. J. 55(123): 273-279.*
- Abdelghafar, R.M.; Ahmed, B.H. and Bakheit, A.O. (2007a):* Crown- Rump Length and Bi Parietal Diameter to predict gestational age in Saanen goats. *Journal of Animal and Veterinary Advances 6 (3): 454-457.*
- Abdelghafar, R.M.; Bakheit, A.O. and Ahmed, B.H. (2007b):* B-Mode real-time ultrasonography for pregnancy diagnosis and fetal numbers in Saanen goats. *Journal of Animal and Veterinary Advances, 6 (5): 702-705.*
- Acland, A.M. (2001):* Reproductive System: Female, In Thomson's special Veterinary Pathology pp 601-614, Ed. 3. Mosby, Inc, a Harcourt Health Sciences Company, 11830 West line Industrial Drive, St. Louis, Missouri 63146.
- Ahmed, B.H.; Hamad, R.J. and Abdelghafar, R.M. (2010):* Ultrasonography for diagnosis of hydrometra and pyometra (two case reports). *Assiut, Vet. Med. J. 56 (124): 225-229.*
- Azevedo, E.; Aguiar Filho, C.; Freitas Neto, L.; Robelo, M.; Santos, M.; Lima, P.; Freitas, V. and Oliveira, M. (2007):* Ultrasound fetal measurement parameters for early estimate of gestational age and birth weight in ewe, *Medicina Veterinaria, (1): 2, 56-61.*
- Beal, W.E.; Perry, R.C. and Corah, L.R. (1992):* The use of ultrasound in monitoring reproductive physiology of beef cattle. *J. Anim. Sci. 70: 924-929.*
- Dixon, A.; Knights, M.; Winker, J.; Marsh, D.; Pates, J.; Wilson, M.; Dailey, R.; Seidel, G. and Inskoop, E. (2007):* Patterns of late embryonic and fetal mortality and association with several factors in sheep. *Journal of Animal Science, 85: 1274-1284.*

- Drost, M. (2007):* Complications during gestation in the cow, *Theriogenology* (86): 487-491.
- England, G.C. (1995):* Small Animal Reproductive Ultrasonography. In Goddard, P.J. *Veterinary Ultrasonography*. pp. 55-85 Cab International. Wallingford, Oxon OX108DE. UK.
- Gonzalez, F.; Cabrera, F.; Batista, M.; Rodriguez, N.; Alamo, D.; Sulon, J.; Beckers, J. and Gracia, A. (2004):* A comparison of diagnosis of pregnancy in the goat via transrectal ultrasound scanning, progesterone, and pregnancy-associated glycoprotein assays. *Theriogenology*, 62: 1108-1115.
- Griffin, P.G. (1995):* Equine Reproductive Ultrasonography. In Goddard, P. J. *Veterinary Ultrasonography*. pp. 165-184. Cab International Wallingford, Oxon OX108DE. UK.
- Hesselink, J.W. and Taverne, M.A. (1994):* Ultrasonography of the uterus of the goat, *Veterinary Quarterly* (16): 1: 41-45.
- Jones, T.C.; Hunt, R.D. and King, N.W. (1997):* Genital system in: *Veterinary Pathology*. 6th edition, Williams and Wilkins company pp 1149- 1221.
- Jonker, F. (2004):* Fetal death: Comparative aspects in large domestic animals, *Animal Reproduction Science* (82-83): 415-430.
- Kumar, V. and Purohit, G.N. (2009):* Ultrasonographic diagnosis of the bovine genital tract disorders. *Online Veterinary Journal* (4): 2: 43.
- Romano, J.E. and Christians, C.J. (2008):* Early pregnancy diagnosis by transrectal ultrasonography in ewes. *Small Ruminant Research*, 72: 51-57.