

Animal Health Research Institute,  
Assiut Laboratory.

**ROLE OF RED SWAMP CRAYFISH FOR  
TRANSMISSION OF FLAVOBACTERIAL INFECTION  
TO AFRICAN SHARPTOOTH CATFISH,  
*CLARIAS GARIEPINUS*  
(With 6 Tables and 3 Figures)**

By

**AYA G. SAAD EL-DEEN and SH.M. AHMED\***

\*Fish Diseases and Management, Department of Animal Medicine,  
Faculty of Veterinary Medicine, Assiut University;  
(Received at 15/9/2010)

**دور أسماكوزا المستنقعات الحمراء في نقل عدوى الفلافوباكثيريا إلى  
الأسماك القطيه (القراميط)**

**آيه جلال سعد الدين ، شعبان محمد أحمد**

تم اجراء هذه الدراسة لتسجيل إصابة أسماكوزا المستنقعات الحمراء بميكروب الفلافوباكثيريا وقدرة هذه الأسماكوزا على نقل عدوى الفلافوباكثيريا إلى الأسماك القطيه النيلية (القراميط). أجريت هذه الدراسة على عدد ١٠٠ أسماكوزا من أسماكوزا المستنقعات الحمراء ، ولكن لم تظهر عليها أى أعراض أو صفات تشريحية للمرض. تم التعرف على الميكروب عن طريق أشكال المستعمرات وسلوك النمو الخلوى وكذلك الفحص المجهرى والتفاعلات البيوكيميائية. كشف الفحص البكتريولوجى بأن نسبة الإصابة بميكروب الفلافوباكثيريا كولمينارس ١٥% وقد تم عزل عدد ١٦ عترة. كما تم دراسة قدرة ميكروب الفلافوباكثيريا كولمينارس المعزول من اسماكوزا المستنقعات الحمراء على أحداث المرض فى أسماك القراميط عن طريق العدوى بواسطة الغمر مع جرح أو خدش السمك سواء الخياشيم / أو الجلد عند قاعدة الزعنفة الظهرية. الاعراض الظاهرية لاسماك القراميط المصابة تجريبيا بعترة الفلافوباكثيريا كولمينارس توضح وجود التهابات فى الجلد وسقوط جزء من الجلد حتى تصل إلى فقد الطبقة الخارجية من الجلد تماماً مع ظهور بعض الأعراض التنفسية ، كما ظهرت الخياشيم شاحبة اللون. كان معدل الوفيات فى حالات العدوى مع جرح الجلد والخياشيم إلى ١٠٠% وفى حالة جرح الجلد ٨٠% ، وفى حالة خدش الخياشيم ٦٠% بينما فى حالة العدوى بدون خدش كانت ١٠%. توضح نتيجة عمل اختبار حساسية دوائية لميكروب الفلافوباكثيريا كولمينارس هى أنه شديد الحساسية للاوكسيبتراسيكلين وللايسروميسين وحمض الاوكزولينك وانها مقاومة للبوليميكسين بى والتوبراميسين والسلفاميتازول والاموكسيسيلين وللنيوميسين.

**SUMMARY**

The aim of this study was to investigate the infection of Red Swamp crayfish, *Procambarus clarkii* with *Flavobacterium columnare* and the

role of crayfish for transmission of columnaris disease to wild sharptooth catfish, *Clarias gariepinus*, 100 crayfish were subject to clinical, postmortem and bacteriological examinations. Pathogenicity of *Flavobacterium columnare* was also assessed to sharptooth catfish. Out of 100 apparently health crayfish, *F. columnare* was isolated from only 15 (15%) crayfish. Bacteria identification was based on colony morphology and culture behavior on cytophaga agar, microscopic examination, biochemical tests and carbohydrate fermentation. Strains *F. columnaris* isolated from gills of infected crayfish were used throughout this study. Pathogenicity of *Flavobacterium columnare* was investigated through an immersion challenge. Catfish groups to be challenged were subjected to skin and/or gill scarification, others remained un-scarified. All challenged fish were immersed in  $2.1 \times 10^6$  colony forming unit/ml of *F. columnare* challenge suspension. Clinical signs on challenged fish were restricted to the external surface, erosion, ulceration until reach to complete loss of skin, pale gills. The mortality rate in skin and gill scarification group, skin with scarification group, gills scarification was 100%, 80%, 60% respectively, whereas, mortality rate in immersion-without scarification group was only 10%. The antibiogram of *F. columnare* was also investigated where it was sensitive to oxytetracycline, oxalinic acid and erythromycin but resistant to tobramycin, amoxicillin, sulfamethazole, polymixin B and neomycin.

**Keywords:** Red swamp crayfish, *Procambarus clarkii*, *Flavobacterium columnare*, African sharptooth catfish, *Clarias gariepinus*, Columnaris.

## INTRODUCTION

*Procambarus clarkii* have been introduced recently in Egypt. The only available explanation is that the initial access and colonization of *P. clarkii* started as commercial aquaculture in Giza (Manial-Sheiha), in the early 1980's when the first immigrants of this species was introduced from USA. This project was shortly terminated due to administrative failure (Fishar, 2006).

*P. clarkii* is a carrier of many bacterial species known to be pathogenic to aquatic animals such as *Acinetobacter*, *Aeromonas*, *Citrobacter*, *Flavobacterium*, *Pseudomonas*, *Vibrio*, *Corynebacterium*, *Micrococcus* and *Staphylococcus* species (Edgerton *et al.*, 2002).

Yellow pigmented filamentous bacteria of the genera *Flavobacterium* and *Flexibacter* are one of the most important Gram-negative bacteria groups affecting different species of fish. They have been found in connection with external symptoms on fish, like gill or jaw

erosion, fin or tail rot, or saddle like skin lesions (Shotts and Starliper, 1999). Mortalities have been reported due to infection with *Flavobacterium columnare*, *Flavobacterium psychrophilum* (Holt *et al.*, 1993) and *Flavobacterium branchiophilum* in freshwater fish (Wakabayashi *et al.*, 1980).

*Flavobacterium columnare* is an important bacterial pathogen of freshwater fish (Decostere *et al.*, 1999a) and causes columnaris disease which affects a wide variety of fish including wild, cultured and ornamental fish in both freshwater and saltwater environments (Plump, 1999 and Shotts and Starliper, 1999) and African sharptooth catfish, *Clarias gariepinus* (Ahmed *et al.*, 2007). *F. columnare* can infect catfish of any age, under a variety of water conditions, and during any season of the year (Griffin, 1992).

The ubiquitous distribution of the organism in freshwater environments and tendency for fish to acquire the disease after mechanical and/or environmental stress makes *F. columnare* among the most detected pathogens in cultured, ornamental and wild fish population (Shamsudin, 1994). Any species of infected fish may serve as a reservoir of infection for the disease (Schachte, 1983) and the carrier fish can shed *F. columnare* into the water (Becker and Fujihara 1978).

*Flavobacterium columnare* is recognized as a pathogen of freshwater fish with the world wide distribution which can be manifested by loss appetite, sluggish movement, hard respiration and brown to yellow brown lesion on their gills, skin and fins. A characteristic lesion is a pale white band encircling the body, often referred to as saddle back condition with center yellowish-brown ulcer (Robert *et al.*, 1998).

Columnaris disease is the second most prevalent bacterial disease in channel catfish accounting for approximately 23% of the total cases of bacterial etiology (Hawke and Thune, 1992). Columnaris disease is usually restricted to the external surfaces of fish (Bernardet 1997 and Tripathi *et al.*, 2005). Based on the site of infection and appearance of infected tissues, the disease has been commonly known as saddleback, fin rot, or cotton wool disease (Griffin, 1987). Columnaris (Saddleback, Fin rot, cotton wool disease) can affect both the skin and gills. Skin lesions usually begin as irregular areas of epidermal loss, which can progress to areas of extensive ulceration with penetration of dermis and underlying musculature. The most severe infections can affect almost all of the gill arches (Thune, 1993). The progression of the disease in fish is fast; fish will usually die within a few hours of the first visible sign and in some acute cases fish may die before any of the signs are observed (Tripathi *et al.*, 2005).

Commercial farming of African sharptooth catfish, *Clarias gariepinus*, has significantly increased in upper Egypt over the past few years. African sharptooth catfish is widely accepted by consumers in upper Egypt as a relatively cheap source of fish protein (Ahmed and El-Kamel, 2006).

In Egypt, there has been very little research on bacterial pathogens in crayfish, scarce or no data present on the role of crayfish for transmission of columnaris disease to sharptooth catfish. Thus, the aim of this study was to investigate the full description of clinical signs and postmortem lesions of naturally infected crayfish, and due to isolate and identify of *Flavobacterium*, challenge *Clarias gariepinus* with isolated *Flavobacterium columnare* and test antimicrobial susceptibility of bacterial isolates to select antimicrobial agent(s) of choice.

## **MATERIALS and METHODS**

### **Crayfish:**

A total of 100 alive crayfish *P. clarkii*, were collected from the small tributaries of El-Ibrahemia canal and River Nile, Assiut city. A total length of examined crayfish ranged from 10-16 cm. Crayfish were transported to animal health research institute in Assiut where clinical and bacteriological examinations were conducted.

### **Clinical and bacteriological examination of crayfish:**

Crayfish were examined for any apparent clinical signs or lesions according to Melba *et al.* (2001). Bacterial sampling was taken from gills, haemolymph and hepatopancreas on cytophaga agar and incubated at 25°C for 48 hours. Suspected colonies were picked up and subculture for purification and identification according to Austin and Austin (1987).

### **Bacterial identification:**

Purified bacterial isolates from collected crayfish were identified by studying the colony morphology, color, ability to produce flexirubin pigment and cultural characteristics on cytophaga agar, nutrient agar, MacConkey agar and blood agar, microscopic examination (Gram Stain), various biochemical reactions that include oxidase, catalase, indole, Voges-Proskauer, methyl red, H<sub>2</sub>S production, urease and carbohydrate utilization according to Austin and Austin (1987).

### **Pathogenicity of *Flavobacteria columnare*:**

#### **Fish:**

Apparently healthy sharptooth catfish with an average body weight of 100±10 g and total length as 19±1 cm were obtained from Ibrahemia canal at Assiut Governorate. Fish were acclimated to laboratory conditions for 2 weeks according to Ellsaesser and Clam (1986).

**Bacterial challenge suspension and counts:**

A preliminary growth curve study was conducted to determine counts of colony forming units (CFU) of *F. columnare* in cytophaga broth at various growth phases using standard plate count method (El-Kamel and Thune, 2003). *F. columnare* was grown in cytophaga broth at 25°C to reach an optical density of 0.3 at 600 nm, which was found to be equivalent to  $4.2 \times 10^6$  cfu/ml. Challenge suspension was prepared by diluting the above *F. columnare* culture in sterile water (1:1) to reach  $2.1 \times 10^6$  cfu/ml.

**Experimental infection:**

Acclimated sharptooth catfish were divided into 5 groups where each group has ten fish. Fish groups to be challenged were either subjected to skin and/or gill scarification (Bader *et al.*, 2003, 2006) or remained un-scarified. All challenged fish were immersed for 30 min in the challenge suspension prepared, while the control group was un-scarified and immersed in a solution of sterile cytophaga broth and sterile water (1:1) as shown in Table (1). Once fish were exposed to infection, clinical signs and mortalities were recorded daily up to 21 days. Alive and freshly dead fish were microbiologically examined to re-isolate the predominant bacteria.

Identification of bacteria re-isolated was conducted by biochemical approaches. By the 21<sup>st</sup> days, all remained catfish were sacrificed and examined as described above.

**Table 1:** Experimental infection of sharptooth catfish, *Clarias gariepinus*, with *Flavobacterium columnare*.

Group	No. of fish	Route	Immersion dose
Gill scarified	10	Gill scarification	$2.1 \times 10^6$ cfu/ml
Skin scarified	10	Skin scarification	$2.1 \times 10^6$ cfu/ml
Skin and gills scarified	10	Gill and skin scarification	$2.1 \times 10^6$ cfu/ml
Un-scarified	10	--	$2.1 \times 10^6$ cfu/ml
Un-scarified control	10	--	Sterile broth and water

**Antibiogram:**

Antimicrobial susceptibility test was investigated on cytophaga agar medium against eight antimicrobial agents using the disc diffusion technique as described by Finegold and Martin (1982). Antibiotic sensitivity was determined based on the diameter of clearance zone around the discs. Tested antimicrobial agents were Neomycin (30 µg), Tobramycin

(10 µg), Oxytetracycline (30 µg), Amoxicilin (25 µg), Sulfamethazole (25 µg), Oxalinic acid (2 µg), Erythromycin (15 µg) and Polymixin B (300 µg).

## RESULTS

### **Clinical examination:**

Clinical and postmortem lesions of examined crayfish revealed no gross lesion, where all crayfish appeared to be clinically healthy.

### **Bacteriological examination:**

Bacterial examination of crayfish resulted in isolation of 41 isolates from gills, hepatopancrease and haemolymph of 100 red swamp crayfish on cytophaga agar. The isolates were identified as *Flavobacterium* spp. According to culture and morphology. After biochemical reactions these isolates were classified as 16 *F. columnare*, 12 *F. branchiophilum* and 13 unidentified isolates. *F. columnare* colonies were mucoid, yellow or orange in colour with irregular swarm on cytophaga agar. On nutrient agar, *F. columnare* were flat, smooth, moist, no pigments. On 5% sheep blood agar, the colonies were flat, smooth, moist and clear zone of B-hemolysis and were not grown on the Macconkey agar medium. Bacterial cells were gram-negative long slender filamentous rods.

The frequent distributions of the recoved isolates are presented in Table (2).

### **Biochemical characters:**

Biochemical characters of *Flavobacterium* sp. are presented in Table 3.

### **Experimental infection:**

#### **A – Fish infected through immersion with skin and gill scarification:**

The appearance of clinical signs and mortalities began on fish within few hours post challenge, rapid onset of skin loss appeared within few hours. Skin loss began along the base of the dorsal fin within 3 hours (Fig. 1), after only about 7 hours, a complete loss of skin and fin rot were observed (Fig. 2),

mortalities appeared after 12 hours. Two days later, all the remaining fish were dead with erosion, ulceration, wound and loss of the skin (Fig. 3). At necropsy, pale coloration of gills was evident. The mortality rate in this group was 100%.

Out of the group that had skin scarification, three fish died in the first day with ulceration and skin loss on both sides of the body and at the base of the dorsal fin, while the surviving fish showed respiratory manifestations with gasping air. The mortality rate in this group was 80%. The group that

had gill scarification, clinical signs began to appear on fish 48 hours post challenge as respiratory manifestation, fish hanged vertically in the water column, and gasping air were evident; fish had erosion, ulceration and loss of skin, pale areas were found at the base of dorsal fin and pale coloration of gills. The mortality rate in this group was 60%. Fish which were challenged through immersion without scarification did not develop typical signs of infection and survived till the end of the experiment except one fish showed erosion, ulceration and loss of skin. Other fish showed respiratory manifestation. Some fish were found near the water surface and gasping air. The mortality rate in this group was 10%.

The control fish did not show any clinical signs and remain alive without any mortality after the 21<sup>st</sup> days of the experiment.

**Antibiogram:** *Flavobacterium columnare* in the present study was sensitive to Oxytetracycline, Amoxicillin and Erythromycin but resistant to Tobramycin, Amoxicillin, Sulfamethazole, Polymixin B and Neomycin.

**Table 2:** Frequent distribution of the recovered isolates n= 41

Bacterial species	No. of strains	%
<i>F. columnare</i>	16	39.24
<i>F. branchiophilum</i>	12	29.27

**Table 3:** Biochemical characters of isolated bacteria.

Biochemical reaction	<i>F. columnare</i>	<i>F. branchiophilum</i>
Gram stain	-ve	-ve
Flexirubin pigment	+	-
Oxidase	+	+
Catalase	+	+
Indole	-	-
Vogus proskauer	-	-
Methyl red	-	-
H <sub>2</sub> S production	+	-
Urease	-	-
Glucose	-	+
Sucrose	-	+
Maltose	-	+
Lactose	-	+
Reffinose	-	+
Arabinose	-	-

**Table 4:** Percentage of *Flavobacterium* isolates from red swamp crayfish.

Disease	No. of infected crayfish	%
<i>F. columnare</i>	15	60
<i>F. branchiophilum</i>	10	40


Some crayfish were infected with more than one species of bacteria.

**Table 5:** Prevalence of *Flavobacterium columnare* and *F. branchiophilum* in freshwater crayfish.

Total No. of examined crayfish	<i>F. columnare</i> infected crayfish	%	<i>F. branchiophilum</i> infected crayfish	%
100	15	15	10	10

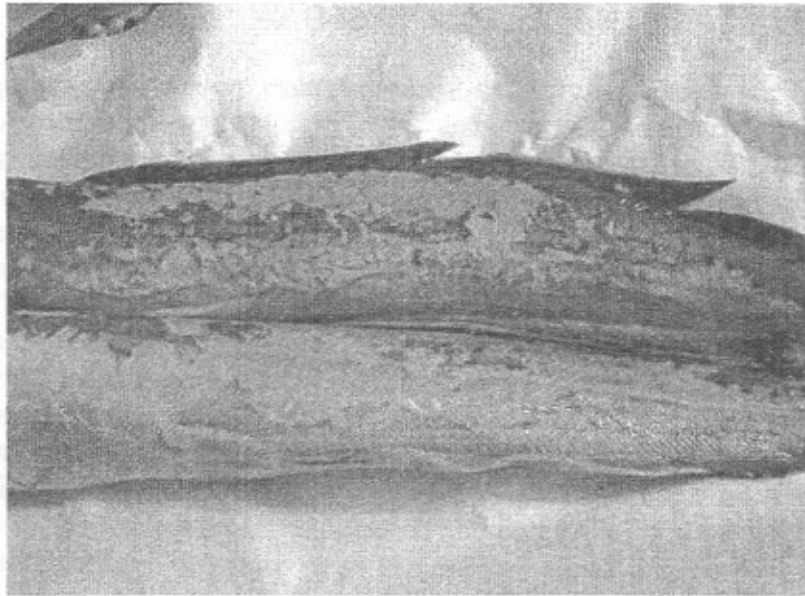
**Table 6:** Organ susceptibility of crayfish to *Flavobacterium* infections.

No. of infected fish	Organ	No. of isolates
15 crayfish infected with <i>F. columnare</i>	Gill	12
	Digestive gland	4
	Haemolymph	0
10 crayfish infected with <i>F. branchiophilum</i>	Gill	10
	Digestive gland	2
	Haemolymph	0

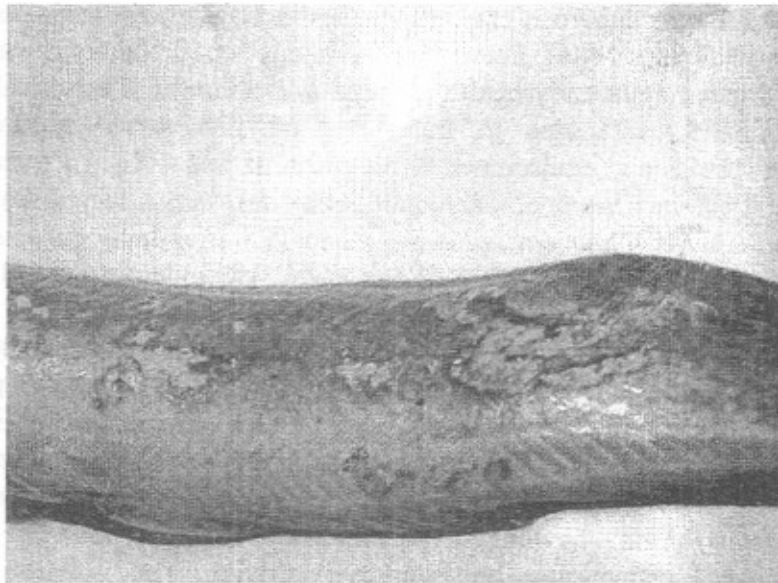


**Fig. 1:** African sharptooth catfish, *Clarias gariepinus* challenged after skin and gill scarification showing the beginning loss of skin within few hours.





**Fig. 2:** African sharptooth catfish, *Clarias gariepinus* after skin and gills scarification showing complete loss of skin.



**Fig. 3:** Sharptooth catfish, *Clarias gariepinus* after skin and gills scarification showing ulceration and wound on the skin.

## DISCUSSION

Freshwater crayfish, *Procambarus clarkii*, which recently appeared in River Nile and its resources all over Egypt, was microbiologically evaluated in order to determine the role of crayfish for transmission of columnaris disease to sharp-toothed catfish. Although *Flavobacterium columnaris* were successfully isolated from the gills and digestive gland, external and internal clinical signs were not apparent. This could be due to columnaris disease is usually restricted to the surface of fish (Tripathi *et al.*, 2005). Also, *F. columnare* has a strong affinity to fish tissues and it is therefore able to attach on fish surface (Wakabayashi, 1991), where as crayfish are covered with carapace. Typical clinical and gross signs of infection were not obvious in clinical and postmortem examination of naturally infected red swamp crayfish, suggesting that the infection was during the stage of asymptomatic bacteremia, which means lack of bacteria multiplication and toxin secretion as was described by Edgerton *et al.* (2002) in case of asymptomatic bacteremia.

Asymptomatic bacteremia has been reported in apparently healthy freshwater crayfish. It is characterized by the presence of a mixed bacterial population in hemolymph samples (Scott and Thune, 1986; Webster, 1995; Wong *et al.*, 1995; Madetoja and Jussila, 1996). This condition has been demonstrated in numerous crayfish species including *Procambarus clarkii* (Scott and Thune, 1986). Prevalence of asymptomatic bacteria was 100% in investigated apparently healthy *Procambarus clarkii*. The prevalence of asymptomatic bacteremia in freshwater crayfish varied according to crayfish species and environmental condition. It was 41% in *Procambarus clarkii*, 100% in *Cherax albidus* and *Cherax destructor*, varied from 98 to 100% in *Cherax quadricarinatus* and 41 to 79% in *Astacus astacus* (Scott & Thune, 1986; Webster, 1995; Wong *et al.*, 1995; Madetoja and Jussila, 1996).

The bacteriological examination of collected samples resulted in recovery of 41 suspected (*Flavobacterium*) from gill and digestive gland of 100 examined freshwater crayfish. These results were similar to Edgerton *et al.* (2002) who could isolate *Flavobacterium* species from *Procambarus clarkii*. Moreover, Ambroski *et al.* (1975) stated that *Pseudomonas* sp., *Citrobacter freundii*, *Aeromonas* sp. and *Flavobacterium* sp. were isolated from aquaria water, fish, bullfrogs and crayfish. The isolation rate of *F. columnare* from gills was higher than from digestive gland. This may be due to the restriction of columnaris disease to external surface of fish (Tripathi *et al.*, 2005). Welker *et al.* (2005) stated that in some cases, *F. columnare* can be isolated from inner organs, but skin and gills are the

tissue of choice for re-isolation. *F. columnare* could not be isolated from haemolymph, this was stated by (Koski *et al.*, 1993) who reported *F. columnare* is able to enter the blood stream through the external lesions, causing septicaemia, although this has only been reported in a limited cases.

Results of biochemical reactions of isolated *Flavobacterium* sp. were nearly similar to (Bernardet and Grimont, 1989; Griffin, 1992; Hawke and Thune, 1992 and Inglis *et al.*, 1993). This result indicated that freshwater crayfish carry asymptotically infection with *Flavobacterium columnare*.

A widely used, but not-well documented challenge model for *F. columnare* utilizes the scarification or abrasion of the host prior to bath immersion. In contrast to the majority of fish pathogens, artificial infection by a highly virulent strain of this bacterium is more effective by contact exposure than by injection (Pacha and Ordal, 1970). Contact infection represents a more natural way of infection whereas intramuscular injection by passes the natural defense mechanisms such as skin and mucus. The interruption of the protective epithelial layer appears to create a portal of entry for *F. columnare*, and loss of the mucus or slime layer present on the epidermis, which normally serves as a barrier to bacterial infection (Ellis, 2001). In the current study, clinical signs of *C. gariepinus*, experimentally infected with *F. columnare*, were erosion, ulceration until a complete loss of skin, pale gills and respiratory manifestation. The obtained clinical signs were nearly similar to those reported by Noga (1996), Stringer-Roth *et al.* (2002), Zaki and El-Boushy (2004), Ahmed *et al.* (2007) and Mohamed (2008).

The disease is usually restricted to the external surfaces of fish (Bernardet 1997 and Tripathi *et al.*, 2005). The extensive necrosis and tissue destruction associated with *F. columnare* infection suggests that this bacterium produce strong tissue-destroying enzymes. When attached onto host surfaces, *F. columnare* release proteases to break down proteins of the host extracellular matrix (Aumailley and Gayraud, 1998 and Durborow, *et al.*, 1998), thus causing necrotic lesions (Miyoshi and Shinoda 2000). The mortality rate in fish with skin and gill scarification was 100%, in case of gill scarification was 60% whereas in case of skin scarification was 80%. Mortality rate in immersed without scarification was 10%. These results nearly similar to Shotts and Starliper 1999, who reported that morbidity in crowded or poorly managed situations, may reach 100% and mortality approaches 70%. Sever osmotic stress that resulted from acute skin loss might be the main cause of mortalities. Extensive damage of the skin causes sever losses of osmotic regulation and electrolyte homestasis, which eventually causes death to fish (Tripathi *et al.*, 2005).

Immersion of non-scarified fish failed to induce typical signs of infection. This result were explained by Vogel (1958) who stated that, typically columnaris disease is not spontaneous but requires some type of physical and environmental insult, normal healthy fish are usually resistant to *F. columnare*. These infection sites increase the number of organisms in the water column and facilitating the spread of the disease. Madetoja *et al.*, 2000 and Bader *et al.*, 2003 reported that, skin damage has been shown to enhance the invasion of Flavobacterial pathogens when the mucus layer was removed or damaged before exposure to bacteria.

The present study clearly revealed that freshwater crayfish carry *F. columnare* and act as a reservoir infections among Africa sharptooth catfish, *Clarias gariepinus*. So, red swamp crayfish have a bad effect on the fish resources in Egypt.

Control and treatment of *F. columnare* have primarily been directly toward the use of improved water-management practices to reduce physiological and environmental stress (Wakabayashi, 1991). On other hand medicated feed are commonly used (Noga, 1996). In this study, eradication of red swamp crayfish is considered a means of controlling columnaris disease.

In the present study, *F. columnare* were sensitive to oxytetracycline, oxalinic acid and erythromycin but resistant to tobramycin, amoxicilin, sulfamethazole, polymixin B and neomycin. These results were explained by Johnson, 1991 who reported that, a high degree of resistance in isolates of *F. columnare* from catfish farms was recorded. These results are nearly similar to those reported by Bernardet and Grimont (1989). Griffin (1992), Hawke and Thune (1992), and Abdel-Rahman (2002).

## REFERENCES

- Abdel-Rahman, B.A.A. (2002):* Bacteriological studies on the causative agent of bacterial gills disease (*Flavobacterium columnaris*) in the fresh water fish.10<sup>th</sup> Sci. Cong. 2002. Fac. Vet. Med., Assiut Univ., Egypt.139-152.
- Ahmed, S.H.M. and El-Kamel, A.A. (2006):* *Proteus vulgaris*, an emerging fish pathogen in Egypt. Assiut Veterinary Medicine Journal. Vol. 52, No. III, 36-50.
- Ahmed, S.H.M.; Ahmed, A.I.; El-Kamel, A.A. and Walaa, F.E. (2007):* Columnaris disease in sharptooth catfish, *Clarias gariepinus*. Assiut Veterinary Medicine Journal. Volume 53, No. 1.

- Ambroski, R.L.; Glorioso, J.C. and Amborski, G.F. (1975): Common potential bacterial pathogens of crayfish, Frogs and fish. *Freshwater Crayfish*. 2: 317-326.
- Aumailley, M. and Gayraud, B. (1998): Structure and biological activity of the extracellular matrix. *Journal of molecular medicine*.76: 253-265.
- Austin, B. and Austin, D.A. (1987): Bacterial fish pathogens. Ellis Horwood, West Sussex, England. Pp. 225-247.
- Bader, J.A.; Nusbaum, K.E. and Shoemaker, C.A. (2003): Comparative challenge model of *Flavobacterium columnare* using a braded and unabraded channel catfish, *Ictalurus punctatus*, (Rafinesque). *J. Fish Disease*. 26: 461-467.
- Bader, J.A.; Moore, S.A. and Nusbaum, K.E. (2006): The effect of cutaneous injury on a reproducible immersion challenge model for *Flavobacterium columnare* infection in channel catfish (*Ictalurus punctatus*). *Aquaculture* 235: 1-5.
- Becker, C.D. and Fujihara, M.P. (1978): The bacterial pathogen *Flexibacter columnaris* and its epizooticology among Columbia River fish. A review and synthesis. Monograph No. 2. Am. Fish. Soc, Washington, DC.
- Bernardet, J.F. and Grimont, P.A.D. (1989): Deoxyribonucleic acid relatedness and phenotypic characterization of *Flexibacter columnaris* sp. nov., nom. rev., *Flexibacter psychrophilus* sp. nov., nom. rev., and *Flexibacter maritimus*. Wakabayashi, Hikida and Masumura, 1986. *Int. J. Syst. Bacteriol*. 39: 346-354.
- Bernardet, J.F. (1997): Immunization with bacterial antigens: *Flavobacterium* and *Flexibacter* infections. *Developments in biological standards*. 90: 179-188.
- Decostere, A.; Haesebrouck, F.; Turnbull, J.F. and Charlier, G. (1999a): Influence of water quality and temperature on adhesion of high and low virulence *Flavobacterium columnare* strains to isolated gill arches. *J. Fish Disease*. 22: 1-11.
- Durborow, R.; Thune, R.; Hawke, J. and Camus, A. (1998): Columnaris disease: A bacterial infection caused by *Flavobacterium columnare*. SRAC publication, No. 479.
- Edgerton, B.F.; Evans, L.H.; Stephens, F.J. and Overstreet, R.M. (2002): Review of freshwater crayfish diseases and commensal organisms. *Annual Review of Fish Disease*. 206: 57-135.
- El-Kamel, A.A. and Thune, R.L. (2003): Invasion and replication of *Photobacterium damsela* subspecies piscicida in fish cell lines. *J. Aquatic Animal Health*. 15: 167-174.

- Ellis, A. (2001): Innate host defense mechanisms of fish against viruses and bacteria. *Dev. Comp. Immunol.* 25: 827-839.
- Ellsaesser, C.F. and Clem, L.W. (1986): Haematological and immunological changes in channel catfish by handling and transport. *J. Fish Biol.* 28: 511-521.
- Finegold, S.M. and Martin, W.J. (1982): *Diagnostic microbiology*. 6<sup>th</sup> Ed. C.V. Mosby, USA.
- Fishar, M.R. (2006): Red swamp crayfish, *Procambarus clarkii*, in River Nile, Egypt. National institute of oceanography and fisheries. <http://Egypt.chm.org/chm/implementation/pdf/alien/crayfish.pdf>.
- Griffin, B.R. (1987): Columnaris disease: Recent advances in research. *Aquaculture magazine* 13: 48-50.
- Griffin, B.R. (1992): A simple procedure for the identification of *Cytophaga columnaris*. *J. Aquatic Animal Health.* 4: 63-66.
- Hawke, J.P. and Thune, R.L. (1992): Systemic isolation and antimicrobial susceptibility of *Cytophaga columnaris* from commercially reared channel catfish. *J. Aquatic Animal Health.* 4: 109-113.
- Holt, R.A.; Rohovec, J.S. and Fryer, J.L. (1993): Bacterial coldwater disease. In: *Bacterial diseases of fish* (ed. By V. Inglis, R.J. Roberts and N.R. Bromage), pp. 3-22, Blackwell, Scientific Publications, Oxford.
- Inglis, V.; Roberts, R.J. and Bromage, N.R. (1993): *Bacterial diseases of fish*. Great Britain, by the University Press, Cambridge.
- Johnson, M.J. (1991): Bacterial resistance to antibiotics: A growing problem in the channel catfish industry. Louisiana Aquaculture Conference. P. 22-23. Baton Rouge, Louisiana.
- Koski, P.; Hirvela-Koski, V. and Bernardet, J.F. (1993): *Flexibacter columnaris* infection in arctic charr *Salvelinus alpinus*(L.): first isolation in Finland. *Bull. Eur. Ass. Fish pathol.* 13: 66-69.
- Madetoja, M. and Jussila, J. (1996): Gram-negative bacteria in the haemolymph of noble crayfish, *Astacus astacus*, in an intensive crayfish culture system. *Nordic Journal Freshwater Research.* 72: 88-90.
- Madetoja, J.; Nyman, P. and Wiklund, T. (2000): *Flavobacterium psychrophilum*, invasion into and shedding by rainbow trout (*Oncorhynchus mykiss*). *Dis. Aquat. Org.* 34: 27-38.
- Melba, G.B.; McGladdery, S.E.; East, I. and Subasinghe, R.P. (2001): *Asia diagnostic. Guide to aquatic animal diseases*. FAO Fisheries Technical. Paper 402/2.
- Miyoshi, S. and Hinoda, S. (2000): Microbial talloproteases and pathogenesis. *Microbes and Infection.* 2: 91-98.

- Mohammed, H.H. (2008):* Flavobacterial infection in African sharptooth catfish, *Clarias gariepinus*. M.V.Sc. Thesis. Faculty of Veterinary Medicine, Assiut University.
- Noga, E.J. (1996):* Fish Disease: Diagnosis and Treatment. Mosby, St. Louis, MO, USA.
- Pacha, R.E. and Ordal, E.J. (1970):* Myxobacterial diseases of salmonids. In: Symposium on disease of fish and shellfishes (ed. By S.F. Snieszko), pp. 243-257. Am. Fish. Soc., Special Publication. No. 5, Washington, DC.
- Plump, J.A. (1999):* Health maintenance and principal microbial diseases of cultured fishes. Iowa State University Press, Ames, Iowa. 328 pp.
- Robert, M.D.; Ronald, L.T.; John, P.H. and Camus, A.C. (1998):* Columnaris Disease: A bacterial infection caused by *Flavobacterium columnare*. SRAC Publication, 1998(9), No.479.
- Schachte, J.H. (1983):* Columnaris Disease. In Meyer, F.P., Warren, J.W. and Carey T.G. (Eds.), A guide to integrated fish health management in the great lake basin. Special Publication No. 83-2. Great Lake Fisheries Commission, Ann Arbor, Michigan, USA.
- Scott, J.R. and Thune, R.L. (1986):* Bacterial flora of hemolymph from redswamp crawfish, *Procambarus clarkii* (Girard), from commercial ponds. Aquaculture. 58: 161-165.
- Shamsudin, M.N. (1994):* Pathogenesis of *Flexibacter columnaris* and immunity in the channel catfish. Ph.D. Dissertation. Auburn University, AL, USA.
- Shotts, E.B. and Starliper, C.E. (1999):* Flavobacterial diseases: columnaris disease, cold-water disease and bacterial gill disease. In: Fish disease and disorders. Vol. 3: Viral, Bacterial and Fungal infections (ed. By P.T.K. Woo and D.W. Bruno), pp. 559-576. CABI Publishing, Oxon, UK.
- Stringer-Roth, K.M.; Yunghans, W. and Caslake, L.F. (2002):* Differences in chondroitin AC Lyase activity of *Flavobacterium columnare* isolates. J. Fish Disease. 25: 687-691.
- Thune, R.L. (1993):* Bacterial diseases of catfish. In Fish Medicine, Ed. By Stoskopf M., W.B. Saunders Company. pp. 513.
- Tripathi, N.K.; Latimer, K.S.; Gregory, C.R.; Ritchie, B.W. and Walker, R.L. (2005):* Development and evaluation of an experimental model of *Cutaneous columnaris* disease in Koi *Cyprinus carpio*. J. Vet. Diagnostic Investigation. 17: 45-54.
- Vogel, H. (1958):* Mycobacteria from cold blooded animals. American review of tuberculosis and pulmonary disease. 77: 823-828.

- Wakabayashi, H. (1991):* Effect of environmental conditions on the infectivity of *Fexibacter columnaris* to fish. J. Fish Dis. 14: 279-290.
- Wakabayashi, H.; Egusa, S. and Fryer, J.L. (1980):* Characteristics of filamentous bacteria isolated from a gill disease of Salmonoids. Canadian Journal of fisheries and aquatic Sciences. 37: 1499-1504.
- Webster, N.S. (1995):* The isolation and identification of bacterial flora from the redclaw crayfish, *Cherax quadricarinatus*. Honours Thesis. James Cook University of North Queensland, Townsville, Australia. 111 p.
- Welker, T.L.; Shoemaker, C.A.; Arias, C.R. and Klesius, P.H. (2005):* Transmission and detection of *Flavobacterium columnare* in channel catfish *Ictalurus punctatus*. Dis. Aquat. Org. 63: 129-138.
- Wong, F.Y.K.; Fowler, K. and Desmarchelier, P.M. (1995):* Vibriosis due to *Vibrio mimicus* in Australian freshwater crayfish. J. of Aquatic Animal Health. 7: 284-291.
- Zaki, V.H. and El-Boushy, M.E. (2004):* Immunodulating effect of levamisole and ascorbic acid in *Oreochromis niloticus* infected with *Flavobacterium columinare*. SCVMJ, Vol. II (2): 367-378.