

Haemato-chemical, histopathological and immunological studies on chicks infected with low pathogenic avian influenza virus (H5N2)

**Hala M. E. El-Makaki^{1*}, O. G. A. Salman¹, Lamiaa M. Omar², N.A. Sherif²,
Hoda I. Tawfik¹**

¹Veterinary Serum and Vaccine Research Institute, ² Central Laboratory for Evaluation of Veterinary Biologics, Abbasia, Cairo, Egypt.

The haematochemical, histopathological and immunological studies were carried out on chicks experimentally infected with the low pathogenic avian influenza virus (LPAIV) (A/Turkey/CA/209092/02) H5N2. Eighty SPF one day old chicks were serologically negative for specific antibodies against avian influenza virus. The birds were divided into 2 groups, birds in the 1st group were inoculated with the virus via the intraocular and intranasal routes, while the other group was kept as non-infected control. Five birds were sacrificed from both groups at 5, 7, 10, 15, and 21 days post inoculation. Sera and heparinized blood as well as tissue specimens from lung, liver, spleen, trachea, small intestine and bursa of Fabricius were collected. Estimation of haemagglutination inhibition antibodies response against AI, liver and kidney function tests, rate of proliferation of T-lymphocyte were conducted. The experimentally infected birds showed general signs of illness with 80% morbidity and 6 % mortality. There was an increase in aniline aminotransferase (ALT) and aspartate aminotransferase (AST) enzymes which reflected liver damage. High urea and creatinine values were also detected in sera of infected birds which proved kidney dysfunction. There was no significant proliferation of T-lymphocyte among examined groups. Very low haemagglutinating inhibiting (HI) antibodies was detected in infected birds. Histopathological examination displayed conspicuous depletion and necrosis of the lymphocytic aggregation in the organs of the haemobiotic system (Bursa of Fabricius, spleen and thymus). Such finding may decipher the low sero-conversion as well as the unproliferation of T-lymphocyte. The necrobiotic changes in liver and kidney sections in addition to congestion and edema elucidate the increased parameters in their functions. Also, the epithelial hyperplasia of the tracheal mucosa and the sloughing in the lining mucosal epithelium are indicative for the epithelio-tropism of the AI virus.

Avian influenza initially was recognized as a highly lethal, systemic disease caused by avian influenza (AI) viruses that are classified in the family *Orthomyxoviridae*, genus *Influenzavirus* A (Saif et al., 2008). The AI strains can be sub-typed based on the two surface glycoproteins, into 16 different haemagglutinin (HI-16) and nine different neuraminidase (NI-9) subtypes. H and N subtypes seem to be able to assort into many of 144 possible combinations (Fouchier et al., 2005). The HA protein is the primary mediator of pathogenicity where the proteolytic cleavage site sequence determines whether infection will be systemic (highly pathogenic "HP") or restricted to the respiratory and enteric tracts (low pathogenic "LP"), based on which proteases recognize the sequence that present (Rott, 1992). The extent of disease signs depend on the virulence of the virus, the species lineage,

age of birds and weather or not there is accompanying bacterial infection (Garcia et al., 1998). Low pathogenic AI outbreaks in domestic poultry (chicken and turkeys) reflected abnormalities in the respiratory, digestive, urinary and reproductive organs. Also high morbidity and low mortality are typical. Losses from LPAI epidemics include mortality losses, condemnations at slaughter, medication against secondary bacteria, cleaning and disinfection and delayed placements of new birds (Saif et al., 2008).

Therefore, this study was planned to reproduce the disease in chickens by LPAI virus as seen in the field for demonstration of clinical signs, antibody response, cellular immune response, some haemato-chemical parameters and some histopathological changes that produced in infected chicks.

Materials and methods

* Corresponding author. Tel.: +202 3424406;
Fax: +202 3428321
E-mail address: svri@idsc.gov.eg
(H. M. E. El-Makaki)

Virus. Low pathogenic (LP) A/Turkey/CA/209092/02 (H5N2) avian influenza (AI) virus was used for experimental infection of chicken as well as HI test. The virus was provided to the Veterinary Serum and Vaccine Research Institute, Abbasia, Cairo by the United State Department of Agriculture (USDA, Ames). The original titre of the virus was $10^{8.5}$ EID₅₀/ml with HA activity 2⁶ HAU.

Chicks. Eighty, one day old SPF chicks were obtained from Nile SPF farm, Koum Oshiem, Fayoum, Egypt. The chicks were housed in bio-safety level 3 isolators till the end of the experiment.

Serum samples. Blood samples were allowed to coagulate and serum samples were collected. Antibody titer against AI virus and estimation of alanine aminotransferase (ALT), aspartate aminotransferase (AST), creatinine and urea values were performed.

Heparinized blood. Heparinized blood samples were collected from the experimental birds and used in the lymphocyte blastogenesis assay.

Haemagglutination inhibition test (HI). HI test was performed according to OIE manual (2005) for detection of AI antibodies. Four HA unit of AIV (antigen) were used.

Transaminases (AST and ALT) activity. AST and ALT activity were measured calorimetrically at wavelength 505 nm (Reitman and Frankel, 1957).

Serum creatinine (gm%). Creatinine was determined according to Henry *et al.*, (1974) at a wave length 545 nm. Creatinine forms a coloured complex with picrate in an alkaline medium which was compared with the colour of standard creatinine solution.

Serum urea level (gm%). Urea level was determined according to (Patton *et al.*, 1977).

Lymphocyte proliferation by T-lymphocyte blastogenesis assay. The test was carried out using cell proliferation kit with XTT reagent (Cat. No.406005 Mobiosciences) (Jost *et al.*, 1992).

Histopathological examination. Autopsy samples were taken from the liver, lung, trachea, small intestine, spleen, bursa of Fabricius and thymus of the 2 groups at the different intervals and fixed in 10% formol saline for twenty four hours. Washing was done in tap water then serial dilutions of alcohol (methyl, ethyl and absolute ethyl alcohol) were used for dehydration. Specimens were cleared in xylene embedded in paraffin at 56 °C in paraffin bath for twenty four hours. Paraffin bees wax tissue

blocks were prepared for sectioning at 4 microns thickness by sledge microtome. The obtained tissue sections were collected on glass slides, deparaffinized and stained by Haematoxylin and eosin stain for histopathological examination through the electric light microscope (Banchroft *et al.*, 1996).

Results and Discussion

Avian influenza virus represents one of the greatest concerns for public health that has emerged from the animal reservoir in recent times and considered in the same time one of the viruses which causes devastating losses to poultry industry. Understanding the mechanism by which this virus produces a disease in chickens is necessary to develop an appropriate preventive measure. The principle targets for mildly pathogenic AIV replication and lesion production are the lungs, lymphoid organs and visceral organs containing epithelial cells such as kidney and pancreas, while the HP AI viruses are pan-tropic in their replication (Swayne, 1997).

In the present work, it was found that the experimentally infected chicks had general signs of illness as ruffled feather, dullness, depression, decreased water and food intake. Mild respiratory signs (coughing, sneezing and ralls) were also seen in some of infected chicks. The mortality rate was 6% (only 3 birds out of 50). The control un-infected group didn't show any abnormalities. The obtained results come in agreement with Mo *et al.*, (1997) who recorded that mild pathogenic AIVs showed restricted ability to replicate or produce lesion or both in non-respiratory or non-enteric tissues; such effect were associated with only sporadic deaths. Also the appeared clinical signs and low mortality rate agreed with Spackman (2008) and Swayne (2008). The results of haemagglutination inhibition (HI) test as shown in table (1) revealed that the average log₂ HI antibody titers were 1.66, 1.2, 0.4 and 2 at 7, 10, 15 and 21 days post infection (DPI) respectively, while there were no antibody titers in chickens at pre-infection time and at 5 DPI as well as non-infected control group. These very low HI antibody titers could be attributed to lymphopenia where in our study it was proved histopathologically that there was a lymphoid depletion appeared in bursa of Fabricius and spleen (Photo 5, 6 and 8) and it is well known that the production of antibodies depending on B lymphocytes that originate from bone marrow, developed in bursa of Fabricius and then respond to the antigen in spleen (Tizard, 2009). This run

in accordance with Chen Yiping *et al.*, (2002) who showed lymphopenia in bursal medulla of experimentally infected chickens with H9 AI virus and Gross and Siegel (1984) who proved also severe lymphopenia caused by AI virus as well as severe depletion of lymphocyte and necrosis of bursa.

Concerning the results of aniline aminotransferase (ALT) and aspartate aminotransferase (AST) as shown in table (2) it indicated a difference in their level in both infected and non-infected groups where it were higher in infected group than in non-infected one. ALT reached its maximum value on the 7th and 21st DPI, 16.6 μ /ml and 15.83 μ /ml in infected group, while in non-infected group it reached 8.8 μ /ml and 8.1 μ /ml at the same intervals. AST level increased from 26.2 μ /ml pre-inoculation to 34.5 μ /ml (maximum value) at 5th DPI then decreased to 28 μ /ml at 7th DPI and increased reached 33.3 μ /ml at 21st DPI while in control group the level of AST was 13, 13 and 21.3 μ /ml at the same intervals. So there was a clear difference in AST level of infected and non- infected groups, where the higher increase in aspartate aminotransferase (AST) enzyme in the infected group than control one. These results agree with Klopffleisch *et al.*, (2007) who found that a marked increase of enzyme activities of AST and ALT in cats infected with HPAI virus and Cornelius *et al.*, (1959) who reported that significant rise in ALT in Newcastle infected groups as a result of liver damage. Also in the present work the increase in liver enzymes rely upon the extent of liver lesions. Since, the synthesis of this enzyme is mostly of liver origin. So, its level in the serum was indicative to the extent of liver damage (Photo 1 and 2) and could be used as a convenient and accurate method for evaluating the extent of the disease.

Regarding results of urea and creatinine (Table 3) as a parameter for kidney function, there was an increase in level of urea where it reached 3.24 mg/ml at 10th DPI in infected group comparing with 2.1 mg/dl in control group. Creatinine values increased at 5th DPI where it reached 1.831 & 1.948 mg/dl at 7th and 10th DPI for infected group and raised to 1.977 & 4.037 mg/dl at 15th and 21st DPI. These results agree with those of Rivetz *et al.*, (1977) who found that ND virus (as a model) induced higher urea and creatinine values in sera of infected birds than the control group.

The measurement of avian cellular immunity is critical to understanding the role and

regulation of avian lymphocytes following avian influenza virus infection. The results in table (4) showed that no proliferation of lymphocytes as measured by lymphocytes blastogenesis as Delta Optical Density (Δ OD) were 0.339 and 0.255 for infected and control chickens, respectively. These results agree with Gross and Siegel (1984) who found severe lymphopenia and decrease of total number of circulating lymphocyte caused by AI virus and also Hana *et al.*, (1989) stated that the decrease in the total number of circulating lymphocytes was evident 12 hours post inoculation and was sustained until the death of the birds.

The histopathological findings of infected birds were as follow: birds sacrificed at 5th DPI, the liver showed severe congestion was observed in the central and portal veins and sinusoids, associated with edema and inflammatory cells infiltration in the portal area (Photo 1A, 1B). Focal necrosis was noticed in the hepatic parenchyma (Photo1C).

While the lung manifested diffuse edema in the interlobular stromal connective tissue (Photo3A) but trachea showed mild hyperplasia was detected in the mucosal lining epithelium (Photo 4A). The examination of spleen revealed severe lymphoid depletion was noticed in the white pulps (Photo 5A).

Bursa of Fabricius showed Severe lymphoid depletion was present in the follicles (Photo 6A). There was no histopathological alteration could be seen in intestine and thymus.

Concerning to birds sacrificed at 10th DPI, in the Liver The portal area showed edema with congestion in the portal vein (Photo 1D), associated with focal necrosis in the hepatic parenchyma (Photo 2A). There was severe congestion in the interlobular stromal blood vessels of the lung: (Photo 3B). Severe lymphoid depletion was noticed in the white pulps of the spleen: (Photo 5B), associated with focal necrosis in the spleen parenchyma (Fig.13). Severe depletion and necrobiosis in lymphoid elements was detected in the follicles of bursa of Fabricius (Photo 6B).

The mucosal lining epithelium of the Intestine showed focal sloughing associated with inflammatory cells infiltration in the underlying lamina propria (Photo 7A). There was no histopathological alteration in the trachea and thymus

Birds sacrificed at 15th DPI, congestion in the portal vein associated with edema in the portal area was detected in the examined Liver

Table (1): Mean of HI antibody (\log_2) titers in the 2 groups of chicks.

Group	Days post infection					
	Pre-Infection	5	7	10	15	21
1	0	0	1.66	1.2	0.4	2
2	0	0	0	0	0	0

Group (1): Chicks infected with LPAIV.

Group (2): Control non-infected chicks.

Table (2): Mean values of liver enzymes in sera of chicks of both groups (μ /ml).

Group	Parameter	Days post infection					
		Pre- Infection	5	7	10	14	21
1	AST (GOT)	26.2	34.5	28	32.166	31.5	33.3
	ALT (GPT)	8.8	9.67	16.6	10.33	8.83	15.83
2	AST (GOT)	23	13	13	24.5	23.1	21.3
	ALT (GPT)	7.1	6.8	8.8	8.8	8.4	8.1

Group (1): Chicks infected with LPAIV.

Group (2): Control non-infected chicks.

Table (3): Mean values of urea and creatinine (mg/dl) as a kidney parameter in sera of chicks of both groups

Group	Parameter	Days post infection					
		Pre-Infection	5	7	10	14	21
1	Urea	2.214	1.428	1.91	3.24	2.27	2.54
	Creatinine	1.066	1.208	1.831	1.948	1.977	4.037
2	Urea	2.101	1.09	1.94	2.1	2.2	2.23
	Creatinine	1.011	1.063	1.006	1.003	1.3	1.06

Group (1): Chicks infected with LPAIV.

Group (2): Control non-infected chicks.

Table (4): Results of lymphocyte proliferation of chicks of both groups as measured by lymphocyte blastogenesis using XTT kits expressed by Delta optical density

Group	Days Post Infection					
	Pre infection	5	7	10	15	21
1	0.228	-	0.339	1.035	0.293	0.278
2	0.233	-	0.255	0.038	0.166	0.239

Group (1): Chicks infected with LPAIV.

Group (2): Control non-infected chicks.

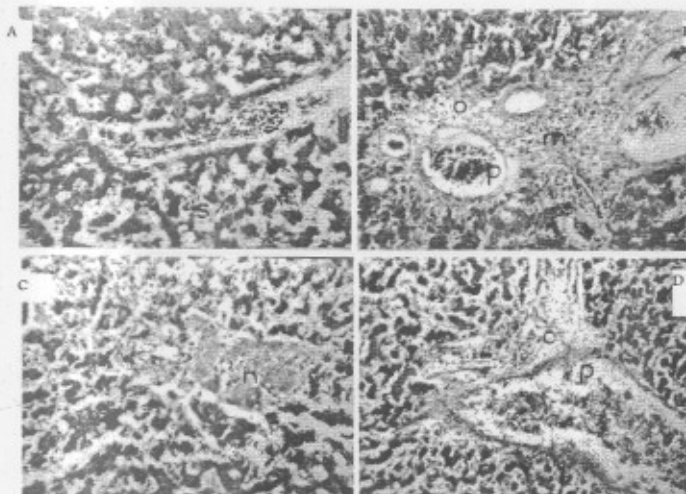


Photo (1): Liver of infected chicks with LPAI virus (H & E x40) showing:
 (A): Severe congestion in central vein and sinusoid (5th DPI).
 (B): Congestion in portal vein with oedema and inflammatory cell infiltration in the portal area (5th DPI).
 (C): Focal necrosis in the hepatic parenchyma (5th DPI).
 (D): Severe congestion in the portal vein with oedema in the portal area (10th DPI).

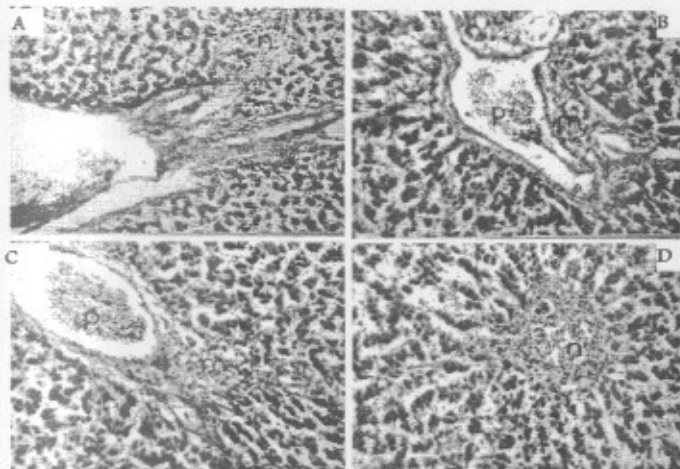


Photo (2): Liver of infected chicks with LPAI virus (H & E x64) showing:
 (A): Focal necrosis in the hepatic parenchyma (10th DPI).
 (B): Congestion in portal vein with oedema and inflammatory cell infiltration in the portal area (15th DPI).
 (C): Congestion in portal vein with oedema and inflammatory cell infiltration in the portal area (21st DPI).
 (D): Focal necrosis in the hepatic parenchyma (21st DPI).

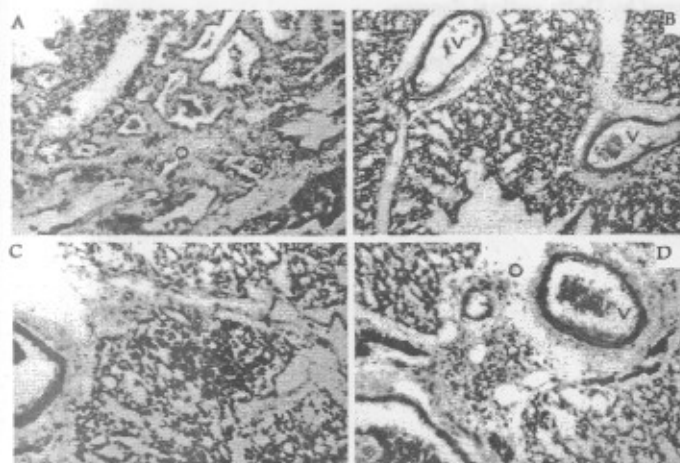


Photo (3): Lung of infected chicks with LPAI virus (H & E x40) showing:
 (A): Oedema in the lobular stroma (5th DPI).
 (B): Severe congestion in the interlobular stromal blood vessels (10th DPI).
 (C): Focal mononuclear leucocytes inflammatory cells aggregation in interlobular stromal connective tissue (15th DPI).
 (D): Oedema, focal inflammatory cell infiltration and sever vascular congestion in the interlobular stromal connective tissue (21st DPI).

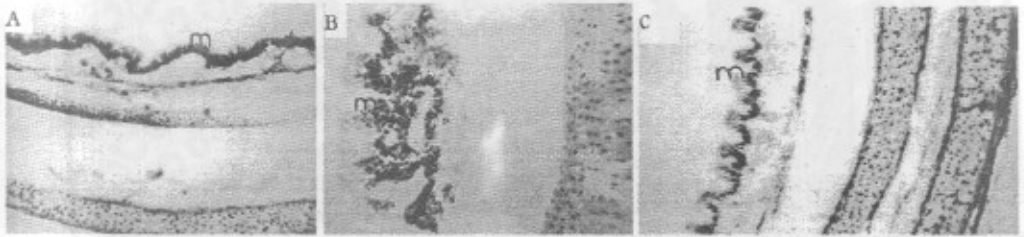


Photo (4): Trachea of infected chicks with LPAI virus (H & E x40) showing:

- (A): Mild hyperplasia in the lining mucosal epithelium (5th DPI).
 (B): Severe lining mucosal epithelial cells hyperplasia (15th DPI).
 (C): Epithelial mucosal hyperplasia (21st DPI).

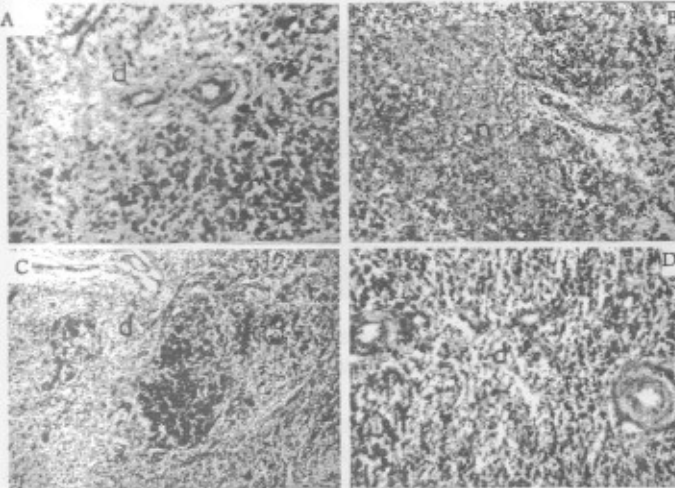


Photo (5): Spleen of infected chicks with LPAI virus (H & E x64) showing:

- (A): Severe lymphoid depletion in the white pulps (5th DPI)
 (B): Focal necrosis in spleen parenchyma (10th DPI)
 (C): Lymphoid depletion of the white pulps (15th DPI)
 (D): Lymphoid depletion in white pulps (21st DPI)

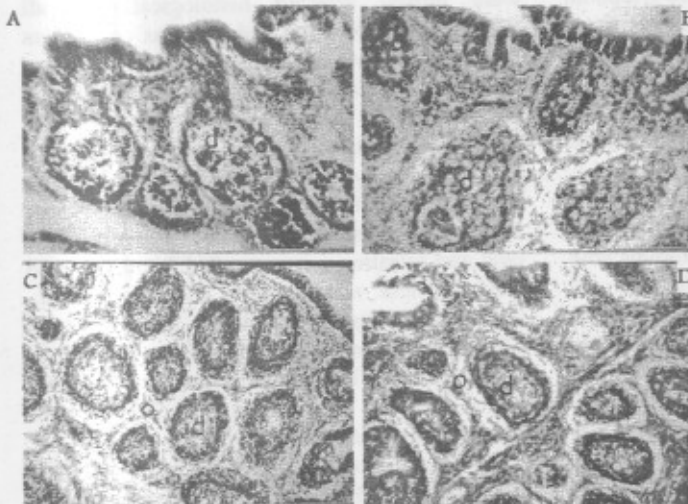


Photo (6): Bursa of infected chicks with LPAI virus (H & E x40) showing:

- (A): Severe lymphoid depletion in the lymphoid follicles (5th DPI).
 (B): Severe depletion and necro-biosis in the lymphoid follicles (10th DPI).
 (C): Severe lymphoid depletion in the lymphoid follicles with oedema in between (15th DPI).
 (D): Lymphoid depletion in the follicles of the lamina propria with oedema in between (21st DPI).

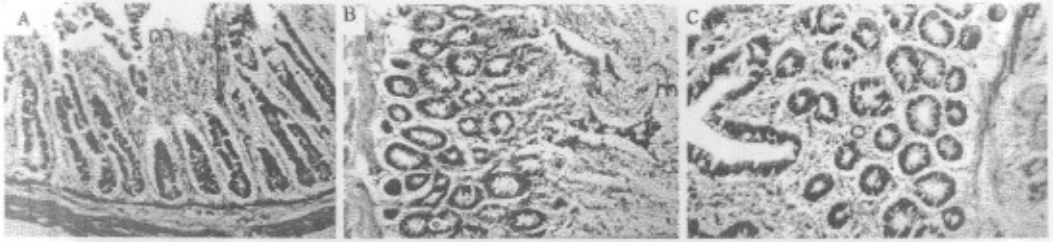


Photo (7): Intestine of infected chicks with LPAI virus (H & E x64) showing:
 (A): Sloughing of mucosal lining epithelium of the villi with inflammatory cells infiltration in the lamina propria (10th DPI).
 (B): Sloughing of mucosal lining epithelium of the villi (15th DPI).
 (C): Oedema in lamina propria (21st DPI).

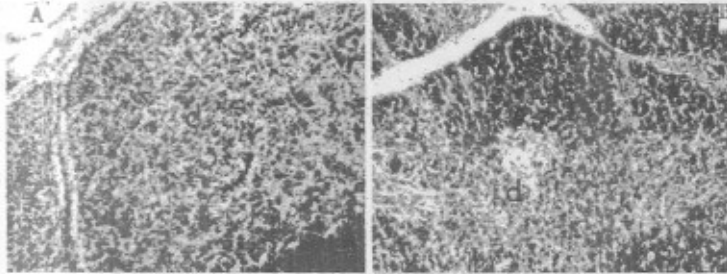


Photo (8): Thymus of infected chicks with LPAI virus (H & E x64) showing:
 (A): Depletion in the lymphoid cells of the medulla (15th DPI).
 (B): Mild lymphoid depletion in the medulla (21st DPI).

(Photo 2B). Focal mononuclear leucocytes inflammatory cells aggregation was detected in the interlobular stromal connective tissue of the lung (Photo3C).

Severe hyperplasia was noticed in the lining epithelium of the mucosal layer of the Trachea: (Photo4B). The splenic white pulps showed lymphoid depletion (Photo5C). Severe lymphoid depletion was observed in the follicles of bursa of Fabricius: together with sever edema in between (Photo6C). There was diffuse sloughing in the lining mucosal epithelium of the Intestine: (Photo7B). Lymphoid depletion was observed in the medullary portion of the Thymus (Photo8A).

When birds sacrificed at 21st DPI were examined, it was found that the portal area of the liver showed inflammatory cell infiltrations with congestion in the portal vein (Photo2C). Focal necrosis was noticed in the hepatic parenchyma (Photo2D). The interlobular connective tissue stroma showed edema, focal inflammatory cell infiltrations and congestion in the blood vessels of the lung (Photo3D). There was hyperplasia in the lining mucosal epithelium of the Trachea (Photo4C). There was lymphoid depletion in the splenic white pulps (Photo5D). The follicles of the bursa of Fabricius showed lymphoid depletion associated with edema in between (Photo 6D). Diffuse edema was noticed in the lamina propria of the Intestine: (Photo 7C). Mild depletion was noticed in the lymphoid cells at the medulla of the Thymus (Photo 8B). There

were no histopathological alterations in control un-infected birds along the different intervals of the experiment.

The marked histopathological lesion was severe lymphoid depletion in bursa of Fabricius at all intervals post infection and this agrees with Chen Yiping *et al.*, (2002). Lung and trachea were mostly affected histologically at all intervals post infection and this was convenient with result of Mo *et al.*, (1997) who found that chickens inoculated with mild pathogenic AIV had histological lesions most frequently in lung and trachea. At 10 days post inoculation, necrobiosis in the lymphoid follicles of bursa and focal necrosis in splenic lymphoid follicles were noticed. Inflammatory cells infiltration in liver, lung and intestine were recorded in the infected chicks. These results agree with Saif *et al.*, (2008) who found that birds that die from LPAIV have lymphocyte depletion and necrosis of lymphocytes in the cloacal bursa, thymus and spleen whereas other tissues as trachea have lymphocyte accumulation.

From this study, it could be concluded that infection with LPAI virus caused high morbidity and very low mortality. Infection with LPAI virus alter the lymphocyte distribution in the internal organs as the number of lymphocytes increased in (lung, liver and intestine) and decreased in others (spleen, thymus and bursa of Fabricius). Depletion of B-lymphocyte in bursa resulted in very low HI antibody titer. Severe

congestion and necrosis were conspicuous in livers of infected birds that have led to raising levels of ALT and AST enzymes in their sera. Increasing the level of creatinine and urea in sera of infected birds indicated kidney damage by the LPAI virus. All the above mentioned results proved that the LPAI virus is an immunosuppressive virus and chickens must be protected against it. The hyperplastic proliferation of the mucosal lining of the trachea was due to the direct replication of the AI virus, as the virus is primarily epitheliotropic as mentioned by Taubenberger *et al.*, (2001). The virus replication furthermore induced production of the interferon, cytokines and other mediators (Nicholas, 2007) leading to local and systemic inflammatory responses, this resulted in the symptoms as well as the histological alterations seen in most of the internal organs. The danger of the LPAI virus resides in being lympho-tropic leaving the birds vulnerable to secondary invaders that positively threatens their life. Although the LPAI virus induced low mortality rate but it is considered as deleterious as the HP strains. So, both types need good regimens of vaccination.

References

- Banchroft, J.D.; Stevens, A. and Turner, D.R. (1996): Theory and practice of histopathological techniques. Fourth Ed. Churchill Livingstone, New York, London, San Francisco, Tokyo.
- Bosch, F.X.; Orlich, M.; Klenk, H.D. and Rott, R. (1979): The structure of the haemagglutinin, a determinant for the pathogenicity of infectious influenza virus. *Virology*, 95: 197-207.
- Chen Y.; Wu L.; Wan H.; Xu Y.; Wang B. and Zhu K. (2002): Effect of experimental infection with H9 avian influenza virus on the immune system of chicken. *Chinese J. Vet. Sci.*, 22, 2, 153-154.
- Cornelius, C.E.; Bishop, J.; Switzer, J. and Rhode, E.A. (1959): Serum and tissue transaminase activities in domestic animals. *The Cornell Veterinarian*, Vol. XLIX, No. 1.
- Spackman, E. (2008): A brief introduction to the avian influenza virus. *Avian Influenza Virus. Methods in molecular biology* 436, Chap. 1, pp. 1-6.
- Fouchier Ron, A.M.V.; Munster, A.; Wallenston, T.M.; Bestebroer, S.; Herfst, D.; Smith, G.F.; Rimmelzwaan, B. Olsen and Osterhaus, D.M.E. Albert (2005): Characterization of a novel influenza virus haemagglutinin subtype (h16) obtained from black-headed gulls. *J. Virol.*, 79 (5): 2814-2822.
- Garcia, A.; Johnson, H.; Srivastava, D.K. Jayawadsen, A.D.; Wehr, R.D. and Webster, G.R. (1998): Efficacy of inactivated H5N2 influenza vaccine against lethal A/chicken/quereta.v/19195 infection. *Avian Dis.*, 42:248-256.
- Gross, W.B. and Siegel, H.S. (1984): Evaluation of heterophil / lymphocyte ratio as a measure of stress in chicken. *Avian Dis.*, 27: 972-979.
- Hana, V.; Bernard, E. and Virginia, H. (1989): Destruction of lymphocytes by a virulent avian influenza A virus. *J. Gen. Virol.*, 70: 467-472.
- Henry, R.G.; Harper Row and Hagerstein (1974): *C. Chemistry Principles and Techniques*, 2nd Ed.
- Jost, L.M.; Kirkwood, J.M. and Whiteside, T.L. (1992): Improved short- and long-term XTT-based colorimetric cellular cytotoxicity assay for melanoma and other tumor cells. *J. Immunol. Methods*, 147 (2): 153-165.
- Mo, L.P.; Brugh, M.; Fletcher, O.J.; Rowland, G.N. and Swayne, D.E. (1997): Comparative pathology of chickens experimentally inoculated with avian influenza viruses of low and high pathogenicity. *Avian Dis.*, 41(1):125-136.
- Nicholas, H.A. (2007): Negative-strand and double-stranded RNA viruses. Chapter VI. Orthomyxoviruses, *Fundamentals of Molecular Virology*, pp. 248-260.
- OIE manual, (2005): *Manual of Diagnostic Tests and Vaccines for Terrestrial Animals. Part 2 Section 2.1.*
- Patton, C.J. and Crouch, S.R. (1977): Colorimetric method for the detection of urea. *Analy. Chem.*, 49: 464-469.
- Reitman, S. and Frankel, S. (1957): Colorimetric determination of GOT and GPT activity. *Am. J. Clin. Pathol.*, 28: 26-59.
- Rivetz, B.; Bogin, E.; Hornstein, K. and Merdinger, M. (1927): Biochemical changes in fowl serum during infection with strains of Newcastle disease virus of differing virulence, changes in serum proteins, uric acid, lipids and electrolytes. *Res. Vet. Sci.*, 22: 285-291.
- Rott, R. (1992): The pathogenic determinant of influenza virus. *Vet. Microbiol.*, 33: 303-310.
- Saif, Y.M.; Fadly, A.M.; Glisson, J.R.; McDougald, L.R.; Nolan, L.K. and Swayne, D.E. (2008): *Diseases of poultry* 12th Ed., Chap. 6, Influenza, pp. 153-184.
- Swayne, D.E. (2008): Pathobiology of avian influenza virus infections in birds and mammals, *Avian Influenza*. Chap. 5, pp. 87-122.
- Swayne, D.E. (1997): Pathobiology of H5N2 Mexican avian influenza virus infections of chickens. *Vet. Pathol.*, 34(6):557-567.
- Swayne, D.E. and Halvorson, D.A. (2003): Influenza. In: Y.M. Saif, H.J., Barnes, A.M., Fadly, J.R., Glisson, L.R. McDougald and D.E. Swayne (eds). *Diseases of Poultry*. 11th ed. Iowa State Univ. Press, Ames, IA, 135-160.
- Taubenberger, J.K.; Reid, A.H.; Jancewski, T.A. and Fanning, T.G. (2001): Integrating historical, clinical and molecular genetic data in order to explain the origin and virulence of the 1918 Spanish influenza virus. *Philosophical Transactions: Biol. Sci.*, 365:1829-1839.
- Tizard, R.I. (2009): *Organs of the immune system. Veterinary Immunology, An Introduction*, 8th ed., Chap. 10, pp.112-127.
- Klopfleisch, R.; Wolf, P.U.; Uhl, W.; Gerst S.; Harder, T.; Starick E.; Vahlenkamp, T.W.; Metteleiter, T. C. and Teifke, J. P. (2007): Distribution of Lesions and Antigen of Highly Pathogenic Avian Influenza Virus A/Swan/Germany/R65/06 (H5N1) in Domestic Cats after Presumptive Infection by Wild Birds. *Vet. Pathol.*, 44:261-268.

دراسات دموية كيميائية و هستوباثولوجية و مناعية على كتاكيت محقونة بفيروس انفلونزا الطيور العترة الأقل ضراوة (HSN2)

في دراسة لمعرفة تأثير العترة منخفضة الضراوة لفيروس انفلونزا الطيور (HSN2) على الكتاكيت من الناحية الكيميائية الدموية و الهستوباثولوجية و المناعية, تم حقن ٥٠ كتكوت (خالى من الأحسام المضادة لفيروس انفلونزا الطيور) بفيروس انفلونزا الطيور العترة منخفضة الضراوة (HSN2) (A/Turkey/CA/209092/02) و ترك ٣٠ كتكوت بدون حقن كمجموعة ضابطة ثم اخذت عينات مصل و دم و أعضاء من كلنا المجموعتين على فترات مع ملاحظة الأعراض و النفوق لمدة ٢١ يوم. ظهرت أعراض مرضية عامة على الكتاكيت المحقونة فقط و بلغت نسبة النفوق ١٠%. كان مستوى الأجسام المناعية الخاصة بالفيروس منخفض جدا في مصل الكتاكيت المحقونة بدأ من اليوم السابع بعد الحقن في حين لم يكن هناك أي أجسام مناعية خاصة بالفيروس في مصل الكتاكيت الغير محقونة. ارتفع مستوى انزيمات الكبد (AST&ALT) و كذلك مستوى اليوريا و الكرياتينين في مصل الكتاكيت المحقونة في حين لم ترتفع هذه المستويات في مصل الكتاكيت غير المحقونة. كذلك أظهرت الكتاكيت المحقونة عدم تكاثر الخلايا الليمفاوية. أما التغيرات الهستوباثولوجية فكانت أهم ما يميزها في الكتاكيت المحقونة هو الأضمحلال الليمفاوي في الأعضاء الليمفاوية و هجرة الخلايا الليمفاوية للأعضاء الداخلية مثل الكبد و الرئة و الأمعاء مع وجود تركز في خلايا هذه الأعضاء.