

Animal Health Research Institute,
Beni Suef.

**CLINICOPATHOLOGICAL AND
BACTERIOLOGICAL SALMONELLA
TYPHIMURIUM EXPERIMENTALLY STUDIES
ON THE EFFECT OF PROBIOTIC
ON INFECTED CHICKEN**
(With 6 Tables and 8 Figures)

By

SAMIA M. MOHAMED and SAMIA I. AFIFI

(Received at 3/9/2011)

دراسات باثولوجية اكلينيكية وبكتريولوجية على تاثير البروبيوتك على العدوى
التجريبية للسالمونيلا في الدواجن

سامية مصطفى محمد ، سامية ابراهيم عفيفي

تم تقسيم عدد ستون كتكوت عمر يوم الى ثلاث مجموعات متساوية المجموعة الاولى تم استخدامها كمجموعة ضابطة تم عدوى المجموعة الثانية والثالثة بميكروب السالمونيلا املى يحتوى على (٧٠) عترة عن طريق الغم لمدة ثلاث ايام غذيت المجموعة الثالثة على عتيقه تحتوى على البروبيوتك اما المجموعتين الاولى والثانية غذيت على عتيقة خالية من البروبيوتك وتم تسجيل نسبة الوفيات وتم اعادة العزل البكتريولوجى لميكروب السالمونيلا من الكتاكيت المصابة والناqqه وتعيين مدى قدرتها على الانقسام فى الغشاء المبطن للأمعاء وايضا قدرتها على غزو كل من خلايا الكبد والطحال تم ذبح ٥ من الكتاكيت فى اليوم ٣ و٧ و٤ ا بعد العدوى وتم اخذ عينات منها وقد وجد نقص معنوى فى عدد كرات الدم الحمراء والهيموجلوبين وحجم الكريات التكتفى كما وجد نقص غير معنوى فى كرات الدم البيضاء فى المجموعة الثانية. وجد نقص فى البروتين والالبومين وزيادة فى انزيمات الكبد واليوريا فى المجموعة الثانية. أظهرت النتائج فى المجموعة الثالثة تحسنا فى صورة الدم ووظائف الكبد. اظهر الفحص الباثولوجى وجود تغيرات باثولوجية فى الكبد والكلى والامعاء.

SUMMARY

Sixty one day old chicks were used in this experiment. Chicks were divided into three equal groups. The first group used as control. The second and third group inoculated orally with one ml containing 10^7 cfu

of *Salmonella typhimurium* for three successive days. The 1st and 2nd group fed ration without probiotic, while the third group fed ration contain probiotic (1 g per kg of ration). Mortalities were recorded and examined bacteriologically and five birds from each group were killed at 3,7, and 14 day post infection for sampling and to evaluate cecal colonization, and organ invasion by *S. typhimurium*. RBCs count, Hb concentration and PCV were decreased in group II. Non significant decrease in WBCs count in group I on the 7 and 14 days post infection. Significant increase in lymphocytes with significant decrease in neutrophils in group II. Values of total protein and albumin showed significant decrease in group II three days post infection. Activities of ALT and AST increase in group II after two weeks of experiment Values of GGT showed no significant changes in the different groups. Urea showed significant increase in group II at 7 and 14 day post infection. The changes in the blood parameters in group III were within the range of the control group. Pathological lesions were observed in the liver and kidney of group II. Pathomorphological changes were also observed in the intestine.

Key words: Probiotics, chicken, *S.typhimurium*.

INTRODUCTION

Salmonella, a genus of zoonotic bacteria, represents one of the primary causes of food poisoning throughout the world (Fantasia and Filetici, 1994) and is thus of considerable public health and economic importance (Uzzau *et al.*, 2000), *Salmonella* is one of the major sources of toxi-infection in humans, most often because of consumption of poultry products. The main reason for this association is the presence in hen flocks of silent carriers. Many prophylactic means have been developed to reduce the prevalence of *Salmonella* carrier-state Zongo *et al.* (2010). Various prophylactic measures have been employed to control *Salmonella* infection in poultry production, including the use of probiotics, to improve immune responses of poultry, (Jung *et al.*, 2010), moreover they have potential antimicrobial effects against several pathogens including *Listeria monocytogenes* (Nomoto *et al.*, 1985), *Salmonella typhimurium* (Simone *et al.*, 1988) and *Escherichia coli* (Mack *et al.*, 1999).

Probiotics are living naturally occurring microorganisms that are employed as feed supplements. Consumption of probiotics benefits the host animal by improving intestinal microbial balance (Fuller, 1993) and by altering the immune system to reduce colonization by pathogens under certain conditions (Patterson and Burkholder, 2003).

Oral inoculation of animal with lactobacilli led to elevated levels of total serum protein, globulin and increased white blood cell count (Pollmann *et al.*, 1980) and increase production of anti-salmonella IgM antibodies (Dunham *et al.*, 1993)

Aim of work:-

To determine the effect of an avian-specific probiotic on the cecal colonization, organ invasion of *S. typhimurium*, blood pictures, liver function, kidney function and pathological changes in experimentally infected chicken.

MATERIALS and METHODS

Chickens:

Sixty apparently healthy Balady chicks one-day-old were used in these experiment, it was proved that they were free from *S. typhimurium* through cultural and serological examination.

Bacterial strain

Salmonella typhimurium NCTC 12023 / ATCC 14028 obtained from Animal Health Research Institute - Dokky Gizza.

Probiotic:-

Bacillus subtilis 0.4 x10⁶ CFU / g of ration

Saccharomyces cerevisiae 3 x 10⁹ CFU / g of ration

Isolation and identification:- Isolation and identification of *S. typhimurium* was carried out according to Collee *et al.* (1996)

Experimental Design

Sixty (one-day-old) Balady chicks were divided into three groups each one contain 20 birds.

The first group (I) used as control fed ration without probiotic kept in a separate room (negative control).

- The second group (II) was fed ration without probiotic.

The third groups (III) was fed ration contain a commercial probiotic (1 g per kg of ration) (Alkhalifa *et al.*, 2010).

At the 4th day, the second and third group were inoculated orally with one ml containing 10^7 cfu of *Salmonella typhimurium* for three successive days. (according to Revolledo *et al.* (2009).

Mortalities were recorded and examined bactreiolgically and five birds from each group were killed at 3, 7, and 14 day post infection for sampling and to evaluate cecal colonization, and organ invasion.

To determine cecal colonization, the whole cecum was removed aseptically, weighed, homogenized and diluted 1:10 with a sterile solution of 0.1% in peptone water (Oxoid). One hundred microliters was spread on *Salmonella-Shigella* agar (Oxoid) and incubated at 37°C for 24 h. In cases in which growth was detected, a series of biochemical and serological confirmatory tests were performed according to Collee *et al.* (1996).

To determine organ invasion, after challenge, samples of liver and spleen were taken from birds of each experimental treatment. Samples were appropriately removed, and after recording liver and spleen weights, organs were homogenized separately. The homogenates of each organ were diluted 1:10 with a sterile solution of 0.1% peptone water (Oxoid) and 100 μ L was spread on *Salmonella-Shigella* agar (Oxoid) as described above. Organ invasion was evaluated by enumeration of *S. typhimurium* in liver and spleen samples using the method as described above. Negative samples were placed in tetrathionate broth (1:10), incubated at 37°C for 24 h and streaked on *Salmonella-Shigella* agar (Oxoid).

Diagnostic kits.

Commercial diagnostic kits were purchased from Sinreact, Diamond, Egypt and Biodiagnostic for determination of hemoglobin (Hb), serum total protein, albumin, aspartateaminotranseferase (AST), alanine aminotransferase (ALT), Gammaglutamyl transeferase (GGT) and urea.

Samples.

a - Blood samples:

Blood samples were collected from the wing vein after three days, one week and two weeks. Blood samples were divided into 2 parts; the first part was collected on EDTA for erythrocytes (RBCs) and

leucocytes (WBCs) count, Hb concentration, packed cell volume (PCV) and differential leucocytic count according to (Feildman *et al.*, 2000). The second part was collected into plain centrifuge tube for serum separation and determination of total protein according to (Henry *et al.*, 1974), serum albumin according to (Doumas, 1971), aspartate amino transeferase and alanin aminotransferase activites according to (Reitman and Frankel, 1957), serum gamma glutayltransferase (GGT) urea according to Patton and Crouch (1977).

b - Tissues samples:

Tissues specimens were taken from liver, kidney, spleen and intestine. The specimens were fixed in 10%formaline solution, trimmed then processed sectioned at 5 Mu and stained with haematoxylin and eosin according to Bancroft *et al.* (1994).

Statistical analysis:

Collected data from the different groups of chickens were statistically analyzed for the mean and standard error according to Selvin (1996).

RESULTS

Mortality rate of each group, colonization of the ceca at d 3,7 and 14 after (inoculation with 10^7 cfu *S. typhimurium*) and invasion of liver and spleen at d 3,7 and 14 after (inoculation with 10^7 cfu *S. typhimurium*) were shown in Tables 1,2,3 and 4.

Hemogram:

Results of hemogram in experimental group of chickens were shown in (Table 5). Results revealed that values of RBCs count, Hb concentration and PCV were significantly decreased in group II in comparison to group I and III .Non significant decrease in WBCs count in group II on the 7th and 14th days post infection. Significant increase in lymphocytes with significant decrease in neutrophils in group II was observed 3 days post infection. Parameters of hemogram in group III were non significantly changed from that of the control group.

Serum biochemical:

Results of serum biochemical parameters in chickens of different experimental groups are shown in Table 6.

Values of total protein and albumin showed significant decrease in group II after three days of experiment in comparison with control

group. Activities of ALT showed significant increase in group II after two weeks of experiment while AST activities was increased insignificantly in group II at three days, one week and two week of the experiment. Values of GGT showed no significant changes in the different groups. Determination of urea showed significant increase on the 7th and 14th days post infection in group II in comparison to group I and III.

Changes in the parameters of serum biochemistry in group III were not significantly differ from that of the control group.

Histopathological finding:

Comparative study of the microscopical picture of organs from normal control non infected chicken with those of salmonella- infected ones revealed pathological changes mainly in the liver, kidney, spleen and intestine.

In cases examined in the early stages of infection, ie., 3 and 7 days post- infection, sheets of hepatocytes were widely separated from each other's and the sinusoidal spaces showed the presence of increased number of macrophages (Fig.1). The hepatic and portal veins were congested and the liver parenchyma was oedematous. Circumscribed, single or multiple foci of aggregated mononuclear cells were distributed in the hepatic parenchyma (Fig. 2) .In later stages, ie., 14 days post-infection, pathological changes consisted of a relatively widened area of necrosis with accumulation of debris and fragmented cells and infiltration of polymorphnuclear leucocytes (Fig. 3 and 4). Fibrinous exudates may be found in the liver capsule mixed with mononuclear inflammatory cells.

At all stages, the kidneys showed acute lymphocytic interstitial nephritis with infiltration of mononuclear cells in the intertubular connective tissue of the renal parenchyma (Fig. 5 and 6). This inflammatory change was accompanied by degenerative and necrotic changes in the epithelial lining of the renal tubules and presence of bacterial colonies in the glomeruli. The spleen showed accumulation of vesicular macrophages in a circumscribed manner in the parenchyma ((Fig. 8 and 9). The intestinal villi were relatively short, and epithelial cells showed necrotic changes and were desquamated and accumulated in the lumen intermixed with fibrinous exudates (Fig. 10 and 11). The lamina propria was infiltrated with few inflammatory cells.

Table 1: Mortality rate of each group

Group	N. of birds	N .of died birds			Mortality rate
		2 nd day	3 rd day	total	
I – Negative control	20	0	0	0	0%
II - (<i>S. typhimurium</i> without a probiotic)	20	1	2	3	15%
III - (<i>S. typhimurium</i> + a probiotic)	20	0	3	3	15%

Table 2: Colonization of the ceca at d 3, 7 and 14 after (inoculation with 10⁷ cfu *S. typhimurium*)

Group	3days post infection	7 days post infection	14 days post infection
I – Negative control	0	0	0
II - (<i>S. typhimurium</i> without a probiotic)	2.5 x 10 ⁴	2.2 x 10 ⁴	1.4 x 10 ⁴
III -(<i>S. typhimurium</i> + a probiotic)	1.7 x 10 ⁴	1.3 x 10 ⁴	0.5 x 10 ⁴

Table 3: Invasion of liver at d 3, 7 and 14 after (inoculation with 10⁷ cfu *S. typhimurium*)

Group	3days post infection	7days post infection	14days post infection
I – Negative control	0	0	0
II -(<i>S. typhimurium</i> without a probiotic)	1.2 x 10 ⁴	0.7 x 10 ⁴	0
III -(<i>S. typhimurium</i> + a probiotic)	0.6 x 10 ⁴	0.2 x 10 ⁴	0

Table 4: Invasion of spleen at d 3, 7 and 14 after (inoculation with 10⁷ cfu *S. typhimurium*)

Group	3days post infection	7days post infection	14days post infection
I – Negative control	0	0	0
II -(<i>S. typhimurium</i> without a probiotic)	1.3 x 10 ⁴	0.9 x 10 ⁴	0.5 x 10 ⁴
III - (<i>S. typhimurium</i> + a probiotic)	0.8 x 10 ⁴	0.5 x 10 ⁴	0

Table 5: Mean values \pm S.E. of hemogram in different experimental group of chickens.

Time	Group	RBCs $\times 10^6/\mu\text{l}$	HB g/dl	PCV %	WBCs $\times 10^3/\mu\text{l}$	Lymph. %	Neut. %	Mono. %
3days post infection	I	2.63 \pm 0.09	9.90 \pm 0.30	27.75 \pm 1.30	25.80 \pm 2.22	66.40 \pm 1.30	28.60 \pm 1.00	5.00 \pm 0.40
	II	1.69 \pm 0.09*	7.83 \pm 0.50*	23.75 \pm 0.30*	26.75 \pm 3.09	70.00 \pm 1.10*	24.00 \pm 1.30*	6.00 \pm 0.40
	III	2.14 \pm 0.14	9.20 \pm 0.50	24.33 \pm 2.80	24.50 \pm 3.27	68.70 \pm 0.70	26.00 \pm 0.70	5.30 \pm 0.60
7days post infection	I	2.23 \pm 0.20	9.74 \pm 0.20	26.2 \pm 1.70	26.23 \pm 2.00	67.00 \pm 0.90	27.70 \pm 0.70	5.30 \pm 0.40
	II	1.83 \pm 0.20*	7.34 \pm 0.50*	19.00 \pm 1.70*	22.80 \pm 2.22	64.67 \pm 0.60	32.00 \pm 1.20	6.30 \pm 0.33
	III	1.99 \pm 0.60	10.09 \pm 0.60	25.75 \pm 2.10	30.00 \pm 6.25	65.25 \pm 2.00	30.35 \pm 1.80	4.40 \pm 0.20
14days post infection	I	2.23 \pm 0.20	9.74 \pm 0.20	28.25 \pm 0.80	26.00 \pm 1.00	67.50 \pm 0.95	27.45 \pm 0.85	5.05 \pm 0.28
	II	1.72 \pm 0.04	8.68 \pm 0.60	21.67 \pm 0.60*	21.00 \pm 3.05	70.80 \pm 2.87	23.20 \pm 2.47*	6.00 \pm 0.94
	III	1.89 \pm 0.08	11.46 \pm 0.70	27.00 \pm 0.57	23.00 \pm 1.52	67.80 \pm 1.62	26.60 \pm 0.97	5.60 \pm 1.20

Group I: Normal control. Group II: Salmonella infected group.

Group: Probiotic and salmonella treated group.

*Significant different from control, p 0.05

Table 6: Mean values \pm S.E. of some serum biochemical parameters in different experimental group of chickens.

Time	Group	T. P g/dl	Alb. g/dl	Glob. g/dl	AST U/ml	ALT U/ml	GGT U/ml	Urea mg/dl
3days post infection	I	4.04 \pm 0.38	2.44 \pm 0.28	1.60 \pm 0.17	58.71 \pm 0.71	33.14 \pm 4.86	16.67 \pm 0.22	6.81 \pm 0.63
	II	2.27 \pm 0.07*	1.37 \pm 0.07*	0.90 \pm 0.09*	57.08 \pm 1.51	45.91 \pm 4.81	16.10 \pm 0.51	7.97 \pm 0.47
	III	3.88 \pm 0.29	2.04 \pm 0.12	1.84 \pm 0.29	58.36 \pm 0.95	33.84 \pm 1.08	16.03 \pm 0.38	6.75 \pm 0.39
7days post infection	I	3.99 \pm 0.20	2.29 \pm 0.26	1.69 \pm 0.21	57.79 \pm 0.64	33.98 \pm 4.80	16.82 \pm 0.17	7.34 \pm 0.50
	II	3.05 \pm 0.15	1.03 \pm 0.04	2.02 \pm 0.33	59.58 \pm 0.70	39.14 \pm 5.55	17.59 \pm 1.23	9.78 \pm 1.87*
	III	3.75 \pm 0.37	2.38 \pm 0.04	1.37 \pm 0.32	57.81 \pm 1.59	29.53 \pm 6.11	15.66 \pm 0.831	7.28 \pm 1.12
14days post infection	I	3.94 \pm 0.24	2.12 \pm 0.22	1.82 \pm 0.23	58.71 \pm 0.71	34.79 \pm 4.11	16.84 \pm 0.19	7.80 \pm 0.77
	II	2.80 \pm 0.04	1.75 \pm 0.03	1.05 \pm 0.14	62.29 \pm 1.49	52.96 \pm 5.75*	17.64 \pm 0.78	10.38 \pm 1.95*
	III	3.96 \pm 0.42	2.29 \pm 0.13	1.67 \pm 0.265	57.96 \pm 1.44	37.03 \pm 7.28	17.24 \pm 0.20	7.69 \pm 0.52

Group I: Normal control. Group II: Salmonella infected group. Group: Probiotic and salmonella treated group.

*Significant different from control, p 0.05.

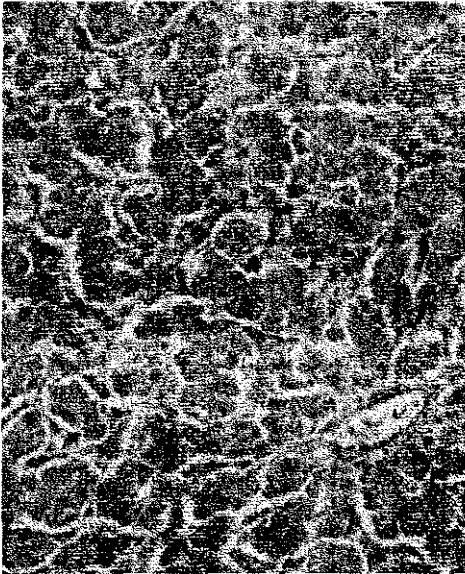


Fig. 1 a: - Section of the liver showing hepatic cords in normal control chickens (H&E x400).

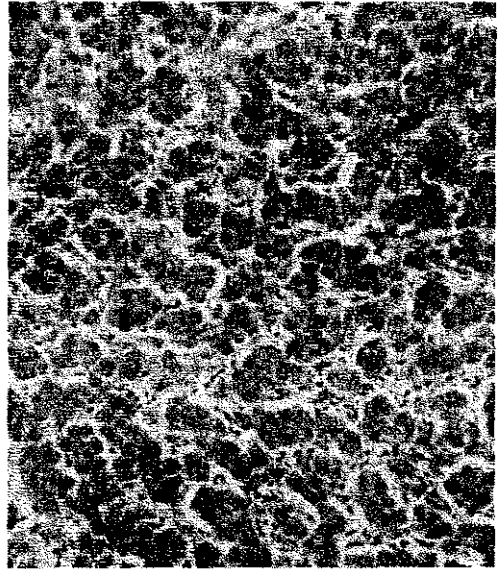

Fig. 1 b: - Hepatic cords widely separated; the sinusoidal spaces are filled with phagocytic Kupffers cells (H&E X 400).

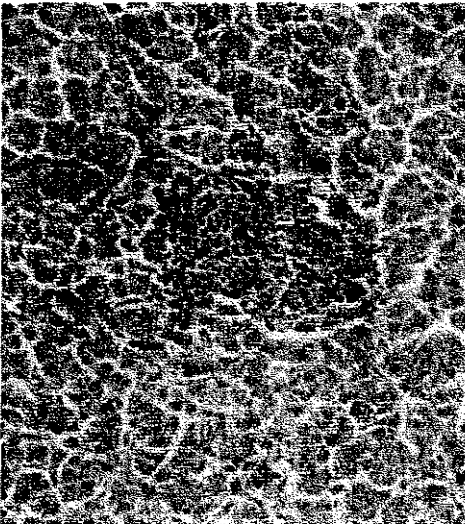


Fig. 2:- Section of liver showing focal granuloma consisting of mononuclear cells (H&E x400).




Fig. 3:- Section of the liver shows extensive areas of necrosis (H&E x100).




Fig. 4: Section of the liver showing necrotic hepatocytes and disintegrated leucocytes (H&EX400)

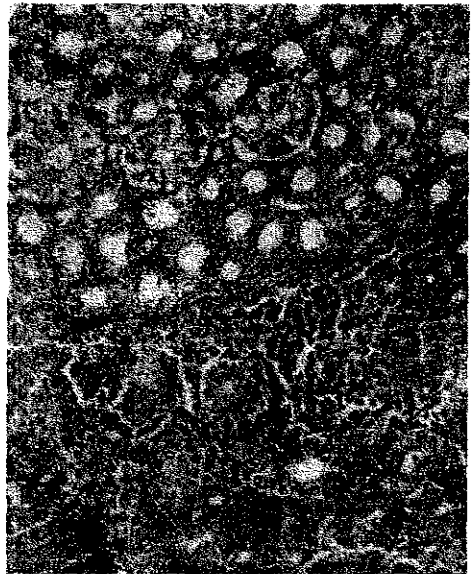

Fig. 5: Section of the kidney shows interstitial nephritis with infiltration of mononuclear cells in interstitial areas (H&EX400)

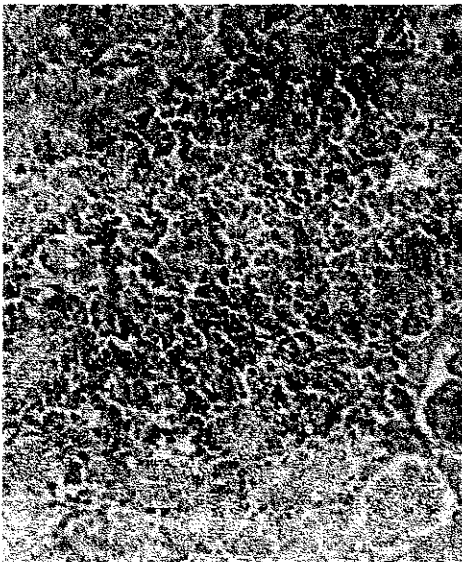


Fig. 6:- Section of the kidney with widened area showing infiltrating mononuclear cells (H&EX400).

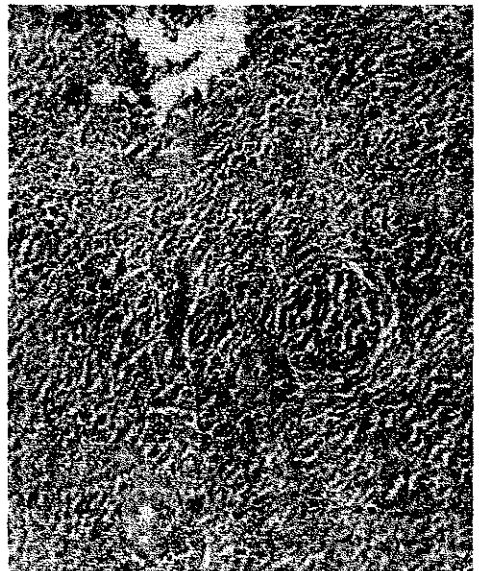

Fig. 7:- Section of the spleen shows focal aggregation of histocytes (H&E X 100).



Fig. 8:- Section of intestine; necrosis of mucosa and accumulation of necrotic tissue in the mucosa (H&E X100).

DISCUSSION

S. typhimurium is a gram-negative enteropathogenic bacterium, which have been most frequently associated with human infections (Porwollik *et al.*, 2004). Poultry are among the most common reservoir of salmonellae that can be transmitted through the food chain to humans. In young chicks, *S. typhimurium* infection can lead to increased incidence of illness, while older birds are less susceptible to the effects of this pathogen, often experiencing intestinal colonization and even systemic dissemination without significant morbidity or mortality, (Gast 2003). Various prophylactic measures have been employed to control *Salmonella* infection in poultry production, including the use of

probiotics, (Jung *et al.*, 2010). Probiotics are live microorganisms that, when administered in adequate amounts, confer a health benefit to the host (Borchers *et al.*, 2009).

The present study showed that the oral infection of three days old chicks with *S. typhimurium* produce 15% mortalities in chicks fed on ration either supplemented with a probiotic or without a probiotic (Table 1), the results disagreed with (Jung *et al.*, 2010), these may contribute to the difference in age of chicks, they used 20 day old chicks while we used one day old chicks with ill developed immune system. Table (2) clearing that there was a difference between cecal colonization of *S. typhimurium* in chicks fed on ration supplemented with a probiotic and chicks fed on ration without a probiotic, thus supplementation of ration with a probiotic decrease cecal colonization of *S. typhimurium* in chicks, the results agreed with results recorded by Simone *et al.* (1988) and Jung *et al.* (2010), also lower number of *S. typhimurium* colonized the ceca in both infected groups at 14 day post infection and this due to the immune response of birds.

Regarding to Tables 3 and 4, invasion of liver and spleen by *S. typhimurium* decreased in the group feed on ration supplemented with a probiotic, similar results were recorded by Revollo *et al.* (2009) and Jung *et al.* (2010), *S. typhimurium* began to disappear from liver and spleen 14 day post infection but more rapidly in the group feed on ration supplemented with a probiotic, these results agreed with the results recorded by Simone *et al.* (1988) and Revollo *et al.* (2009), but the sever lesions in the liver and spleen may be contribute to the endotoxins released after death of the bacterial celles as explained by Saif *et al.* (2003). From the results of the experiment we noticed that *S. typhimurium* was cleared early from organs than ceca, the results agreed with results recorded by Jones *et al.* (2007) and Taseen *et al.* (2009), they explained that *S. typhimurium* was recovered at lower levels from the ceca over a period of 14 days postinfection, while the recovery from the liver and spleen were lower at 3 days post infection.

In this study, we evaluate the effect of probiotic on chickens after challenge by *S. typhimurium*. The results of this study showed that values of RBCs count, Hb concentration and PCV were significantly decrease in group II and non significant decrease in WBCs count. These results agree with Maková *et al.* (2008).

The decreased values of total protein and albumin with increase in ALT, AST and urea could be due to the pathological effect of salmonella endotoxin on liver Saif *et al.* (2003) and kidney. The histopathological result coincide these result.

With regard to the influence of probiotic on haematological and serum biochemical parameters investigated in the experiment, no significant changes on RBCs count, haemoglobin concentration and PCV in group III all times of experiments as illustrated in Table 5 and 6. This is in agreement with Dimcho *et al.* (2005) and Alkhalf *et al.* (2010). In contrast, the finding disagree with Cetin *et al.* (2005) who observed that the probiotic supplementation caused statistically significant increase in the RBCs count, Hb concentration and hematocrit values of turkeys. The difference may be attributed to type and number of species of bacteria present in probiotics.

It is clear that the us/he pathogen for adhesion sites or nutritional sources Guillot (2003) immuonomodulation of the host Isolauri *et al.* (2001) and inhibition of the production of bacterial toxins Brandao (1998).

In conclusion supplementation of poultry ration with a probiotic decrease cecal colonization and organs invasion by *S. typhimurium* and the probiotic strains could increase the protective effects against *S. typhimurium* infection.

REFERENCES

- Alkhalfa, A.; Alhajb, M. and Al-homidanc, I. (2010):* Influence of probiotic supplementation on blood parameters and growth performance in broiler chickens Saudi J. Biolo. Scien. (17), 3: 219-225.
- Bancroft, D.J.; Cook, C.H.; Stirling, R.W. and Tuner, D.R. (1994):* Histological techniques and their diagnostic applications. Churchill Livingston, Edinburgh.
- Borchers, A.T.; Selmi, C.; Meyers, F.; Keen, C.L. and Gershwin, M.E. (2009):* Probiotics and immunity. J. Gastroenterol. 44: 26-46.
- Cetin, N.; Güçlü, B.K. and Cetin, E. (2005):* The effects of probiotic and mannanoligosaccharide on some haematological and immunological parameters in Turkeys. Journal of Veterinary

Medicine Series A – Physiology Pathology Clinical Medicine 52: 263–267.

- Brandao, R.L.; Castro, I.M.; Bambirra, E.A.; Amaral, S.C.; Fietto, L.G. and Tropaia, M.J.M. (1998):* Intracellular signal triggered by cholera toxin in *Saccharomyces boulardii* and *Saccharomyces cerevisiae*. *Applied Environ. Microbiol.*, 64: 564-568.
- Collee, J.G.; Fraser, A.Ca.; Marmion, B.P. and Simmons, A. (1996):* Practical medical microbiology. 14th ed. Charchill Livingstone. New-York, Edinburgh London, Madrid Melbourne, Sanfrancisco and Tokyo.
- Dimcho Djouvinov; Boicheva Svetlana; Simeonova Tsvetomira and Vlaikova Tatiana (2005):* Effect of feeding Lactina probiotic on performance, some blood parameters and caecal microflora of mule ducklings, *Trakia Journal of Sciences* 3: 22–28.
- Doumas, B. (1971):* Determination of serum albumin. *Clinical Chem. Acta*, 31:87.
- Dunham, H.J.; Williams, C.; Edens, F.W.; Casas, I.A. and Dobrogosz, W.J. (1993):* Lactobacillus reuteri immunomodulation of stressor- associated diseases in newly hatched chickens and turkeys, *Poultry Science*, 72 (2):103.
- Fantasia, M. and Filetici, E. (1994):* *S. enteritidis* in Italy. *Int. J. Food Microbiol.* 21:7–13.
- Feildman, B.F.; Zinki, J.G. and Jain, N.C. (2000):* *Shalms Veterinary Hematology*. 5th ed. Lea and Febiger, Philadelphia, U.S.A.
- Fuller, R. (1993):* Probiotics foods – Current use and future developments. *Int. Food Ingred.* 3:23–26.
- Gast, R.K. (2003):* *Salmonella* infections, p. 567. In Y.M. Saif, H.J. Barnes, J.R. Glisson, A. M. Fadly, and L. R. McDougald (ed.), *Diseases of poultry*, 11th ed. Iowa State Press, Ames, IA.
- Guillot, J.F. (2003):* Probiotic feed additives. *J. Vet. Pharmacol. Ther.*, 26: 52-55.
- Henry, R.J.; Cannon, D.C. and Winkelman, J.W. (1974):* Determination of cholesterol and total protein. *Clinical Chemistry Principles and Techniques*. Harper and Row New York, 1440. *Vet. Rec.*, 74: 156-167.
- Jones, M.A.; Hulme, S.D.; Barrow, P.A. and Wigley, P. (2007):* The *Salmonella* pathogenicity island 1 and *Salmonella* pathogenicity island 2 type III secretion systems play a major role in

- pathogenesis of systemic disease and gastrointestinal tract colonization of *S. enterica* serovar *typhimurium* in the chicken. *Avian Pathol.* 36: 199-203.
- Jung, B.G.; KO, J.H. and Lee, B.J. (2010): Dietary Supplementation with a Probiotic Fermented Four-Herb Combination Enhances Immune Activity in Broiler Chicks and Increases Survivability against *S. Gallinarum* in Experimentally Infected Broiler Chicks *J. Vet. Med. Sci.* 72(12): 1565–1573.
- Mack, D.R.; Michail, S.; Wei, S.; McDougall, L. and Hollingsworth, M.A. (1999): Probiotics inhibits enteropathogenic *E.coli* adherence in vitro by inducing intestinal mucin gene expression. *Am. J. Physiol.* 276: G941–950.
- Maková, Z.; Piešová, E.; Faixová, Z.; Levkut, M.Jr.; Lauková, A. and Pistl, J. (2008): The effect of *S. enteritidis* PT4 and *E. faecium* EF55 on chicken intestine mucus production and some haematological parameters. *Poult. Sci.* 2009. 88: 734-743.
- Nomoto, K.; Miake, S.; Hashimoto, S.; Yokokura, T.; Mutai, M.; Yoshikai, Y. and Nomoto, K. (1985): Augmentation of hostresistance to *Listeria monocytogenes* infection by *Lactobacillus casei*. *J. Clin. Lab. Immunol.* 17: 91–97
- Patterson, J.A. and Burkholder, K.M. (2003): Application of prebiotics and probiotics in poultry production. *Poult. Sci.* 82: 627–631.
- Patton, C.J. and Crouch, S.R. (1977): Spectrophotometric and kinetics investigation of Berthelot reaction for determination of ammonia. *Anal.Chem.*, 49: 464-469.
- Polmann, D.S.; Danielson, D.M. and Peo, E.R. (1980): Effect of microbial feed additives on performance of starter and growing – finishing pigs. *J. of Animal Sciences*, 51: 577-581.
- Porwollik, S.; Boyd, F.; Choy, C.; Cheng, P.; Florea, L.; Proctor, E. and McClelland, M. (2004): Characterization of *S. enterica* subspecies I genovars by use of microarrays. *J. Bacteriol.* 186: 5883-5898.
- Rath, N.C.; Huff, G.R.; Huff, W.E. and Balog, J.M. (2000): Effects of *S. typhimurium* Lipopolysaccharide on Broiler Chickens. *Poultry Science* 79: 33–40.
- Reitman, S. and Frankel, S. (1957): A colorimetric method for determination of AST and ALT. *Am. J. Clin. Path.*, 25: 56.

- Revollo, L.; Ferreira, C.S.A. and Ferreira, A.J.P. (2009): Prevention of *S. typhimurium* colonization and organ invasion by combination treatment in broiler chicks. *Poult Sci.* 88:734-743
- Saif, Y.M.; Barnes, H.J.; Glisson, J.R.; Fadly, A.M.; Mcbougald, L.R. and Swayne, D.E. (2003): *Diseases of poultry*. 11th ed. Iowa State Press. a Blackwell Publishing Company.
- Selvin, S. (1996): *Statistical analysis of Epidemiologic Data*. "2nd., PP44-78, Oxford Univ. Press, New York, London.
- Simone, C.; Tzantzoglou, S.; Baldinelli, L.; Di Fabio, S.; Bianchi-Salvadori, B.; Jirillo, E. and Vesely, R. (1988): Enhancement of host resistance against *S. typhimurium* infection by a diet supplemented with yogurt. *Immunopharmacol. Immunotoxicol.* 10: 399-415.
- Taseen, S.D.; Lam, S.B.K.; Birgit, K.; Mickael, C.; Berberov, E.; Amanda, L.S.W.; Hugh, G.G.; Andrew, A.P. and Köster, W. (2009). *S. enterica* Serovar Enteritidis Pathogenicity Island 1 Is Not Essential for but Facilitates Rapid Systemic Spread in Chickens *Infect. Immun.* July; 77(7): 2866-2875.
- Todor Kokosharov (2002): Clinical and hematological effects of *S. gallinarum* endotoxin in cockerels. *Veterinarski Arhiv* 72 (5): 269-276.
- Uzzau, S.; Brown, D.J.; Wallis, T.; Rubino, S.; Leori, G.; Bernard, S.; Casadesus, J.; Platt, D.J. and Olsen, J.E. (2000): Host adapted serotypes of *S. enterica*. *Epidemiol. Infect.* 125: 229-255.
- Vandenbergh, P.A. (1993): Lactic acid bacteria, their metabolic products and interference with microbial growth. *FEMS Microbiology Review* 12: 221-238.
- Young, D.S. (2001): *Effects of disease on Clinical Lab. Tests*, 4th ed AACC.
- Zongo, P.; Viet, A.F.; Magal, P. and Beaumont, C. (2010): A spatio-temporal model to describe the spread of *Salmonella* within a laying flock. *J. Theor. Biol.* Dec. 21; 267(4): 595-604.