

MOLECULAR AND HISTOPATHOLOGICAL DETECTION OF RABBIT HEMORRHAGIC DISEASE VIRUS IN YOUNG RABBITS

El-Nahas, E.M.

Departments of virology, Faculty of Veterinary Medicine,
Moshtohor, Benha University, Egypt.

ABSTRACT

Calicivirus infection causes rabbit haemorrhagic disease (RHD) that kills more than 90% of adult animals, whereas young rabbits are naturally resistant to this viral disease. Interestingly, we have detected rabbit haemorrhagic disease virus (RHDV) in liver and intestinal tissues from suddenly died young rabbits (5-6 weeks old) in a remote private farm at Tukh, Kaluobia. Preliminary detection using haemagglutination (HA) test revealed a higher titer of HA antigen 2^7 and 2^8 in liver and intestine respectively using type O human erythrocytes. A genomic region encoding the capsid protein (VP60) within RHDV was identified by Reverse Transcriptase Polymerase Chain Reaction (RT-PCR). The amplified cDNA gives size of approximately 538 bp. Also Liver and intestinal homogenates reacted positively by haemagglutination (HA) assays to different human blood groups (O, A, B, and AB) at 4 °C. Experimentally RHDV detected strain appears likely to be of high pathogenicity to young rabbits rather than adult. Histopathological examination showed acute necrotizing hepatic necrosis and crypt necrosis in the intestine. We conclude that a new RHDV strain infecting young rabbits (5-6 weeks old) was circulated and further characterization of the strain was required.

INTRODUCTION

Rabbit haemorrhagic disease (RHD) is a highly contagious viral disease of domestic and wild rabbits (*Ferreira et al., 2006*). The causative agent is RHDV, a member of the genus *Lagovirus* within the family *Caliciviridae* (*Green et al 2000*). The genome of RHDV consists of a 7.5 kb single stranded positive sense RNA and contains two open reading frames (ORF) overlapping by 17 nucleotides. ORF1 (nucleotides 10–7044) encodes a polyprotein which is cleaved into the non-structural proteins as well as the 60 kDa major structural protein VP60 forming the capsid while ORF2 (nucleotides 7025–7378) encodes the 10 kDa minor structural protein VP10. A 2.2 kb sub-genomic RNA, collinear with the 3' end of the genomic RNA, can be recovered from tissues of infected rabbits and is packaged into particles (*Meyers et al., 2000*). All known isolates of RHDV appear to belong to one serotype but like other RNA viruses, Caliciviruses has a high genetic mutation rate (*Gould et al., 1997*).

Only a few studies have investigated *calicivirus* infection of young rabbits (*Shien et al., 2000*). Several methods are used commonly to detect RHDV, haemagglutination test (*Gong et al., 2003*), electron microscopy (*Capucci et al., 1998*), enzyme-linked immunosorbent assay (ELISA) (*Liu et al 2006*), and Reverse Transcriptase-Polymerase Chain Reaction (RT-PCR) (*Hu et al., 2006*) which can provide clinical diagnosis.

In Egypt, a highly fatal infectious disease appeared on May 16, 2011 among 500 young domestic rabbits (5-6 weeks old) reared in a remote private farm at Tikh, Kaluobia. Onset of the disease was sudden

and the mortality rate was 100%. Infected rabbits died suddenly without any observed clinical manifestation. Depression and neurologic signs were observed in few cases. Post mortem findings included bloody mucous in the intestine and discolored liver. In this paper we try to detect RHDV in clinically affected young rabbits using haemagglutination and RT-PCR assays beside histopathological examination from liver and intestinal samples.

MATERIALS AND METHODS

2.1. Specimens: liver and small intestine were collected from young rabbits (5-6 weeks old) during May 2011. The clinical signs were limited to difficulty in movement, depression and convulsion. The main gross lesions were characterized by bloody mucous in the intestine and discolored liver. These were used for RHDV detection and histopathological examination.

2.3. Virus strain: Local RHDV-Egypt.96 strain (*Daoud et al., 1998*) was kindly supplied by Veterinary Serum and Vaccine Research Institute, Abbasia, Cairo and used as positive control in RT-PCR and haemagglutination inhibition (HI) test.

2.2. Rabbits: Ten New Zealand white rabbits were purchased from the Laboratory Animal Center, College of veterinary medicine Benha University, Egypt. The animals were divided in two age groups: 5- and 10-week-old rabbits that are thereafter designated as “young” and “adult” rabbits. All animals were free from detectable RHDV antibodies as examined by HI test according to *shien et al., 1998*. They were used in inoculation test.

2.4. Oligonucleotide primers: Their sequences, positions and the expected size of the amplification products are listed in Table 1. They were used in one step RT-PCR for amplification of portions VP60 gene. It was designed in Metabion Company, Germany.

Table (1): Oligonucleotide primers and PCR products for VP60 gene of RHDV.

Primer name	Polarity	5'-end position	Primer sequence, 5' to 3'	Product size (bp)
P33	+	6473	CCACCACCAACACTTCAGGT	538
P34	-	7011	CAGGTTGAACACGAGTGTGC	

2.5. Preparation of viral samples: Liver and small intestine were homogenized separately in phosphate buffer saline solution (PBS) pH 7.2 at 10% W/V and clarified by centrifugation at 4000g for 10 minutes *Shien et al (1998)*. The supernatant were used for haemagglutination test and inoculation test.

2.6. Haemagglutination (HA) tests: It were carried out according to (*shien et al., 1998*) briefly, equal volume of a serial 2-fold dilution of the filtered tissue homogenates (liver and intestine) and 0.5% suspensions of group O human erythrocytes for viral titration . The reaction was performed at 4°C, 22°C and 37°C in PBS with erythrocytes of four human blood groups (O,A,B,Ab) at pH 7.4 to study HA property of detected RHDV.

2.7. RT-PCR: Viral RNAs were extracted from the samples of liver suspension with RNeasy (QIAGEN, Germany) and amplified using a one step RT-PCR kit (Cat.NO.210212, QIAGEN, Germany). The RT-PCR was carried out using oligonucleotide primers according to *Vende et al (1995)*.

2.8. Inoculation test: It was performed according to *Ferreira et al 2004* where both young (5-6 week-old) and adult (10-week-old) rabbits were injected intramuscularly with a PBS suspension of caliciviruses that had a 2⁸ titer in haemagglutination units.

2.9. Histopathological examination: Specimens of liver and small intestine were taken at necropsy and fixed in 10 per cent phosphate-buffered formalin. The samples were dehydrated through graded alcohols and xylene and embedded in paraffin wax by standard methods. Sections (4 µm thick) of liver tissue were cut, stained with haematoxylin–eosin (HE) according to *Carleton, 1967*.

RESULTS

3.1. Preliminary detection of RHDV using Haemagglutination (HA): The HA titer was relatively increased with one log for HA antigen prepared from intestinal tissues than that from liver (Table 1).

Table (1): HA titer for antigen prepared from liver and intestine samples for RHDV with type O human erythrocytes at 4 °C.

Prepared antigen	log ₂ HA titer
Liver	7
Intestine	8

HA= Haemagglutinating

3.2. RHDV detection in liver and intestine of clinically infected young rabbits. The RT-PCRs for RHDV were positive for liver and intestinal samples. The amplified PCR products of 538 bp were analyzed by agarose gel electrophoresis and visualized by ultraviolet rays with ethidium bromide (Fig. 2).

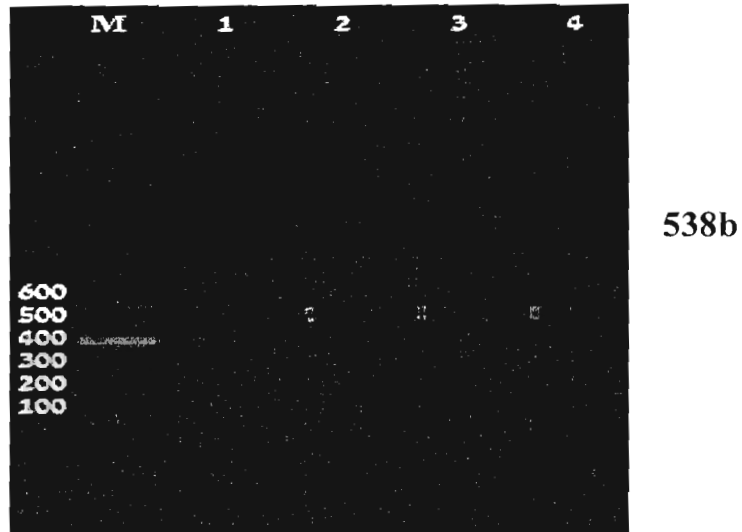


Fig. (2): RT-PCR results of liver and intestinal samples from infected young rabbits (5-6weeks old) with primer specific to VP60 gene of RHDV. M= 100bp DNA ladder. Lane 1: Negative control. Lane 2= Positive control amplified with RHDV Egypt-96. Lanes 3= liver sample and 4: intestinal sample. Samples were positive with an expected size (538bp) amplicon.

3.3. Characterization of RHDV using Haemagglutination

(HA): Similar results were obtained for HA antigen prepared from liver and intestinal samples (Table 2). Both gave Positive HA at 4 °C with O, A, B, and AB, and at 22 °C with B and AB human blood group. These findings indicated that the most sensitive erythrocytes for HA were type B and AB followed by O and A. Moreover, HA activity was stable at low temperature (4 °C) and became less stable as the temperature increased.

Table (2): Activities of HA antigen prepared from liver and intestine samples for RHDV with human erythrocytes at various temperatures.

Type of erythrocytes	positive samples for RHDV		
	4 °C	22 °C	37 °C
O	+ ^{a)}	-	-
A	+	-	-
B	+	+	-
AB	+	+	-

a) Positive or negative in HA

3.4. Susceptibility of adult and young rabbits to RHDV detected in young (5-6 weeks old) rabbits: After inoculation of suspensions from positive samples for RHDV. Young rabbits exhibited fever as early as 12 hours PI (40.5°C) then increased to 41°C and remained till 72 hours PI. Young Rabbits Died within 24-72 hours PI with Depression, diarrhea, and convulsion in few cases and characteristic lesions at necropsy including mainly liver and intestine. However, the adult rabbits exhibited fever at 48hours PI (40.8°C) and remained till 48 hours PI without deaths or clinical signs (table. 3).

Table (3): Response induced in adult and young rabbits inoculated with RT-PCR positive samples for RHDV from young rabbits.

Rabbits			Signs and mortality				
group	age	No.	12*	24	36	48	72
Adult	(>2 month	5	-	-	-	-	-
Young	5-6week	5	-	+(1)**	+(2)	+(1)	+(1)

* hour post inoculation

** Number of deaths

+/- Positive or negative signs or mortalities.

3.5. Histopathological examination of liver and intestinal samples: Examined liver samples revealed that diffuse, periportal to midzonal coagulative necrosis of single or groups of hepatocytes were characteristic (Fig.1A). Multifocal areas of lytic necrosis infiltrated with small numbers of inflammatory cells were observed (Fig.1B). Moreover,

multifocally, portal areas were markedly expanded by proliferation of biliary epithelium and aggregates of inflammatory cell mainly lymphocytes and few heterophils (Fig.1C). The intestines showed congested blood vessels and capillaries in lamina propria and sub mucosa. Multifocally, the intestinal mucosa exhibited crypt necrosis (Fig.1D) with mixed inflammatory cellular infiltration mainly macrophages, lymphocytes, plasma cells and few heterophils.

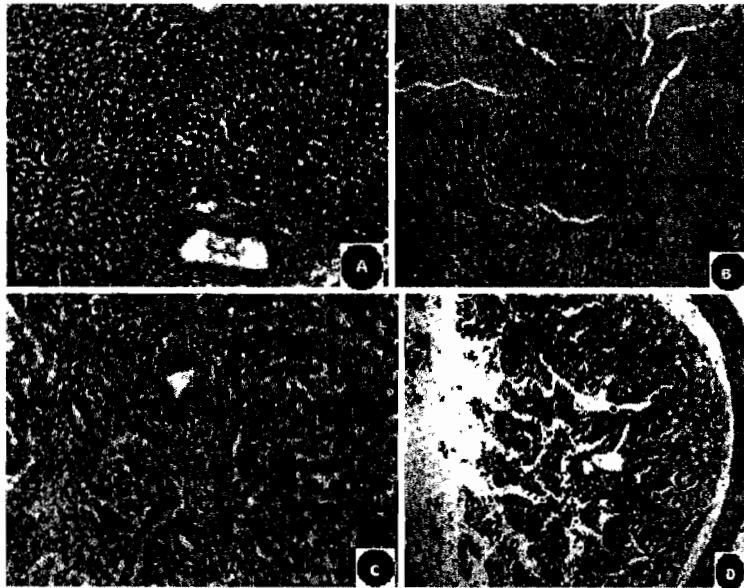


Fig. (1. Light micrograph of liver and intestine paraffin sections of a 5-week-old rabbit suspected to be infected with RHDV. infected Liver showing multifocal areas of lytic necrosis infiltrated with small numbers of inflammatory cells (A), periportal to midzonal coagulative necrosis of single or groups of hepatocytes (B),and aggregates of inflammatory cells in portal area mainly lymphocytes and few heterophils (C). Multifocal crypt necrosis of the intestinal mucosa with inflammatory cellular infiltration

(D).Haematoxylin–eosin stain (200x) for (A and B), (400x) for(C), and (100x) for (D).

DISCUSSION

It has been reported recently that young rabbits, at the age of 4–8 weeks, or shortly after weaning, are likely to be infected by RHDV (*Teifke et al., 2002*). When young rabbits were challenged with RHDV, they got infected and died, but the clinical symptoms are different from those of typical RHD in adult rabbits. RHD in young rabbits tends to occur in local sporadic outbreaks (*Ji et al., 1994*).

In this study, a naturally occurring disease outbreak with clinical signs and pathologic findings suggestive of RHD was observed in young rabbit (5-6 weeks old). The clinical picture included sudden deaths within 6 to 24 hours of the onset of fever with few neurologic signs, including excitement, incoordination, paddling, and opisthotonos. Similar symptoms were previously described by *Lavazza and Capucci 2008*. The gross pathological findings were bloody mucous in the intestine and discolored liver. These observations were similarly described by *Strive et al., 2009*.

Results of HA test on liver and intestinal suspensions using Human erythrocytes at various temperatures gave positive results with high titer (2^7 and 2^8) respectively. HA test should be conducted at a low temperature (4 °C). This is in accordance with findings (*Mizoguchi et al 2002*) who indicated that HA RHDV strain and the intestine is considered to be a potential a pathogenic RHDV progenitor (*Capucci et al., 1996*).

Based on primer specific to VP60 gene of RHDV, A 538 bp product was generated from liver and intestinal samples using RT-PCR. Besides the obvious advantages of the time and cost savings, RT-PCR has the advantages of enabling us to detect RHDV that might not replicate well in culture (*Tunon et al., 2003*). Our results come in agreement with *shien et al., 2000 and Fahmy et al 2010*.

On the basis of the percentage of affected animals in the outbreak and the failure to generate clinical disease in inoculated adult rabbits, RHDV detected strain appears likely to be of high pathogenicity to young rabbits rather than adult. RHDV-associated illness and death in laboratory rabbits can be lower than in field situations unless the animals are immune-primed by other disease agents (*McIntosh et al., 2007*). Alternately, the failure to reproduce disease in adult may be due to low viable virus dose (difficult to assess for a noncultivable virus) (*Bergin et al., 2009*) or existence of new natural recombinant of RHDV (*Forrester et al. 2008*).

Histopathology of the liver revealed periportal to mid-zonal coagulative necrosis and massive area of lytic necrosis of hepatocytes. The intestine showed crypt necrosis. These data were consistent with other reports on RHDV (*Bergin et al., 2009*). The pathological changes were believed to result from viraemia with wide spread circulatory dysfunction. The sudden death of animals may be due to multiple organ dysfunctions (*McIntosh et al., 2007*).

In conclusion RHDV strain which was highly pathogenic for young rabbits (5-6weeks old) and detected by RT-PCR needs further serological and molecular characterization.

REFERENCES

- **Bergin, I. L., Wise, A.G., Bolin, S.R., Mullaney, T.P., Kiupel, M. and Maes R.K. (2009):** Novel Calicivirus Identified in Rabbits, Michigan, USA. *Emerging Infectious Diseases* 15(12):1955-1962.
- **Capucci, L., Fusi, P., Lavazza, A., Pacciarini, M.L. and Rossi, C. (1996):** Detection and preliminary characterization of a new rabbit calicivirus related to rabbit hemorrhagic disease virus but nonpathogenic. *J. Virol.* 70 (12), 8614–8623.
- **Capucci, L., Fallacara, F., Grazioli, S., Lavazza, A., Pacciarini, M.L. and Brocchi, E. (1998):** A further step in the evolution of rabbit hemorrhagic disease virus: the appearance of the first consistent antigenic variant. *Virus Res.* 58 (1–2), 115–126.
- **Carleton, H. M. (1967):** *Histological technique.* 4th ed. New York, London and Toronto Oxford Univ. press.
- **Daoud, A.M., Khodeir, M.H., Abbass, A.M. and Ibrahim, S.I. (1998):** preparation of a specific inactivated vaccine against rabbit haemorrhagic disease virus. 4th scientific congress of faculty of veterinary medicine Zagazig University (Hurgodad) P. 230-234.
- **Fahmy, H.A., Arafa, A., and Mahmoud, A.H. (2010):** Molecular diagnosis of rabbit haemorrhagic disease virus (RHDV). *Egypt. J.comp.and clinic. Path.* 23(1), 85–101.
- **Ferreira, P.G., Costa-e-Silva, A., Monteiro, E., Oliveira, M.J.R., andguas, A.P. (2004):** Transient decrease in blood heterophils and sustained liver damage caused by calicivirus infection of young rabbits that are naturally resistant to rabbit haemorrhagic disease. *Research in Veterinary Science* 76, 83–94.

- **Ferreira, P.G., Costa-e-Silva, A., and Guas, A.P. (2006):** Liver disease in young rabbits infected by calicivirus through nasal and oral routes. *Res. Vet. Sci.* 81, 362–365.
- **Forrester, N., Moss, S.R., Turner, S.L., Schirmer, H. and Gould, E.A. (2008):** Recombination in rabbit haemorrhagic disease virus: possible impact on evolution and epidemiology. *Virology* 376 (2), 390–396.
- **Gong W., Wei L., Fu R., He Z.M., Xing R.C. (2003):** Analysis of Factors Affecting the Haemagglutination and Haemagglutination-inhibition Test for Detection of Antibody to Rabbit Hemorrhagic Disease Virus. *Laboratory Animal Science Administration*, 20 (3), 7-10.
- **Gould, A.R., Kattenbelt, J.A., Lenghaus, C., Morrissy, C., Chamberlain, T., Collins, B.J. and Westbury, H.A. (1997):** The complete nucleotide sequence of rabbit haemorrhagic disease virus (Czech strain V351): use of the polymerase chain reaction to detect replication in Australian vertebrates and analysis of viral population sequence variation. *Virus Res.* 47 (1), 7–17.
- **Green, K.Y., Ando, T., Balayan, M.S., Berke, T., Clarke, I.N., Estes, M.K., Matson, D.O., Nakata, S., Neill, J.D., Studdert, M. J. and Thiel, H.J. (2000):** Taxonomy of the caliciviruses. *J. Infect. Dis.* 181 (Suppl. 2), 322–330.
- **Hu, Y.D., Liu, H.R., Si, C.D., Liu, J.S., Han, L.X., Jiang, Q. and Qu, L.D. (2006):** Establishment and initial application of RT-PCR test for rabbit hemorrhagic disease virus. *Prog. Vet. Med.* 27, 87–90.

- **Ji, C.Y., Zhang, Y., Sun, Z.F. and Du, N.X. (1994):** Artificially infections of rabbit haemorrhagic disease virus to the young rabbits. Anim. Husbandary Vet. Med. 5,212–214.
- **Lavazza A., and Capucci, L. (2008):** How Many Caliciviruses are there in Rabbits? A Review on RHDV and Correlated Viruses. In Lagomorph Biology: Evolution, Ecology, and Conservation by P.C. Alves, N. Ferrand, and K. Hackländer (Eds.) published by Springer-Verlag Berlin Heidelberg. Page: 263–278.
- **Liu H.R., Guan Y.T., Li. C.W. (2006):** Preparation and preliminary application of indirect ELISA Kits for rabbit hemorrhagic disease antibody detection. Acta Laboratorium Animalis Scientia Sinica, 3 (14).
- ~~**McIntosh, M.T., Behn, S.C., Mohamed, F.M., Lu, Z., Moran, K.E., Burrage, T.G., Nelson, J.G., Ward, G.B., Botti, J., Capucci, L. and Metwally, S.A. (2007):**~~ A pandemic strain of calicivirus threatens rabbit industries in the Americas. Virol. J. 4, 96–108.
- **Meyers, G., Wirblich, C., Thiel, H.J. and Thumfart, J.O. (2000):** Rabbit hemorrhagic disease virus: genome organization and polyprotein processing of a calicivirus studied after transient expression of cDNA constructs. Virology 276 (2), 349–363.
- **Mizoguchi, T., Itou, K. and Sakurai, M. (2002):** Haemagglutination and antigenic comparison of rabbit haemorrhagic disease virus. J. Vet. Med. Sci. 65(1): 95–97.

- **Shien, J.H., Shieh, H.K. and Lee, L.H. (1998):** Characterization of rabbit hemorrhagic disease virus field isolates in Taiwan. *J. Virol. Methods* 71, 27–33.
- **Shien, J.H., Shieh, H.K., and Lee L.H. (2000):** Experimental infections of rabbits with rabbit haemorrhagic disease virus monitored by polymerase chain reaction. *Res. Vet. Sci.* 68 (3), 255–259.
- **Strive, T., Wright, J.D. and Robinson, A.J., (2009):** Identification and partial characterization of a new Lagovirus in Australian wild rabbits. *Virology* 384, 97–105.
- **Teifke, J.P., Reimann, I. and Schirrmeyer, H. (2002):** Sub-acute liver necrosis after experimental infection with rabbit haemorrhagic disease virus (RHDV). *J. Comp. Pathol.* 126, 231–234.
- **Tunon, M.J., Sanchez Campos, S., Garcia Ferreras, J., Alvarez, M., Jorquera, F. and Gonzalez Gallego, J. (2003):** Rabbit hemorrhagic viral disease: characterization of a new animal model of fulminant liver failure. *J. Lab. Clin. Med.* 141, 272–278.
- **Vende, P., Le Gall, G. and Rasschaert, D. (1995):** an alternative method for direct sequencing of PCR products for epidemiological studies performed by nucleic sequence comparison. Application of rabbit haemorrhagic disease virus. *Vet. Res.*, 26, 174–179.

الكشف الجزيئي والهستوباثولوجي عن فيروس مرض النزف الدموي للأرانب في الأرانب الصغيرة.

* إيهاب مصطفى النحاس ، ** شوقي احمد مصطفى

* قسم الفيروسولوجيا - كلية الطب البيطري بمشتهر - جامعة بنها - مصر

** قسم الباثولوجيا - كلية الطب البيطري بمشتهر - جامعة بنها - مصر

تتسبب العدوى بفيروس الكالسي مرض النزف الدموي للأرانب (RHD) والذي يُقتل أكثر من 90 % من الحيوانات البالغة، بينما الأرانب الصغيرة مقاومة طبيعياً إلى هذا المرض الفيروسي. بشكل مثير للانتباه تم الكشف عن فيروس مرض النزف الدموي للأرانب (RHDV) في الكبد والأنسجة المعوية لأرانب صغيرة (عمرها 5-6 أسابيع) ماتت فجأة بمزرعة خاصة بعيدة بمدينة طوخ بمحافظة القليوبية. بالكشف التمهيدي عن فيروس باستخدام اختبار التلزن الدموي لكرات الدم الحمراء للإنسان نوع (O) كانت أعلى عيارية للفيروس ⁷2 و ⁸2 بكل من عينات الكبد والأمعاء على التوالي. تم التعرف على المنطقة الجينية المشفرة لبروتين الغلاف (VP60) الخاص بفيروس مرض النزف الدموي للأرانب باستخدام النسخ العكسي الاستردادي لتفاعل البلمرة المتسلسل (RT-PCR) حيث كان ناتج التفاعل المضخم 538 قاعدة جينية مزدوجة تقريباً. أيضاً تفاعل كلا من مستخلص عينات الكبد والأمعاء مع فصائل الدم للإنسان نوع (O, A, B, and AB) عند 4 درجة سيلزيوس وذلك عند إجراء اختبار التلزن الدموي. وبالتجربة فقد لوحظ أن العترة المكتشفة من فيروس مرض النزف الدموي للأرانب ذات تأثير باثولوجي مرتفع في الأرانب الصغيرة عنها في الأرانب البالغة. وقد عرض الفحص الهستوباثولوجي تركزاً حاداً لكل من خلايا الكبد والأمعاء للأرانب الصغيرة المصابة. واستنتاجاً لذلك فإنه يمكن القول بأن هناك عترة جديدة من فيروس RHDV والتي تصيب الأرانب الصغيرة (عمرها 5-6 أسابيع) موجودة وتتطلب تلك العترة وصفاً إضافياً.