

## Studies on Pathogenicity of Local Newcastle Disease Genotype VIIj and Avian Influenza H9N2 Isolates to Commercial Vaccinated Male Layer Chickens.

M. M. Amer\*, Asmaa M. Maatouq\*\*, M. A. Bosila\*, M. I. Abdrabou.\*\*,  
M. H.H. Awaad\*, M. A. Kutkat\*.

\* Department of Poultry Disease, Faculty Veterinary Medicine, Cairo University, P.O. Code 12211 Giza, Egypt.

\*\* Department of Poultry Disease, Veterinary Research Division, NRC, P.O. Code 12311 Dokki, Giza, Egypt.

\*\*\* Cytology and Histology Department, Faculty Veterinary Medicine Cairo University, P.O. Code 12211 Giza, Egypt.

**T**HIS STUDY was carried out to compare pathogenicity of single and co-infection of Newcastle disease virus (NDV) genotype VIIj and Avian Influenza (AI) H9N2 virus in commercial male layer chicken vaccinated with live ND (Hitchner B1, La Sota) vaccines from different commercial producers in two vaccination schemes. NDV haemagglutination inhibition (HI (log<sub>2</sub>) mean titers in group received vaccines 1 ( $4.8 \pm 0.8$ ,  $2.4 \pm 1.2$  and  $3.9 \pm 0.5$ ) were lower than group given vaccine 2 ( $4.5 \pm 1.2$ ,  $3.6 \pm 1.1$  and  $4.0 \pm 0.4$ ) at 14, 21 and 29 days of age, respectively. Chicken group received ND vaccine 2 and inactivated H9 showed relatively higher HI titres ( $5.0 \pm 1.5$ ,  $3.5 \pm 1.4$  and  $4.5 \pm 1.3$ ). HI titres against H9N2 in group given H9N2 inactivated vaccine are  $3.7 \pm 1.6$ ,  $2.5 \pm 1.1$  and  $5.1 \pm 1.3$  at 14, 21 and 29 days, respectively. Challenge with Newcastle disease virus (NDV) genotype VIIj at 33 days of age resulted in 100% mortality with severe signs as well as in non-vaccinated control sub-group challenged and 100% mortalities. Sub-groups (2a, 3a and 4a) vaccinated with ND vaccine 1, ND vaccine 2 and ND vaccine 2+ H9N2 showed signs of depression, off food and moderate respiratory signs with protection rates is 70, 70 and 75%, respectively. Control group challenged with H9N2 showed general signs with mild respiratory signs and 10% mortalities while, sub-groups given ND vaccine 2+ H9N2 and challenged with H9N2 showed 100% survival. Chicken sub-groups vaccinated with ND vaccine 1, ND vaccine 2 or ND vaccine 2+ H9N2 and challenged with NDV+ H9N2 (co-infection) showed signs from the 3rd s post infection (dpi) with moderate respiratory signs and protection rate of 50, 70 and 70%, respectively. Post-mortem lesions in Velogenic NDV (vNDV) challenged birds were septicemia, intestinal and respiratory lesion, while those challenged with both NDV and H9N2 showed more prominent lesions. The vaccinated groups showed unsatisfactory protection rates (50- 75%). Vaccine 2 showed higher protection and HI titers than vaccine 1. Simultaneous chicken challenge with H9N2 and vNDV pointed out that co-infection increased severity of clinical signs, mortality and gross lesions. Histological changes were reported in lung, intestine, and spleen of challenged non-vaccinated and vaccinated groups. The severity of tissue alteration was remarkably high in the non-vaccinated group and slightly mild tissue alteration in the vaccinated group. The histological changes ranged from severe congestion in blood vessels in tested organ with lymphoid depletion in spleen and hyperplasia of mucosal-associated lymphoid tissue in the intestine, with partial limited tissue change in the challenged vaccinated group.

The local NDV strain genotype VIIj is highly pathogenic to male layer commercial chickens and the inoculation of NDV with H9N2 at the same time didn't increase its severity. Also, it was notable that commercial Hitchner B1 and La Sota vaccines conferred partial protection for experimentally used chickens against challenge this ND field isolate.

**Keywords:** local isolates, H9N2, vNDV vaccines, HI titres, co-infection, histopathology.

## Introduction

Avian influenza virus (AIV) and Newcastle disease virus (NDV) are two of the most important separate viruses affecting poultry or co-infections especially in areas of the world where both viruses are endemic [1]. Both viruses show different pathotypes ranging from low virulent forms that produce subclinical infections, occasional upper respiratory disease, and drops in egg production (low pathogenicity AIV [LPAIV] or low virulence NDV [l NDV]) to more-virulent forms that can cause high mortality and great economic losses in poultry (velogenic NDV [vNDV] and highly pathogenic AIV [HPAIV]) [2,3].

Now days, severe NDV outbreaks are still frequently occurring in commercial vaccinated poultry flocks, despite the intensive vaccination programs [4-8]. LPAIV infections clinically induce asymptomatic, mild-to-severe respiratory signs, loss of weight, diarrhea and decrease in egg production with lesions in respiratory and reproductive systems [9, 10].

Frequent co-infections/interferences were reported in many areas of the world, especially where both viruses are endemic in many forms, like (a) lentogenic NDV with either LPAIV or HPAIV and (b) velogenic NDV with either LPAIV or HPAIV [10,11]. LPAIV has become endemic in domestic poultry in different countries in Asia and the Middle-East, causing subclinical infections, mild respiratory symptoms, and/or drops in egg production [12]. Co-infection of poultry with more than one virus is common and has resulted in increased clinical signs [13-16]. But also, the infection of a host with one virus can affect infection by a second virus, a phenomenon known as viral interference [17]. Viral interference can be elucidated by different mechanisms encompassing (a) competition for cell receptors attachment for replication, (b) intracellular host machinery competition, and (c) virus-induced interferon interference. Attachment and entry of both viruses requires the presence of sialic acids (SA) on target cells [18, 19]. AIV and NDV preferentially bind to SA<sub>2,3</sub>-Gal receptors. This is due to the circumstance that AIV and APMV-1 have identical receptors and the same site of localization in the body (airways and gastrointestinal tract) due to their dependency on trypsin and trypsin-like enzymes. There, they compete for target cells. As a result, the co-infection (depending on the host bird species) could result in altered production of progeny virus

with effects on clinical signs, immune response which could impede the detection in avian flocks [20-23].

It is not clear if co-infections will exacerbate clinical signs of disease or if viral interference might occur and consequently mask or affect infections by one or other virus, LPAI H9N2 are a continued circulate to poultry in Egypt and, therefore, it's important to understand the pathogenesis of these viruses in field situations where birds are likely co-infected with other viruses, including NDV.

This study aimed to detect levels of protection induced by the commercial ND genotype II Hitchner B1, La Sota vaccination regime and inactivated H9N2 against challenge with vNDV and/or H9N2 (separately and co-infection) under experimental condition.

## Material and Methods

### *Pathogenic virus strains*

Avian influenza H9N2 AI/CHICKEN/EGYPT48/Ob/NRC2014/ and a genotype VIIj vNDV NDV/CHICKEN/EGYPT48/Ob/NRC2014/ isolated from chickens from field cases suffering from mortalities and respiratory symptoms. These strains were molecular identified, sequenced for haemagglutinin (HA) genes and submitted to GenBank [24]. The two viruses were titrated according to Reed and Muench [25] to be used as challenge viruses.

### *Experimental chicks*

Two hundred, LSL male layer chicks were obtained from a commercial hatchery. The chicks were reared according to the breed manual. Sera were collected from 15 random chicks at 1 and 7 days of life and tested for maternal H9 and NDV antibodies using hemagglutination inhibition assay (HI).

### *Vaccines*

*I. Newcastle disease vaccines:* Chicken was vaccinated using ND vaccines from different commercial sources in 2 vaccination schemes as vaccine 1 (HB1.1 and La Sota 1) and vaccine 2 (HB1.2 and La Sota 2).

### *Hitchner HB1*

- Jovac® Live attenuated vaccine 1000 dose/each 10<sup>6.0</sup> Embryo infective dose<sub>50</sub> (EID<sub>50</sub>). Patch no. 01D0116. Produced by Jovac Jordan bioindustry center. Jordan.
- IZOVAC®: Freeze dried live La Sota

vaccine 1000 dose/each  $10^{6.5}$  EID<sub>50</sub>. Produced by IZO S.R.L. asocio unico, via san zeno 99/A-25124 Berscia (Italy).

#### *La Sota*

- JOVAC® Live Attenuated Vaccine lot no 02D0418 Produced by Jovac Jordan bioindustry center. Jordan.
- Nobilis ®Live La Sota Vaccine A120AJ01 Intervet.

#### *H9N2 Inactivated vaccine*

Jova zeit 7®: Inactivated oil emulsion vaccine H9N2 Produced by Jovac Jordan bioindustry center. Jordan.

#### *Embryonated chicken eggs (ECEs)*

Specific pathogen frees (SPF) 9 days old, Embryonated Chicken Eggs (ECEs) were obtained from Kom Oshim, El-Fayoum, Egypt. ECEs were used for vaccine titration and propagation of virus strains for both challenge and HI antigen. ECEs were inoculated according to Allan [26] and Pearson and Senne [27].

#### *Haemagglutination (HA) test and Haemagglutination inhibition (HI) test*

HA test was used for titration of used antigens to 4 HA units/0.05 ml. HI was carried out using homologous antigens to the challenge viruses, according to WHO [28].

#### *Experimental design*

Two hundreds, 1 day old LSL male chicks were divided into 4 mean groups (1-4). Groups 1 and 2 were 40 chicks each, while groups 3 and 4 were 60 chicks each. Chicks of groups 1-3 were intraocularly vaccinated with 50 ul/bird of live HB1 strain and La Sota strains at 7 and 19 days, respectively. Chicken group was given ND vaccine 1 while groups 2 and 3 were given vaccine 2. Chicks of group 4 were kept as non-vaccinated control (Table 1). Birds of groups 3 were subcutaneously vaccinated with inactivated H9N2 vaccine (0.3 ml/bird) at the 10<sup>th</sup> day of life. Fifteen blood samples were collected for serum from each chickens group to evaluate antibody titer against NDV and H9N2 vaccine at 1, 7 14, 21 and 29 days of age.

At 33 days of age chicken groups 1 and 2 were subdivided randomly into 2 sub-groups ( a and b) while groups 2 and 3 were sub grouped into 3 (a, b and c). Chicken subgroups were intraocularly challenged with 100 ul containing  $10^6$  EID<sub>50</sub> of vNDV VIIj genotype and or 200 ul containing

$10^7$  (EID<sub>50</sub>) of H9 strain (Table 1). Birds were observed daily for 10 days post challenge for morbidity and mortality.

Tissue samples including lung, intestine and spleen were collected in 10% neutral buffered formalin from 2 birds/group at 1, 2 and 4 at 6, 8, and 10 days post infection (dpi) for histopathological examination.

#### *Histopathological and histological examination*

Lung, intestine and spleen tissue specimens were fixed in 10% formol saline, then trimmed off, washed and dehydrated in ascending grades of alcohol. The dehydrated specimens were then cleared in xylene, embedded in paraffin blocks and sectioned at 4-6  $\mu$ m thick. The obtained tissue sections were deparaffinized using xylol and stained using hematoxylin and eosin (H&E) for histological examination through the electric light microscope [29].

#### *Statistical analysis*

The obtained HI titres expressed as means  $\pm$ SE (standard error of the mean) and protection rates analyzed using GraphPad Prism 6 software (Graph Pad Software Inc., USA). One-way analysis of variance (ANOVA) including Bonferroni correction was used for data at same time point in different groups. Differences in the mean values were considered statistically significant at the *p* value was <0.05.

### **Results and Discussion**

Both NDV and AIV are the most worldwide economically important viruses affections in poultry [1] and co-infections were reported in endemic forms [11]. Co-infections by low and highly pathogenic type (LPAI/HPAI) AIV and Lentogenic, mesogenic and velogenic NDV has been reported [21, 30-33]. This interference depends on the titer of the viruses used, the virulence of the NDV, and the timing of the infections [32]. Velogenic NDV VII is usually recovered outbreaks in poultry worldwide including Egypt [16, 34, 35, and 37]. Natural LPAI H9N2 and virulent NDV co-infections were occurred and have been reported in poultry in Egypt [16, 38, and 39]. Impact of such co-infections in face of used life ND vaccines is the aim of this study.

Maternal mean HI antibody titres in control negative (non-vaccinated ) group (1) against H9N2 (Table 2) were  $7.9 \pm 1.8$ ,  $6.7 \pm 1.3$ ,  $4.3 \pm 1.7$ ,  $2.8 \pm 0.5$  and  $1.6 \pm 1.2$ , while NDV HI

antibody titers were  $7.6 \pm 1.7$ ,  $7.7 \pm 1.2$ ,  $5.5 \pm 1.6$ ,  $2.8 \pm 1.4$  and  $1.8 \pm 0.7$  at 1, 7, 14, 21, 29 days, respectively. The detected HI antibody titres against ND and H9 at 1 and 7 days of age measure the maternal-derived antibody level and its natural decline [40,41]. No detectable clinical signs or mortality (100% survival) in control non vaccinated non challenged sub-group (1c) (Table 3). These results indicated no possibility for outer infections during the study.

In vaccinated group: The mean NDV HI ( $\log_2$ ) antibody titers in group (2) received vaccines 1 were  $4.8 \pm 0.8$ ,  $2.4 \pm 1.2$  and  $3.9 \pm 0.5$  at age of 14, 21 and 29 days, respectively, while, Group (3) given ND vaccine 2 showed titres  $4.5 \pm 1.2$ ,  $3.6 \pm 1.1$  and  $4.0 \pm 0.4$  at 14, 21 and 29 days, respectively (Table 2). HI titres in group (4) received ND vaccine 2 and inactivated H9 vaccine were  $5.0 \pm 1.5$ ,  $3.5 \pm 1.4$  and  $4.5 \pm 1.3$ , respectively. Similar results were reported by Amer and Abd

**TABLE 1. Experimental design.**

Group	No of chicks	NDV VACCINE				H9N2 Vaccine 10 D	sub-group	Challenge Virus 33 days of age
		Vaccine 1		Vaccine 2				
		HB1 7D	La Sota 19 D	HB1 7D	La Sota 19D			
1	60	Negative control				-	1a	NDV
							1b	H9N2
							1a	-
2	40	+	+	-	-	-	2b	NDV
							2a	NDV+ H9N2
							3b	NDV
3	40	-	-	+	+	-	3c	NDV+ H9N2
4	60	-	-	+	+	+	4a	NDV
							4b	H9N2
							4c	NDV+ H9N2

**TABLE 2. HI antibody  $\log_2$  Mean  $\pm$  SD titres against NDV and H9 in vaccinated chicken groups (N=15).**

Gr No.	Vaccine	Age/ days	ND HI titres	H9N2 HI titres
			Mean $\pm$ SE	Mean $\pm$ SE
1	Control	1	$7.6 \pm 1.7$	$7.9 \pm 1.8$
		7	$7.7 \pm 1.2$	$6.7 \pm 1.3$
		14	$5.5 \pm 1.6$	$4.3 \pm 1.7$
		21	$2.8 \pm 1.4$	$2.8 \pm 0.5$
		29	$1.8 \pm 0.7^a$	$1.6 \pm 1.2^b$
2	NDV Vaccine 1	14	$4.8 \pm 0.8$	$4.5 \pm 1.2$
		21	$2.4 \pm 1.2$	$2.1 \pm 1.5$
		29	$3.9 \pm 0.5^a$	$1.8 \pm 1.2^b$
3	NDV Vaccine 2	14	$4.5 \pm 1.2$	$3.7 \pm 1.2$
		21	$3.6 \pm 1.1$	$2 \pm 1.4$
		29	$4.0 \pm 0.4^a$	$2.8 \pm 0.4^b$
4	NDV Vaccine 2 + H9N2	14	$5.0 \pm 1.5$	$3.7 \pm 1.6$
		21	$3.5 \pm 1.4$	$2.5 \pm 1.1$
		29	$4.5 \pm 1.3^a$	$5.1 \pm 1.3^b$

a,b Mean values in the same age that share a common letter differ significantly ( $P < 0.05$ )

El-Ghany [42] and Hager [5]. Generally, birds of vaccinated with ND vaccine 2 +H9 (Gr. 4) showed relatively higher HI titers followed by group 3 given vaccine 2 than group 1 vaccinated with vaccine 1. Both vaccine 1 and vaccine 2 were prepared from the same related NDV but the obtained HI titres produced by vaccine 1 were lower than that produced by vaccine 2. This result can be explained by the considerable variation that exists among the same strains produced by different biologics manufacturers [42- 45]. Also, the demonstrated immunity was differing [46, 47]. This result indicated that ND vaccine strains have the same pathogenic index can differ in their immunogenicity [48].

Group 4 given H9N2 inactivated vaccine at the 10<sup>th</sup> day of age showed HI titres of  $3.7 \pm 1.6$ ,  $2.5 \pm 1.1$  and  $5.1 \pm 1.3$  at 14, 21 and 29 days, respectively (Table 2) [49,50,51].

Vaccinated control group challenged with NDV genotype VII strain at 33 days of age (sub-group 1 a) (Table 3) showed acute disease started in the 2<sup>nd</sup> dpi with severe signs including sudden death with cyanosis of comb in the 3<sup>rd</sup> dpi with 4/20 (20%), depression, off food, greenish diarrhea and respiratory signs in day 3 to the 8<sup>th</sup> dpi. Mortality started at the 3<sup>rd</sup> to the 8<sup>th</sup> dpi to reach (100%) in the 8<sup>th</sup> dpi. Signs and mortality resulted from vNDV in control group agree with previous results [4, 5, 14, 52, 53]. This pointed out that maternal antibodies cannot protect against acute infections [54, 55].

Birds of sub-group (1c) challenged with H9N2 showed general signs with mild respiratory signs lasted for 4 days with death of 2 birds (10% mortalities). Halvorson [12] and Lee *et al.* [13] reported no mortalities. H9N2 infection was reported as asymptomatic or induced signs and lesions in respiratory, digestive and reproductive systems [10]. Sub-groups (2a, 3a and 4a) vaccinated with ND vaccine 1, ND vaccine 2 and ND vaccine 2+ H9N2 challenged with NDV (Table 3) showed signs of depression, off food and moderate respiratory signs from day 4 to day 8 with mortalities started in the 4<sup>th</sup> dpi where protection rates were 70, 70 and 75%, respectively.

Chicken sub-groups 2b, 3b and 4c of vaccinated group 2, 3 and 4 with ND vaccine 1, ND vaccine 2 or ND vaccine 2+ H9N2 and challenged with NDV+ H9N2 (Co-infection) showed signs from the 3<sup>rd</sup> dpi including depression, severe decrease in feed intake and moderate respiratory signs with protection rates of 50, 70 and 70%, respectively. Infection with both viruses had synergistic effect especially if the viruses were given sequentially [21, 31,32]. Also, there are many previous suggestions for interface between both 2 viruses [18, 19, 21, 31,32, and 33].

H9N2 sub-groups 4b given ND vaccine 2+ H9N2 and challenged with H9N2 showed 100% survival rate and transient depression at day 4 and 5 pi without further clinical signs. Vaccine may be providing protection from mortalities [14, 51].

**TABLE 3. Mortality in NDV, H9N2 virus or NDV+H9N2 challenged vaccinated and non-vaccinated chicken sub-groups (n= 20)**

Group No	Vaccine		sub-group	Challenge Virus	No of dead +ve birds	Mortality rate	Protection rate
	ND	H9N2					
1	Negative control		1a	NDV	20	100.0	10.0 <sup>a</sup>
			1b	H9N2	2	10.0	90.0
			1c	-	0.0	0.0	100.0
2	Vaccine 1	-	2b	NDV	8	40.0	60.0 <sup>a</sup>
			2a	NDV+ H9N2	10	50.0	50.0 <sup>a,b</sup>
3	Vaccine 2	-	3b	NDV	6	30.0	70.0 <sup>a,b</sup>
			3c	NDV+ H9N2	6	30.0	70.0 <sup>a,b</sup>
4	Vaccine 2 + H9N2	+	4a	NDV	5	25.0	75.0 <sup>a</sup>
			4b	H9N2	-	0.0	100.0
			4c	NDV+ H9N2	6	30.0	70.0 <sup>a,b</sup>

a,b : Protection rate values in that share a common letter differ significantly ( $P < 0.05$ )

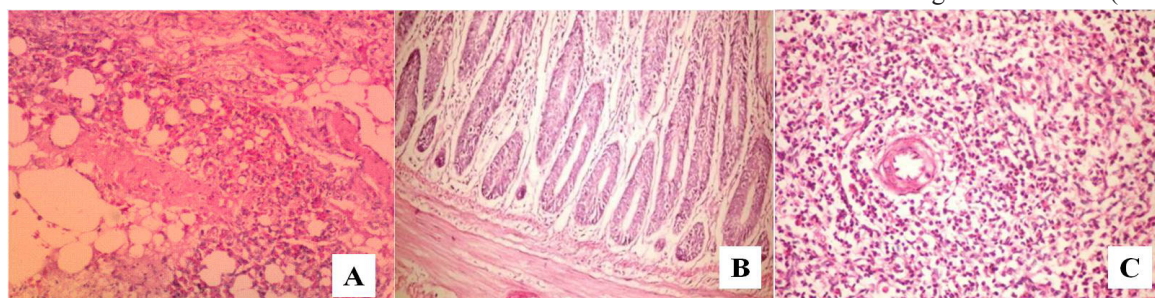


Generally, the obtained protection was unsatisfactory indicating that we still need highly effective vaccine against NDV genotype VIIj. ND vaccinated sub-groups with ND vaccine 2 survived longer and showed higher titres and protection rates as compared with those given vaccine 1 and control group.

Post mortem examination of dead birds from all non-vaccinated groups or vaccinated and inoculated with NDV showed lesions of septicemia (congested muscles and internal organs with hemorrhage on body and coronary fat), dehydration, hemorrhages on the tips of periventricular glands, greenish discoloration of intestinal proventriculus and gizzard contents, greenish content, severe necrosis and ulceration on cecal tonsils, catarrhal tracheitis with severe pneumonia, congestion of serosal intestine blood vessels and hemorrhage in intestinal mucosa [7,37,53]. Birds challenged with both NDV and H9N2 showed more prominent respiratory and proventriculus lesions. Same results were found by Lee *et al* [14] who concluded that co-infection of H9N2 with ND virus causes high mortality due to acute disease, more severe the pathologic lesions than single infection and synergistic effect if the viruses were given sequentially [21,31,32].

The recorded signs and gross lesions of vNDV challenge are in agreement with those previously reported [4, 7, 37, 52, 53, and 56].

Lung 1 (A), intestine (Fig 1, B) and spleen (Fig 1, C) sections of control negative (non vaccinated non challenged) subgroup (1c) showed apparent normal tissue structures.



**Fig. 1. Sections of control of control negative sub-group:**

**A: Apparent normal lung tissue. B: Apparent normal intestinal tissue. C: Apparent normal spleen tissue.**

*Apparent normal intestinal tissue. C: Apparent normal spleen tissue.*

Lung section of non vaccinated chicken subgroup (1b) challenged with H9 showing mild congestion of pulmonary artery at the 6<sup>th</sup> dpi (Fig 2,A), severe inflammatory infiltration

of mucosa of tertiary bronchi at the 8<sup>th</sup> dpi (Fig 2,B) and inflammatory cell infiltration in the mucosa with hyperactivity of the goblet cell in the epithelial lining of tertiary bronchi with presence of mucous mixed with desquamated cells in the tertiary bronchi lumen at the 10<sup>th</sup> dpi (Fig 2,C). Similar lung lesions following H9N2 infection in chickens were reported [9, 10, 57-60]. The tertiary bronchi of NDV challenged chickens subgroup (1a) showing lymphocytic infiltration of mucosa and presence of mucous mixed with blood in the lumen (Fig 2,D), congestion of mucosa of tertiary bronchi with inflammatory cell infiltration (Fig 2,E) at 6, 8 and 10 dpi, respectively [61-63].

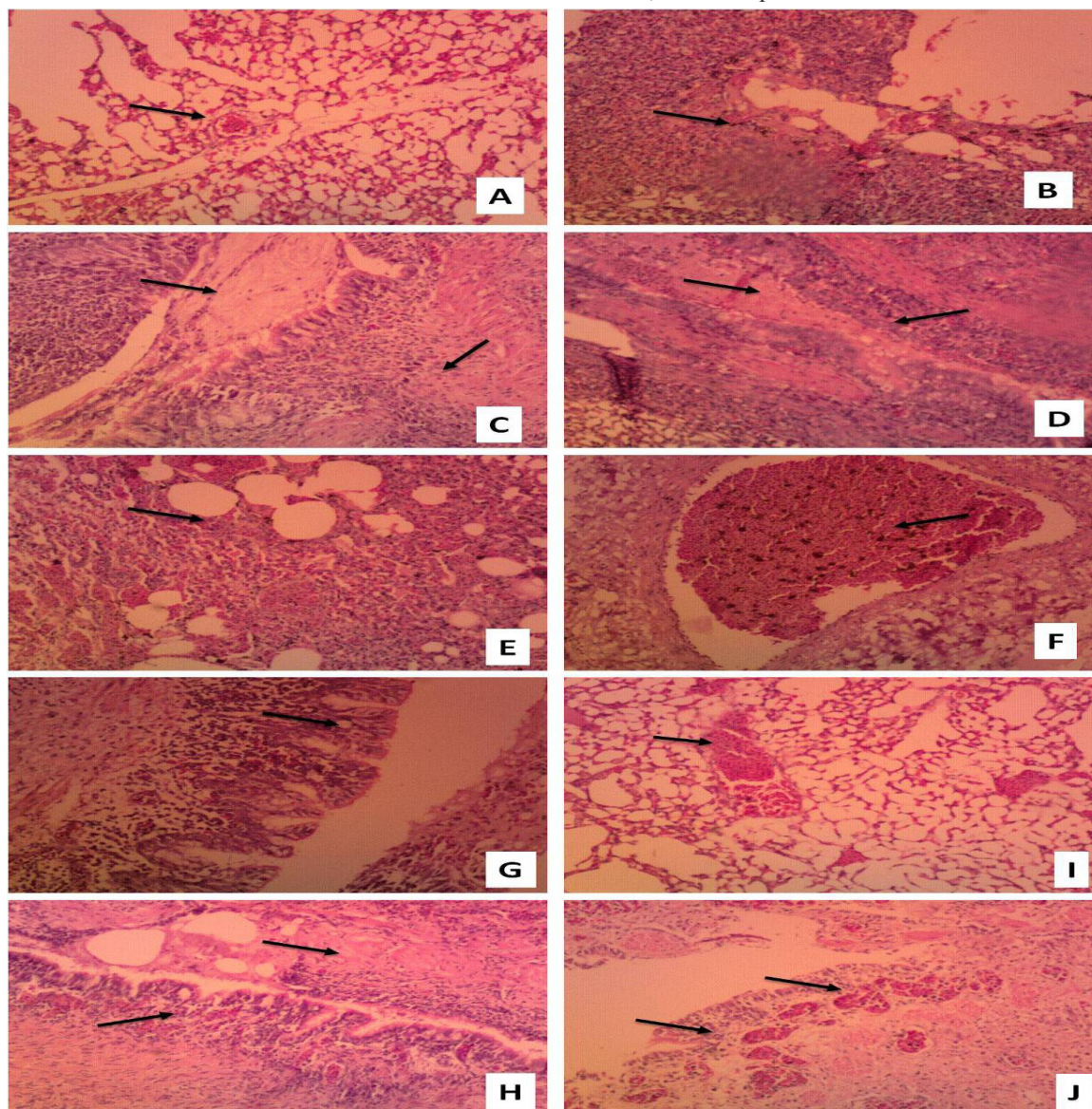
Chicken given live ND vaccine 1 and challenges with NDV (sub-group 2a): at 6 dpi, lung section showing mild to moderate congestion of pulmonary artery (Fig 2,A), while at 8 dpi congestion of pulmonary blood vessels was seen (Fig 2,F). Congestion of the blood vessels of the mucosa with inflammatory cell infiltration, hyperplasia of the epithelial lining forming finger like projection in the secondary bronchi at the 10<sup>th</sup> dpi (Fig 2,G). While, those challenged with both NDV and H9N2 (sub-group 2b) showing moderate congestion of pulmonary blood vessels (Fig 2,D), congestion of pulmonary blood vessels with presence of mucous of the lumen of tertiary bronchi (Fig 2, G) as well as congestion of the blood vessels of the mucosa with inflammatory cell infiltration. hyperplasia of the epithelial lining forming finger like projection in the secondary bronchi (Fig 2,D) at 6,8 and 10 dpi, respectively.

Group given ND life vaccine 2 and inactivated H9N2 vaccine and challenged with NDV (sub-

group 4a) showed severe congestion of pulmonary artery (Fig 2,I) at 6 dpi, severe congestion of blood vessels of mucosa with lymphocytic infiltration.. hyperplasia of epithelial lining forming finger like projections in the lumen of tertiary bronchi with presence of mucous with desquamated cells

in the lumen at 8 dpi (Fig 2,J) as well as 10 dpi, congestion of the blood vessels of the mucosa with inflammatory cell infiltration .hyperplasia of the epithelial lining forming finger like projection in the secondary bronchi (Fig 2,G) at 6,8 and 10 dpi, respectively [37]. Chicken sub-group 4b challenged with H9 showed only mild congestion of pulmonary artery at the 6<sup>th</sup> dpi (Fig 2,A) [51]. In

the other hand, sub-group 4c those challenged with NDV +H9) showing submucosal hemorrhage of secondary bronchi with lymphocytic infiltration of mucosa (Fig 2,C), congestion of pulmonary artery (Fig 2, A) and Congestion of the blood vessels of the mucosa with inflammatory cell infiltration hyperplasia of the epithelial lining forming finger like projection in the secondary bronchi (Fig 2,G) at 6 ,8 and 10 dpi.



**Fig. 2.** Lung sections of AI-H9 and/or ND virus challenged chickens (H&E X100) showing: **A:** mild congestion of pulmonary artery. **B:** severe inflammatory infiltration of mucosa of tertiary bronchi. **C:** inflammatory cell infiltration in the mucosa with hyperactivity of the goblet cell in the epithelial lining of tertiary bronchi with presence of mucous mixed with desquamated cells in the lumen. **D:** lymphocytic infiltration of mucosa and presence of mucous mixed with blood in the lumen. **E:** congestion of mucosa of tertiary bronchi with inflammatory cell infiltration. **F:** congestion of pulmonary blood vessels. **G:** Congestion of the blood vessels of the mucosa with inflammatory cell infiltration, hyperplasia of the epithelial lining forming finger like projection in the secondary bronchi. **I:** severe congestion of pulmonary artery. **J:** severe congestion of blood vessels of mucosa with lymphocytic infiltration, hyperplasia of epithelial lining forming finger like projections in the lumen of tertiary bronchi with presence of mucous with desquamated cells in the lumen.



Intestine section of control negative sub-group (1a) challenged with H9 showing congestion of mucosa with inflammatory cell infiltration and desquamation of epithelial lining of the villi at 8 dpi, (Fig. 3, A), while at 10 dpi intestine shows mild inflammatory cells infiltration of the mucosa [57,59,60]. Intestine sections of ND challenged sub- group (1b) at 6 dpi showing (Fig.3,C) necrosis of villi and lymphocytic infiltration as well as congestion of blood vessels of tunica muscosa were recorded at the 8<sup>th</sup> dpi (Fig.3,D) [5,7,53,62-64]. Chicken of sub- group 2a given ND vaccine 1 and challenged with vNDV intestine showing mild lymphocytic infiltration of the mucosa (Fig. 3,E), hemorrhage of the intestinal mucosa (Fig. 3, F) severe inflammatory cells infiltration of the mucosa (Fig. 3,G) at 6,8 and 10 dpi, respectively. Sub-group (2b) challenged with both ND and H9 viruses showing mild lymphocytic infiltration of the mucosa (Fig. 3, E) at 6 dpi , congestion of blood vessels of tunica mucosa and muscosa with inflammatory cell infiltration and necrosis (Fig. 3 , H) at 8 dpi while at 10 dpi congestion of mucosa with inflammatory cell infiltration were seen (Fig. 3, I).

Intestine of chicken group given ND vaccine 2 and inactivated, H9 V virus challenged sub-group 4a showed mild lymphocytic infiltration of the mucosa at 6 dpi (Fig. 3,J). While those challenged with NDV (sub-group 4b) showed severe lymphocytic infiltration of the intestinal mucosa (Fig.3,K) 6 dpi, severe congestion of the mucosa with necrosis of villi (Fig.3, L) at 8 dpi, and congestion of mucosa with inflammatory cell infiltration (Fig.2 ,M) at 10 dpi. Sub-group (4c) challenged with ND and H9 at 6 dpi showing necrosis of mucosa and lymphocytic infiltration (Fig.3, N) , at 8 dpi showed lymphocytic infiltration of the mucosa (Fig.3, O) while at 10 dpi intestinal section showed congestion of mucosa with inflammatory cell infiltration (Fig. 3, I).

Spleen sections of control negative H9 challenged birds (sub-group 1a) showing mild depletion of lymphoid follicle in the cortex at 6 dpi (Fig. 4, B), congestion of red pulp at 8 dpi and normal spleen (Fig. 4, C) [5, 6, 10, 53, 57]. Apparent normal spleen was seen at 10 dpi (Fig. 4, A). ND challenged chicken sub-group (1b) showing severe necrosis of the lymphoid follicle in the wide pulp accompanied with area of focal necrosis in the center of follicle (Fig.

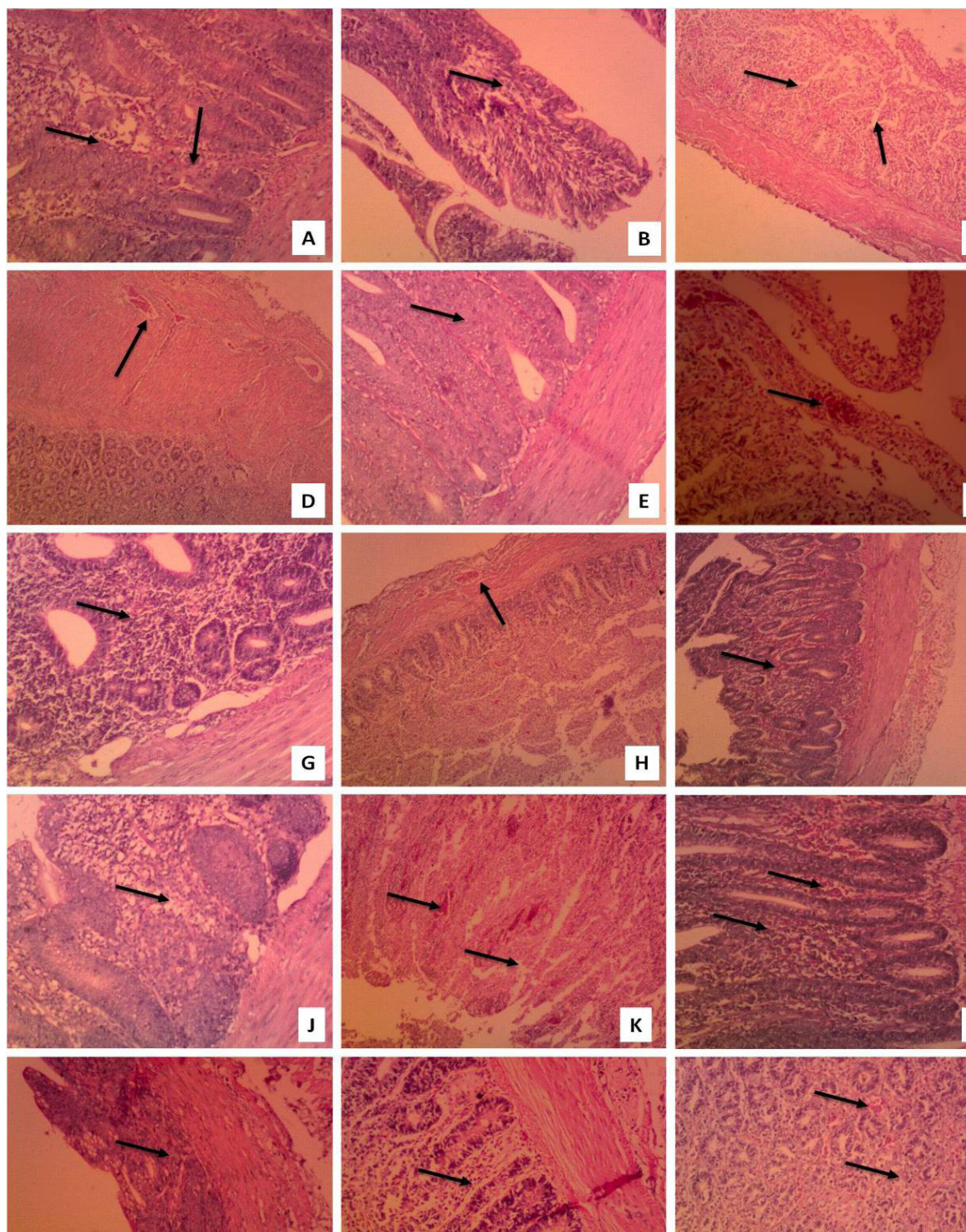
4, D) at 6 dpi, and , congestion of red pulp to area of hemorrhage in the red pulp (Fig. 4, E) at 8 dpi [62,6365]. Spleen sections of chicken given live ND vaccine1 and challenged with H9 virus (sub-group 2a) showing mild depletion of lymphoid follicle in the wide pulp 6 dpi (Fig. 4, F) , subcapsular hemorrhage (Fig. 4, G) at 8 dpi and depletion of lymphoid follicle was seen at 10 dpi (Fig. 4,H). Chicken sub-group ( 2b ) challenged with NDV at 6 dpi showing mild depletion of lymphoid follicle in the cortex (Fig. 4,I), at 8 dpi showing depletion of lymphoid follicle (Fig 4 , H) and at 10 dpi depletion of lymphoid follicle with congestion of red pulp were detected (Fig. 4, J) [66,67]. Chicken sub-group (4a) given live ND vaccine 2 and inactivated H9 vaccine followed by H9 virus challenge showed congestion of red pulp in spleen sections at 6dpi (Fig 4, B). Sub-group (4b) challenged with NDV showing depletion of lymphoid follicle in the cortex at 6 dpi (Fig.4, I) and depletion of lymphoid follicle at both 8 and 10 dpi (Fig. 4, H). While those dual challenged with H9 and ND viruses (sub-group 4c) showed severe necrosis of the splenic lymphoid follicle (Fig. 4, K), congestion of blood vessels (Fig.4, L) and depletion of lymphoid follicle (Fig.4, H) at 6, 8 and 10 dpi [68].

A comparison on the starting and severity of clinical signs of the disease as well as mortality among different vaccinated vNDV challenged groups pointed out that the vaccinated-challenged groups showed later , milder clinical signs and both gross and microscopic lesions as well as higher protection against clinical signs and mortality than the non vaccinated challenged control group [42,54,55,69,70]. Furthermore, the used vaccines did not offer good protection in face of challenge with vNDV genotype VII. This area had been discussed with researcher as they concluded that NDV genotype II still offer protection [5,52] and others with field observation found no satisfactory protection [4,53,71]. Additionally, ND and H9N2 co-infection resulted in more adverse cases.

## **Conclusion**

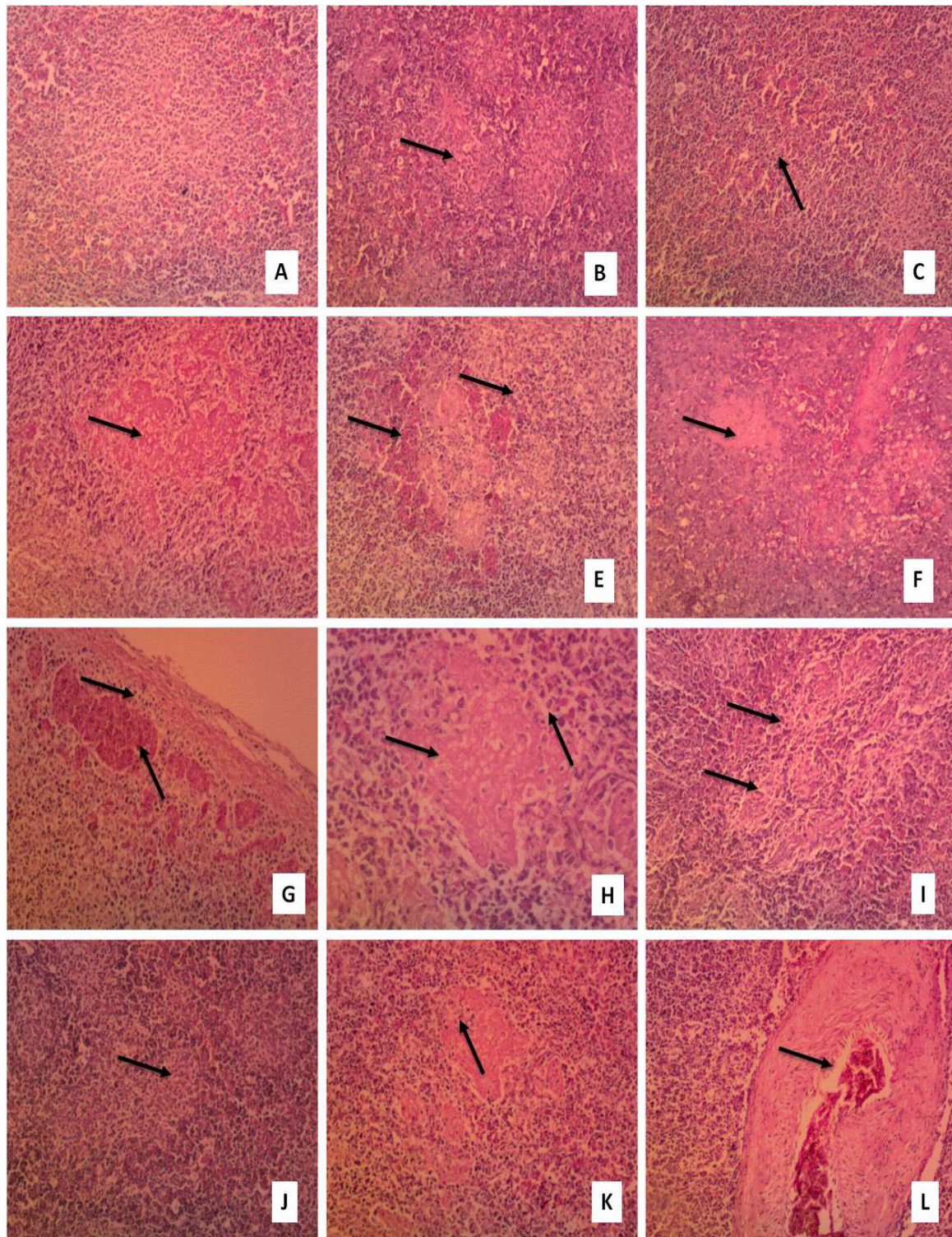
The local NDV strain genotype VIIj is highly pathogenic to male layer commercial chickens and the inoculation of NDV with H9N2 at the same time didn't increase its severity. Also, it was notable that commercial Hitchner B1 and La Sota vaccines conferred partial protection for experimentally used chickens against challenge this ND field isolate.





**Fig. 3.** Tissue section of intestine AI-H9 and/or ND virus challenged chickens (H&E X100) showing: **A:** congestion of mucosa with inflammatory cell infiltration and desquamation of epithelial lining of the villi. **B:** mild inflammatory cells infiltration of the mucosa. **C:** necrosis of villi and lymphocytic infiltration. **D:** congestion of blood vessels of tunica muscosa. **E:** mild lymphocytic infiltration of the mucosa. **F:** hemorrhage of the intestinal mucosa. **G:** severe inflammatory cells infiltration of the mucosa. **H:** congestion of blood vessels of tunica mucosa and muscosa with inflammatory cell infiltration and necrosis. **I:** congestion of mucosa with inflammatory cell infiltration. **J:** mild lymphocytic infiltration of the mucosa. **K:** severe lymphocytic infiltration of the mucosa. **L:** severe congestion of the mucosa with necrosis of villi. **M:** congestion of mucosa with inflammatory cell infiltration. **N:** necrosis of mucosa and lymphocytic infiltration. **O:** lymphocytic infiltration of the mucosa.





**Fig. 4.** Tissue section of spleen AI-H9 and/or ND virus challenged chickens (H&E X100) showing: **A:** Normal spleen. **B:** Mild depletion of lymphoid follicle in the cortex. **C:** Congestion of red pulp. **D:** Severe necrosis of the lymphoid follicle in the wide pulp accompanied with area of focal necrosis in the center of follicle. **E:** Congestion of red pulp to area of hemorrhage in the red pulp. **F:** Mild depletion of lymphoid follicle in the wide pulp. **G:** Subcapsular hemorrhage. **H:** Depletion of lymphoid follicle. **I:** Mild depletion of lymphoid follicle in the cortex. **J:** Depletion of lymphoid follicle with congestion of red pulp. **K:** Severe necrosis of the lymphoid follicle. **L:** Congestion of blood vessels.



*Ethical approval*

This study was approved from the Institutional Animal Ethics Committee and in accordance with local laws and regulations.

*Authors' Contributions:*

MMA and MHHA designed, planned this study, drafted and revised the manuscript. MAK, supervised the practical work and sampling. AMA shared in samples collection, performing the tests. MAB and A-RMI prepared tissue samples, carried out histopathological and histological examination, manuscript writing and data analysis. All authors read and approved the final manuscript.

*Acknowledgments*

The authors thank the members of Departments of Poultry Diseases, Faculty of Veterinary Medicine, Cairo University and Veterinary Research Division, National Research Centre, who facilitate the application of the molecular techniques.

*Funding statements*

The authors declared that they have funded by National Research Centre project NO 11020103.

*Conflict of Interests*

The authors declare that there is no conflict of interests regarding the publication of this article.

**References**

- Alexander, D.J. The epidemiology and control of avian influenza and Newcastle disease. *J. Comp. Pathol.*, **112**, 105-126 (1995).
- Miller, P. J., Koch, G. Newcastle disease, other avian paramyxoviruses and avian metapneumovirus infections. In: *Diseases of poultry*, 13<sup>th</sup> ed. D. E. Swayne, J. R. Glisson, L. R. McDougald, L. K. Nolan, D. L. Suarez and N. Venugopal, (Ed.), Wiley Blackwell, Ames, IA. pp. 89- 138 (2013).
- Swayne, D. E., Suarez, D. L., Sims L. D. Influenza. In: *Diseases of Poultry*, 13<sup>th</sup> Ed. J. R. Glisson, D. E. Swayne, L. R. McDougald, V. Nair, L. K. Nolan, and D. L. Suarez, (Ed.) Wiley-Blackwell, Ames, IA, pp.181- 218 (2013).
- Awad, A. M., Sedeik, M. E. , Abdel Kariem, A. A. Isolation, Molecular Characterization And Pathotyping Of Newcastle Disease Viruses From Field Outbreaks Among Broiler Flocks In Egypt From 2014-2015. *Internat. J. Current Res.*, **7** (2), 12925-12934-ISSN: 0975-833X(2015).
- Hagar M. Ahmed, Amer, M. M., Kutkat, M. A., Elbayoumi, Kh. M. Isolation and identification of Genotype VII of Newcastle disease virus from chicken flocks in six Egyptian Governorates. *Specialty J. of Medical Res and Health Sci.*, **2** (1) 1-5 (2017).
- Hussein, H.A., Emar, M.M. , Rohaim, M.A. Molecular characterization of Newcastle Disease Virus Genotype VIID in Avian influenza H5 N1 Infected Broiler Flock in Egypt. *Internat. J. Virol.* **10** (1), 46 – 54 (2014).
- El-behairy, M.A. Some Epidemiological studies on Newcastle Disease in domesticated chicken and Turkey Flocks in different Egyptian Governorates on 2015. *MSC, Thesis. Cairo University* (2016).
- Abdel-Moneim, A. S., El-Sawah, A. A., Kandil, M. A. Characterization of variant strain of Newcastle disease virus in Egypt. *BS. Vet. Med. J.*, **16**, 12-17 (2006).
- Swayne, D.E., Halvorson, D.A. Influenza. In: *Diseases of Poultry*, 12<sup>th</sup> ed., (Y.M. Saif, J.R. Glisson, A.M. Fadly, L.R. McDougald , L. Nolan (Ed.), Blackwell, Ames, Iowa, pp 153-184 (2008).
- Pantin-Jackwood, M.J., Swayne, D.E. Pathogenesis and pathobiology of Avian influenza virus infection in birds. *Rev Sci Tech* **28**, 113-36 (2009).
- Shortridge, K.F., King, A.P. Cocultivation of avian orthomyxoviruses and paramyxoviruses in embryonated eggs: Implications for surveillance studies. *Appl. Environ. Microbiol.*, **45**, 463- 467 (1983).
- Halvorson, D.A. Control of low pathogenicity avian influenza. In *Avian Influenza*, Swayne, D.E., Ed., Blackwell Publishing: Ames, IA, USA, pp. 513–536 (2008).
- Bonfante, F., Cattoli, G., Leardini, S., Salomoni, A., Mazzetto, E., Davidson, I., Haddas, R., Terregino, C. Synergy or interference of a H9N2 avian influenza virus with a velogenic Newcastle disease virus in chickens is dose dependent. *Avian Pathol.*, **46** (5) 488- 496 (2017) .
- Lee, S.M., Cho E.S., Choi B.H., Son, H.Y. Clinical and pathological studies on co-infection of low pathogenic avian influenza virus and Newcastle disease virus in the chicken. *Korean J. Vet. Serv.*, **36** (3), 163-169 (2013). <http://dx.doi.org/10.7853/kjvs>.



15. Taher, M.T., Ame, M. M., Arafah, A., Saad, F.E. Epidemiology of viral components causing respiratory problems in broilers in six Egyptian Governorates. *J. Vet. Med. Res.*, **24** (1), 308-320 (2017).
16. Hassan, K.E., Shany, S.A., Ali, A., Dahshan, A.H., El-Sawah, A.A., El-Kady M.F. Prevalence of avian respiratory viruses in broiler flocks in Egypt. *Poult. Sci.*, **95** (6), 1271-1280 (2016).
17. DaPalma, T., Doonan, B. P., Trager, N. M., Kasman, L. M. A systematic approach to virus-virus interactions. *Virus Res.*, **149**, 1-9 (2010).
18. Connaris, H., Takimoto, T., Russell, R., Crennell, S., Moustafa, I., Portner, A., Taylor, G. Probing the sialic acid binding site of the hemagglutinin neuraminidase of Newcastle disease virus: identification of key amino acids involved in cell binding, catalysis, and fusion. *J. Virol.*, **76** (4) 1816–1824 (2002).
19. Gambaryan, A., Webster, R., Matrosovich, M. (2002) Differences between influenza virus receptors on target cells of duck and chicken. *Arch. Virol.*, **147** (6), 1197–1208.
20. Woolcock, P. R. Avian influenza virus isolation and propagation in chicken eggs. In E. Spackman, (Ed.). *Avian Influenza Virus* listed. pp 35-46. Totowa, NJ: Humana Press (2008).
21. Costa-Hurtado, M., Afonso, C. L., Miller, P. J., Spackman, E., Kapczynski, D. R., Swayne, D. E., Shepherd, E., Smith, D., Zsak, A., Pantin-Jackwood, M. Virus interference between H7N2 low pathogenic avian influenza virus and lentogenic Newcastle disease virus in experimental co-infections in chickens and turkeys. *Vet. Res.*, **45** (1), 1(2014). doi: 10.1186/1297-9716-45-1.
22. França, M., Howerth, E. W., Carter, D., Byas, A., Poulson, R., Afonso, C. L., Stallknecht, D. E. Co-infection of mallards with low-virulence Newcastle disease virus and low-pathogenic avian influenza virus. *Avian Pathol.*, **43** (1), 96-104 (2014).
23. Umar, S., Azeem, T., Abid, S. A., Mushtaq, A., Aqil, K., Qayyum, M.R., Rehman, A. Effect of lentogenic Newcastle disease virus (La Sota) on low pathogenic avian influenza virus (H9N2) infection in fayoumi chicken. *J. Avian Res.*, **1** (1) 1-4 (2015).
24. Amer, M.M., Asmaa M. Maatouq, Abdel-Alim, A.G., Awaad, H.H.M. and Kutkat, A.M. Isolation and Identification of H9N2 influenza and Newcastle disease viruses co-infections in chicken. *In Press in the Journal of EJVS* (2018).
25. Reed, L.J., Muench, H. Simple method of estimating 50 per cent end point. *Am. J. Hyg.*, **27**, 493-499 (1938).
26. Allan, W.H. Diagnostic Procedures-Response, *In the Proc of the 1<sup>st</sup> Internat. Symp on Avian Influenza, Beltsville, Maryland, USA. U.S. Animal Health Ass.*, 167-171, (1981).
27. Pearson, J.E., Senne, D.A. Avian Influenza Diagnostic Procedures in the United States, In Proc, of the 1st International Symposium on Avian Influenza, Beltsville, Maryland, USA. *U.S. Animal Health Asso.*, 157-167 (1981).
28. World Organization For Animal Health (OIE) . *Manual of Diagnostic Tests and Vaccines for Terrestrial*, 7<sup>th</sup> ed., 2012.
29. Bancroft, J.D., Stevens, A., Turner, D.R. *Theory and Practice of Histological Techniques*, 4<sup>th</sup> ed., Churchill, Livingston, New York, London, San Francisco, Tokyo (1996).
30. Ge, S., Zheng, D., Zhao, Y., Liu, H., Liu, W., Sun, Q., Li, J., Yu, S., Zuo, Y., Han, X., Li, Lin., Yan, L., Wang, Y., Liu, X., Wang Z. Evaluating viral interference between Influenza virus and Newcastle disease virus using real-time reverse transcription–polymerase chain reaction in chicken eggs. *Virology Journal*, **9**, 128, (2012). DOI: 10.1186/1743-422X-9-128.
31. Costa-Hurtado, M., Afonso C.L., Miller P.J., Shepherd E., Cha R.M., Smith D., Spackman E., Kapczynski D.R., Suarez D.L., Swayne D.E., Pantin-Jackwood M.J. Previous infection with virulent strains of Newcastle disease virus reduces highly pathogenic avian influenza virus replication, disease, and mortality in chickens. *Vet. Res.*, **46**, 97-100. (2015) doi: 10.1186/s13567-015-0237-5.
32. Costa-Hurtado, M., Afonso, C.L., Miller, P.J., Shepherd, E., DeJesus, E., Smith, D. and Pantin-Jackwood, M.J. Effect of Infection with a Mesogenic Strain of Newcastle Disease Virus on Infection with Highly Pathogenic Avian Influenza Virus in Chickens. *Avian Dis.*, **60** (1 Suppl), 269-278 (2016). doi: 10.1637/11171-051915-Reg.

33. Pantin-Jackwood, M.J., Costa-Hurtado, M., Miller, P.J., Afonso, C.L., Spackman, E., Kapczynski, D.R., Shepherd, E., Smith, D. and Swayne, D.E. Experimental co-infections of domestic ducks with a virulent Newcastle disease virus and low or highly pathogenic avian influenza viruses. *Vet. Microbiol.*, **177**, 7- 17 (2015).
34. Alexander, D.J. Parsons, G. Protection of chickens against challenge with the variant virus responsible for Newcastle disease in 1984 by conventional vaccination. *Vet. Rec.*, **118**, 176-177 (1986).
35. El-Bagoury, G.F., Samar, F., El-Adaway, El-Habbaa, A.S. and Suzan S. El-Mahdy. Isolation, identification and pathotyping of Newcastle disease virus from chickens in Egypt. *Benha Vet. Med. J.*, **29** (1) 196-204(2015).
36. Vidanović D, Sekler M, Asanin R, Milić N, Nisavić J, Petrović T, Vladimir Savić V. Characterization of velogenic Newcastle disease viruses isolated from dead wild birds in Serbia during 2007. *J Wild Dis.* **47** (2), 433-441(2011).
37. Hager M. A. El-S. Studies on Newcastle disease in chicken. Poultry diseases Department, Faculty of Veterinary Medicine, Cairo University (2017).
38. Davidson, I., Fusaro, A., Heidari, A., Monne, I., Cattoli, G. Molecular evolution of H9N2 avian influenza viruses in Israel. *Virus Genes*, **48**, 457-463 (2014).
39. Banet-Noach, C., Perk, S., Simanov, L., Grebenyuk, N., Rozenblut, E., Pokamunski, S., Pirak, M., Tendler, Y., Panshin, A. H9N2 influenza viruses from Israeli poultry: a five-year outbreak. *Avian Dis.*, **51**, 290 – 296 (2007).
40. Mayahi1, M., Seifyabad Shapouri1, M.R. , Goumaran Darabi, G. Effect of time of vaccination on immunization broiler chicks against influenza a subtype H9N2 virus. *Proc. of XXII WPC. Sc.* June 8-13 Istanbul, (2004).
41. Amer, M.M., Hamouda, A.S., EL-Bayomi , K. M. Studies on maternal antibodies to avian influenza H9N2 vaccine. In *procc. of the 6<sup>th</sup> sci.Conf., Facult. Vet. Med., Beni- Suef Uni.*, 24-27, April (2010).
42. Amer M. M., Abd El-Ghany, A. W. Use of Newcastle disease vaccines from different sources in vaccination of chickens have maternal antibodies against mycoplasma. *Beni-Suef Vet. Med. J.*, **16** (1), 18-26 (2006).
43. Alexander, D. J., Sennein, D. A. Newcastle Disease: in *Poultry Diseases . Saif Y.M , Fadly, A. M., Glisson J. R McDougald L. R.. Nolan L. K. , Swayne, D. E., 12<sup>th</sup> Ed.*, Iowa State Press, Iowa, 75 –100 (2008).
44. Borland, L. J., Allan, W. H. Laboratory tests for comparing live lentogenic Newcastle disease vaccines. *Avian Pathol.*, **9** (1) 45-59 (1980).
45. Thornton, D. H., Hopkina , I. G. ,Hebert, C. N. Potency of live Newcastle disease vaccines. *Avian Pathol.*, **9** (3), 457- 464 (1980).
46. Bunens, B., Spanoghe, L., Devos, A., Vlaene, N. Commercial Newcastle disease vaccines: II: Vaccination of SPF layer chicks and ordinary broilers with five vaccines derived from La Sota and clone 30 virus strains. *Valaams Diergeneeskundig Tijdschrift.*, **52** (4), 237-254 (1983).
47. Panshsin, A., Shihmanter, E., Weisman, Y., Orveli, C. , Lipkind, M. Antigenic heterogenicity amongst the field isolated Newcastle disease virus (NDV) in relation to vaccine strain Part NII: Studies on viruses isolated from domestic birds in Israel. *Comp. immunol. Microbiol. Inf. Dis.*, **25** (3), 173-185 (2002).
48. Eidson, C. S., Kleven, S. H. Vaccination of chickens with a clone selected La Sota strain of Newcastle disease virus. *Poult. Sci.*, **59** (5), 979-984 (1980).
49. Bahl, A.K., Pomeroy, B. S. Efficacy of avian influenza oil-emulsion vaccine in breeder turkeys. *J. of Amer. Med. Asso.*, **171**, 1105 (1977).
50. Hadipour, H M, Nili, H, Asasi, K , Farjadian, S. Histologic lesions and tissue tropism of H9N2 avian influenza virus in broiler chickens. *Iran South Med J*, **10**(2),119-127(2008).
51. Nili, H., Asasi, K. Natural cases and an experimental study of H9N2 avian influenza in commercial broiler chickens of Iran. *Avian Pathol.* , **31**, 247- 252 (2002).
52. Susta, L., Miller, P. J., Afonso, C.L., Brown, C. C. Clinicopathological characterization in poultry of three strains of Newcastle disease virus isolated from recent outbreaks. *Vet. Pathol.*, **48**, 349 -360 (2011) .
53. Moussa S. A. Molecular Evolution and Pathogenicity of local Newcastle Disease Viruses and the evaluation of a selected vaccination program. PhD. Thesis, Sadat City University, Menoufiya, Egypt (2015).

54. Fentie, T, Dadi, K, Kassa, T, Sahle, M, Cattoli, G. Effect of vaccination on transmission characteristics of highly virulent Newcastle disease virus in experimentally infected chickens. *Avian Pathol.*, **43**(5), 420- 426 (2014) .
55. Kapczynski, D.R., King, D.J. Protection of chickens against overt clinical disease and determination of viral shedding following vaccination with commercially available Newcastle disease virus vaccines upon challenge with highly virulent virus from the California 2002 exotic Newcastle disease outbreak. *Vaccine*, **23**, 3424 – 3433 (2005).
56. Abd El Aziz, M.A., Abd El-Hamid S.H. , Ellkany, F. H., Soad A. Nasef, Nasr, M. S., El Bestawy, R.A. Biological and molecular characterization of Newcastle Disease virus circulating in chicken flocks, Egypt, during 2014-2015. *Zagazig Vet. J.*, **44** (1), 9-20 (2016).
57. Ebrahimi, M.S, Nili, H, Sohrabi, N. Histopathological Evaluation of A/chicken/iran/339/02 (H9N2), an Iranian Field Isolate of Influenza Virus, on Japanese Quail (*Coturnix coturnix aponica*). *World Applied Sci. J.*, **9** (2), 226 - 229 (2010).
58. Aslam, R., Aslam, A., Tipu, Y., Nazir, J., Ghafoor, A. , Fatima, S. Histopathological and immunohistochemical studies for the pathogenesis of a low pathogenicity H9 avian influenza virus in experimentally infected commercial broilers. *The J. of Animal and Plant Sciences*, **25**(1), 45-52 (2015).
59. Taubenberger, J.K., Morens D.M. The pathology of influenza virus infections. *Annu. Rev. Pathol.*, **3**, 499 – 522 (2008).
60. Capua, I. , Marangon S., (2007) Control and prevention of avian influenza in an evolving scenario. *Vaccine*. **25**, 5645-5652.
61. Chevillat, N.F., Beard, C.W. Cytopathology of Newcastle disease. *Laboratory Investigations* **27**, 129-133 (1972).
62. Alexander, D.J. Newcastle disease and other Paramyxoviridae infections. In: Calnek BW, Barnes HJ, Beard CW and McDougald L, Saif YM, (Ed.), Diseases of poultry. 10<sup>th</sup> ed., Iowa State University Press, Ames, Iowa, 1997. pp:541-570(1997).
63. Alexander, D. J. Newcastle disease, other avian paramyxoviruses, and pneumovirus infections, In: Saif YM, Barnes HJ, Glisson IR, Fadly AM, McDougald JR and Swayne DE (Ed.). Disease of Poultry, 11th ed. Iowa State University Press, Ames, 2003. pp: 63-92 (2003).
64. Lam, K., M., Newcastle disease virus-induced damage to embryonic tracheae and red blood cells. *Avian Dis* **47**, 197–202(2003).
65. Nagy, Z.A. , Horvath, E. Antigen capture in spleen and relationship to phagocytic activity in chickens. *Nature (New Biology)* **242**, 241-247(1973).
66. Hamid, H, Campbell, R. S. F., Parede, L. Studies of the pathology of velogenic Newcastle disease: virus infection in non-immune and immune birds. *Avian Pathol.*, **20**, 561-575(1991).
67. Amer, M.M., Sherein S. abdelgayed , Abeer, A. Abd El-Baky. Evaluation of some avian Influenza vaccines on commercial layer chicks. *1<sup>st</sup> International Sci. Conf. of Pathol. Dept., Faculty of Vet. Med.* ,60-78(2013).
68. Elbayoumi, Kh. M., Zeinab M.S. Amin Girh, Eman R. Hassan, Bosila, M.A., Aziza M. Amer, Amer, M.M. Semi Field Study for Evaluation of Broiler Immune Response to Used Newcastle And Avian Influenza Vaccines. *RJPBCS* , **8**(3) 2499-2509 (2017).
69. Degefa, T., Dadi, L., Yami, A., Mariam, K.G., Nassir, M. Technical and economic evaluation of different methods of Newcastle disease vaccine administration. *J. of Vet. Med.*, **51**, 365 – 369 (2004).
70. Boven, M.V., Bouma, A., Fabri, T.H.F., Katsma, E., Hartog, L., Koch, G. Herd immunity to Newcastle disease virus in poultry by vaccination. *Avian Pathol.* , **37**(1) 1- 5 (2008) .
71. Miller, P.J., King, D.J., Afonso, C.L, Suarez, D.L. Antigenic differences among Newcastle disease virus strains of different genotypes used in vaccine formulation affect viral shedding after a virulent challenge. *Vaccine*, **25**, 7238- 7246 (2007).

(Received 29/08/2018;  
accepted 20/09/2018)



## دراسات على إمرضية للعترات المحلية لفيروس النيوكاسل النمط الوراثي السابع J وأنفلونزا الطيور H9N2 في ديوك الدجاج التجاري المحصنة.

محمد محروس عامر\* أسماء محمود معتوق\*\* محمد عبد الرحمن بصيله\*\* محمد عابدين عبد ربه\*\*\* محمد جسين حسن عواض\* محمد عبد العزيز قطقاط\*\*

\* امراض الدواجن - كلية الطب البيطري - جامعة القاهرة - القاهرة - مصر.

\*\* امراض الدواجن - شعبه البحوث البيطريه - المركز القومي للبحوث - القاهرة - مصر.

\*\*\* الخليه والانسجه - كلية الطب البيطري - جامعة القاهرة - القاهرة - مصر.

الاجسام المناعيه المانع لتلازن الدم (HI) لفيوس مرض النيوكاسل (ND) في المجموعه المحصنه باللقاحات ١ (٠,٨ ± ٤,٨ ، ٢,٤ ± ١,٢ و ٣,٩ ± ٠,٥) كانت اقل منها في المجموعه اللقاح ٢ (٤,٥ ± ١,٢ ، ٣,٦ ± ١,١ و ٤,٠ ± ٠,٤) عند ١٤ و ٢١ و ٢٩ يوم من العمر ، على التوالي. مجموعه الدجاج التي تلقت لقاح النيوكاسل ٢ ولقاح H9 المعطل أظهرت ارتفاعا نسبيا في الاجسام المناعيه (٥,٠ ± ١,٥ ، ٣,٥ ± ١,٤ و ٤,٥ ± ١,٣). الاجسام المناعيه ضد H9N2 في المجموعه المعطاه لقاح H9N2 المعطل كانت ٣,٧ ± ١,٦ ، ٢,٥ ± ١,١ و ٥,١ ± ١,٣ في ١٤ و ٢١ و ٢٩ يوماً من العمر ؛ على التوالي. نتج عن اختبار التحدي بفيروس النيوكاسل النمط الجيني J السابع في عمر ٣٣ يوماً وفيات بنسبة ١٠٠٪ مع علامات حاده في المجموعه الضابطه غير الملقحة. المجموعات (٢ ، ٣ ، ٤) أ و ٤ أ) المحصنة بلقاح النيوكاسل ١ ، لقاح النيوكاسل ٢ و لقاح النيوكاسل ٢ + H9N2 أظهر علامات الخمول ، ونقص تناول العلف واعراض تنفسيه ومعيه ومعدلات الحماية كانت ٧٠ و ٧٠ و ٧٥٪. على التوالي. ظهرت المجموعه الضابطه التي اعطيت فيروس H9N2 علامات عامه مع اعراض تنفسيه خفيفه و ١٠٪ فوق ، في حين أن المجموعات السالبه اظهرت نسبة بقاء ١٠٠٪. مجموعات الدجاج التي تم تلقيحها بلقاح النيوكاسل 1 أو لقاح 2 أو لقاح ٢ مع اللقاح المعطل H9N2 وتحديها بالعدوي المزدوج (Co-infection) اظهرت اعراض تنفسيه ومعيه شديده ومعدل حمايه قدرها ٥٠ و ٧٠ و ٧٠٪ ؛ على التوالي.

كانت آفات التشريحيه في الطيور النافقه بفيروس النيوكاسل الضارى عبارة عن احتقان دموي ، وآفات معويه و تنفسيه ، بينما أظهر التي تم اعطاها العدوي المزدوج NDV و H9N2 آفات أكثر بروزاً. بصفه عامه أظهرت المجموعات التي تم تحصينها معدلات حمايه غير مرضيه (٥٠ - ٧٥٪). وأظهر اللقاح ٢ اجسام مناعيه وحمايه من اللقاح ١ وأن العدوى المشتركه تزيد من شدة الاصابه و العلامات السريره والوفيات.

تم تسجيل التغيرات النسيجه في الرئه والأمعاء والطحال من المجموعات غير المحصنه والمحصلة. كانت شدة تغير الأنسجه عاليه بشكل ملحوظ في المجموعه غير المحصنه وتغيير الأنسجه المعتدل قليلاً في المجموعه المحصنه. تراوحت التغيرات النسيجه بين الازدحام الشديد في الأوعيه الدمويه في الجهاز المختبر مع استنزاف للمفاوي في الطحال وتضخم الأنسجه للمفاويه المرتبطه بالأغشيه المخاطيه في الأمعاء. مع تغير جزئي جزئي في الأنسجه في المجموعه التي تم تحصينها.

الخلاصه: إن النمط الوراثي السابع J من فيروس مرض النيوكاسل من شديده الأمراض لديوك للدجاج التجاري ، كما أن العدوي المتمزانه بكل من فيروس النيوكاسل و الانفلونزا H9N2 يزيد من شدتها. الملاحظ أن اللقاحات التجاريه الحيه لمرض النيوكاسل Hitchner B1 و La Sota والمتاحه تجاريا تمنح حمايه غير كافيه للدجاج المعدى تجريبيا بهذه المعزولات الحقيه.

**الكلمات الداله:** العزلات المحليه H9N2 و vNDV ، لقاحات NDV ، الاجسام مناعيه التلازن ، العدوى المتمزانه ، التغيرات النسيجه والتشريجه.