

EVALUATION OF THE EFFECT OF SOME ANTIOXIDANTS FOR CONTROLLING AFLATOXICOSIS IN BROILER CHICKENS

YASMIN ALI HASSAN SADIEK ¹; TOLBA YOUNIS ABD ELMOTELIB¹;
NASHWA HAMAD MOHAMED ²;
ALAA ELDIN KAMAL YOUSSEF ³ AND OMAR AMEN¹

¹Department of Avian and Rabbit Diseases, Faculty of Veterinary Medicine, Assiut University, Egypt

²Department of Pathology and Clinical Pathology, Faculty of Veterinary Medicine,
Assiut University, Egypt

³Food Hygiene Department, Veterinary Teaching Hospital, Faculty of Veterinary Medicine,
Assiut University, Egypt

Received: 24 July 2022; **Accepted:** 28 August 2022

ABSTRACT

This study aimed to evaluate the ability of antioxidants (curcumin and lipoic acid) to ameliorate the hazardous effects of aflatoxins in broiler chickens in terms of performance, liver and kidney functions, and histopathological structures as well as compare them with the effect of a mycotoxin adsorbent (Agrimos®), a specific combination of mannan-oligosaccharides (MOS) and β-glucans extracted from the yeast cell walls of *Saccharomyces cerevisiae*. A total of 120 broilers were used and divided into 5 equal groups (n=24), each group subdivided into 2 replicates (12 birds/replicate). control negative (G1) received the basal diet, control positive (G2) basal diet+ 100µg AFB1/kg diet; Curcumin treated group (G3) received control Positive + 1 g Curcumin /kg diet ; Lipoic acid treated group (G4) received control Positive + 300 mg Lipoic acid /kg diet; Agrimos treated group (G5) received control Positive + 1 g Agrimos /kg diet. All treatments were administered from 1-30 days of age. By the end of the experiment, antioxidants (curcumin and lipoic acid) ameliorated the harmful effects of aflatoxin on performance, histopathology of target organs and serum biochemical parameters in broilers as the same degree of improvement induced by Agrimos® (mycotoxin binders).

Key words: aflatoxicosis; curcumin; lipoic acid; manan and betaglucan

INTRODUCTION

Aflatoxins are the forceful mycotoxin produced as secondary metabolites of *Aspergillus* spp including *Aspergillus flavus*, *Aspergillus paraciticus*, *Aspergillus nomius* and others. Aflatoxins are dangerous to the health of humans and animals due to

their teratogenic, carcinogenic, mutagenic, and immunosuppressive effects. In addition, aflatoxins cause massive financial loss by delaying animal growth and decreasing meat production (Khetmalis *et al.*, 2018). There are four aflatoxins produced naturally, B1, B2, G1, and G2. Aflatoxin B1 (AFB1) is the greatest shared in feed and is said to be the most biologically active form causing genotoxicity, cytotoxicity and oxidative stress (El-Nekeety *et al.*, 2017). Aflatoxins elimination from feedstuff remains one of the main tasks in animal production; this

Corresponding author: Yasmin Ali Hassan Sadiek
E-mail address: yasminali24@yahoo.com

Present address: Department of Avian and Rabbit Diseases, Faculty of Veterinary Medicine, Assiut University, Egypt

may be due to the heat stability of aflatoxin or due to other physical conditions that limit the use of these forms of inactivation (Neeff *et al.*, 2018). Upon consumption, AFB1 is absorbed in the duodenum and reaches the liver where it is bio-activated by the action of cytochrome enzymes (CYP450) (Benkerroum, 2020). Aflatoxins have been stated to produce oxidative stress owing to the generation of free radicals and reactive oxygen species (ROS) which are considered participating in the main mechanism of aflatoxin toxicity (Neeff *et al.*, 2018). There is sufficient evidence suggesting that antioxidants improve oxidative stress during mycotoxicosis by reducing the level of free radicals (Neeff *et al.*, 2018). Curcumin is a potent inhibitor of oxidative stress, acting as a direct free radicals hunter and eliminating superoxide and peroxide (Vallianou *et al.*, 2015). Lipoic acid (LA) is a metal chelator that hunt several types of free radicals and regenerates other antioxidants, such as vitamin E and glutathione (GSH) (Li *et al.*, 2014). Manno-oligosaccharides (MOS) and β -glucans have been proposed as a mycotoxin binder for inhibiting the adverse effects of mycotoxins in poultry feeds (Mustafa *et al.*, 2018) (Anwer *et al.*, 2014).

Agrimos® is a specific combination of manno-oligosaccharides (MOS) and β -glucans extracted from the yeast cell walls of *Saccharomyces cerevisiae*. The objective of the current study was to study the adverse effects of aflatoxicosis on performance and serum biochemical parameters in addition to pathological alterations. Also, to estimate the protective effect of antioxidants (curcumin and lipoic acid) and mycotoxin binder (Agrimos®) against chronic aflatoxicosis in broilers.

MATERIALS AND METHODS

Experimental Chickens:

One hundred and twenty Arbor Acres broiler chicks (one day old) were obtained from a marketable company for poultry in Egypt. Chicks were raised in litter under standard environmental and hygienic conditions and were fed on a balanced basal ration formulated according to NRC (NRC, 1994) (Table1). Feed and water were given ad libitum. All birds were vaccinated against Newcastle disease and IBD disease at suitable times.

Table 1: Composition of basal diets used for 100 kg feed

Ingredients %	Starter*	Grower**
Rice	28.1	28.1
Corn grain	28.1	33
Soyabean44%protein	33.5	30
Corn gluten	4.5	3
Sun flower oil	2.5	3.5
Lime stone	2.1	2.1
Sodium chloride	0.3	0.3
Mono-calcium phosphate	0.7	–
L-Lysine	0.05	–
DL-Methionine	0.1	–
Threonine	0.05	–

* A starter diet was fed up to 21 d. ** A grower diet was fed up to 30 d.

Aflatoxin production and determination

The aflatoxin was produced from *Aspergillus flavus* strain (AUMC No.9779)

and was obtained from Assiut University Moubasher Mycological center (AUMMC), Faculty of Sciences, Assiut University, Egypt via fermentation of rice by the

technique of Shotwell *et al.* (1966). Successfully fermented rice was then autoclaved to destroy the fungus, dried and crushed to a fine powder. Aflatoxin levels in rice powder were measured by HPLC method in the Central Lab of the Faculty of Veterinary Medicine at Assiut University. The aflatoxin within the rice powder consisted of 97.19% AFB1, and 2.8% AFB2. Crushed rice was added to the basal diet to offer (100 ppb) according to Abdel-Sattar *et al.* (2019).

Treatments:

- 1- **Curcumin powder (C₂₁H₂₀ O₆):** Molecular weight 368.39 g/mole, It was bought from a research lab company introduced from India LOT#00088EERF98, it was added to the diet in a dose rate of 1g/kg diet according to (Ruan *et al.*, 2019).
- 2- **Alpha-Lipoic acid (Thiotacid tablets):** each tablet contains (alpha-lipoic acid) 300 mg/tablet, manufactured by EVA Pharma for pharmaceuticals and medical appliances, Egypt. Each tablet was added to a 1 kg diet according to (Mourad *et al.*, 2020).
- 3- **Agrimos:** is a specific combination of mannan-oligosaccharides (MOS) and β-glucan extracted from the yeast the cell wall of *Saccharomyces cerevisiae* from Lallemand animal nutrition, it was added to the diet at a dose rate of 1 g/kg diet according to the manufacturing company.

Experimental Design:

A total number of chicks (120) were divided into five groups (n = 24) each group with two replicates). The experimental dietary groups included: control negative (G1) received the basal diet, control positive (G2) basal diet+ 100µg AFB1/kg diet; Curcumin treated group (G3) received as control Positive + 1 g Curcumin/kg diet; Lipoic acid treated group (G4) received as control Positive + 300 mg Lipoic acid/kg diet; Agrimos treated group (G5) received as control Positive + 1 g Agrimos /kg diet. All

treatments were administered from 1-30 days of age.

Health condition: Birds were reserved under remark for 30 days for the detection of any clinical signs.

Growth Performance and post-mortem examination: Body weight was individually determined on weekly basis. Body weight gain, feed consumption and feed conversion ratio (FCR) were calculated for the whole experimental period (Shehab 2008). Post-mortem examination of all birds was conducted after sacrificing at the end of the experimental period for any gross lesions.

Biochemical examinations:

Blood samples were collected in non-heparinized tubes at 21th and 30th days of the experiment. Sera were separated and kept at -18°C till usage. The separated sera were analyzed for Alanine aminotransferase (ALT) and Aspartate aminotransferase (AST) which were determined spectrophotometrically according to IFCC, (1986) using commercial kits supplied by Spectrum, Cairo, Egypt. Gamma-glutamyl transpeptidase enzyme (GGT) was determined spectrophotometrically according to the method described by Szasz and Persij, (1974) using a commercial kit supplied by Spectrum, Cairo, Egypt. Total protein, albumin, creatinine and urea were determined colorimetrically according to the method described by Kaplan and Szalbo (1983) using a commercial kit supplied by Spectrum, Cairo, Egypt.

Histopathological examination: Fresh tissue specimens were taken from the liver, kidney, spleen and bursa of Fabricius and fixed in 10 % neutral buffered formalin. The tissue processing and the staining procedure of tissue sections were applied according to Scheuer and Chalk, (1986).

Statistical analysis

Differences among groups were investigated by using One-Way ANOVA followed by

Duncan's multiple comparison Post Hoc tests (Duncan, 1955). Statistical analysis was carried out using the statistical software package SPSS for Windows (version 2016; SPSS Inc., Chicago, IL, USA). Statistical significance between mean values was set at $P < 0.05$.

RESULTS

Health condition:

The AF intoxicated chicks showed different degrees of depression; their excreta passed semisolid (soft) and loose droppings (pasty vent). They exhibited ruffled and broken feathers, abnormal wing feathers, and irregular gait from the first week till the end of the experiment. A notable improvement in the above-mentioned signs was detected in the treated groups.

Performance parameters and post-mortem findings:

Sacrificed chickens of control negative and all treated groups showed no observable gross muscle changes. Aflatoxicated birds (G2) exhibited severe congestion and petechial hemorrhages of thigh and breast muscles (Figure 1). Livers of these aflatoxicated birds were enlarged, friable and pale-discolored with subcapsular hemorrhages and distended gall bladder. Livers of curcumin- and lipoic acid- treated groups showed mild subcapsular haemorrhages, whereas those of Agrimos® were pale in color (Figure 2). Kidneys of aflatoxicated birds showed enlargement, pallor, hemorrhages and distended ureters with ureate, whereas birds of treated groups showed only mild enlargement (Figure 3).

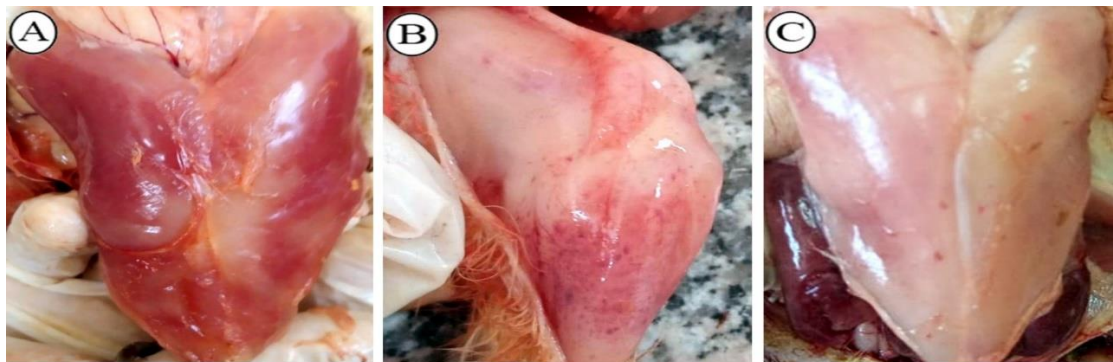

Figure 1: Gross lesions of muscles of 30 days old boilers fed with an aflatoxin-contaminated diet (G2). A) Showing congested breast muscle. B) Showing petechial haemorrhages on the thigh muscle. C) Showing petechial haemorrhages on breast muscle.

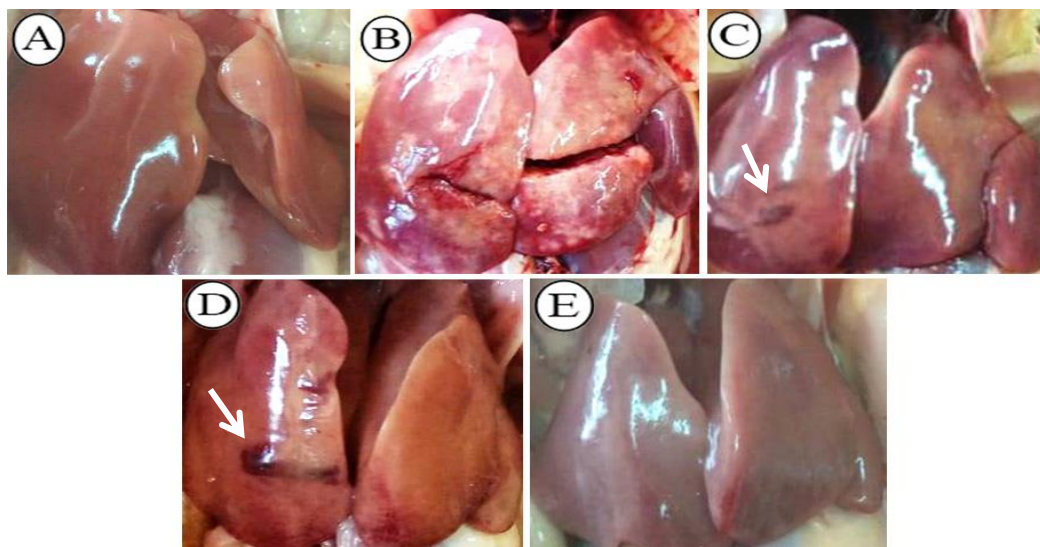


Figure 2: Gross lesions of livers of 30 days old boilers of normal control and other experimental groups. A) Control negative group (G1) showing normal gross liver appearance. B) Control positive group (G2) showing pale-colored and friable liver with severe subcapsular hemorrhages. C) Curcumin-treated group (G3) and D) Lipoic acid treated group (G4) showing mild subcapsular hemorrhages (arrows). E) Agrimos® treated group (G5) showed pale colored liver.

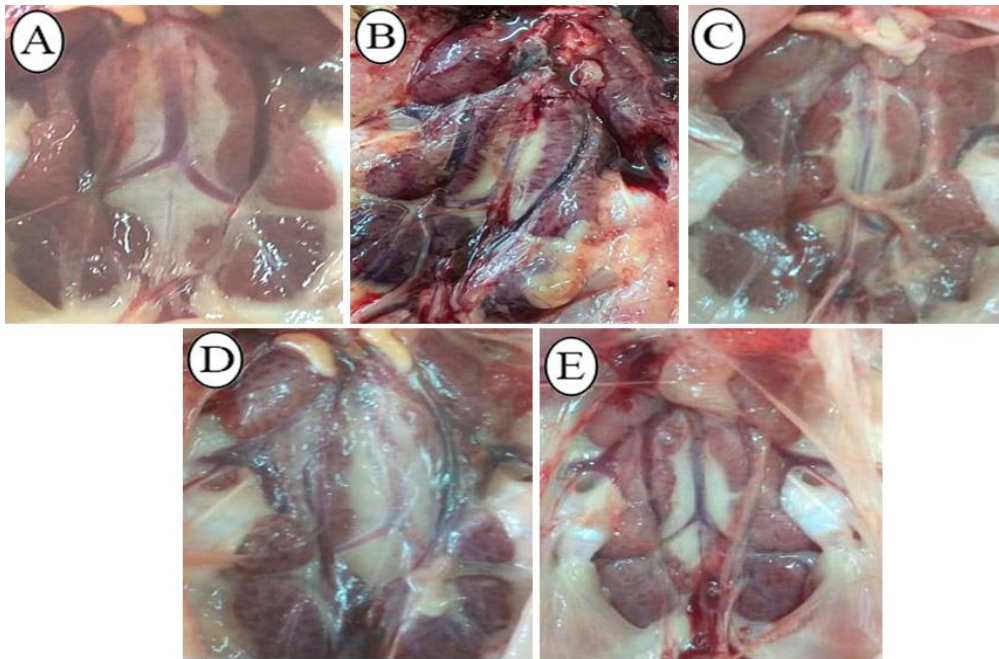


Figure 3: Gross lesions of kidneys of 30 days old boilers of normal control and other experimental groups. A) Control negative group (G1) showing normal kidney gross appearance. B) Control positive group (G2) showing enlarged and haemorrhagic kidney. C) Curcumin-treated group (G3), D) Lipoic acid treated group (G4) and E) Agrimos® treated group (G5) showing mildly enlarged kidneys.

Performance parameters:

Table (2) provides the data on the body weight of chicks during the experiment and Table (3) provides the data on the feed conversion ratio.

From Tables 2 and 3 it is important to note that:

At the end of the experiment (4th Week), there was a significant increase in body weight in the curcumin-treated group (G3) (914.67 ± 8.57) and Agrimos®-treated group (G5) (915 ± 28.71) when compared with the

control positive group (G2) (838.5 ± 17.87), while there was a significant decrease in aflatoxicated groups when compared with the control negative group (G1) (1023.5 ± 17.25^a).

At the end of the experiment, there was a significant decrease ($P < 0.05$) of FCR in the curcumin-treated group (G3), lipoic acid-treated group (G4) and agrimos®-treated group (G5) when compared with the control positive group (G2).

Table 2: Effect of the compounds used as feed additives on body weight of the broiler chickens challenged with 100 ppb aflatoxins.

Group	Treatment	Day 0	1 st Week	2 nd Week	3 rd Week	4 th Week
1	Control negative	46.6 ± 0.62^a	146.32 ± 2.71^a	362.8 ± 9.58^a	629.17 ± 19.05^a	1023.5 ± 17.25^a
2	Control positive	45.33 ± 0.52^a	125 ± 2.11^b	303.08 ± 14.26^c	500.87 ± 22.50^c	838.5 ± 17.87^c
3	Curcumin 1 gm	46.93 ± 0.54^a	131.38 ± 2.53^b	332.5 ± 9.5^{abc}	540.47 ± 13.67^{bc}	914.67 ± 8.57^b
4	Lipoic acid 300 mg	45.6 ± 0.76^a	124.92 ± 3.33^b	315 ± 11.49^{bc}	503.47 ± 22.31^c	869.5 ± 7.71^{bc}
5	Agrimos® 1 gm	46.4 ± 0.77^a	127 ± 2.9^b	343.62 ± 8.9^{ab}	573 ± 9.81^b	915 ± 28.71^b

“a, b & c”: There is a significant difference ($p < 0.05$) between any two means, within the same column that have different superscript letters, values are expressed as mean \pm standard errors.

Table 3: Effect of the compounds used as feed additives on the feed conversion ratio of the broiler chickens challenged with 100 ppb aflatoxins.

Group	Treatment	1 st Week	2 nd Week	3 rd Week	4 th Week
1	Control negative	0.948±0.00 ^d	1.18± 0.01 ^d	1.58±0.01 ^b	1.81±0.05 ^d
2	Control positive	1.14±0.01 ^a	1.48±0.02 ^a	2.17±0.07 ^a	2.59±0.09 ^a
3	Curcumin 1 gm	1.07±0.01 ^b	1.4±0.01 ^{ab}	1.7±0.04 ^b	2.23±0.03 ^b
4	Lipoic acid 300 mg	1±0.02 ^c	1.35±0.03 ^{bc}	1.65±0.04 ^b	1.97±0.02 ^{cd}
5	Agrimos® 1 gm	1.04±0.01 ^{bc}	1.28±0.02 ^c	1.67±0.02 ^b	2.15±0.05 ^{bc}

a, b & c^o: There is a significant difference ($p<0.05$) between any two means, within the same column that have different superscript letters, values are expressed as mean \pm standard errors.

Biochemical changes:

Liver function tests: The effects of aflatoxin, curcumin, lipoic acid and agrimos on liver function were evaluated and presented in table (4). On day 21, there was a significant increase ($p<0.05$) in ALT, AST and GGT (57 ± 1.7 , 39 ± 17.1 and 29.3 ± 1.08), respectively, in the control positive group (G2) when compared to the control negative group (G1) (36.3 ± 0.7 , 78.6 ± 7.1 and 9.1 ± 1.5). Also ALT, AST and GGT were significantly decreased ($p<0.05$) in curcumin and Agrimos treated groups when compared to the control positive group, whereas the lipoic acid treated group showed a

significant decrease ($p<0.05$) in ALT and AST only in comparison with control positive group.

At the end of the experiment (30 days), there was a significant increase ($p<0.05$) in ALT, AST and GGT in the control positive group (G2) when compared to the control negative group (G1). Curcumin-treated group showed significantly decreased of ALT, AST and GGT ($p<0.05$) when compared to the control positive group. But lipoic acid and Agrimos treated groups revealed a significant decrease ($p<0.05$) in ALT and GGT only in comparison with the control positive group.

Table 4: Effect of the compounds used as feed additives on liver enzymes in the broiler chicken challenged with 100 ppb aflatoxins.

Group	Treatment	ALT(U/L)		AST (U/L)		GGT(U/L)	
		21 st day	30 th day	21 st day	30 th day	21 st day	30 th day
1	Control negative	36.3±0.7 ^c	33.8±0.6 ^c	78.6±7.1 ^b	91.1±2.4 ^c	9.1±1.5 ^c	13.5±0.6 ^b
2	Control positive	57±1.7 ^a	47.7±1.2 ^a	139±17.1 ^a	144.5±1.9 ^a	29.3±1.08 ^a	21±0.9 ^a
3	Curcumin 1 gm	35.6±0.7 ^c	35.4±1.7 ^{bc}	83±3.7 ^b	116.3±1.6 ^b	15.7±3.1 ^{bc}	14.6±0.8 ^b
4	Lipoic acid 300 mg	43.4±1.8 ^b	39.1±2.2 ^{bc}	99.1±13.3 ^b	131.3±1.6 ^{ab}	20.3±5.4 ^{ab}	14±2.7 ^b
5	Agrimos®	47±1.1 ^b	40.6±3.0 ^b	76±13.9 ^b	132.3±10.9 ^{ab}	13±0.3 ^{bc}	12.2±1.2 ^b

a, b & c^o: There is a significant difference ($p<0.05$) between any two means, within the same column that have different superscript letters, values are expressed as mean \pm standard errors.

Kidney function tests: The effects of aflatoxin, curcumin, lipoic acid and Agrimos on kidney function were evaluated and presented in Table (5).

At 21 day, there was a significant increase ($p<0.05$) in serum urea and creatinine levels in the control positive group (G2) when compared to the control negative group. There was a non-significant difference in urea levels of all treated groups (G3, G4, G5) when compared to the control positive group (G2), but there was a significant

decrease in creatinine in both curcumin and Agrimos treated group.

At the end of the experiment (30 days), there was a significant increase ($p<0.05$) in serum urea and creatinine levels in the control positive group (G2) when compared to the control negative group. Agrimos treated group showed a significant decrease in both urea and creatinine levels but curcumin and lipoic acid treated groups only showed a significant decrease in creatinine level only without any significant difference in serum urea levels.

Table 5: Effect of the compounds used as feed additives on serum urea and serum creatinine levels in the broiler chicken challenged with 100 ppb aflatoxins.

Groups	Treatment	Urea (mg/dl)		Creatinine(mg/dl)	
		21 st day	30 th day	21 st day	30 th day
1	Control negative	9.1±0.39 ^b	11.59±0.62 ^b	0.55±0.02 ^c	0.44±0.08 ^b
2	Control positive	14.1±0.82 ^a	18.1±1.02 ^a	1.34±0.18 ^a	0.99±0.17 ^a
3	Curcumin 1 gm	10.9±1.01 ^{ab}	19.4±0.32 ^a	0.9±0.01 ^b	0.44±0.04 ^b
4	Lipoic acid 300 mg	12.4±2.18 ^{ab}	18.1±1.74 ^a	1.2±0.16 ^a	0.61±0.07 ^b
5	Agrimos®	14.5±1.17 ^a	13.5±1.35 ^b	0.73±0.62 ^{bc}	0.45±0.11 ^b

a, b & c": There is a significant difference ($p<0.05$) between any two means, within the same column that have different superscript letters, values are expressed as mean ± standard errors.

Serum proteins:

As clarified in table 6, on the 21st day of experiment, intoxicated chicks in the control positive group (G2) showed a significant decrease ($p<0.05$) of total protein and albumin concentrations when compared to the control negative group G1. The use of curcumin, lipoic acid and Agrimos as feed additives displayed a significant increase ($p<0.05$) in total protein and albumen concentrations when compared to the control positive group G2.

At the end of the experiment (30th day), Intoxicated chicks in the control positive

group (G2) showed a significant decrease ($p<0.05$) in total protein and albumin concentrations when compared to the control negative group G1. The use of curcumin as feed additives showed a significant increase ($p<0.05$) in total protein and albumen concentrations when compared to control positive group G2. Using lipoic acid and Agrimos as feed additives revealed a significant increase ($p<0.05$) in total protein concentrations when compared to control positive group G2 but showed no significant difference in albumen concentrations in comparison with control positive group G2.

Table 6: Effect of the compounds used as feed additives on serum urea protein levels in the broiler chicken challenged with 100 ppb aflatoxins.

G	Treatment	Total protein (g/dl)		Albumen (g/dl)	
		21 st day	30 th day	21 st day	30 th day
1	Control negative	3.6±0.08 ^a	4.9±0.14 ^{ab}	1.8±0.09 ^a	2.5±0.15 ^a
2	Control positive	2.7±0.08 ^b	2.8±0.54 ^c	1.2±0.06 ^b	1.4±0.18 ^c
3	Curcumin 1 gm	3.5±0.16 ^a	4.7±0.33 ^{ab}	1.7±0.13 ^a	2.1±0.21 ^b
4	Lipoic acid 300 mg	3.4 ±0.08 ^a	5.3±0.22 ^a	1.7±0.15 ^a	1.5±0.08 ^c
5	Agrimos®	3.6±0.21 ^a	4.1±0.39 ^b	1.7±0.09 ^a	1.6±0.07 ^c

a, b & c^o: There is a significant difference ($p < 0.05$) between any two means, within the same column that have different superscript letters, values are expressed as mean \pm standard errors.

Histopathological findings:

Liver sections of the control negative group (G1) revealed a normal histomorphological appearance of hepatic parenchyma. The control positive group (G2) showed marked changes in the form of extensive vascular congestion, hemorrhage, diffuse

mononuclear cellular infiltration and widespread hepatocyte necrosis. Liver sections of birds of treated groups (G3, G4, and G5) displayed noticeable improvement of hepatic parenchymal architecture with mild vascular congestion (Figure 4)

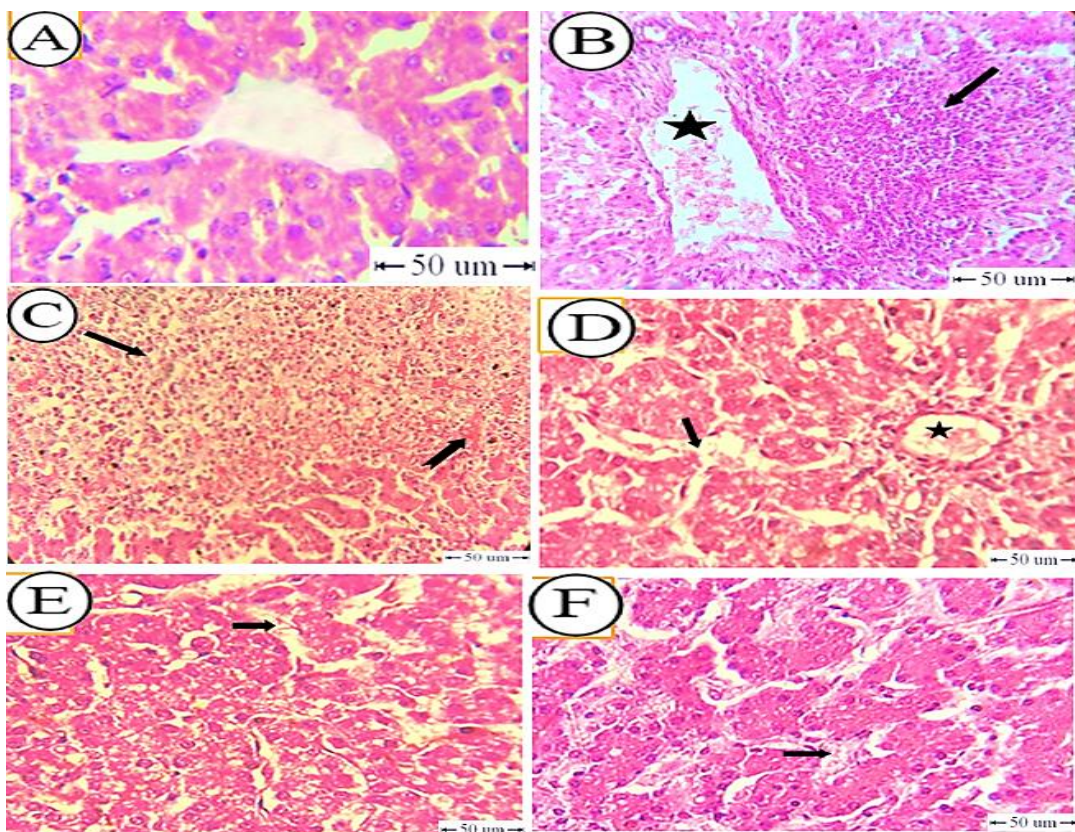


Figure 4: Photomicrograph showing histopathological changes of liver tissues of control negative and other experimental groups. A) Control negative group showing normal histological criteria of the hepatic parenchyma. (B-C) Showing control positive group. B) Vascular congestion (star) and diffuse mononuclear cells infiltration (arrow). C) Diffuse hepatocytes necrosis (arrow) and hemorrhage (notched arrow). (D-F) treated groups (G3, G4, G5) showing mild vascular congestion (arrow) (H&E, bar= 50 μ m).

Microscopical examination of kidney sections from the control negative group (G1) showed a normal histological appearance. Control positive group (G2) revealed diffuse tubular necrosis, mononuclear cells infiltration and cortical

fibrosis. G3, G4, and G5 showed marked improvement of the kidney parenchyma with only mild changes which were represented by coagulative necrosis of some cortical tubules (Figure 5).

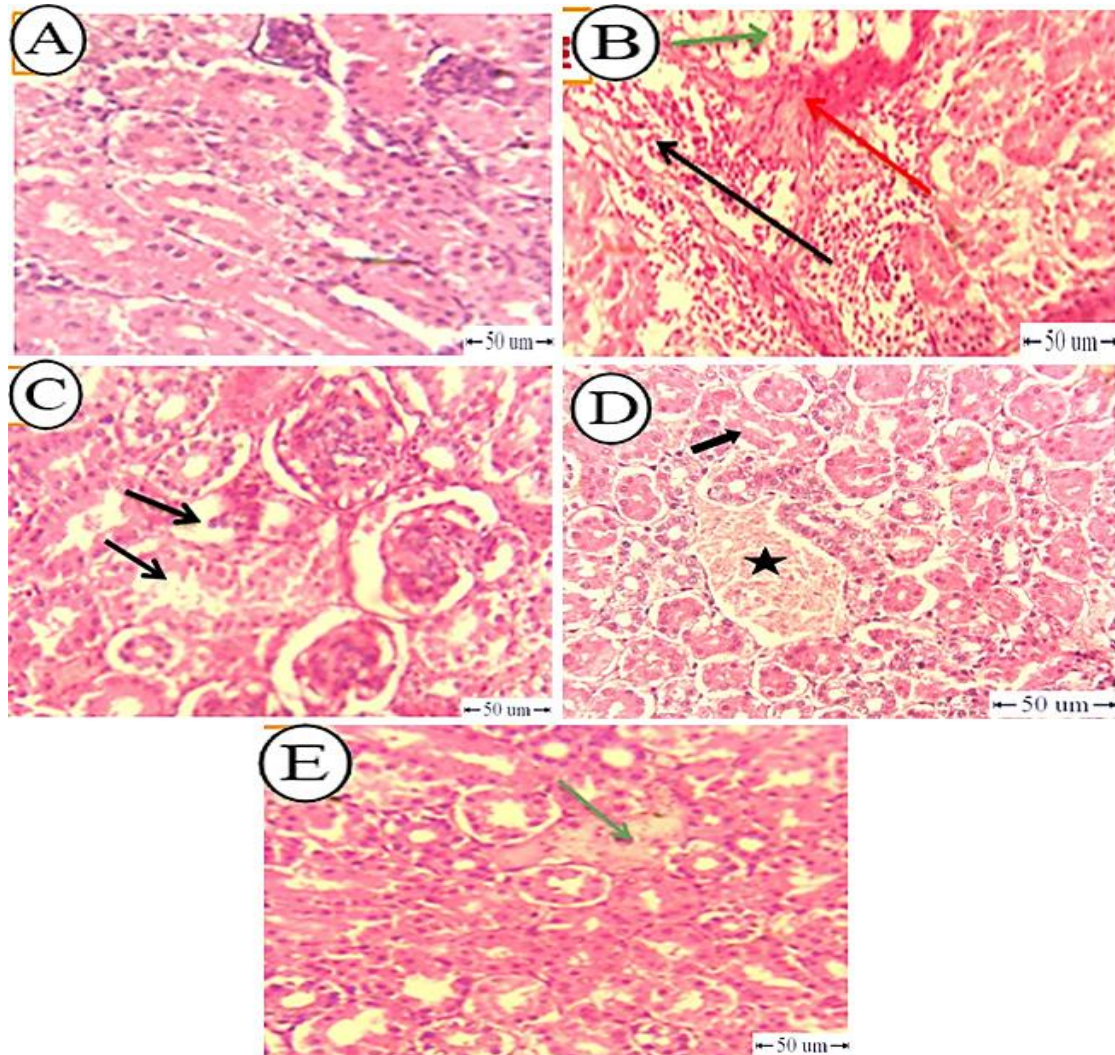


Figure 5: Photomicrograph showing histopathological changes of kidney tissues of control negative and other experimental groups. A) Control negative group showing normal histological appearance. B) Control positive group showing diffuse tubular necrosis (green arrow), mononuclear cells infiltration (black arrow) and cortical fibrosis (red arrow). C) G3 showing coagulative necrosis of individual renal tubules (arrow). D) G4 showing mild vascular congestion (star) and coagulative necrosis of individual tubule (arrow). E) G5 showing a focal area of necrosis (arrow) (H&E, bar= 50µm).

Spleen tissue sections of the control negative group (G1) showed a normal appearance of white and red pulps. Control positive group (G2) revealed marked lymphoid necrosis and depletion as well as fibrosis. G3 showed

perivascular fibrosis and lymphoid depletion. Mild depletion of the lymphoid elements of white and red pulps was observed in G4 and G5 (figure 6).

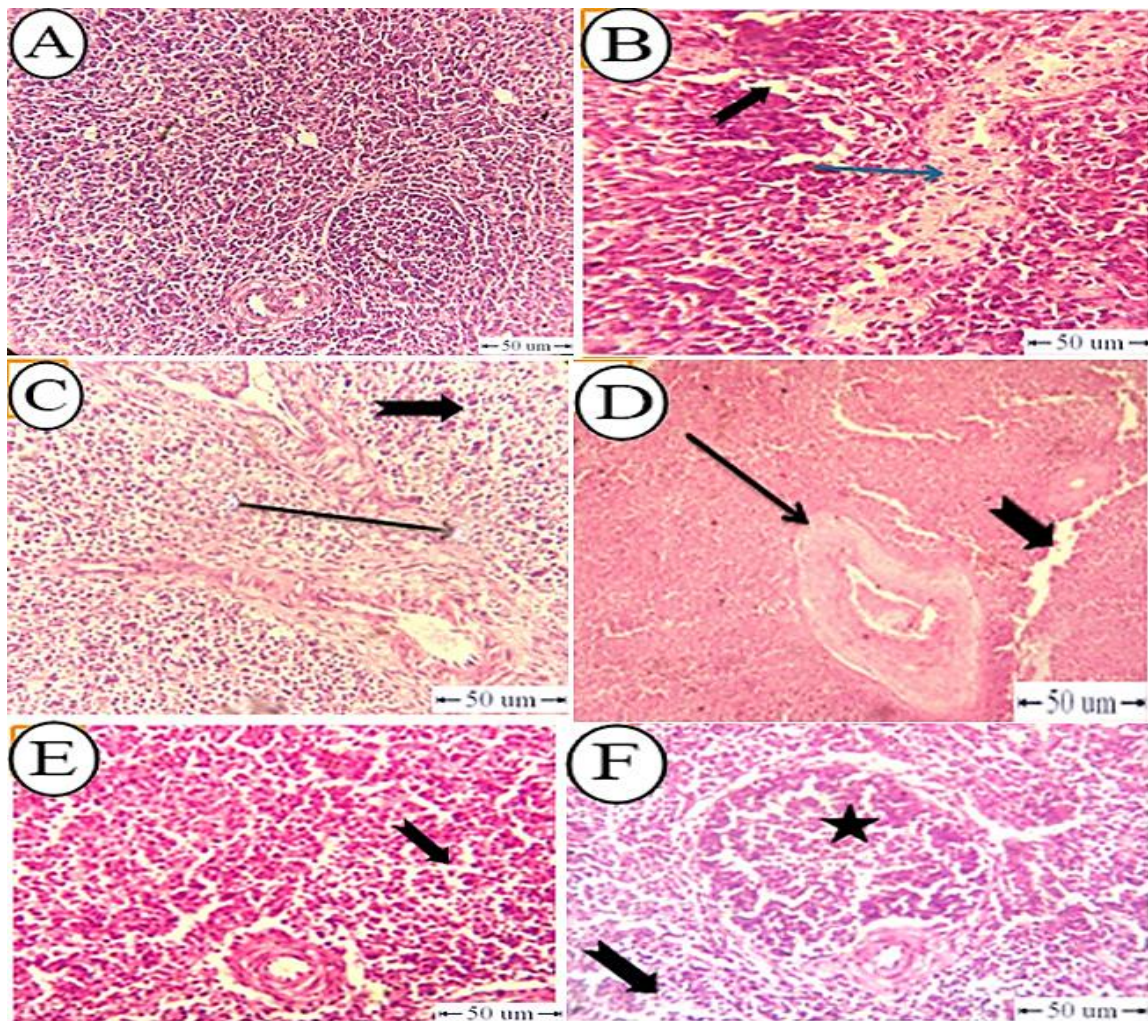


Figure 6: Photomicrograph showing histopathological changes of spleen tissues of control negative and other experimental groups. A) Control negative group showing normal histological appearance. (B-C) Control positive group showing lymphoid depletion (notched arrow) and fibrosis (arrow). D) G3 showed perivascular fibrosis (arrow) and lymphoid depletion (notched arrow). E) G4 showing mild depletion of the lymphoid elements of the red pulp (notched arrow). F) G5 showing mild lymphoid depletion of white (star) and red pulp (notched arrow) (H&E, bar= 50µm).

Tissue sections of the bursa of Fabricius of the control negative group (G1) showed normal histological appearance. Control positive group (G2) displayed marked depletion of the lymphoid follicles.

G3 and G4 showed moderate depletion of the lymphoid follicles. Mild depletion of the lymphoid elements and edema of the interfollicular connective tissue were observed in G5 (Figure 7).

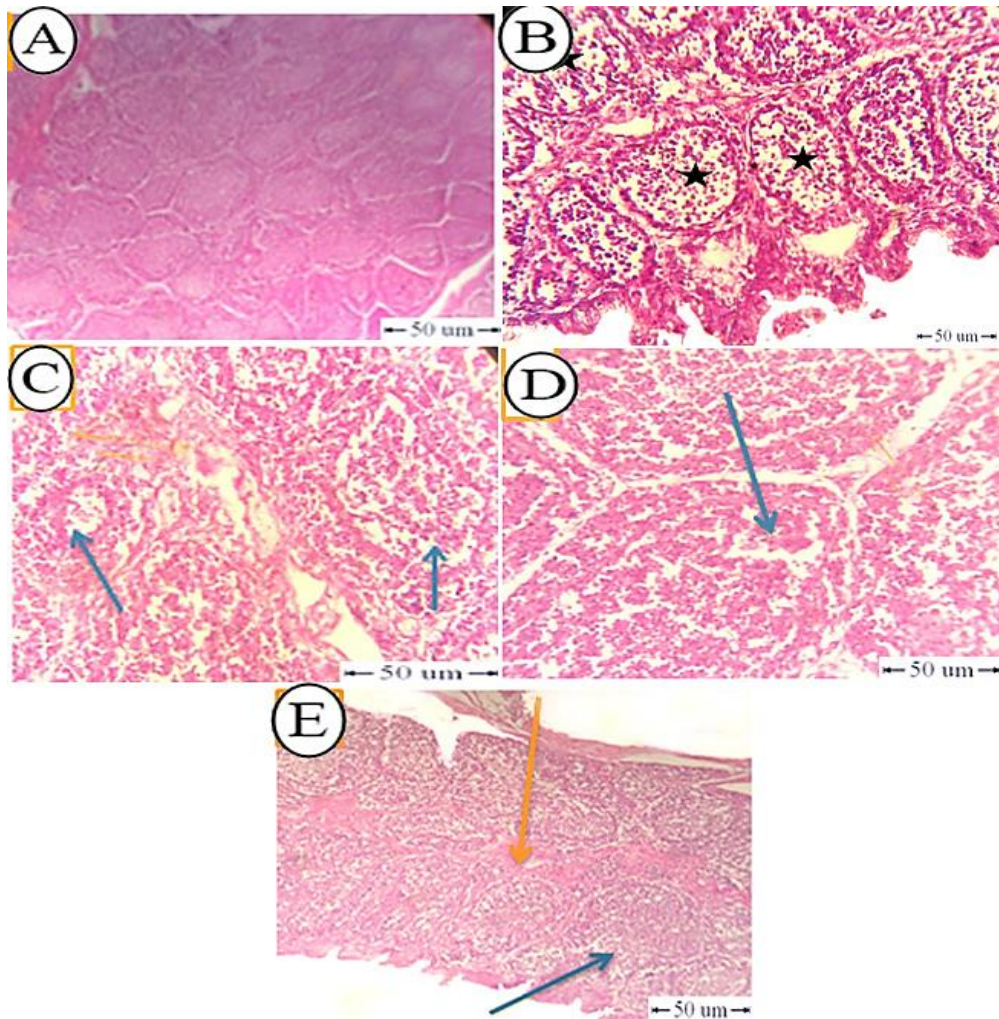


Figure 7: Photomicrograph showing histopathological changes of the bursa of Fabricius of control negative and other experimental groups. A) Control negative group showing normal histological appearance. B) Control positive group showing marked depletion of the lymphoid follicles (star). C) G3 and D) G4 showed moderate depletion of the lymphoid follicles (arrow). E) G5 showing Mild depletion of the lymphoid elements (blue arrow) and edema of the interfollicular connective tissue (yellow arrow) (H&E, bar= 50µm).

DISCUSSIONS

Mycotoxins are well-thought-out as unavoidable contaminants in diets all over the world. Aflatoxins are the most common mycotoxin in poultry ration (Surai and Mezes, 2005). Our findings of clinical signs in aflatoxicated group and aflatoxicated treated groups (G3, G4 and G5) were well-matched with Ashry *et al.* (2022); Hussain *et al.* (2016) and Mourad *et al.* (2020) who observed clinical signs in the form of stunted growth, foot, wing paralysis, lameness and diarrhea although using the previously

treated compound decrease the severity of clinical signs for some extent.

Our results of post-mortem lesions in both aflatoxicated (G2) and aflatoxicated treated groups (G3, G4 and G5) were in agreement with Fani Makki *et al.* (2013); Lande *et al.* (2019) and Sharma and Singh (2019) who reported that aflatoxicated groups had enlarged, pale yellow colored liver with friable consistency and occasional necrotic foci. Kidneys of birds from aflatoxicated groups were enlarged, pale and hemorrhagic with distinct lobulations.

One of the most economic effects of AFB1 in broilers is the diminution of performance parameters (Resanovic et al, 2009). In the current study, the administration of 100 ppb in the control positive group (G2) showed a significant decrease in body weight and a significant increase in feed conversion ratio when compared with the control negative from 1st week till the end of the experiment (4th week). Our results are in agreement with Magnoli *et al.* (2017); Abdelnaser *et al.* (2017); Arafat *et al.* (2017); Salema *et al.* (2018); Abdel-Sattar *et al.* (2019); Kurniasih and Prakoso, (2019) and Lin *et al.* (2022) who noticed that AFB1(100ppb) diminished daily weight gain and average daily feed intake, causing growth retardation of broilers, the harmful effect on growth parameters of broiler chicken may be caused as a result of diminishing of protein synthesis by aflacotoxins. The addition of curcumin 0,1 % or Agrimos® 0,1 % to the diet contaminated with 100 ppb aflatoxin significantly alleviated its adverse effects on these performance parameters. This result matched with Gowda et al, (2008) who found that the addition of turmeric powder at a dose of 74 mg /kg diet to the AFB1(1000 ppb) diet significantly enhanced weight gain, and with Cruz *et al.* (2019) who reported that the addition of curcumin (0.2%) to the diet containing Aaflatoxin significantly reduced its adverse effects on these performance parameters, and with Darwish and El shukary, (2020) who found that using turmeric powder supplement in fayoumi broiler feed improved body weight gain and FCR, also Attia *et al.* (2016) observed that supplementation of mannan oligosaccharides at 2 g/kg diet-induced recovery in growth performance of groups challenged by 200 ppb AF for 21 days; Yildirim *et al.* (2011) evaluated the effect of glucomannan in broilers challenged by aflatoxiosis 2 mg/kg for 21 days and demonstrated that the weight gains and feed efficiency were partially restored; Ibrahim *et al.* (2021) who found that The addition of 0.1% agrimos to broilers has a positive effect on growth parameters, carcass traits without adverse effect on

broiler immunity; Abdel-raheem and Esmail, (2012) found that quils fed diets with medium MOS level (3 g /kg feed) recorded significant ($P < 0.05$) improvements in body weight, weight gain and feed conversion efficiency, The addition of alpha-lipoic acid (0.03%) didn't significantly increase BW or BWG, but only made a significant decrease ($P < 0.05$) of FCR as compared to the non-treated aflatoxicated group. These agreed with Sakr *et al.* (2020) who indicated that the addition of alpha lipoic acid (50,100 and 200 mg/kg diet) significantly ($p \leq 0.05$) improved FCR results when compared with the control group and in contrast to Mourad *et al.* (2020) who found that aflatoxicated treated with lipoic chickens showed a significant increase of body weight when compared to aflatoxicated group at the end of the experiment. This may be due to the difference in aflatoxin b1 percentage in the total aflatoxin used as in our present study aflatoxin b1 was 97.19% of total 100ppb and the rest was aflatoxin b2(2.8%).

Increased levels of serum ALT, AST, GGT are indicators of liver injury (ÇELİK *et al.*, 2005). In this study, at 21 days and at the end of the experiment 30 days there was a significant increase ($p < 0.05$) in ALT, AST and GGT in the control positive group (G2) when compared with the control negative group(G1) as reported by (Subhani *et al.*, 2018) and (Zabiulla *et al.*, 2021). These biochemical alterations resulted from liver damage. In curcumin supplemented group serum ALT, AST and GGT were significantly decreased ($p < 0.05$) at 21 and 30 days consistent with the findings of Ahangaran *et al.* (2016) who noticed that chickens fed with turmeric extract in food contaminated with 3 ppm of aflatoxin had significant lower ALT and AST. The addition of alpha-lipoic acid or Agrimos to aflatoxicated diet significantly decreases serum ALT and GGT at 30 days when compared to the control positive group but they only made a numerical improvement in serum AST when compared to the control positive group. These results agreed to some

extent with that reported by Sakr *et al.* (2020) who demonstrated that alpha-lipoic acid supplementation (50, 100 and 200 mg/kg diet) significantly reduced ($p \leq 0.05$) serum ALT, AST, and GGT when compared with the control group. And also agreed with Chen *et al.* (2020) who observed that compared with the heat stress group, dietary supplementation of manan oligo saccharides reduced serum ALT activity ($P < 0.05$) in broilers challenged with heat stress.

Our findings for kidney function tests at 21 day till the end of the experiment indicated that broilers in the control positive group (G2) showed a significant increase ($P < 0.05$) in both serum urea and creatinine level when compared with levels of the control negative group. These results agreed with those mentioned by Naseem *et al.* (2018) who found that at the end of the experiment, serum urea and creatinine concentrations of aflatoxicated groups were significantly higher in comparison with the control group. The high serum creatinine level is an indicator of kidney dysfunction and kidney damage, submits that it may be caused by the toxic effect caused by aflatoxin (Andretta *et al.*, 2012) and (Chen *et al.*, 2014). Also, the cause of high plasma urea concentrations is related to AFB1-induced nephrotoxicity (Kubena *et al.*, 1991). Also, Gowda and Ledoux (2008) reported that increased urea and creatinine levels in 2 and 6-weeks old broilers fed 3 mg/kg AFB1 contaminated feed was related to inflammatory and dystrophic processes in the renal tubules. These results are accepted as a suggestion that AFB1 exposure may lead to degenerative changes in the kidney, leading to a decrease in the function of this organ. Agrimos® treated group showed a significant decrease ($p < 0.05$) in serum urea level at the end of the experiment and serum creatinine from 21 days till the end of the experiment. These results agreed with a previous study mentioned by Yildirim *et al.* (2011) who studied the effect of glucomannan in broilers challenged by aflatoxicosis 2 mg/kg for 21 days and

demonstrated that the uremia and the creatininemia were significantly enhanced regardless of the presence of liver and kidney damage similar to those observed in the aflatoxin group. Curcumin-treated group didn't show any significant difference in urea level but creatinine level was significantly decreased ($p < 0.05$) at 21 and 30 days when compared to the control positive group. Our results were in agreement with that reported by (Cruz *et al.*, 2019). Likely, curcumin treated group addition of lipoic acid didn't show any significant difference in urea level and only significantly improved creatinine level at the end of the experiment. This result matched with Li *et al.* (2014) who reported numerical enhancement of uric acid and creatinine in the lipoic acid treated group while increased in aflatoxicated chickens as compared to control and totally agreed with Mourad *et al.* (2020) (who stated that at the end of the experiment, only creatinine was significantly reduced in lipoic acid treated group).

Serum total protein and albumin were significantly decreased after 21 days till the end of the experiment in the aflatoxin administrated group (G2) when compared to the control negative (G1). This is indicative of the toxic effect of aflatoxin B1 on the liver and kidneys and is an indicator of diminished protein synthesis (Hussain *et al.*, 2016). These results were in agreement with that reported by (Arafat *et al.*, 2017); (Subhani *et al.*, 2018) and (Cruz *et al.*, 2019). The addition of curcumin showed a significant increase in serum protein and albumin at the end of the experiment when compared to the control positive group. Our results go hand in hand with (Cruz *et al.*, 2019).

The use of lipoic acid and Agrimos led to a significant increase in total protein level but showed no significant difference in serum albumin level. These results were in agreement with that reported by Murali and George (2020) who found that supplementation of alpha lipoic acid at 100

mg/kg diet did not have any effect on serum albumin level in broiler chicken consumed with an animal fat-containing diet, however serum protein levels. Also, our results agreed to a certain degree with Ashry *et al.* (2022) who demonstrated that the addition of Saccharomyces cell wall to the aflatoxicated diet in broilers for 35 days resulted in a significant increase ($p < 0.05$) in serum protein and albumin when compared to control positive group.

It was clear that curcumin, lipoic acid and agrimos® effectively controlled aflatoxicosis in broilers. These results were confirmed by the histopathological examination which showed the severity of histopathological lesions induced by aflatoxins in the liver, kidney, spleen and bursa of Fabricius were reduced in aflatoxicated treated groups (G3, G4 and G5) when compared with aflatoxicated group (G2). This was going hand by hand with that mentioned by Cruz *et al.* (2019) who observed that histopathological findings that were obtained from the treated group with curcumin are close to the negative control group, showing that the addition of curcumin (0.2%) to the diets could be a choice to decrease the detrimental effects of AFB1, and Li *et al.* (2014) who observed that livers from broilers fed the AFB1 plus lipoic acid showed minor lymphocytes infiltration and slight vacuolar degeneration suggesting a protective effect of lipoic acid on aflatoxicosis and Mourad *et al.* (2020) who found that adding lipoic acid to aflatoxicated diet exhibited slight infiltration and hemorrhage in livers and slight congestion and edema of tubules when compared with the severity in histopathological results in aflatoxicated group. Yavuz *et al.* (2017) observed that 1g Glucomannan/kg to aflatoxicated diet for one-day-old quails result in a partial reduction in the severity of microscopic lesions seen in the liver, bursa of Fabricius and spleen.

CONCLUSION

It could be concluded that broilers feeding with 100 ppb of AF caused severe toxic effects on performance, target organs and serum biochemical variables. The dietary supplementation with curcumin (1g/kg diet), lipoic acid (300 mg/kg diet) and Agrimos (1g/kg diet) separately could significantly diminish some of the toxic effects that incurred by AF.

REFERENCES

- Abdelnaser, T.H.A.; El Nabarawy, M.A.; Zyan, A.K.; Afaf, D. Abd El Magid, D.A. and El Basuni, S.S (2017): Evaluation of the Economic Efficacy of Some Antimycotoxicosis Compounds on Production and Humoral Immunity in Broiler Chickens. Journal of Advanced Veterinary Research, 7(4): 100-107.
- Abdel-Sattar, W.M.; Sadek, K.M.; Elbestawy, A.R. and Mourad, D.M. (2019): The Protective Role of Date Palm (Phoenix Dactylifera Seeds) against Aflatoxicosis in Broiler Chickens Regarding Carcass Characteristics, Hepatic and Renal Biochemical Function Tests and Histopathology. World Vet. Journal. 9(2): 59-69.
- Abdel-raheem, M.SH. and Esmail, H.S.Z. (2012): EFFECTS OF MANNAN OLIGOSACCHARIDES AS A DIETARY SUPPLEMENT ON PERFORMANCE AND CARCASS CHARACTERISTICS OF JAPANESE QUAILS (COTURNIX JAPONICA). Assiut Vet. Med. J ,58 (134) :303-311.
- Ahangaran, G.M.; Rangsaz, N. and Azizi, S. (2016): Evaluation of turmeric (Curcuma longa) effect on biochemical and pathological parameters of liver and kidney in chicken aflatoxicosis. Pharmaceutical Biology, 54(5): 780-787.

- Andretta, I.; Kipper, M.; Lehnen, C.R. and Lovatto, P.A. (2012):* Meta-analysis of the relationship of mycotoxins with biochemical and hematological parameters in broilers. *Poult Sci*, 91:376-382.
- Anwer, M.A., EL-metwally, E.A. and Ibrahim, E.M. (2014):* Biochemical, immunological and histopathological studies on the effect of *saccharomyces cerevisiae* in rabbits exposed to aflatoxin B1. *Assiut Vet. Med. J*, 60 (143):71-88.
- Arafat, Y.R.; Khan, H.S. and Saima (2017):* Evaluation of humic acid as an aflatoxin binder in broiler chickens. *Ann. Anim. Sci.*, 17, (1): 241–255.
- Ashry, A.; Taha, M.; Lebda, A.M.; Abdo, W.; El-Diasty, M.E.; Sabreen, E.; Fadl, E.S. and Elkamshishi, M.M. (2022):* Ameliorative effect of nanocurcumin and *Saccharomyces* cell wall alone and in combination against aflatoxicosis in broilers. 18:178.
- Attia, A.Y.; Abd Al-Hamid, E.A.; Allakany, F.H.; Al-Harhi, A.M. and Mohamed, A.N. (2016):* Necessity of continuing of supplementation of non-nutritive feed additive during days 21–42 of age following 3 weeks of feeding aflatoxin to broiler chickens, *Journal of Applied Animal Research*, 44(1): 87-98.
- Benkerroum, N. (2020):* Chronic and Acute Toxicities of Aflatoxins: Mechanisms of Action. *Int J Environ Res Public Health*. 17(2):423.
- Çelik, S.; Erdoğan, Z.; Erdoğan, S. and Bal, R. (2005):* Efficacy of tribasic copper chloride (TBCC) to reduce the harmful effects of aflatoxin in broilers. *Turk. J. Vet. Anim. Sci.*, 29: 909-916.
- Chen, X.; Horn, N.; Cotter, P.F. and Applegate, T.J. (2014):* Growth, serum biochemistry, complement activity, and liver gene expression responses of Pekin ducklings to graded levels of cultured aflatoxin B1. *Poult Sci*, 93: 2028-2036.
- Chen, Y.; Cheng, Y.; Wen, C. and Zhou, Y. (2020):* Protective effects of dietary mannan oligosaccharide on heat stress-induced hepatic damage in broilers. *Environmental Science and Pollution Research*, 27: 29000–29008.
- Cruz, S.B.; Patlan, H.D.; Petrone, M.V.; Pontin, P.K.; Latorre, D.J.; Beyssac, E.; Velasco, H.X.; Guzman, M.R.; Owens, C.; Hargis, M.B.; Arellano, L.R. and Isaias, T.G.(2019):* Evaluation of Cellulosic Polymers and Curcumin to Reduce Aflatoxin B1 Toxic Effects on Performance, Biochemical, and Immunological Parameters of Broiler Chickens. *Toxins*, 11, (121):1-20.
- Darwish, A.H.M. and El shoukary, D.R. (2020):* Effect of dietary supplementation of turmeric powder on growth performance, behavior and blood biochemical parameters of fayoumi broilers. *Assiut Vet. Med. J*. 66 (164): 15-23.
- Duncan, D.B. (1955):* New multiple range and multiple F test. *Biometrics* 11,1-42.
- El-Nekeety, A.A.; Salman, A.S.; Hathout, A.S.; Sabry, B.A.; Abdel-Aziem, S.H.; Hassan, N.S.; and Abdel-Wahhab, M.A. (2017):* Evaluation of the bioactive extract of *actinomyces* isolated from the Egyptian environment against aflatoxin B1- induce cytotoxicity, genotoxicity and oxidative stress in the liver of rats. *Food and Chem. Toxicol*, 105, 241-255.
- Fani Makki, O.; Afzali, N. and Omidi, A. (2013):* Effect of different levels of *Silybum marianum* seeds on growth rate, carcass variables and liver morphology of broilers contaminated with aflatoxin B1. *Poult. Sci. J.* 1 (2): 105-116.
- Gowda, N.K.S. and Ledoux, D.R. (2008):* Use of antioxidants in amelioration of mycotoxin toxicity: a review. *Animal Nutrition and Feed Technology*, 8: 1-11.
- Gowda, N.K.S.; Ledoux, D.R.; Rottinghaus, G.E.; Bermudez, A.J. and Chen, Y.C.*

- (2008): Efficacy of turmeric (*Curcuma longa*), containing a known level of Curcumin, and a hydrated sodium calcium aluminosilicate to ameliorate the adverse effects of aflatoxin in broiler chicks. *Poultry Science*, 87: 1125-1130.
- Hussain, Z.; Khan, Z.M.; Saleemi, K.M.; Khan, A. and Rafique, S. (2016): Clinicopathological Effects of Prolonged Intoxication of Aflatoxin B1 in Broiler Chicken. *Pak Vet J*, 36(4): 477-481.
- Ibrahim, K.S.N., Ahmed, S.N.A and Abdelraheem, E.S.G. (2021): Impact of dietary supplementation of prebiotics on the growth performance and immunity in broilers fed low protein diets. *Assiut Vet. Med. J.* 67 (171): 103-119.
- IFCC (1986): expert panel on enzymes part 3. *J Clin. Chem. Clin. Biochem*, 20:481-495.
- Kaplan, A. and Szalbo, J. (1983): Clinical chemistry: interpretation and techniques, 2nd edition 1983, p 157.
- Khetmalis, R.S.; More, B.K.; Mote, C.S.; Jadhav, S.N. and Aderao, G.N. (2018): Effect of induced aflatoxicosis on haematobiochemical attributes in broilers and its amelioration by using *Emblica officinalis*. *Journal of Entomology and Zoology Studies*, 6(5): 930-933.
- Kubena, L.F.; Huff, W.E.; Harvey, R.B.; Yersin, A.G.; Elissalde, M.H.; Witzel, D.A.; Giroir, L.E.; Phillips, T.D. and Petersen, H.D. (1991): Effects of a Hydrated Sodium Calcium Aluminosilicate on Growing Turkey Poult During Aflatoxicosis 1. *Poult Sci*, 70:1823-1830.
- Kurniasih and Prakoso, A.Y. (2019): Recent Update: Effects of Aflatoxin in Broiler Chickens. *J. World's Poult. Res*, 9(2): 68-77.
- Lande, T.B.; Gangane, G.R.; Moregaonkar, S.D.; Kulkarni, G.B.; Narote, S.R.; Chavan, P.A. and Tandale, R.U. (2019): Ameliorative effect of *withania somnifera* on growth performance and pathomorphological alterations in experimentally induced aflatoxicosis in broilers. *International Journal of Science, Environment and Technology*, 8(2): 298 – 304.
- Li, Y.; Gang, M.Q.; Hong, Z.L.; Wei, H.; Xiang, D.G.; Zhang, Y.J. and Ji, C. (2014): Effects of Lipoic acid on Immune Function, the Antioxidant Defense System, and Inflammation-Related Genes Expression of Broiler Chickens Fed Aflatoxin Contaminated Diets. *Int. J. Mol. Sci.*, 15: 5649-5662.
- Lin, L.; Fua, P.; Chena, N.; Gaoa, N.; Caoa, Q.; Yuea, K.; Xua, T.; Zhanga, C.; Zhangb, C.; Liua, F.; Wang, X. and Huang, S. (2022): Total flavonoids of *Rhizoma Drynariae* protect hepatocytes against aflatoxin B1-induced oxidative stress and apoptosis in broiler chickens. *Ecotoxicology and Environmental Safety* 230:113148.
- Magnoli, A.P.; Rodriguez, M.C.; González Pereyra, M.L.; Poloni, V.L.; Peralta, M.F.; Nilson, A.J.; Miazzo, R.D.; Bagnis, G.; Chiacchiera, S.M. and Cavaglieri, L.R. (2017): Use of yeast (*Pichia kudriavzevii*) as a novel feed additive to ameliorate the effects of aflatoxin B1 on broiler chicken performance. *Mycotoxin Res*, 33:273–283.
- Mourad, M.S.; Donia, R.G.; Mohamed, S.R. and El-Samahy, S.H. (2020): Biological effect of alpha-Lipoic acid on Aflatoxicosis in Broiler chickens. *Australian Journal of Basic and Applied Sciences*, 14(1): 22-34.
- Murali, P. and George, K. (2020): Supplementation of alpha Lipoic acid on serum biochemical, minerals and antioxidant status in broiler chicken fed diet with animal fat. *Journal of Entomology and Zoology Studies*, 8(4): 1622-1626.
- Mustafa, H.E.A.; Sultan, A.H.; Elshabrawy, A.M.; Elghany, E.M.; Hakim, S.A. and Khalaf, D.D. (2018): Immunological Influences of Experimental

- Aflatoxicosis in Broilers and the Protective Role of Mannan Oligosaccharides. *Jordan Journal of Biological Sciences*, 11 (5): 549 – 555.
- Naseem, N.M.; Saleemi, K.M.; Abbas, Z.R.; Khan, A.; Khatoon, A.; Gul, T.S.; Imran, M.; Sindhu, Z. and Sultan, A. (2018): Hematological and Serum Biochemical Effects of Aflatoxin B1 Intoxication in Broilers Experimentally Infected with Fowl Adenovirus-4 (FAdV-4). Pak Vet J, 38(2): 209-213.*
- Neeff, D.V.; Carão, A.C.P.; Gonçalves, B.L.; Bordin, K.; Corassin, C.H.; Ledoux, D.R.; Rottinghaus, G.E. and Oliveira, C.A.F. (2018): Natural antioxidants as detoxifying agents for aflatoxins in animal feed. Animal Nutrition and Feed Technology, 18: 281-295.*
- NRC (1994): Nutrient Requirements of Poultry. (9th rev. Ed.). National Research Council National Academy Press. Washington, D.C., USA.*
- Resanovic, R.M.; Nešic, K.D.; Nesic, V.D.; Palic, T.D. and Jacevic, V.M. (2009): Mycotoxins. In: Poultry Production. Proc. Nat. Sci, Matica Srp-s ka Novi. Sad. 116: 7-14.*
- Ruan, D.; Zhu, Y.W.; Fouad, A.M.; Yan, S.J.; Chen, W.; Zhang, Y.N.; Xia, W.G.; Wang, S.; Jiang, S.Q. and Yang, L. (2019): Dietary Curcumin enhances intestinal antioxidant capacity in ducklings via altering gene expression of antioxidant and key detoxification enzymes. Poult. Sci., 98: 3705–3714.*
- Sakr, A.O.; Nassef, E.; Fadl, E.S.; Omar, H.; Waded, E. and El-Kassas, S. (2020): The Impact of Alpha-Lipoic acid Dietary Supplementation on Growth Performance, Liver and Bone Efficiency, and Expression Levels of Growth-Regulating Genes in Commercial Broilers . J. World Poult. Res, 10(2S): 172-179.*
- Salema, R.; El-Habashib, N.; Fadlc, E.S.; Sakrd, A.O. and Elbiallye, I.Z. (2018): Effect of probiotic supplement on aflatoxicosis and gene expression in the liver of broiler chicken. Environmental Toxicology and Pharmacology, 60: 118–127.*
- Scheuer, P.J. and Chalk, B.T. (1986): Clinical tests: Histopathology. Wolfe Medical Publications, London.*
- Sharma, M. and Singh, R. (2019): Influence of Dietary Inclusion of Zinc in Ameliorating Adverse Effects of Aflatoxin on Immunity, Pathology of Organs and Jejunal Morphometry in Broiler Chickens. Livestock Research International, 7 (3): 193-200.*
- Shehab, A.E.M. (2008): Some studies on broiler chicken nutrition. Thesis, Master of Veterinary Medicine, Benha University, Egypt.*
- Shotwell, O.L.; Hesseltine, C.W.; Stubblefield, R.D. and Sorenson, W.G. (1966): Production of aflatoxin on rice. Journal of Applied Microbiology, 14(3): 425-428.*
- Subhani, Z.; Shahid, M.; Hussain, F. and Khan, J.A. (2018): Efficacy of *Chlorella pyrenoidosa* to ameliorate the hepatotoxic effects of Aflatoxin B1 in broiler chickens. Pak Vet J, 38(1): 13-18.*
- Surai, P.F. and Mezes, M. (2005): Mycotoxins and immunity. Theoretical consideration and practical applications. Praxis Veterinaria 53: 71-88.*
- Szasz, G. and Persij, J.P. (1974): Clin. Chem. Clin. Biochem. 12: 228.*
- Vallianou, G.N.; Evangelopoulos, A.; Schizas, N. and Kazazis, C. (2015): Potential anticancer properties and mechanisms of action of Curcumin. Anticancer Res, 35(2):645-51.*
- Yavuz, O.; Özdemir, Ö.; Ortatatli, M.; Atalay, B.; Hatipoglu, F. and Terzi, F. (2017): The Preventive Effects of Different Doses of Glucomannan on Experimental Aflatoxicosis in Japanese Quails. Brazilian Journal of Poultry Science, 19 (3) 409-416.*
- Yildirim, E.; Yalcinkaya, I.; Kanbur, M.; Çinar, M. and Oruc, E. (2011): Effects*

of yeast glucomannan on performance, some biochemical parameters and pathological changes in experimental aflatoxicosis in broiler chickens. *Revue Méd. Vét.*, 162, (8-9): 413-420.
Zabiulla, I.; Malathi, V.; Swamy, N.L.V.H.; Naik, J.; Pineda, L. and Han, Y.

(2021): The Efficacy of a Smectite-Based Mycotoxin Binder in Reducing AflatoxinB1 Toxicity on Performance, Health and Histopathology of Broiler Chickens. *Toxins*, 13: 856.

تقييم تأثير بعض مضادات الأكسدة في التحكم في سمية الأفلاتوكسين في بدارى التسمين

ياسمين على حسن صديق ، طلبه يونس عبد المطلب ، نشوى حماد محمد ،
 علاء الدين كمال يوسف ، عمر أمين

E-mail: yasminali24@yahoo.com Assiut University web-site: www.aun.edu.eg

اجريت التجربه لدراسة فعالية اثنين من مضادات الأكسدة (الكرمين وحمض ألفا ليبويك) في تقليل التأثيرات الضاره ل ١٠٠ جزء من البليون من الافلاتوكسين على دجاج التسمين المتغذى تجريبيا على علف مضاف له النسبه المذكوره ومقرانه فاعيله مضادات الاكسده بفاعليه احدى المركبات التى تقوم بامتصاص السموم وهى مزيج من المنان والبيتاجلوكان تحت الاسم التجارى اجرىموس®. تم تقسيم مائة وعشرين كتكوت تسمين بعمر يوم واحد بشكل عشوائي إلى خمس مجموعات (٢٤ طائر / مجموعة) على النحو التالى المجموعة ١: المجموعه الضابطه السلبي المجموعة ٢: المجموعه الضابطه الايجابيه والتي تغذت على علف مضاف له ١٠٠ جزء من البليون من الافلاتوكسين . المجموعه ٣ والتي تغذت على علف مضاف له ١٠٠ جزء من البليون من الافلاتوكسين مضافا له الكركمين (١ جم | كجم), المجموعه ٤: والتي تغذت على علف مضاف له ١٠٠ جزء من البليون من الافلاتوكسين مضافا له حمض ألفا ليبويك (٣٠٠ مجم | كجم) , المجموعه ٥: والتي تغذت على علف مضاف له ١٠٠ جزء من البليون من الافلاتوكسين مضافا له اجرىموس(اجم | كجم).بدات التجربه من عمر يوم واستمرت الى ثلاثون يوما وقد لوحظ التالى:

- ١- اضافته الكركمين والاجرىموس اظهرت تحسنا معنويا على وزن الجسم بالمقارنه بالمجموعه الضابطه الايجابيه .
- ٢- كما ان اضافته الكركمين وحمض الليبويك والاجرىموس ادت الى اظهار تحسنا معنويا على نسبة التحويل الغذائى بالمقارنه مع المجموعه الضابطه الايجابيه.
- ٣- أظهرت التلات مجموعات المعالجه انخفاضًا في النتائج السريرية للدجاج المرضى والآفات الجسمية والآفات النسيجية المرضية للطيور على طول التجربة بالمقارنه مع المجموعه الضابطه الايجابيه.
- ٤- استخدام الكركمين وحمض الليبويك والأجرىموس قلل معنويا من الآثار السلبية للأفلاتوكسين على إنزيمات الكبد وبروتين المصل والكرياتينين . ومن تلك النتائج تم استنتاج ان مضادات الاكسده مثل الكركمين وحمض الليبويك ادت الى تقليل تأثير الافلاتوكسين على دجاج اللحم بنسبه متقاربه مع تأثير خليط المنان والبيتاجلوكان كاحد ممسكات السموم العضويه .